

## Variant Technique of Extra-Anatomic Aortic Bypass in Aortic Recoarctation

Marcelo Biscegli Jatene, Alex Celulari, Nana Miura, Carla Tanamati, Vitor Oliveira Carvalho, Miguel Barbeiro Marcial  
Serviço de Cirurgia Cardíaca Pediátrica do Instituto do Coração do Hospital das Clínicas da Faculdade de medicina da USP (InCor-HCFMUSP), São Paulo, SP - Brazil

### Introduction

Coarctation of the aorta (CoAo) is a congenital narrowing of the proximal region of the descending aorta, adjacent to the site of insertion of the ductus arteriosus or ligamentum arteriosum. Less frequently, the CoAo is located more proximally, between the left common carotid and left subclavian arteries, or in other segments of the aortic arch. It can occasionally occur in the descending thoracic aorta and abdominal aorta. The incidence of CoAo is estimated in 1:1,323 live births, ranking sixth amongst the congenital heart diseases<sup>1</sup>.

After the surgical repair of the CoAo, some complications can occur during the postoperative period, the most common being aortic recoarctation, whose incidence varies, being mostly related to technical and surgical aspects or to the anatomical complexity of the coarctation. In cases of aortic recoarctation, mainly in adults, the extra-anatomic aortic bypass is a viable alternative<sup>2</sup>.

This case report was aimed at describing the use of a technical variant of the extra-anatomic aortic bypass during the surgery of an adult patient, who had previously undergone CoAo repair, and had aortic recoarctation during the evolution.

### Case report

The patient is a 27-year-old white female, who sought the Outpatient Clinic for Congenital Heart Diseases of the Instituto do Coração of the FMUSP, complaining of exertional fatigue. She was on Atenolol and Captopril. Her physical examination showed the following: arterial blood pressure of 145/86 mm Hg on the right upper limb and 120/80 mm Hg on the left upper limb; decreased pulse on the left radial artery and on the lower limbs; and systolic murmur (4+/6+) on the left sternal margin. The patient underwent bovine pericardial patch isthmus plasty for CoAo repair, via left lateral thoracotomy, on 08/23/1999, at the age of 19 years. The echocardiogram showed the following: good ventricular

function; left ventricular hypertrophy and mild dilation ( $\Delta D$ : 37%); tortuous aortic arch with a narrowing site (gradient: 45 mm Hg); and perimembranous ventricular septal defect (VSD) of 7.5 mm. Magnetic resonance imaging (MRI) showed hypoplasia of the aortic arch, and CoAo located immediately before the emergence of the left subclavian artery (Figure 1).

The patient underwent surgery to close the VSD and repair the CoAo in June 2007. She had a good postoperative evolution, being discharged from the hospital in good clinical conditions on the seventh postoperative day.

The surgery was performed through median sternotomy. After dissecting the ascending aorta, aortic arch and its branches, and the initial segment of the descending aorta, the presence of CoAo was confirmed. The coarctation was located immediately before the emergence of the left subclavian artery, and showed a significant reduction in diameter. Because of the segmentary hypoplasia of the aortic arch in addition to the impossibility of aortic mobilization for termino-terminal anastomosis, a Dacron prosthesis (#26) was inserted parallel to the trajectory of the aortic arch. Proximal anastomosis was performed at the beginning of the aortic arch, and distal anastomosis, right after the emergence of the left subclavian artery in the descending aorta. The access was performed with the need for neither heart mobilization nor heart traction. The procedure involved lateral clamping of the aorta, with no cardiopulmonary bypass (Figure 2a). Right after CoAo repair, preparation and installation of the cardiopulmonary bypass were performed. The VSD was closed through right atriotomy with bovine pericardial patch, total cardiopulmonary bypass time of 46 min and anoxia duration of 30 min.

The postoperative echocardiogram showed an 8-mmHg gradient through the prosthesis and correction of the VSD without residual shunt. The MRI one month after surgery evidenced the presence of the Dacron prosthesis interposed between the ascending and descending aorta, with neither angulations nor stenosis (Figure 2b).

The patient is asymptomatic 24 months after surgery, and is on Atenolol, 40 mg, 2x/day. Her blood pressure is 110/70 mm Hg.

### Keywords

Aortic coarctation/surgery; aortic coarctation/complications; adult; recurrence.

#### Mailing Address: Prof. Dr. Marcelo B. Jatene •

Av. Dr. Enéas de Carvalho Aguiar, 44. Postal Code 05403-000, Cerqueira Cesar, SP, Brazil.  
Serviço de Cirurgia Cardíaca Pediátrica, Bloco 2, 2º andar, sala 5, InCor HCFMUSP.

Email: marcelo.jatene@incor.usp.br

Manuscript received November 16, 2011; manuscript revised November 18, 2011; accepted December 19, 2011.

### Discussion

The extra-anatomic aortic bypass was initially described by Vijayanagar et al.<sup>2</sup>, and later by Oliveira et al.<sup>3</sup> for reoperations, in cases in which aortic mobilization was not possible or the aorta was calcified. The results were positive, as reported by Lisboa et al.<sup>4</sup> The procedure was described with cardiopulmonary bypass, but the correction could be performed with lateral clamping of the aorta, which reduces

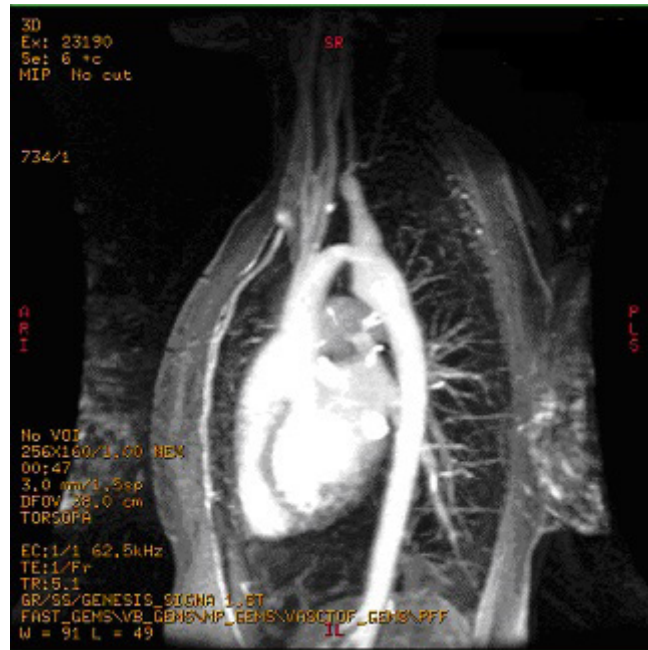


Figure 1 – Magnetic resonance imaging showing hypoplasia of the aortic arch and Coarctation of the aorta before the left subclavian artery

Figure 2a

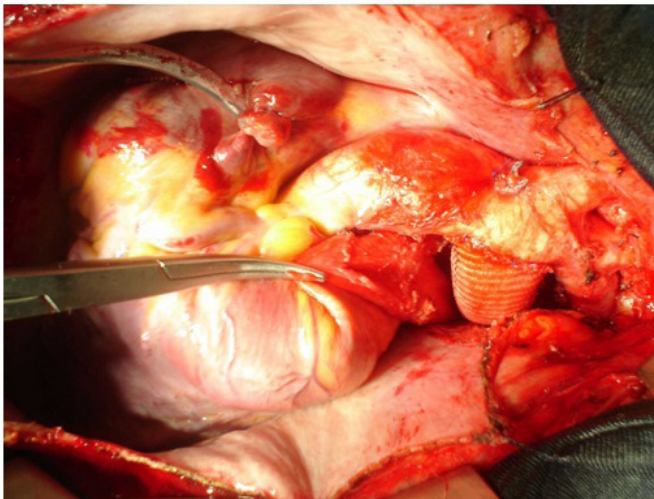


Figure 2b

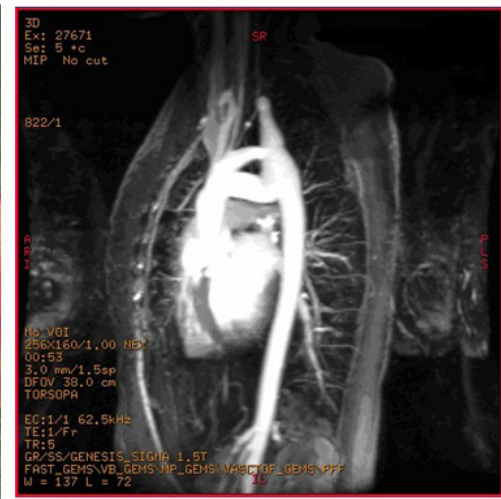


Figure 2a – Final aspect of the operation with Dacron prosthesis anastomosed to the aortic arch; 2b – Magnetic resonance imaging on the 30th postoperative day, evidencing the well-positioned Dacron prosthesis

even more morbidity and mortality rates, because the wide dissection of the aorta and its collateral branches, which are usually hypertrophied and tortuous, is not required.

The following factors account for the great challenge of reoperations for aortic recoarctation: preservation of the spinal cord; preservation of the recurrent laryngeal and phrenic nerves; and the already described difficulty in dissecting the peri-reoarctation region and collateral vessels.

The preferred approach route is also controversial in the literature. While some authors<sup>5</sup> prefer reapproaching via the previous left thoracotomy, others<sup>6</sup> prefer the median sternotomy for complex cases. The combined approach should not be overlooked, especially in the presence of intracardiac lesions associated, and neither should the right thoracotomy<sup>7</sup>.

When CoAo is associated with an intracardiac defect, such as VSD, the best time to intervene surgically and the best approach route for both defects are still controversial. Isomatsu et al.<sup>8</sup> have reported better results operating the defects in different surgical times, with lower comorbidities. Barron et al.<sup>9</sup> prefer to repair coexisting lesions at the same surgical time. In our opinion, the concomitant approach of the defects should be chosen when both defects require immediate correction or correction in the short run. In the presence of intracardiac defects with no hemodynamic repercussion, the CoAo can be solved first, and the repair of the intracardiac defect can be postponed to a second occasion.

There is a tendency in the literature to repair aortic recoarctation by using the extra-anatomic technique, because of its relative easiness and smaller dissection of adhered planes, which might lead to lesions in the aorta or its adjacent structures.

Daebritz et al.<sup>5</sup> have preferred to perform the extra-anatomic aortic bypass via left posterolateral thoracotomy, with mild hypothermia (33.6-31°C); however, patients with associated intracardiac defects were excluded.

Regarding the graft to be used, Schoenhoff et al.<sup>10</sup> have preferred to use expanded polytetrafluoroethylene (ePTFE) reinforced with rings. We preferred to use the pre-clotted Dacron prosthesis because of its flexibility and easier handling.

In the case in question, after preparing and dissecting the descending aorta distal to the area of recoarctation, the possibility of graft interposition was considered. This was due to the good extension of the descending aorta that could be exposed, favoring the lateral clamping and graft anastomosis. The use of other less invasive techniques for this patient, such as balloon dilation or implantation of local stent, were excluded because of the location of the recoarctation, which affected the end of the arch, and the risk of aortic dissection, obstruction of the great vessels, in case of stent placement, or even aortic rupture.

After a six-month follow-up, a change in neither the intraluminal flow in the prosthesis nor the intra-aortic flow was observed as compared with those in the immediate postoperative period. We believe that her long-term evolution will be favorable, because the Dacron prosthesis has a long useful life, preventing future re-interventions.

### Conclusion

The surgical technique here presented is feasible, can be performed without cardiopulmonary bypass and with a short hospitalization time. In addition, the technique had good both immediate and six-month results. We believe that the procedure is a safe alternative for the surgery for aortic recoarctation that affects the aortic arch or the area close to the left subclavian artery.

### Potential Conflict of Interest

No potential conflict of interest relevant to this article was reported.

### Sources of Funding

There were no external funding sources for this study.

### Study Association

This study is not associated with any post-graduation program.

### References

1. Keith JD. Coarctation of the aorta. In: Keith JD, Rowe RD, Vlad P. (eds). Heart disease in infancy and childhood. New York: MacMillan; 1978. p. 736-57.
2. Vijayanagar R, Natarajan P, Eckstein PF, Bognolo DA, Toole JC. Aortic valvular insufficiency and postductal aortic coarctation in the adult: combined surgical management through median sternotomy: a new surgical approach. *J Thorac Cardiovasc Surg.* 1980;79(2):266-8.
3. de Oliveira SA, de Oliveira HA, Kedor HH, Auler JO Jr, de Souza JM. Variante técnica para operação de coarctação do arco aórtico. *Arq Bras Cardiol.* 1981;37(5):395-7.
4. Lisboa LAF, Abreu Filho CAC, Dallan LAO, Rochitte CE, Sousa JM, Oliveira SA. Tratamento cirúrgico da coarctação do arco aórtico em adulto: avaliação clínica e angiográfica tardia da técnica extra-anatômica. *Rev Bras Cir Cardiovasc.* 2001;16(3):187-94.
5. Daebritz S, Fausten B, Sachweh J, Mühler E, Franke A, Messmer BJ. Anatomically positioned aorta ascending-descending bypass grafting via left posterior thoracotomy for reoperation of aortic coarctation. *Eur J Cardiothorac Surg.* 1999;16(5):519-23.
6. Kanter KR, Erez E, Williams WH, Tam VKH. Extra-anatomic aortic bypass via sternotomy for complex aortic arch stenosis in children. *J Thorac Cardiovasc Surg.* 2000;120(5):885-90.
7. Caspi J, Ilbawi MN, Milo S, Bar-El Y, Roberson DA, Thilenius OG, et al. Alternative techniques for surgical management of recoarctation. *Eur J Cardiothorac Surg.* 1997;12(1):116-9.
8. Isomatsu Y, Imai Y, Shin'oka T, Aoki M, Sato K. Coarctation of the aorta and ventricular septal defect: should we perform a single-stage repair? *J Thorac Cardiovasc Surg.* 2001;122(3):524-8.
9. Barron DJ, Lamb RK, Ogilvie BC, Monro JL. Technique for extraanatomic bypass in complex aortic coarctation. *Ann Thorac Surg.* 1996;61(1):241-4.
10. Schoenhoff FS, Berdat PA, Pavlovic M, Kadner A, Schwerzmann M, Pfammatter JP, et al. Off-pump extraanatomic aortic bypass for the treatment of complex aortic coarctation and hypoplastic aortic arch. *Ann Thorac Surg.* 2008;85(2):460-4.