

## Surgical Repair of Aortopulmonary Window in Twins: A Case Report

Marcelo Biscegli Jatene<sup>1,2</sup>, Patricia Marques Oliveira<sup>2</sup>, Fabiana Succì<sup>2</sup>, Stevan Kriger Martins<sup>2</sup>, Vitor Oliveira Carvalho<sup>1</sup>, Ieda Biscegli Jatene<sup>2</sup>

Serviço de Cirurgia Cardíaca Pediátrica do Instituto do Coração do Hospital das Clínicas da Faculdade de Medicina da USP (InCor-HCFMUSP)<sup>1</sup>; Serviço de Cirurgia Cardíaca Pediátrica do Hospital do Coração (HCor)<sup>2</sup>, São Paulo, SP – Brazil

### Introduction

The aortopulmonary window (APW) is a rare congenital heart disease, caused by a septal defect in the common truncus arteriosus into the aorta and pulmonary artery. This septal defect between the ascending aorta and the trunk and/or right pulmonary artery hemodynamically resembles a large patent ductus arteriosus or, more appropriately, the common arterial trunk<sup>1</sup>.

The clinical symptoms in patients with APW are related to pulmonary blood flow and the magnitude of the septal defect between the ascending aorta and the trunk and / or pulmonary artery. Considering Mori's classification<sup>2</sup>, the APW can be classified into three main types; type I (proximal) - above the sinus of Valsalva; type II (distal) - in the distal ascending aorta and type III (total) throughout the ascending aorta. The most common one is type I.

Although there are some reports in the literature on APW, there has been no description in twins. The aim of this study is to describe the surgical treatment of two monozygotic twins with type I APW, as well as technical aspects and follow-up.

### Case Report

Two one-year-old male monozygotic twins had shown gradual manifestations of fatigue during breastfeeding for 3 months and progressive symptoms of heart failure.

The clinical assessment in association with echocardiography and cardiac catheterization confirmed the diagnosis of type I APW (Mori) without associated defects. The angiographic appearance was very similar in the two children (Figure 1).

The surgery was performed in both children by median sternotomy. In both cases, after opening the pericardium, we identified the APW in the proximal ascending aorta and the pulmonary trunk. After careful dissection and isolation of the

APW, we chose not to use cardiopulmonary bypass (CPB), due to the favorable anatomy. After lateral clamping of the aorta and pulmonary trunk, the APW was sectioned and the edges were sutured with two running polypropylene stitches 6-0 (Figure 2-A). The surgical outcome was considered favorable in both cases, without retractions or angles arising from sutures (Figure 2-B). Both children were operated on the same day by decision of the family.

Both children showed good postoperative course, with the occurrence of hypertension in the early hours, which was controlled by intravenous medication (nitroprusside) followed by oral medication (captopril). Both patients remained in the pediatric intensive care unit for 48 hours and were discharged from the hospital 7 days after surgery.

### Follow-up

The 5-years follow-up showed proper development of the twins. The children remain asymptomatic, with adequate weight and height development for their age, without the use of any type of medication. The control echocardiogram showed adequate correction of the APW, no retractions or expansions at the site of surgery and preserved cardiac function in both ventricles.

### Discussion

This case report describes for the first time in literature the presence of APW in twins. In addition, it describes the surgical procedure and the 5-year follow-up.

The surgical treatment of APW is indicated as soon as possible after the diagnosis of heart disease in order to prevent the development of irreversible pulmonary hypertension<sup>3</sup>. The diagnosis of APW can be made in the pre-natal period, which allows the surgical correction to be performed in the neonatal period<sup>4,5</sup>.

Historically, in 1952, Gross performed the first surgical correction of APW in a 4-year-old patient. Thereafter, surgical techniques have improved over the years. The aortotomy allows optimal visualization of the lesion and identification of all anatomical structures<sup>6</sup>. Surgical correction of the APW is performed with CPB in most of the cases, but in this case, it was decided to perform the procedure without ECC due to the favorable anatomy. By dissecting the APW, we identified enough area for positioning two clamps without compromising the lumen of the aorta and pulmonary trunk with the technical possibility of sectioning the APW and

### Keywords

Heart Defects, Congenital / surgery; Heart Septal Defects / surgery; Twins, Monozygotic; Sternotomy.

#### Mailing Address: Marcelo B. Jatene •

Av Dr. Enéas de Carvalho Aguiar, 44. Serviço de Cirurgia Cardíaca Pediátrica, Bloco 2, 2º andar, sala 5. InCor HCFMUSP. Postal Code 05403-900, São Paulo, SP – Brazil  
Email: marcelo.jatene@incor.usp.br  
Manuscript received February 8, 2012; manuscript revised February 9, 2012; accepted July 3, 2012.

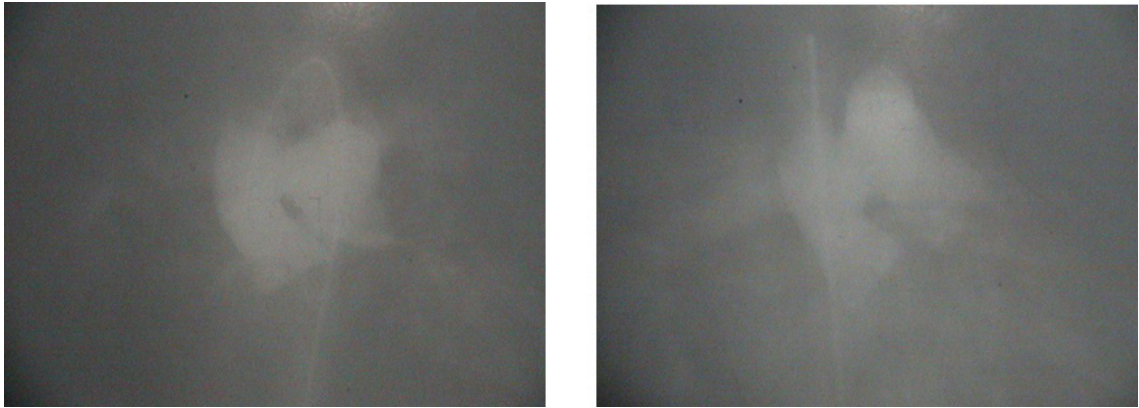


Figure 1 - Angiographic appearance in the twins

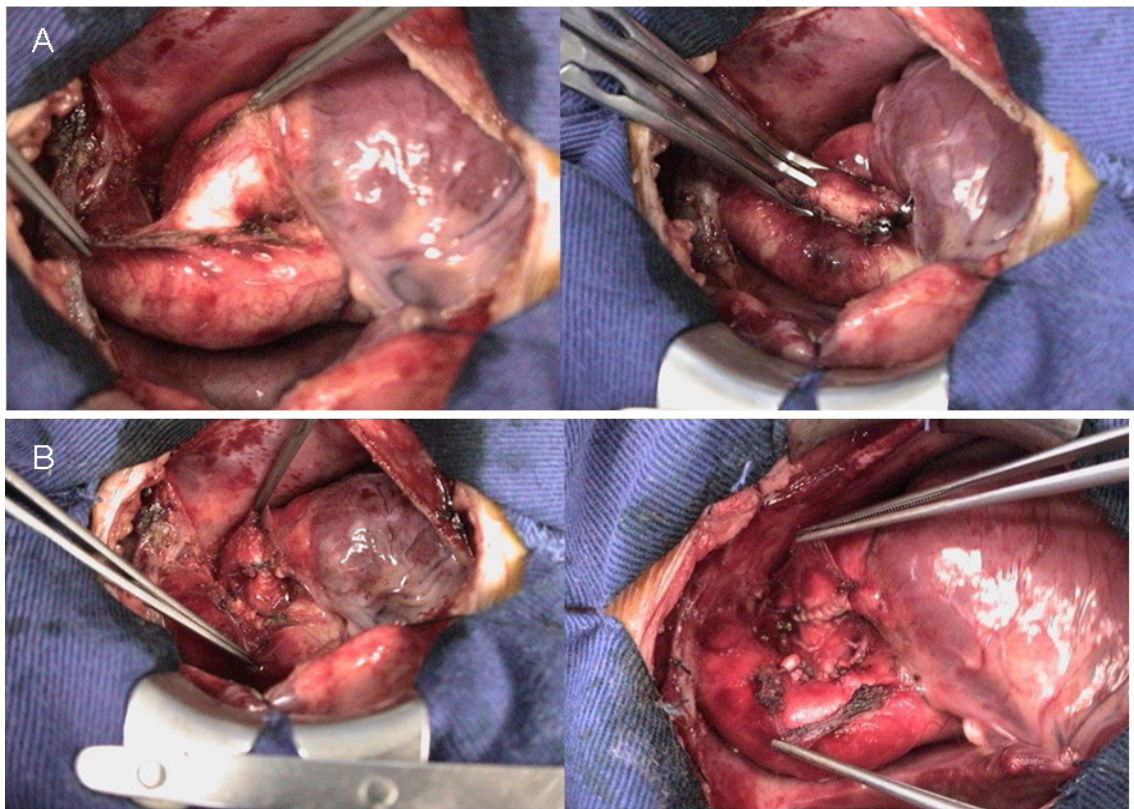


Figure 2 - Aortopulmonary window section and edge suture (A). Favorable surgical outcome (B)

isolated suturing of the two edges. In both surgical cases, the CPB was prepared and available, as previously planned.

It is known that survival after surgical correction of APW is related to the presence of associated malformations, age at diagnosis and adequate reconstruction of vascular structures<sup>7</sup>. Some previous reports found no immediate or late deaths during

a follow-up period of 2 weeks to 28 years<sup>3</sup>. When the APW is not treated, mortality rates can reach 40% in the first year of life<sup>8</sup>. The early diagnosis and treatment associated with the techniques of myocardial protection have contributed to an improvement in the results of surgery in recent years<sup>3</sup>. In both children, there were no deaths or complications except hypertension.

## Case Report

In some selected cases, closing the APW can be carried out by percutaneous technique with a modified double-umbrella occluder system, but the results in the medium and long term are not well established<sup>9</sup>.

Although some cases have been reported in the literature, there has been no report about the occurrence, treatment and follow-up of APW in twins. Reports about the association between genetic and congenital heart disease have been published in the literature, but it remains an open field in pediatric cardiology. Geneticists and clinicians debate whether congenital heart diseases can be caused by a defect in a single gene<sup>10</sup>. Our case report contributes to this debate, although no specific genetic study was performed in the twins.

In conclusion, a very similar APW was found in two monozygotic male twins. The surgical aspects were very

favorable and, after 5 years, the children have remained asymptomatic with normal cardiac function and without use of medication.

### Potential Conflict of Interest

No potential conflict of interest relevant to this article was reported.

### Sources of Funding

There were no external funding sources for this study.

### Study Association

This study is not associated with any post-graduation program.

## References

1. Samánek M, Vorísková M. Congenital heart disease among 815,569 children born between 1980 and 1990 and their 15-year survival: a prospective Bohemia survival study. *Pediatr Cardiol*. 1999;20(6):411-7.
2. Mori K, Ando M, Takao A, Ishikawa S, Imai Y. Distal type of aortopulmonary window: report of 4 cases. *Br Heart J*. 1978;40(6):681-9.
3. Backer CL, Mavroudis C. Surgical management of aortopulmonary window: a 40-year experience. *Eur J Cardiothorac Surg*. 2002;21:773-9.
4. Tometzki AJ, Suda K, Kohl T, Kovalchin JP, Silverman NH. Accuracy of prenatal echocardiographic diagnosis and prognosis of fetuses with conotruncal anomalies. *J Am Coll Cardiol*. 1999;33(6):1696-701.
5. Valsangiacomo ER, Smallhorn JF. Images in cardiovascular medicine. Prenatal diagnosis of aortopulmonary window by fetal echocardiography. *Circulation*. 2002;105(24):E192.
6. Jansen C, Hruda J, Rammeloo L, Ottenkamp J, Hazekamp MG. Surgical repair of aortopulmonary window: thirty-seven years of experience. *Pediatr Cardiol*. 2006;27(5):552-6.
7. Erez E, Dagan O, Georghiou GP, Gelber O, Vidne BA, Birk E. Surgical management of aortopulmonary window and associated lesions. *Ann Thorac Surg*. 2004;77(2):484-7.
8. Tkebuchava T, von Segesser LK, Vogt PR, Bauersfeld U, Jenni R, Kunzli A, et al. Congenital aortopulmonary window: diagnosis, surgical technique and long-term results. *Eur J Cardiothorac Surg*. 1997;11(2):293-7.
9. Stamato T, Benson LN, Smallhorn JF, Freedom RM. Transcatheter closure of an aortopulmonary window with a modified double umbrella occluder system. *Cathet Cardiovasc Diagn*. 1995;35(2):165-7.
10. Pierpont ME, Basson CT, Benson DW Jr, Gelb BD, Giglia TM, Goldmuntz E, et al.; American Heart Association Congenital Cardiac Defects Committee, Council on Cardiovascular Disease in the Young. Genetic basis for congenital heart defects: current knowledge: a scientific statement from the American Heart Association Congenital Cardiac Defects Committee, Council on Cardiovascular Disease in the Young: endorsed by the American Academy of Pediatrics. *Circulation*. 2007;115(23):3015-38.