

Case 3/2015 A 32-year-old Female Patient with Coarctation of the Aorta, Bicuspid Aortic Valve and Dilatation of the Ascending Aorta

Edmar Atik, Raul arrieta, Roberto Kalil Filho

Hospital Sírio Libanês de São Paulo, São Paulo, SP – Brazil

Clinical data: The patient reports that a heart murmur had been heard at childhood; however, the diagnosis of coarctation of the aorta was made 1 month ago by echocardiogram and CT scan, performed due to recent complaints of tired legs. She performed physical activities on a regular basis and did not report headache. She was not receiving any specific medication.

Physical examination: Normal breathing; acyanotic; brisk pulses in upper limbs, absent in lower limbs. Weight: 58 kg; height: 166 cm; blood pressure (BP) in right arm equal to that in left arm = 140/80 mmHg, BP in legs: 80 mmHg; heart rate (HR): 78 bpm; oxygen saturation: 96%. Aorta clearly palpable on the suprasternal notch. Thrill and grade 1/4 mild systolic murmur on the suprasternal notch.

The apical impulse was not palpable in the precordium, and there were no systolic impulses on the left sternal border. Normal heart sounds; grade 1/4 systolic murmur in the aortic area and back, both on the right and left sides. Liver not palpable.

Laboratory tests

Electrocardiogram showed normal sinus rhythm with no signs of chamber overload. The Sokolow index was 34 mm and there was no ventricular repolarization abnormalities. PA: +60°; QRSA: +70°; TA: +40°.

Chest radiograph showed normal cardiac silhouette (cardiothoracic ratio of 0.47). The pulmonary vascular network was normal and the arch of the pulmonary artery was concave. The right upper arch was elongated, suggesting dilatation of the ascending aorta (AscAo). The posterior aortic arch was somewhat prominent and the descending aorta (DescAo) was dilated. Hyperdensity was observed in some ribs (Figure 1).

Echocardiogram showed bicuspid aortic valve with maximum and mean pressure gradients of 31 and 17 mmHg, respectively. The AscAo was dilated (44 mm), the aortic arch had 37 mm and the isthmus region was narrowed, with a pressure gradient of 47 mmHg. The size of the cardiac

chambers was normal, with no myocardial hypertrophy (septum/posterior wall = 10 mm). Left ventricular function was normal (70%).

CT angiography of the aorta showed dilated AscAo (42 mm), aortic crossing (22 mm) and clear 8-mm diameter narrowing in the beginning of the DescAo, being 20 mm diameter at the level of the diaphragm. There was marked collateral circulation.

Cardiac catheterization (Figure 2). Pressure levels were as follows: left ventricle (LV) = 160/12; AscAo = 140/82; and DescAo = 100/80 mmHg. Angiography showed clear narrowing in the aortic isthmus and dilatation of the AscAo and DescAo.

Clinical diagnosis: Severe coarctation of the aorta in the isthmus region and mild aortic valve stenosis in a bicuspid valve with marked ascending aorta dilatation, in natural course.

Clinical reasoning: The clinical elements of coarctation of the aorta are clear and easy to identify, and are mainly represented by contrasting pulses and BP between the upper and lower limbs. Noteworthy, despite the long-standing heart disease with pressure overload, no myocardial hypertrophy or signs of electric overload are observed, and the symptoms are recent and mild. This results from the development of an efficient collateral circulation. Chest radiograph with normal cardiac silhouette expresses preserved ventricular function, and AscAo dilatation suggests the possibility of DescAo obstruction, in addition to the aortic valve stenosis.

Differential diagnosis: Aortic obstruction in adulthood generally results from previous aortitis, as occurs in Takayasu and Kawasaki diseases; connective tissue diseases; and infectious diseases, such as syphilis.

Management: In view of the long-standing systolic impact, even without myocardial hypertrophy and with increased pressures in the proximal aorta circuit, operation is mandatory aiming at relieving the arterial obstruction, which would imply a greater possibility of development of myocardial fibrosis, heart failure, arrhythmias and earlier death. Dilatation of the isthmus region was chosen using therapeutic cardiac catheterization from the right femoral artery with placement of a 40 x 20-mm stent just past the origin of the left subclavian artery. BP levels immediately increased to 200 mmHg and decreased in the sequence. Adequate enlargement of the region was achieved (Figure 2) with equalization of pressures between limbs. Severe chest pain extending to the back persisted for 12 hours, accompanied by BP elevation to 150/100 mmHg; both were relieved by dolantine and beta-blockers. BP decreased to normal levels of 125/80 mmHg in upper and lower limbs. The systolic murmur of aortic valve stenosis remained unchanged.

Keywords

Coarctation of Aorta; Bicuspid Aortic Stenosis; Dilatation of Aorta.

Mailing Address: Edmar Atik •

Rua Dona Adma Jafet, 74, conj. 73, Bela Vista. Postal Code 01308-050, São Paulo, SP – Brazil

E-mail: eatik@cardiol.br; conatik@incor.usp.br

Manuscript received July 23, 2014; revised manuscript August 08, 2014; accepted August 08, 2014.

DOI: 10.5935/abc.20140220

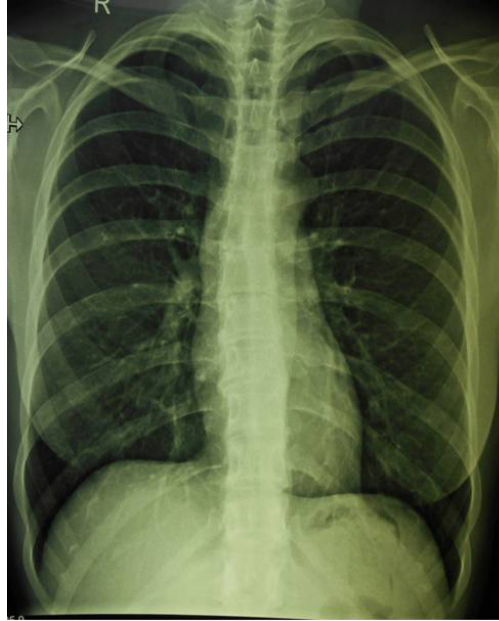

Figure 1 – Chest radiograph shows normal cardiac silhouette, with slightly bulged right upper arch (dilated ascending aorta) and also dilated descending aorta. Hyperdensity can be observed in some lower borders of ribs.

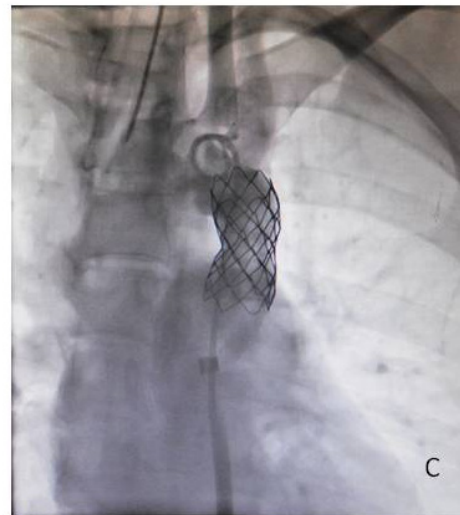
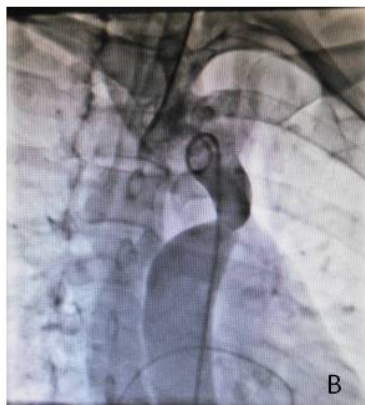
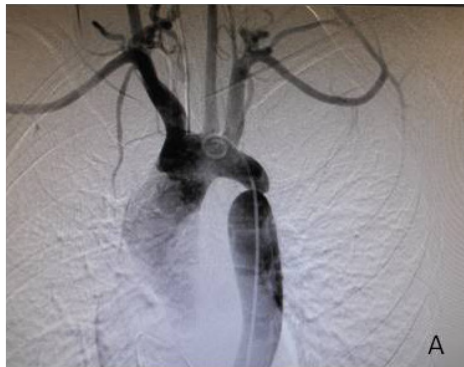

Figure 2 – Angiography showing dilated ascending aorta. Diameter of the aortic crossing decreases up to the isthmic coarctation; descending aorta dilatation in A and B. Effective 40 x 20-mm stent placement in the stenotic region in C.

Clinicoradiological Session

Commentaries: Obstructive congenital anomaly usually manifests early in life by means of a heart murmur. In sudden obstruction during the neonatal period, as occurs in coarctation of the aorta, classic signs of congestive heart failure appear and require immediate surgical intervention. Cardiac compensation with maintained antegrade flow is achieved by the myocardial hypertrophy and development of collateral circulation. In the present case, the favorable course up to the fourth decade of

life, with more recent manifestation of symptoms, resulted from an efficient collateral circulation. Even when it causes less impact, this obstructive anomaly should be treated earlier to prevent an unfavorable outcome in relation to the development of myocardial fibrosis, arrhythmias and heart failure. In the course of bicuspid aortic valve, unfavorable elements such as AscAo dilatation with deficiency of the parietal muscle¹ arise, and this should be invariably treated surgically in due time.

Reference

1. Grewal N, Gittenberger-de Groot AC, Poelmann RE, Klautz RJ, Lindeman JH, Goumans MJ, et al. Ascending aorta dilation in association with bicuspid aortic valve: a maturation defect of the aortic wall. *J Thorac Cardiovasc Surg.* 2014;148(4):1583-90.