

Hypothermia-Induced Electrocardiographic Changes

Ana Marques,¹ Daniel Caldeira,² Alexandra Briosa,¹ Isabel João,¹ Hélder Pereira¹

Hospital Garcia de Orta EPE,¹ Almada - Portugal

Centro Cardiovascular da Universidade de Lisboa - CCUL, Laboratório de Farmacologia Clínica e Terapêutica, Faculdade Medicina, Universidade de Lisboa, Lisboa - Portugal

An elderly female patient was brought to the Emergency Department due to loss of consciousness. The past medical history was remarkable for hypercholesterolemia and essential hypertension. The patient was not treated with any negative chronotropic drug. At the admission, the patient's blood pressure was 90/60 mmHg, she had bradycardia (42/minute), and hypothermia (33°C). Electrocardiogram (ECG) showed sinus bradycardia, 1st grade atrioventricular block, long corrected QT interval, and Osborn waves at the end of QRS complexes (Figure 1 A, arrowheads). Accordingly, these positive notching deflections were best seen in lateral

precordial leads and disappeared after warming the patient to 36°C (Figure 1B). The bradycardia, atrioventricular block, and QT prolongation were also resolved (Figure 1 B). During the inward stay, head computed tomography scan, 24-hour Holter, and laboratory analysis were unremarkable for pathological findings. Transthoracic echocardiogram only revealed degenerative aortic and mitral valve changes. This case is illustrative of hypothermia-induced electrocardiographic changes, namely prolongation of the PR, RR and QT intervals and particularly the presence of Osborn Waves.^{1,2}

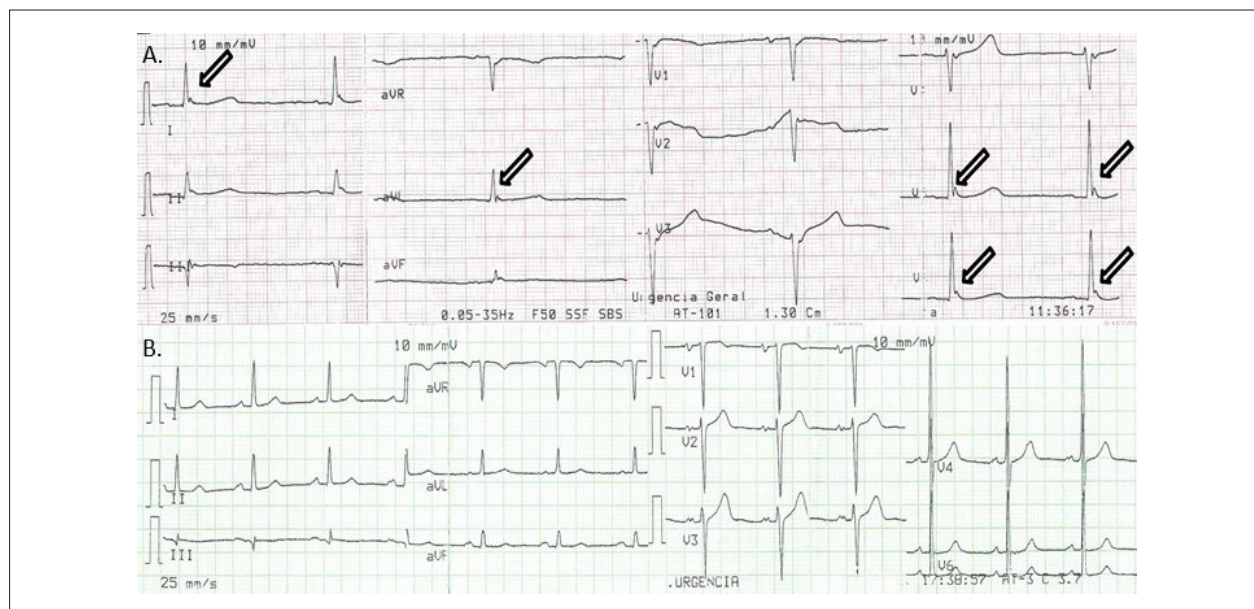


Figure 1 – Panel A) Electrocardiogram (ECG) showing hypothermia-induced ECG changes: sinus bradycardia, 1st grade atrioventricular block, long corrected QT interval, and Osborn waves at the end of QRS complexes (arrowheads). **Panel B)** The ECG after warming the patient showing resolution of hypothermia-induced ECG changes.

Keywords

Bradycardia; Atrioventricular Block; Electrocardiography/ methods; Hypothermia; Osborn Waves.

Mailing Address: Ana Marques •

Hospital Garcia de Orta EPE – Av. Torrado da Silva, 2801-951, Almada – Portugal

E-mail: ana.smc.25@gmail.com

Manuscript received February 11, 2020, revised manuscript March 22, 2020, accepted March 22, 2020

DOI: <https://doi.org/10.36660/abc.20200081>

References

1. Alhaddad IA, Khalil M, Brown EJ Jr. Osborn waves of hypothermia. *Circulation*. 2000;101(25):E233-E244.
2. Doshi HH, Giudici MC. The EKG in hypothermia and hyperthermia. *J Electrocardiol* 2015; 48(2):203–8.



This is an open-access article distributed under the terms of the Creative Commons Attribution License