

MALIGNANT TRANSFORMATION OF A RAT FIBROMA BY THE  
TREATMENT WITH AN ANTI-FIBROSING DRUG:  
CY-168F (PLASTENAN)

SONIA G. ANDRADE\*  
JEAN ALEXIS GRIMAUD\*\*  
ERIC TABONE\*\*  
MANOEL BARRAL NETTO\*

*Fifteen albino (Sprague Dawley) rats with subcutaneous transplanted fibromas was used in the present study. The tumour was formed by typical fibroblasts in a dense collagen matrix and was provenient from a fibroma that appeared spontaneously in an albino rat of the same strain. Ultrastructurally, collagen disclosed normal periodicity and the fibroblasts showed irregular notched nuclei with irregular distribution of chromatin, that suggests transitional aspects to fibrosarcoma. The 15 animals, from different passage groups, were divided into: 8 animals submitted to treatment with the drug acexamic acid (CY-168F) – N acetyl-amino-6-hexanoic acid (Plastenan) and 7 untreated control animals. Three of the treated animals showed a malignant transformation to fibrosarcoma. Transitional histological features from typical fibroma to highly undifferentiated fibrosarcoma could be detected in one animal subjected to repeated biopsies. Ultrastructural study disclosed nuclear alterations and hyperactive ergastoplasm and collagen containing inclusions into the cytoplasm of fibroblasts. In the group of 7 untreated animals, no malignant transformation could be detected histologically. Two aspects deserve attention: the malignant potential of a typical fibroma and the apparent effect of an antifibrosing drug in inducing malignization of this tumour.*

A subcutaneous fibroma which occurred spontaneously in an albino (Sprague Dawley) rat, was successfully transplanted to other rats of the same strain. As described previously by us (Andrade & Grimaud, 1977), this tumour was formed by typical fibroblasts in a dense collagen matrix. Collagen disclosed normal periodicity and the fibroblasts showed irregular, notched nuclei and irregular distribution of chromatin, suggesting transitional features between fibroma and fibrosarcoma.

Considering the dense collagenous matrix present both in the original tumour and in those transplanted, we decided to investigate the effect of an antifibrosing drug:

---

\* Departamento de Patologia – Faculdade de Medicina, Universidade Federal da Bahia – 40000 Salvador, Bahia, Brasil.

\*\* Centre de Microscopie Electronique - Institut Pasteur de Lion, France.

acexamic acid (CY-168F) – Plastenan,<sup>1</sup> on this tumour. This drug has been tested before on experimental cirrhosis of the rat (Gmaz-Nikulín & Sterne, 1966; Marichy, 1973; Tabone, 1976), and in some other models (Flandre et al 1965; Fort & Gineste, 1965; Lagrot, Pessereau & Antoine, 1967).

## MATERIAL AND METHODS

Fifteen *Sprague Dawley* rats, with transplanted fibromas originated from a spontaneous tumour from a rat of the same strain were used. The animals from different passage groups of transplantation were divided into four experimental groups (Tables I and II). They were further divided into 8 treated and 7 untreated animals.

TABLE I

General data on rats with transplanted fibroma treated with plastenan and untreated controls

Experimental groups (No. tumour passages)	Number of rats		Beginning of treatment*	Treatment No doses	Duration of treat. (weeks)
	Treated	Untreated			
2nd	2	3	17 mos.	16	3
3rd	2	—	7 mos.	36	9
4th	3	3	2 mos**	40	8½
5th	1	1	11 mos.	38	9
Total	8	7			

\* Number of months after transplantation of the tumour.

\*\* One of the rats was submitted to a 2nd series of treatment at 15 months after transplantation.

The method of transplantation of the tumour appears elsewhere (Andrade & Grimaud, 1977). It consisted basically in the placement of small fragments of the tumour, immediately after its excision from the animal, under the skin of the abdominal wall of the recipient, under sterile conditions. The fragments were previously washed in Hanks' solution with antibiotics (Penicilin: 50 U/ml and Streptomycin: 50 mcg/ml).

Treatment: acexamic acid (CY-168F) or N acetyl-amino-6-hexanoic acid (Plastenan) was administered daily by gavage in the dosis of 30mg/ 1g b.w., during three to nine weeks. Details on the treatment appear in Table I. The drug was administered in one series for all experimental groups; however, one animal in 4<sup>th</sup> group was treated for a second period 15 months afterwards. Body weight, general health and tumour size were registered periodically. In one of the animals, the one treated twice, biopsy of the tumour were performed 5 months and 10 months after the first treatment and 40 days after the second treatment.

All the animals that died spontaneously or were sacrificed, were submitted to complete necropsies. Fragments of the tumour were fixed in 10% formalin for histopathological study or to double fixation in glutaraldehyde-osmic acid in cacodylate buffer, followed by inclusion in Epon, for electron microscopic study. Histological sections were stained by hematoxylin and eosin, Masson's trichrome, Weigert-Van Gieson for collagen and elastic fibers, Gomori's method for reticulum and Toluidin blue.

<sup>1</sup>Laboratory CHOAY – Paris.

TABLE II

Individual data on rats with fibroma: treated with platenan and untreated controls

Experimental groups ( <sup>1st</sup> four passages)	Animal Ident.	Treatment Yes/No	Evolution*		Tumour size at final (cm)	Final Diagnostic
			Start treat (months)	Period obs. after treat (months)		
2nd	T- 3/1	No	—	5 Biop.	2,0 x 2,0	Fibroma
	T- 3/2	No	—	7 Oper.	3,0 x 1,8	Fibroma
	T- 3/3	No	—	10 Oper.	7,0 x 7,0	Fibroma
	T- 3/4	Yes	17	18 Death	7,0 x 7,5	Fibrosarcoma
	T- 3/5	Yes	17	18 Death	7,0 x 4,0	Fibrosarcoma
3rd	T- 8/1	Yes	7	9 Sacr.	1,0 x 1,0	Fibroma
	T- 8/2	Yes	7	9 Death	1,0 x 1,0	Fibroma
4th	T- 9/1	No	—	7 Death	2,0 x 2,0	Fibroma
	T- 9/2	Yes	2 / 15**	16 Sacr.	4,5 x 3,5	Fibrosarcoma
	T- 9/3	Yes	2	10 Death	4,0 x 3,5	Fibroma
	T- 9/4	No	—	12 Death	3,5 x 3,0	Fibroma
	T- 9/5	No	—	10 Sacr.	2,5 x 2,0	Fibroma
	T- 9/6	Yes	2	7 Sacr.	0,2 x 0,2	Fibroma
5th	T-25/1	No	—	9 Death	5,0 x 4,0	Fibroma
	T-25/2	Yes	11	15 Oper.	1,6 x 1,6	Fibroma

\* Time in months after transplantation.

\*\* Two series of treatment: 2 months and 15 months after transplantation.

## RESULTS

1 — *General features observed in untreated controls* — A dense collagenic stroma was the main feature of the fibroma (Fig. 1a); it stained brightly with Masson's and Van Gieson's stains. Reticulum was scarce and localized around small blood vessels. Toluidin blue stains showed numerous mast cells. By electron microscopy study (Fig. 2) the collagen disclosed normal periodicity and the fibroblasts were well differentiated, but some had exaggerated indented nuclei with irregular chromatin and inclusions of 300 Å. Ergastoplasmic activity was prominent. Neither local invasion or recurrence was seen in the animals in which the tumours had been surgically removed. In one of the animals from the 4<sup>th</sup> experimental group (T-9/5, Table II), a 0,4cm fibromatous nodule of ill defined margins was found in the pulmonary tissue. Its histological appearance was similar to that of the subcutaneous fibroma.

2 — *Platenan treated animals*

a) In three out of 8 treated animals, there was a malignant transformation of the fibroma into a fibrosarcoma (Fig. 1b). Two of these belonged to the 3<sup>rd</sup> passage group (Table II), which were treated after the 17<sup>th</sup> month of transplantation. These animals died spontaneously, three weeks following the beginning of treatment. Histopathologically, marked anaplasia and slight collagenic stroma compatible with fibrosarcoma was present. Another animal, from the 4<sup>th</sup> passage group, treated three months after transplantation, when the tumour had reached 0,2cm in diameter, showed a slow tumour growth following this first treatment. Successive biopsies (Fig. 3a), allowed the detection, four months






Fig. 1 – a) Fibroma with typical fibroblasts and dense collagenic stroma; b) Malignant transformation of a fibroma to a fibrosarcoma in a Plastenan treated animal, showing atypical fibroblasts and slight collagenic stroma. H and E stain, 200 X.

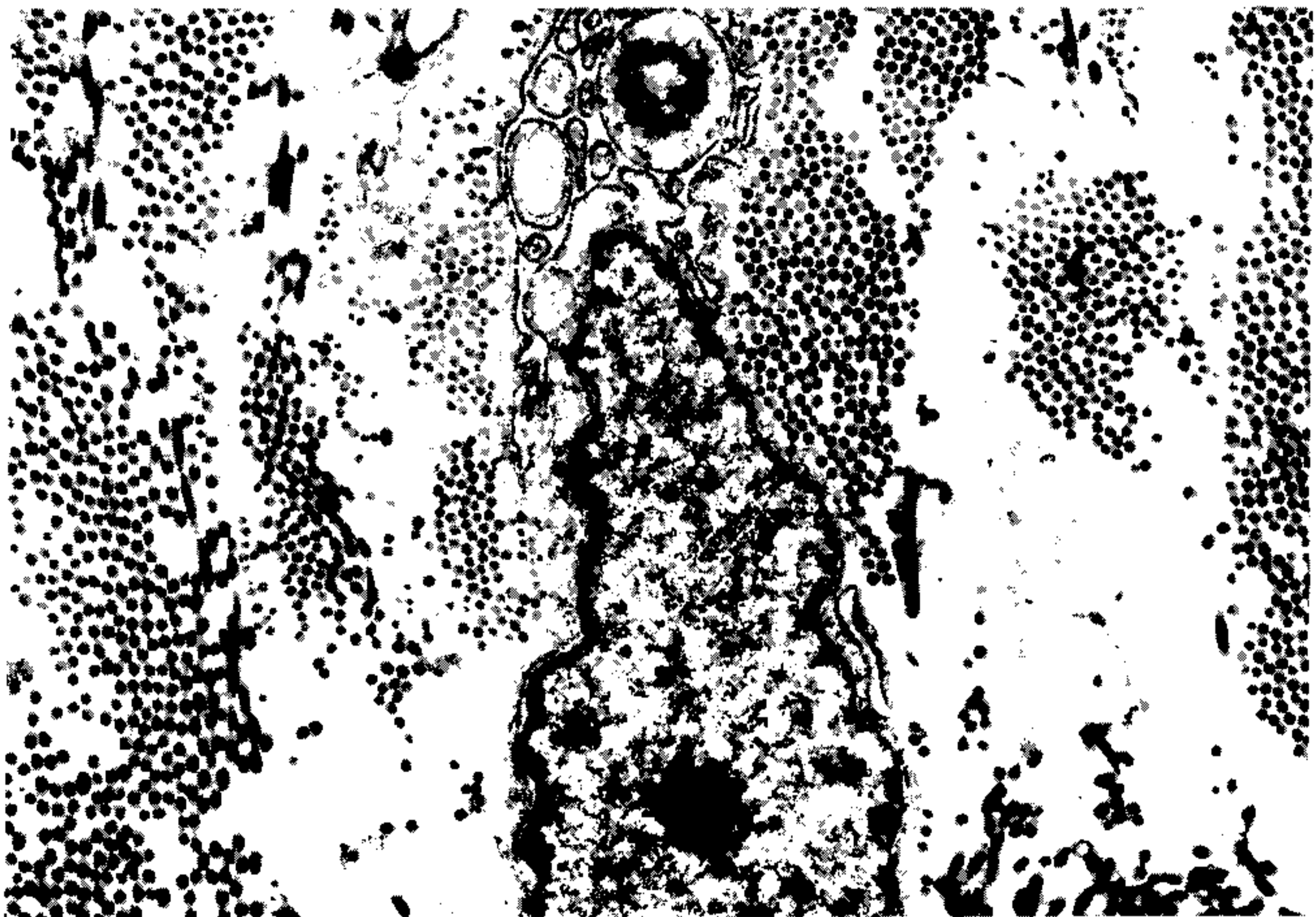

Fig. 2 – Ultrastructural aspect of the fibroma, showing fibroblasts with notched nuclei, ergastoplasmic activity, irregular distribution of chromatin. Collagen disclosed normal periodicity. 5.000 X.

after treatment, of cellular anaplasia with the presence of fibroblasts with atypical nuclei side by side to well differentiated ones, in a dense collagenic stroma (Fig. 3b). Five months afterwards, fibrosarcomatous changes appeared in larger areas, although areas of typical fibroma could still be seen. After a second period of treatment a clear cut acceleration of tumour growth occurred and the tumour disclosed a high degree of anaplasia. This animal was sacrificed and, at autopsy a metastatic tumour was detected in the abdominal cavity, involving mesenteric lymph nodes and adhering to intestinal loops. This tumour was undifferentiated and contained many anaplastic round cells.

The malignant subcutaneous tumour that developed in this animal was transplanted to new experimental groups of animals in successive passages and maintained their characteristics of a well differentiated fibrosarcoma (Figs. 4a, b).

Ultrastructural aspects of the fibrosarcoma showed the following characteristics (Figs. 5, 6): the nucleus was prominent and chromatin distribution appeared to be irregular and condensed in large nuclear areas; fusiform aspect of fibroblasts was sometimes less apparent and collagen containing inclusions were seen in their cytoplasm; hyperactive ergastoplasm was also noted; some elements presented a lipocytic differentiation with triglyceride cytoplasmic inclusions.

b) The other Plastenan treated animals remained with slow growing tumours with the same characteristics observed in untreated animals. Microscopically the fibroma showed focal areas of apparent lysis of the collagenic stroma, with infiltration of polymorphonuclear eosinophils and mononuclear cells. In the areas of collagenic resolution, fibroblast nuclei appeared enlarged and with a loose chromatin.

## COMMENTS

The transplantable fibroma that we succeed in maintaining through serial passages in rats of the same strain (Andrade & Grimaud, 1977), remained during prolonged period with a benign behavior and a stable hard fibromatous structure. However, some early atypical changes were observed by electron microscopy which suggested a transition into a fibrosarcoma. Although usually the fibroma of the rat offers no problem of differential diagnosis (Carter, 1973), transitional aspects has been described sometimes associated with some degree of anaplasia or local invasion (Zackheim, 1973). In the present model, considering the tumour behavior and morphologic criteria at optical microscopy, the diagnosis of fibroma was established from the beginning. However, a nodule of typical fibroma was found in the lung of one of the animals, but it is not clear if this represents a true metastasis or an isolate tumour. It seems apparent that the use of an antifibrosing drug stimulated a malignant transformation in some of these fibromas. The effect of Plastenan on collagen is considered to depend on the mechanism of inhibition of fibrogenesis (Marichy, 1973). Acting as an analogue of the amino acid lysine it induces the formation of a false collagen. Furthermore, studies on the effect of Plastenan in rat cirrhosis (Tabone, 1976) have shown that besides the effect on fibrogenesis, the drug is also fibrolytic. In these studies, no ultrastructural changes in fibroblasts could be detected (Tabone, 1976).

The presence of collagen in the interior of the tumour cells deserves a brief comment. Different types of sarcoma may present collagen fibers in the tumour cells cytoplasm. According to Levine, Reddick & Triche (1978), this fact may indicate either excessive synthesis or autophagic degradation of collagen produced intracellularly. In such cases, rapid synthesis may be far in excess to the rate of transport from the interior toward the exterior of the cells.

Two aspects should be emphasized in this present study: the malignant potential of a typical fibroma and the apparent effect of an antifibrosing drug in stimulating malignization.



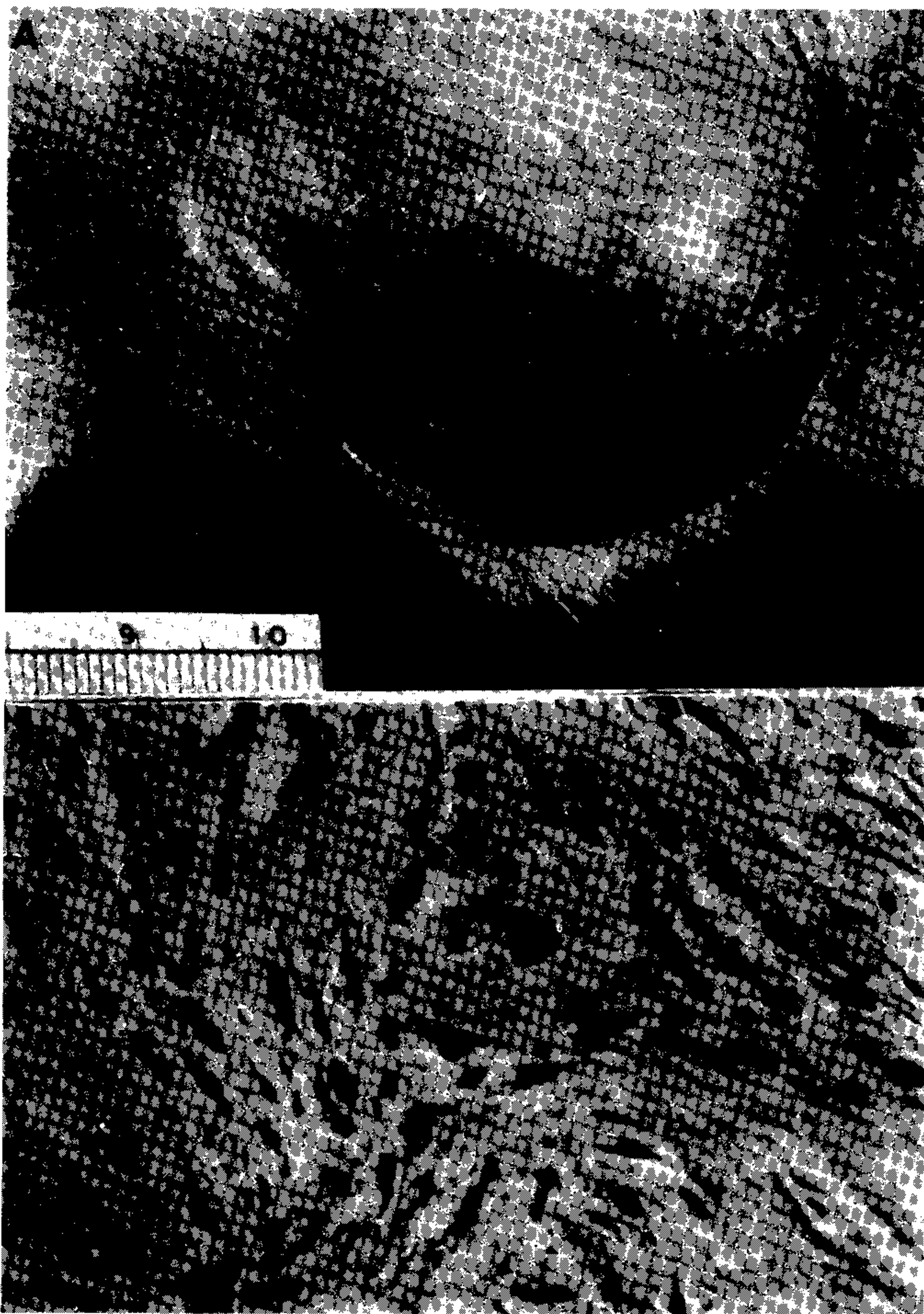


Fig. 3 - a) Aspect of transplanted fibroma in an animal that haven been submitted to two series of treatment, four months after the first series, when submitted to a biopsy; b) Histopathological aspect of biopsied tumour showing slight degree of anaplasia. H and E stain, 200 X.



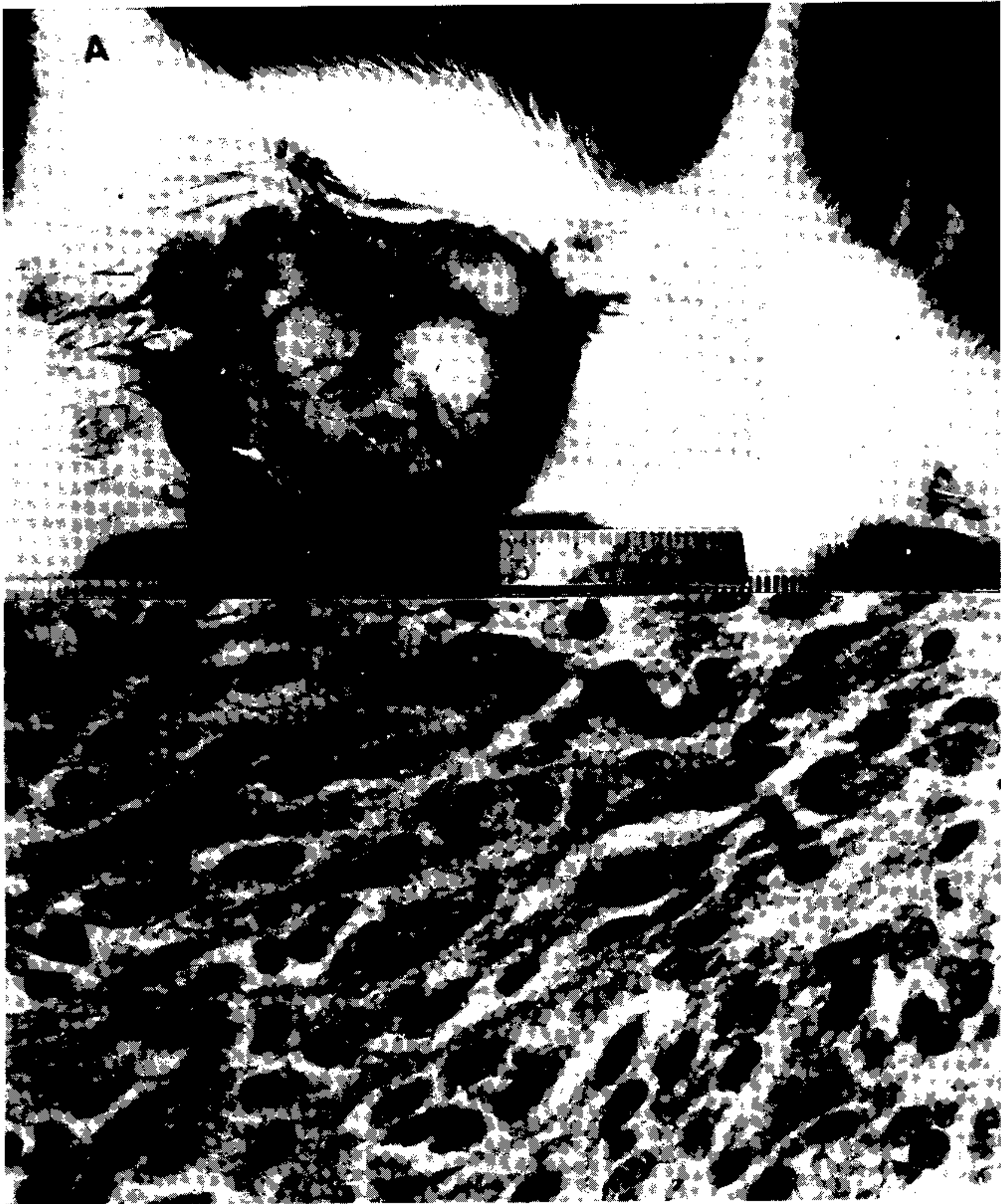

Fig. 4 – a) Transplanted fibrosarcoma in the subcutaneous tissue; b) Microscopical aspect showing atypical fibroblasts and a collagenic stroma. H and E stain, 400 X.



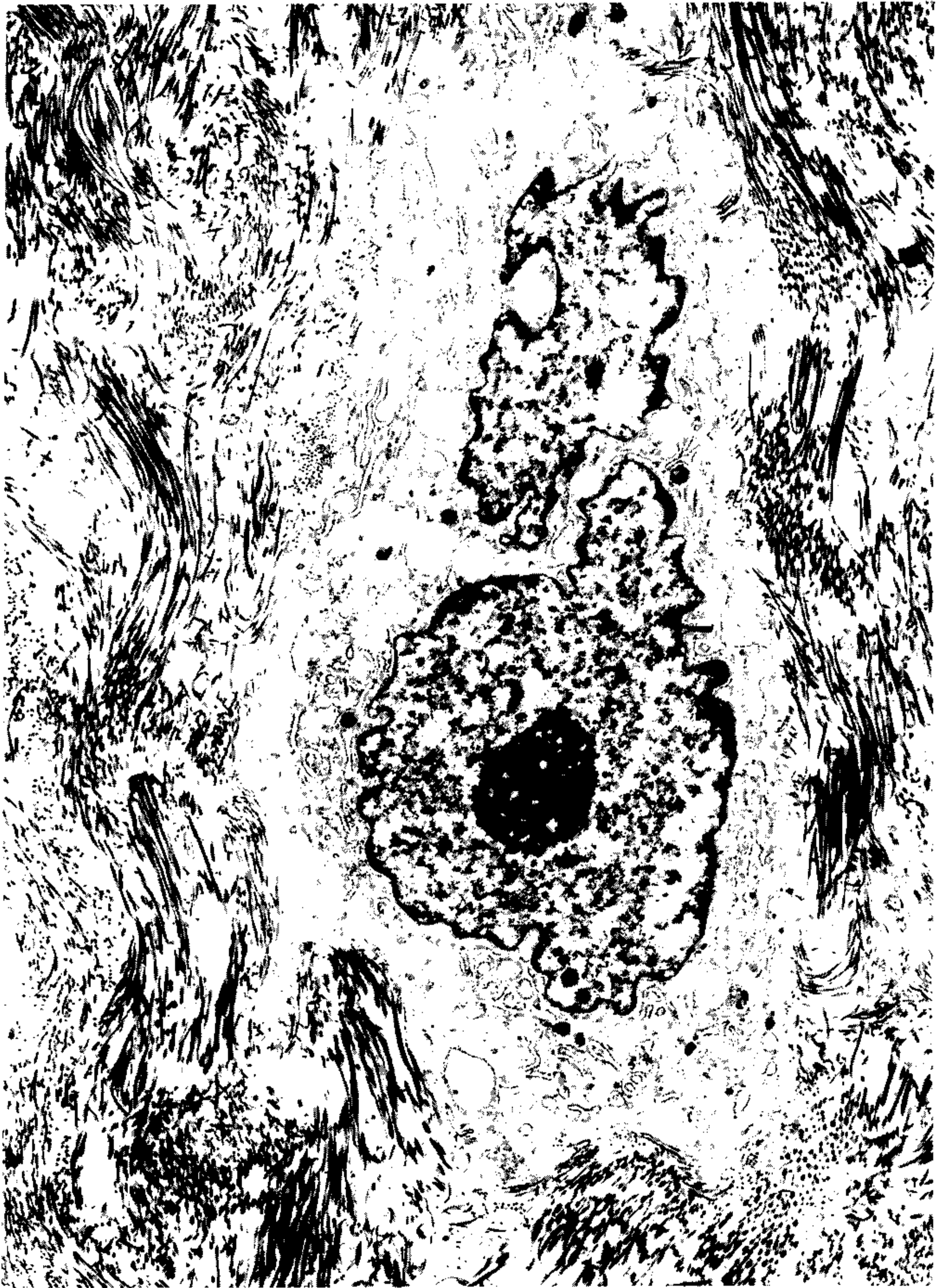


Fig. 5 – Ultrastructural aspect of the transplanted fibrosarcoma: the nucleus is prominent and irregular; the chromatin is condensed in large nuclear areas; hyperactive ergastoplasm, 9.000 X.



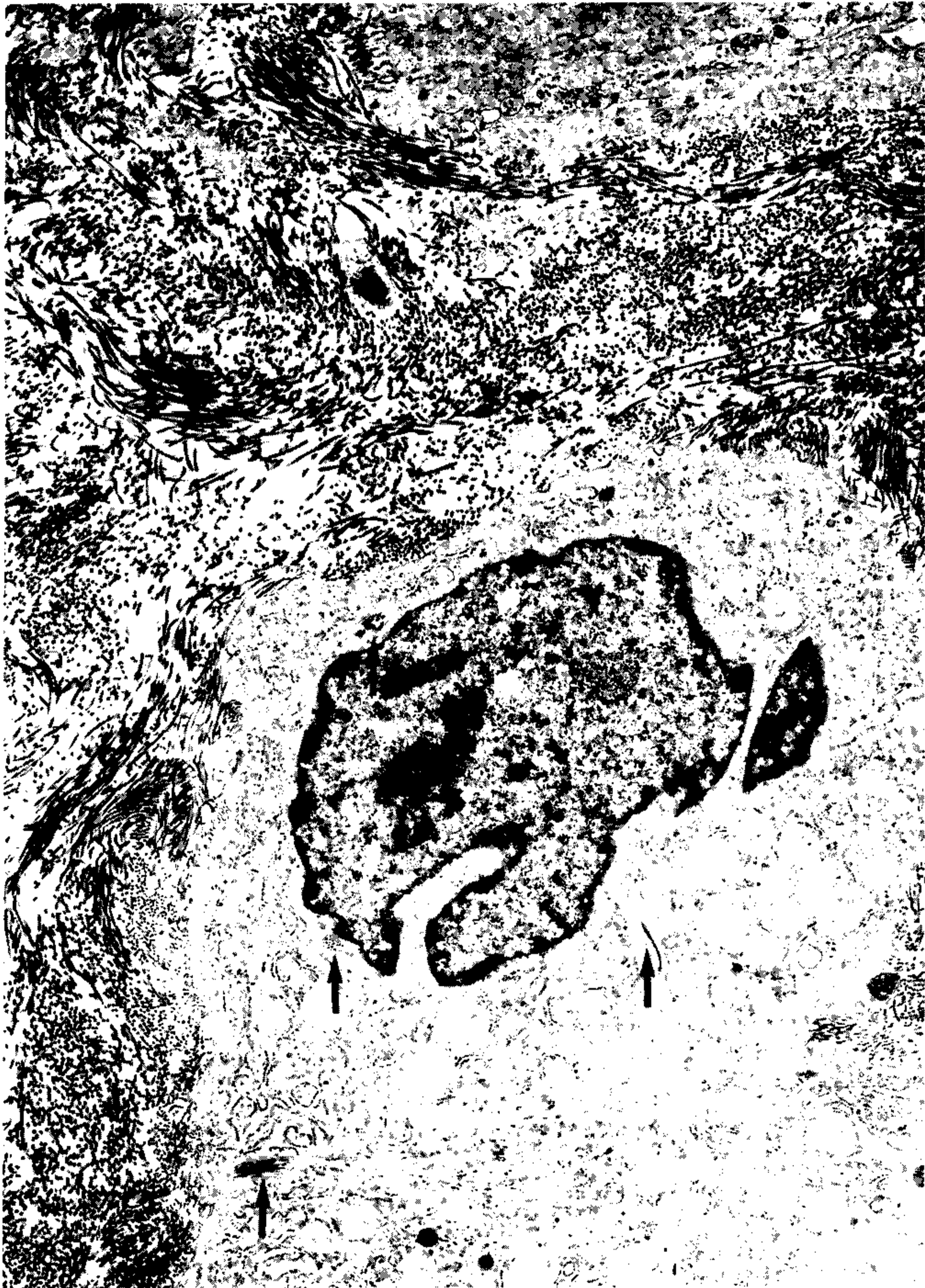

Fig. 6 Irregular fibroblast with collagen containing inclusions in the cytoplasm (arrows), 9.000 X.



The malignant potential of the fibroma showed good correlation with some ultrastructural changes in the fibroblasts at a time when light microscopy could not detect any suspicious alteration. We would like to point out that no untreated animal developed malignization of the tumour after a rather prolonged follow up.

#### RESUMO

Foram utilizados no presente estudo, quinze ratos albinos (*Sprague Dawley*) portadores de fibromas transplantados no tecido subcutâneo da parede abdominal. O tumor era constituído por fibroblastos típicos, em uma densa matriz colagênica e eram provenientes de um fibroma que apareceu espontaneamente em um rato albino da mesma linhagem. Ultraestruturalmente o colágeno mostrava periodicidade normal e os fibroblastos mostravam núcleo irregularmente denteado, com cromatina irregularmente distribuída, sugerindo aspectos transicionais para um fibrossarcoma. Os quinze animais, de diferentes grupos de passagem do tumor, foram divididos em: oito animais submetidos a tratamento com a droga CY-168F (Plastenan) e sete animais controles não tratados. Três dos animais tratados mostraram uma transformação maligna para um fibrossarcoma. Em um dos animais em que foram feitas biópsias sucessivas, foram observados aspectos histológicos transicionais de um fibroma típico até um fibrossarcoma altamente indiferenciado. O estudo ultraestrutural demonstrou alterações nucleares, ergastoplasma hiperativo e inclusões contendo colágeno, no citoplasma dos fibroblastos. No grupo dos sete animais não tratados, não foi verificada transformação maligna do tumor. Dois aspectos merecem atenção neste estudo: o potencial maligno de um fibroma típico e o aparente efeito de um antifibrosante na indução da malignização deste tumor.

#### ACKNOWLEDGMENT

Thanks are due to Miss Tereza Almeida for her technical help.

#### REFERENCES

- ANDRADE, S.G. & GRIMAUD, J.A., 1977. Registro sobre um fibroma de rato facilmente transplantável. *Patologia*, 15 :205-215.
- CARTER, R.L., 1973. Tumours of the soft tissue. In: Pathology of tumours in laboratory animals. WHO International Agency for Research on Cancer, Lyon - França.
- FLANDRE, O.; DAMON, M.; CIURANA, L. & SECCHI, M.J., 1965. Action de l'acide acétyl-epsilon-amino-hexanoïque sur le tissu conjonctif inflammatoire. *Presse Med.* 73 :29-59.
- FORT, V. & GINESTE, J., 1965. Action de l'acide acétyl-6-amino-hexanoïque sur la tolerance des homogreffes chez l'animal. Études des greffes alternées (greffe de Mowlen et Jackson). *Ann. Anesth. Franç.* 6 :707-713.
- GMAZ-NIKULIN, E. & STERNE, P., 1966. The effect of acetyl-6-amino-caproic acid on the cirrhosis of liver in rat. *Atti. Accad. Med. Lombardia* 21 :6-8.
- LAGROT, F.; PESSEREAU, G. & ANTOINE, G., 1967. Action de l'acide N-acétyl-amino-6-hexanoïque sur la cicatrization. (Resultats experimentaux et faits cliniques). *Lyon Chirurg.* 63 :414-418.
- LEVINE, A.M.; REDDICK, R. & TRICHE, T., 1978. Intracellular collagen fibrils in human sarcomas. *Lab. Invest.* 39 :531-540.
- MARICHY, J., 1973. *Cirrhoses experimentales au tetrachlorure de carbone. Essai d'un antifibrosant, le CY-168F.* Thèse. Lyon, França.
- TABONE, E., 1976. *Étude dynamique et ultrastructurale de l'action d'un antifibrosant (CY-168F) sur des cirrhoses experimentales au CC14, chez le rat.* Thèse. Lyon, França.
- ZACKHEIM, H.S., 1973. Tumours of the skin. In: Pathology of tumours in Laboratory animals. WHO International Agency for Research on Cancer. Lyon, França.