

SCHISTOSOMAL GLOMERULAR DISEASE (A REVIEW)

ZILTON A. ANDRADE* & ERIC VAN MARCK**

In this review paper schistosomal glomerulopathy is defined as an immune-complex disease. The disease appears in 12-15 per cent of the individuals with hepatosplenic schistosomiasis. Portal hypertension with collateral circulation helps the by pass of the hepatic clearance process and the parasite antigens can bind to antibodies in the circulation and be trapped in the renal glomerulus. Chronic membranous-proliferative glomerulonephritis is the most common lesion present and the nephrotic syndrome is the usual form of clinical presentation. The disease can be experimentally produced, and schistosomal antigens and antibodies, as well as complement, can be demonstrated in the glomerular lesions. Specific treatment of schistosomiasis does not seem to alter the clinical course of schistosomal nephropathy.

Glomerular changes associated with schistosomiasis appear to be a good example of an immune-complex disease produced by a parasitic infection. Diffuse glomerulonephritis with several histological patterns has been detected both in patients with hepatosplenic disease due to *Schistosoma mansoni* as well as in experimental animals heavily infected either with *Schistosoma mansoni* or *Schistosoma japonicum*. In such lesions, schistosomal antigen(s) and several classes of immunoglobulins and complement have been identified.

PREVALENCE

Chronic schistosomiasis is generally seen under two clinical forms: 1) a *mild form* in which the patient has a low worm load and is either asymptomatic or presents with vague complaints of transient diarrhea and constipation, abdominal pain and bloody stools (hepato-intestinal form); 2) a *severe or advanced form* in which there are signs of portal hypertension, such as splenomegaly and esophageal varices due to periportal (pipe-stem) hepatic fibrosis with marked intrahepatic portal vein obstruction (hepatosplenic schistosomiasis). In Brazilian endemic areas mild schistosomiasis occurs in 95 to 98% of the infected subjects, while the remaining 2 to 5% of all infected patients will disclose hepatosplenic disease (Barbosa, 1970; Silva, 1949). Thus far no relationship between mild schistosomiasis and schistosomal nephropathy has been demonstrated. In addition hepato-intestinal cases have been included as controls in some studies (Andrade & Queiroz, 1968; Andrade, Andrade & Sadigursky, 1971), on renal involvement in hepatosplenic schistosomiasis. The reason for schistosomal glomerulopathy being restricted to the severest forms of schistosomiasis will become apparent later on. In selected cases of hepatosplenic schistosomiasis seen in a general hospital or examined at necropsy, overt renal involvement occurred in 12 to 15% of the cases, (Andrade, Andrade & Sadigursky, 1971; Rocha et al., 1976), whereas the overall incidence of glomerulonephritis was 5.6%. However, the real prevalence of schistosomal renal involvement in endemic areas is not known. The only attempt to correlate renal disease and schistosomal infection in the field was made by Lehman et al. (1975). Higher concentrations of urinary protein were found in subjects with *S. mansoni* infection as compared to those who were uninfected. However, since they looked for splenomegaly rather than signs of portal hypertension it is not evident how proteinuria would correlate with hepatosplenic schistosomiasis. Recently, Bina et al. (1984) detected proteinuria in 24.7% of 89 individuals with hepatosplenic schistosomiasis and in only 4.6% of 86 subjects with mild hepato-intestinal schistosomiasis all of them living in comparable conditions in two endemic areas in Bahia, Brazil.

CLINICAL PRESENTATION

The development of nephrotic syndrome in patients known to have hepatosplenic schistosomiasis due to *S. mansoni* was frequently seen and so did not surprise clinicians working in endemic areas in Brazil. They considered this a complication due to concomitant bacterial (streptococcal) infection not uncommonly seen in those patients. Now, we are aware that the nephrotic syndrome is the most frequent form of clinical presentation of schistosomal nephropathy. The patients are usually young adults and both sexes can be equally represented. There is some evidence that renal manifestations develop slowly, perhaps ten or more years after the onset of hepatosplenic disease (Andrade & Rocha, 1979). Fifteen patients with hepatosplenic disease who had splenectomies as a form of treatment to alleviate the manifestations of portal hypertension

This work was supported by the National Research Council (CNPq), Brazil. Process no. PIDE V 2030/82.

*Centro de Pesquisas Gonçalo Moniz – FIOCRUZ, Rua Valdemar Falcão 121, 40000 Salvador, BA, Brazil.

**Prince Leopold Institut of Tropical Medicine, Antwerp, Belgium.

Received for publication March 20th and accepted July 9th, 1984.

and hypersplenism underwent renal biopsy at the time of surgery. Although they did not have clinical manifestation of renal disease, six had histological glomerular changes. These changes consisted of mesangial expansion with increased cellularity, but one patient presented a classic membrano-proliferative glomerulonephritis, while another disclosed focal glomerular sclerosis (Brito, 1973). Brito et al. (1970) refer to one patient who had a predominant membranous glomerulonephritis that seven years later progressed to a definite lobular pattern. Some have pointed out the low selectivity (Queiroz et al., 1973) or non-selectivity (Hillyer et al., 1975) of the proteinuria in schistosomiasis. Thus, IgM, alfa 2 macroglobulin and lipoprotein can be detected in the urine in rather large amounts, as well as IgG and IgA. The specific anti-schistosome nature of at least part of these urinary immunoglobulins has been demonstrated (Hillyer et al., 1975). Characteristically, the nephrotic syndrome seen in association with schistosomiasis presents with an increased plasma globulin concentration and normal cholesterol levels in a third of the patients.

Other forms of clinical presentation may also be observed. For instance, in a study of 100 consecutive cases of hepatosplenic schistosomiasis seen in a general hospital in Bahia, Brazil, nine patients had nephrotic syndrome, six had only proteinuria, and three patients had hypertension (Brito, 1973).

Clinical response to current drug treatment is the same as for nephrotic syndrome in general. Although several patients have been followed up for more than four years in our hospital in Bahia, Brazil (Andrade & Rocha, 1979) there are as yet no definite data concerning the influence of specific treatment of schistosomiasis on the clinical course of the renal disease.

HISTOLOGICAL FINDINGS

Since earlier studies (Andrade & Queiroz, 1968; Andrade & Sadigursky, 1978) it has become evident that the mesangial area of the glomerulus is the main site of lesions of schistosomal nephropathy. In the least advanced cases there is mesangial expansion due to the presence of amorphous and fibrillar PAS positive material, as well as mesangial cell hypertrophy and hyperplasia. Electron microscopy disclosed electron-dense deposits and laminar bodies in mesangial areas (Brito et al., 1970). It is also in such areas that the main deposition of IgG, IgM, IgA, IgE and C₃ occurs, as demonstrated by immunofluorescence (Silva et al., 1970). Changes in the basement membrane are less marked and consists of sub-epithelial, sub-endothelial, and intramembranous deposits, which can be especially demonstrated at the ultrastructural level (Andrade & Rocha, 1979; Brito et al., 1969/1970). However, in one case of a particularly severe *S. mansoni* infection, a membranous type of glomerulopathy with the classical sub-epithelial "spikes" was found associated with mild to moderate mesangial cell proliferation (Andrade, Andrade & Susin, 1974). When more advanced lesions are considered, the most common findings are those of a classic membranous proliferative glomerulonephritis with lobular accentuation (Fig. 1). The latter picture is suggestive of progression from the earliest lesions of mild mesangial changes. This indicates the mesangium as the critical target area in schistosomiasis, and shows good correlation with the nephrotic syndrome seen clinically.

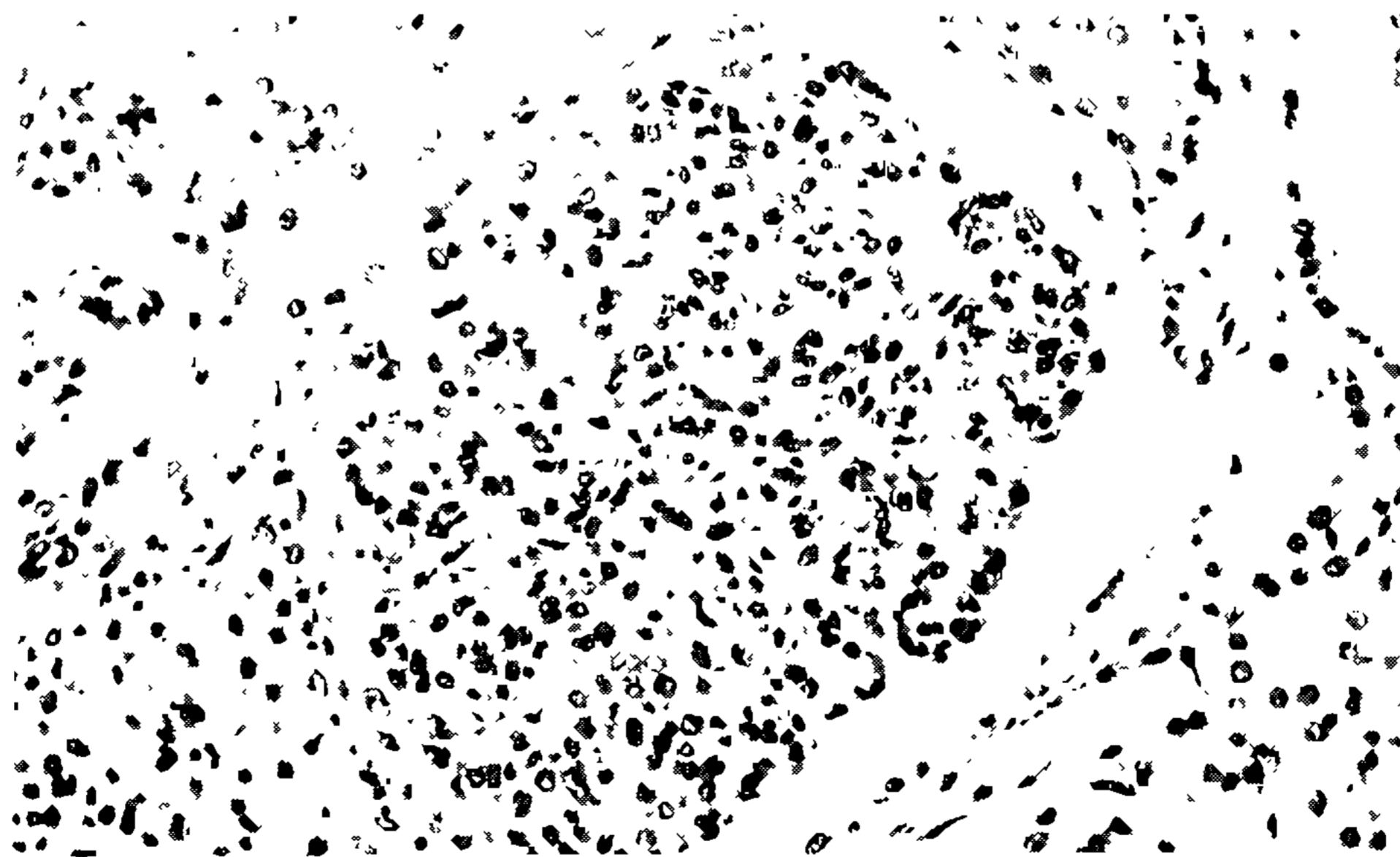


Fig. 1: membranous proliferative type of chronic glomerulonephritis seen in a 25 year old man with hepatosplenic schistosomiasis due to *Schistosoma mansoni*. H & E 400X.

The second most common type of glomerular lesion observed in biopsy material consists of focal sclerosis. When a large number of autopsy cases were examined advanced glomerular disease appeared in 12% (Andrade, Andrade & Sadigursky, 1971). The type of glomerular changes may then be varied. While membranous proliferative glomerulonephritis occurs in 50% of the total, the remaining are represented by focal glomerular sclerosis, membranous glomerulopathy, rapidly progressive glomerulonephritis and acute diffuse proliferative glomerulonephritis. Of course, since no schistosomal antigens were demonstrated in such cases, we cannot be sure that all of them were provoked by schistosomiasis.

Although renal amyloidosis has been found in some children with schistosomiasis in Africa (Omer & Wahab, 1976) and has been detected in rabbits experimentally infected with *S. japonicum* (Robinson,

Lewert & Spargo, 1982), a search of Egyptian and Brazilian necropsy cases failed to demonstrate any relationship between hepatosplenic schistosomiasis and amyloidosis (Sadigursky & Andrade, 1978).

EXPERIMENTAL MODELS

This subject has recently been reviewed by Houba (1979). Infection of experimental animals with *S. mansoni* or *S. japonicum* can result in the production of glomerular lesions that, to a certain extent, mimic the kidney alterations observed in humans with hepatosplenic schistosomiasis. The heterogeneity of these experimentally induced schistosomal glomerulopathies is great and can be explained in part by the use of different animal species. Yet, one common denominator of all these experiments is the detection of granular deposits of immunoglobulin, complement and, sometimes, schistosomal antigen in glomeruli, indicating that the glomerulopathy is most probably mediated by immune complexes. Moreover, some workers found a strong correlation between the occurrence of circulating immune complexes containing schistosomal antigen and glomerular deposits in *S. mansoni* infected mice (Digeon et al., 1979).

It seems that the best results can be obtained in the chimpanzee heavily infected with *S. japonicum* (Von Lichtenberg et al., 1971). However, clear cut glomerulonephritis appears in other species of monkeys infected either with *S. mansoni* (Brito et al., 1971; Houba, Sturrock & Butterworth, 1977) or *S. japonicum* (Tada et al., 1975). The important prerequisite for the reproduction of glomerular lesion in monkeys, as well as other animals, is prolonged and heavy infection (Houba, 1979).

In the mouse it is difficult to detect any inflammatory glomerular lesion by light microscopy. However, electron microscopy and immunofluorescence show, respectively the presence of electron-dense deposits (Figs. 2 and 3) and of antigens (Fig. 4) and immunoglobulin deposits (Fig. 5), confirming previous reports (Andrade & Susin, 1974; Natali & Cioli, 1976).

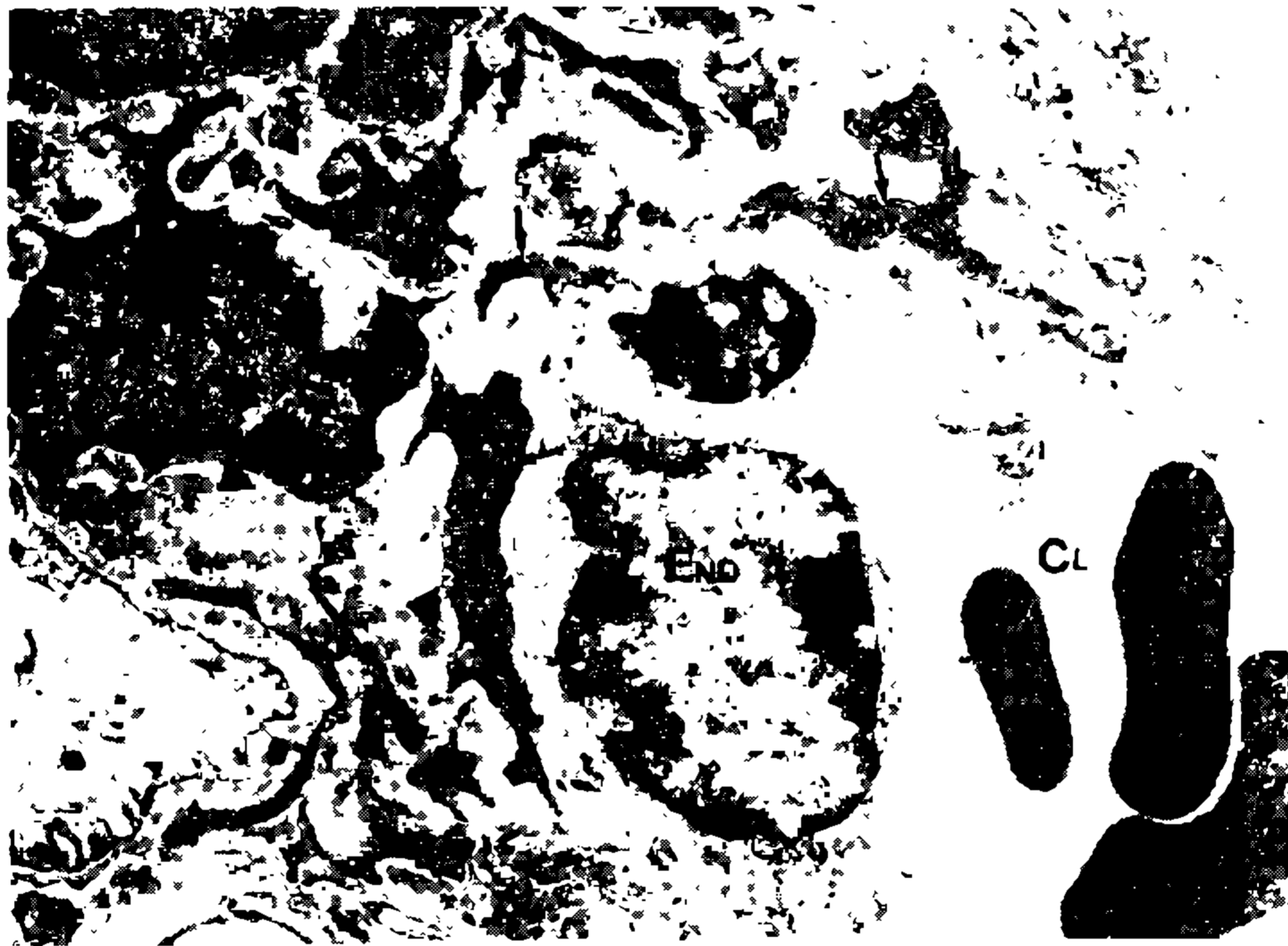

Fig. 2: mesangial area of a glomerulus from a mouse with partial ligation of the portal vein and *S. mansoni* infection (30 cercariae; six months), showing increase of mesangial matrix which contains large electron-dense deposits (arrow-heads). Mesangial cell (M) exhibits many cytoplasmic ramifications (arrows). End: endothelial cell. Cl: capillary lumen. Uranyl acetate and lead citrate. Electron microscopy. 14,000X.

The hamster has the disadvantage of developing amyloidosis too frequently. Studies using the rabbit model and infection with *S. japonicum* have yielded a good reproduction of the schistosomal nephropathy (Von Lichtenberg, Sadun & Bruce, 1972; Robinson, Lewert & Spargo, 1982).

PATHOGENESIS

The presence of schistosomal antigen(s) together with immunoglobulins and complement in the glomerular lesions associated with schistosomiasis has been considered as good evidence of an immune-complex mechanism for schistosomal glomerulopathy. One schistosome antigen has emerged as a good candidate for inducing renal immunopathology. It is a high molecular weight polysaccharide material found in the intestinal lining of the adult worm and has been variously designated as "polysaccharide antigen", "gut antigen", "Nash antigen", and "circulating schistosomal antigen" (CSA). CSA was first detected in the sera and urine of hamsters and mice which were heavily infected with *S. mansoni* (Berggren & Weller, 1967). Nash (1974) characterized it as a polysaccharide of 100,000 Daltons and demonstrated its presence in the intestinal lining of the adult worm. It seems to be the first antigen to be detected in the host, and appears a few days after cercarial exposition (Andrade & Sadigursky, 1978), since it is present in the primordial esophagus of cercariae and in the developing cecum of schistosomulum as well as in the adult worm gut.

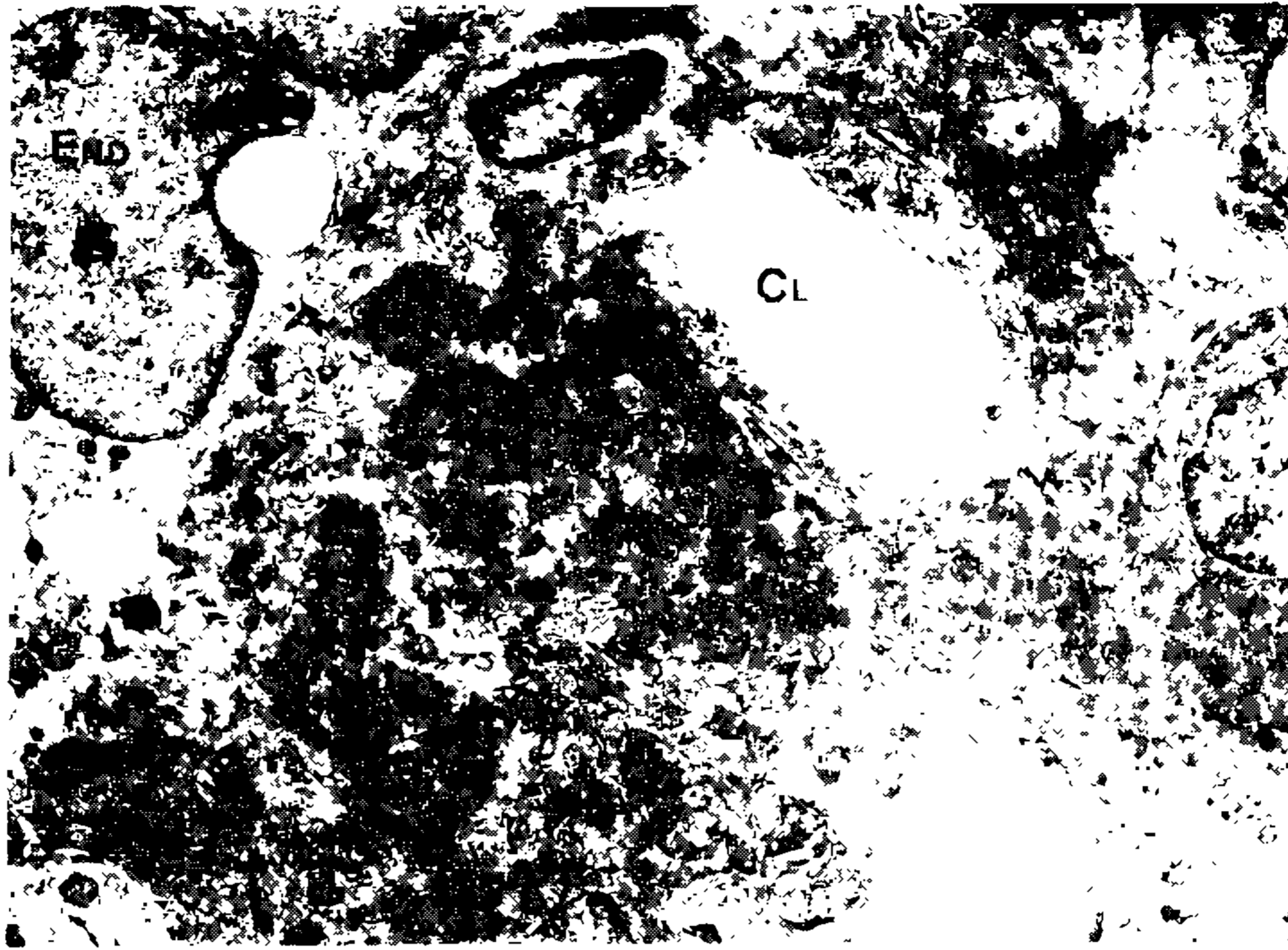

Fig. 3: mesangial electron-dense deposits in glomerulus from a mouse with total ligation of the portal vein and unisexual *S. mansoni* infection (300 cercariae; 60 days). End: endothelial cell. Cl: capillary lumen. Uranyl acetate and lead citrate. Electron microscopy. 14.000X.

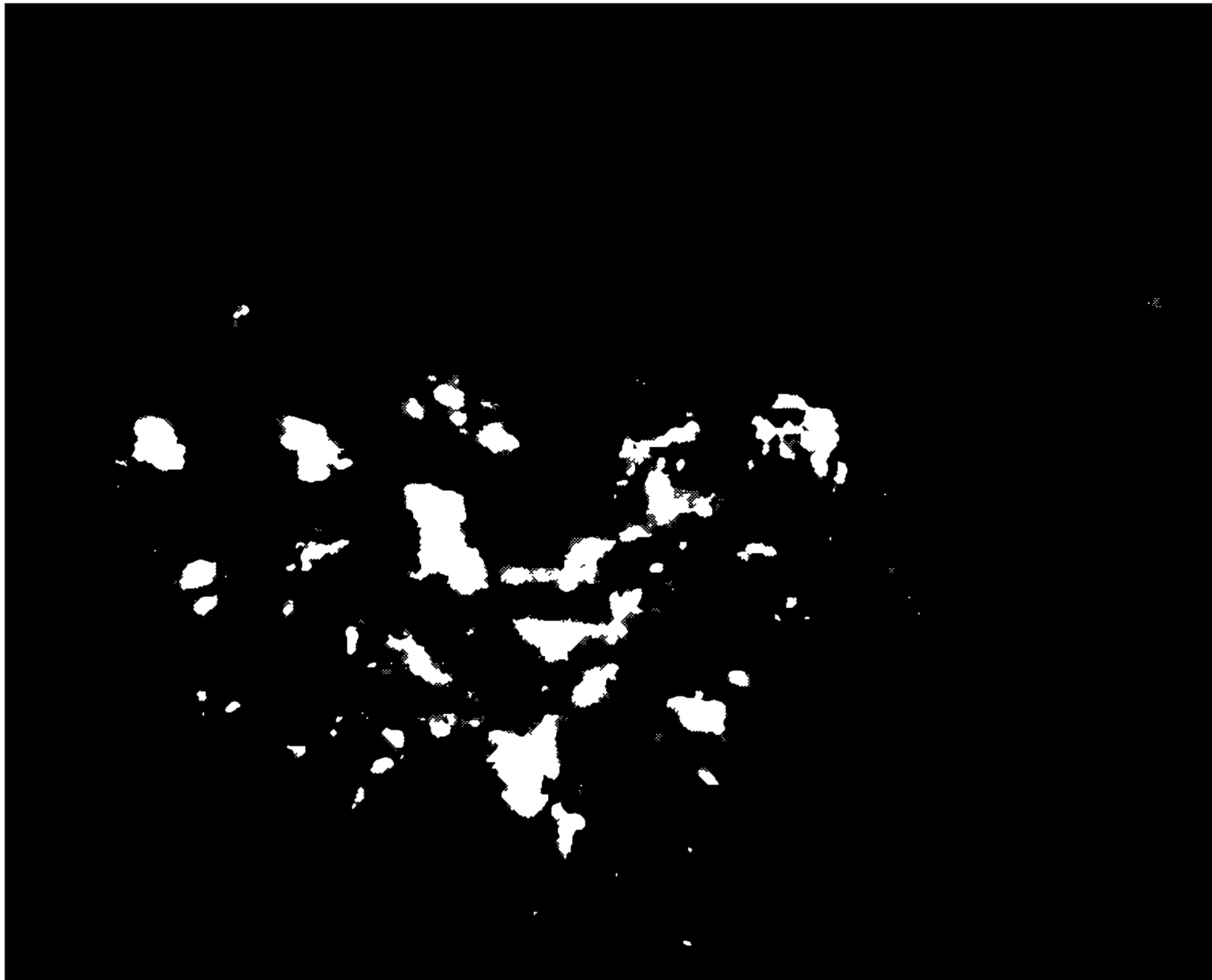


Fig. 4: granular deposits of CSA in glomerulus from a mouse with unisexual *S. mansoni* infection (300 cercariae). Direct immunofluorescence. 830X.

The antigen has been demonstrated in the "vomitus" of the adult worm (Von Lichtenberg, Bawden & Shealey, 1974), and in Kupffer cells of mice (Van Marck, 1975). Thus, it seems that adult worms are constantly synthesizing and eliminating this antigen, but during mild infection almost all of it is cleared by the hepatic macrophage system and does not reach the systemic circulation or the urine. However, in the presence of heavy infection the excess antigen can "spill over" or by-pass the liver by way of the collateral circulation and thus appear in the serum and urine. This would explain why renal involvement in schistosomiasis is restricted to the hepatosplenic form of the disease only. A time sequence analysis of the appearance of CSA in glomeruli and in Kupffer cells demonstrated that CSA could be detected in Kupffer cells at seven weeks post-infection (300 cercariae of one sex) while in glomeruli it was barely detectable by that time. At 12 and 25 weeks Kupffer cells remained strongly positive while substantial quantities of CSA were being detected in the mesangium of glomeruli (Van Marck, Deelder & Gigase, 1977).

In animals with single-sex infections (300 cercariae) and previously subjected to partial or total ligation of the portal vein (Van Marck, 1983), an enhancing effect of the glomerulopathy was observed at 60 days post-infection. The same is true for bisexual infection. Immune deposits in glomeruli of diseased kidneys mainly consisted of IgM and IgA, with lesser amounts of IgG. Location of the deposits was restricted to the mesangium (Fig. 2). Complement (C_3) was consistently detected in cases presenting immunoglobulin




Fig. 5: mesangial deposits of IgM in a glomerulus from a mouse infected with 300 *S. mansoni* cercariae of one sex for 60 days and total ligation of the portal vein. Direct immunofluorescence. 830X.

deposits. In operated animals (partial or total ligation of the portal vein), greater amounts of CSA were found than in unoperated infected mice. Light and electron microscopy disclosed the same mild mesangial glomerulopathy as seen in bisexual infection: increase of the mesangial matrix, presence of mesangial electron-dense deposits, focal proliferation of mesangial cells (Fig. 6), and only occasional thickening of the basement membrane of the glomerular capillary wall (Fig. 7). Specific antibodies prepared in rabbits against the purified CSA have been used to demonstrate its presence in glomerular lesions in man (Hoshino-Shimizu et al., 1976) and in experimental animals (Tada et al., 1975; Natali & Cioli, 1976; Van Marck, 1983). The acidic elution of globulins from human (Hoshino-Shimizu et al., 1976; Moriearty & Brito, 1977) and murine (Houba, Sturrock & Butterworth, 1977) kidneys has permitted the demonstration of their specific binding to the gut region of adult worm. Houba (1979) claims that sometimes the antigen can be extracted from the kidneys of infected animals when immunoglobulins are apparently not yet present. He advanced the idea that the antigen can be trapped alone in the glomerulus and that the antibody binding can occur there later on.

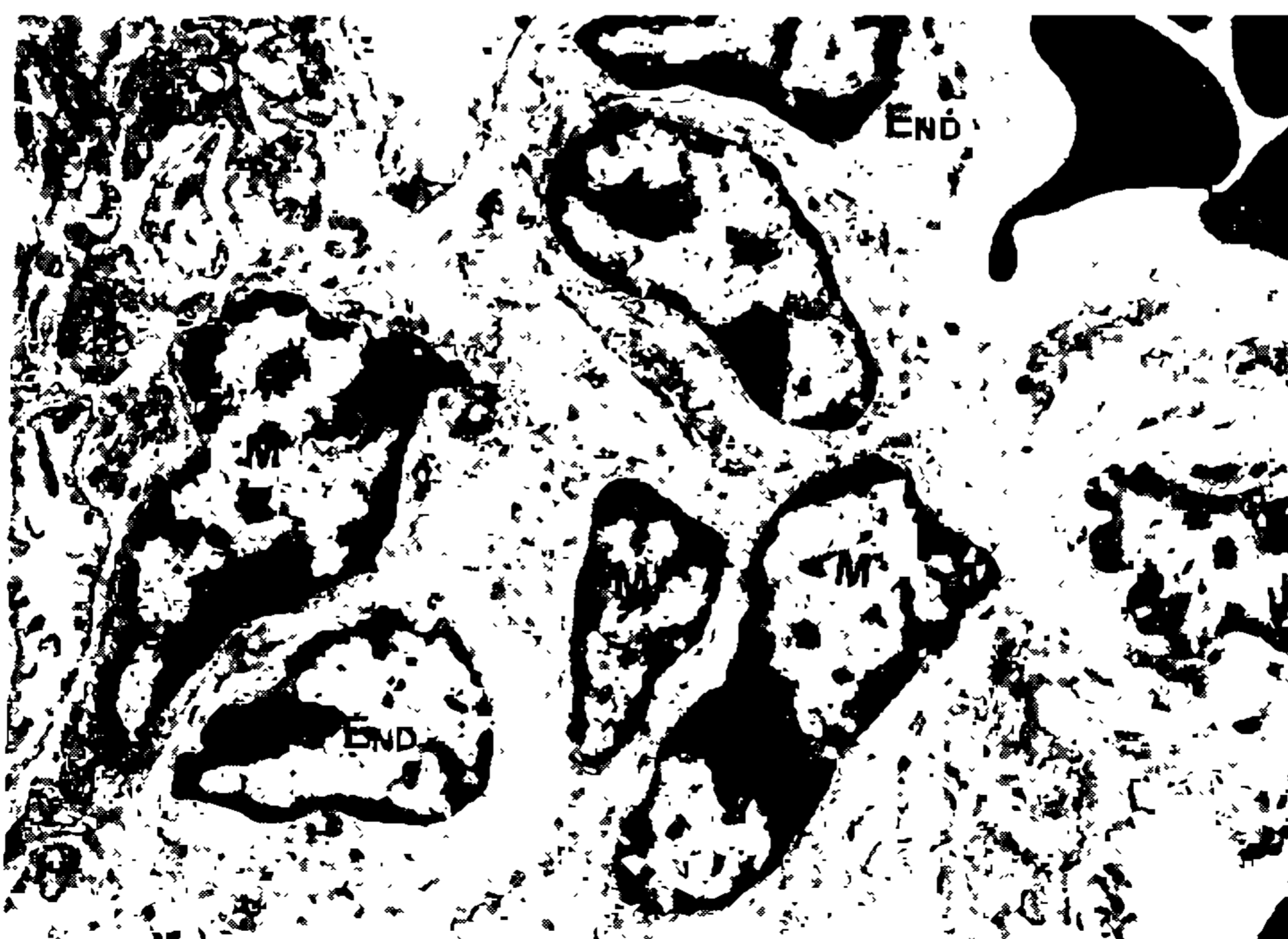


Fig. 6: area of mesangial cell proliferation in glomerulus from a mouse with total ligation of the portal vein and unisexual infection (300 cercariae: 60 days). M: mesangial cells. End: endothelial cells. Uranyl acetate and lead citrate. Electron microscopy. 14,000X.

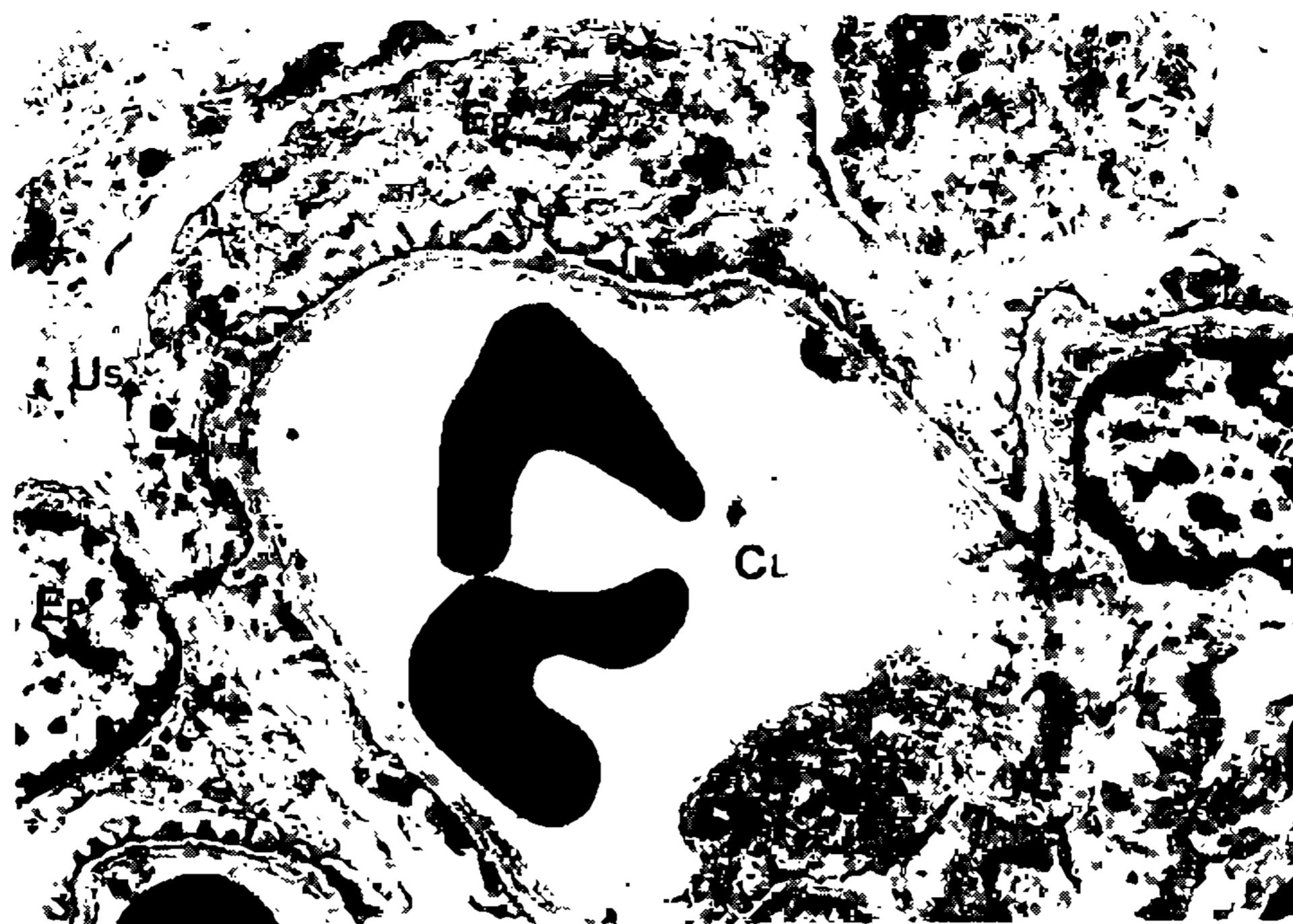


Fig. 7: slight basement membrane thickenings (arrows) in glomerulus from a mouse with total ligation of the portal vein and unisexual infection (300 cercariae; 60 days). Foot-processes of epithelial cell (Ep) are fused over the basement membrane thickenings. Cl: capillary lumen. End: endothelial cell. Us: urinary space. Uranyl acetate and lead citrate. Electron microscopy. 14,000 X.

In mice with schistosomiasis, Digeon et al. (1979) found good correlation between the serum levels of immune complexes and the mesangial deposits of IgA, IgM and C₃. However they did not detect anti-schistosome antibody activity for IgA in the serum. In one study no IgA activity was found in the sera of hepatosplenic patients against egg, cercaria schistosomula or adult *S. mansoni*. The majority of anti-CSA antibodies belonged to the IgM fraction (Andrade & Sadigursky, 1978). Thus, there is good evidence to implicate the intestinal polysaccharide antigen of adult worm and mainly IgM specific antibodies in the genesis of schistosomal glomerulopathy. However it does not mean that other antigens can be excluded.

Another polysaccharide antigen which probably has its origin in the gut of adult worms has been identified by Deelder et al. (1976). It is a cathodic, heat stable low molecular weight substance (30,000 Daltons) and has been demonstrated in the serum and urine of infected hamsters, in adult worm antigen and in secretory and excretory products of adult worms. Thus far attempts to produce an immunogenically active antigen have been unsuccessful. This has hampered further progress with this new antigen. It is probably related to the M antigen detected in the urine of infected patients by Carlier et al. (1975) but its role in the pathogenesis of glomerular lesions is at present difficult to access.

In extracts from the kidneys of baboons infected with *S. mansoni*, Houba (1979) has found soluble egg antigen (SEA) by countercurrent immuno-electrophoresis, and has suggested the participation of this antigen in glomerular lesions. We have not been able to confirm this by using a potent anti-SEA serum and immunofluorescence technique. Since *S. mansoni* eggs can reach the renal tissue, presence of SEA in renal extracts may not be a good indication of its presence in glomerular lesions.

It should be stressed that schistosomes have several metabolic and somatic antigens and that we know very little about most of them. For instance, from the surface of adult worms antigenic material is being constantly shed.

Antibodies against schistosomal metabolic antigens, prepared by Hoshimo-Schimizu et al. (1976) probably reacted with worm tegument material also. The eluted globulins from human kidneys obtained by Moriearty & Brito (1977) were found to bind to adult worm tegument as well as to the intestinal lining.

By using autoradiography and liquid scintillation counting techniques, Hillyer & Lewert (1974) and Hillyer (1973) detected increased amount of deoxyribonucleic acid in the kidneys of infected hamsters. They suggested that DNA and DNA antibodies may play a role in the pathogenesis of renal lesions in schistosomiasis. Thus, schistosomal glomerulopathy resembles that of systemic lupus erythematosus where pathogenesis is mediated by antibodies to DNA.

Diversion of the portal blood from contact with the hepatic filter allows agents, generated in the mesenteric vessel bed, to act as nephritogenic factors. Among these factors, preformed immune complexes (either specific or non-specific, e.g. from intestinal bacteria) or endotoxin should be mentioned. It has indeed been shown that immune complexes and endotoxin, both potential nephritogenic substances (Theofilopoulos & Dixon, 1980) are predominantly cleared or detoxified in the liver (Bjørneboe & Prytz, 1976).

Thus, renal involvement in hepatosplenic schistosomiasis results from an interplay of a series of mechanisms. The most important ones are of course the parasite antigen(s) and host antibodies, but the role of porto-systemic collateral circulation which allows schistosomal antigens, and probably other non-

specific antigens or endotoxin, to reach the general circulation and the kidneys, after or before being tagged to serum factors, is a critical one. As to specific immune complexes, these probably have CSA as their antigenic moiety.

Further characterization of the immune complexes, with regard to their valence, size and nephrotoxicity, needs to be carried out. The demonstration that proteinuria is a prevalent finding in hepatosplenic individuals living in endemic areas of schistosomiasis (Bina et al., 1984) points out the public health importance of schistosomal nephropathy.

RESUMO

A glomerulopatia esquistossomótica é um exemplo de doença causada por complexos imunes. Ela se manifesta em 12 a 15% dos portadores da forma hepato-esplênica da esquistossomose. A hipertensão porta, com circulação colateral, facilita a ultrapassagem do filtro hepático e os antígenos esquistossomóticos podem se acoplar aos anticorpos na circulação e vir a se depositar nos glomérulos. O tipo histológico mais freqüente é a glomerulonefrite crônica membrano-proliferativa, geralmente com síndrome nefrótica. A doença é passível de reprodução experimental e os antígenos esquistossomóticos, os anticorpos e frações do complemento podem ser demonstrados nas lesões glomerulares. O tratamento específico da esquistossomose não mostrou até o momento a capacidade de alterar o curso da nefropatia.

Estes são os principais aspectos apresentados e discutidos no presente trabalho de revisão.

REFERENCES

- ANDRADE, Z.A.; ANDRADE, S.G. & SADIGURSKY, M., 1971. Renal changes in patients with hepatosplenic schistosomiasis. *Amer. J. Trop. Med. & Hyg.*, 20 :77-83.
- ANDRADE, Z.A.; ANDRADE, S.G. & SUSIN, M., 1974. Pathological changes due to massive schistosomal infection in man (a case presentation). *Rev. Inst. Med. trop. São Paulo*, 16 :171-177.
- ANDRADE, Z.A. & QUEIROZ, A., 1968. Lesões renais na esquistossomose hepato-esplênica. *Rev. Inst. Med. trop. São Paulo*, 10 :36-40.
- ANDRADE, Z.A. & ROCHA, H., 1979. Schistosomal glomerulopathy. *Kidney Internat.*, 16 :23-29.
- ANDRADE, Z.A. & SADIGURSKY, M., 1978. Immunofluorescence study of schistosome structures which share determinants with circulating schistosome antigens. *Trans. R. Soc. Trop. Med. Hyg.*, 72 :316-318.
- ANDRADE, Z.A. & SUSIN, M., 1974. Renal changes in mice infected with *Schistosoma mansoni*. *Am. J. Trop. Med. Hyg.*, 23 :400-403.
- BARBOSA, F.S., 1970. Epidemiologia Chapter 3, in *Esquistossomose mansoni* edited by Cunha A.S. São Paulo, Servier Ed., p. 31.
- BERGGREN, W.L. & WELLER, T., 1967. Immunoelectrophoretic demonstration of specific antigen in animals infected with *Schistosoma mansoni*. *Am. J. Trop. Med. Hyg.*, 16 :606-612.
- BINA, J.C.; ANDRADE, Z.A.; DIETZE, F. & PRATA, A., 1984. A field study of proteinuria in individuals infected with *Schistosoma mansoni*. (Submitted for publication).
- BJØRNEBOE, M. & PRYTZ, H., 1976. In: Immunological aspects of the liver and gastrointestinal tract., p. 251. Ferguson, A., Mac Sween, R.N.M.; M.T.P. Press, Lancaster.
- BRITO, E.G.V., 1973. Patologia renal na esquistossomose mansônica hepatoesplênica. Um estudo em material de biópsias renais. Thesis University of Bahia Faculty of Medicine, Brazil.
- BRITO, T.; BONI, D.; LOPES, J.D. & SILVA, L.C., 1969. Kidney biopsy in human schistosomiasis. An ultrastructural study (preliminary report). *Rev. Inst. Med. trop. São Paulo*, 11 :62-64.
- BRITO, T.; GUNJI, J.; CAMARGO, M.E.; CARAVOLO, A. & SILVA, L.C., 1971. Glomerular lesions in experimental infections of *Schistosoma mansoni* *Cebus apella* monkeys. *Bull WHO* 45 :419-422.
- BRITO, T.; GUNJI, J.; CAMARGO, M.E.; PENNA, D.O. & SILVA, L.C., 1970. Advanced kidney disease in patients with hepatosplenic Manson's schistosomiasis. *Rev. Inst. Med. trop. São Paulo*, 12 :225-235.
- CARRIER, Y.; BOUT, D.; BINA, J.C.; CAMUS, D.; FIGUEIREDO, J.F.M. & CAPRON, A., 1975. Immunological studies in human schistosomiasis. I. Parasitic antigen in urine. *Amer. J. Trop. Med. & Hyg.*, 24 :949-954.
- DFELDER, A.M.; KLAPPE, H.T.M.; AARDWEG, G.J.M.J.; MEERBEKE, E.H.E.M., 1976. *Schistosoma mansoni* demonstration of two circulating antigens in infected hamsters. *Exper. Parasitol.* 40 :189-197.
- DIGEON, M.; DROZ, D.; NOEL, L.H.; RIZA, J.; RIEUMAILHOL, C.; BACH, J.F.; SANTORO, F. & CAPRON, A., 1979. A role of circulating immune complexes in the glomerular disease of experimental hepatosplenic Schistosomiasis. *Clin. exp. Immunol.*, 35 :329-337.
- HILLYER, G.V., 1973. Schistosoma deoxyribonucleic acid (DNA) antibodies to DNA in schistosoma infection, and their possible role in renal pathology. *Bol. Assoc. Med. P. Rico* 66 :1-22.
- HILLYER, G.V.; CAMPOS, J.A.; LLUBERES, R. & CANGIANO, J.L., 1975. Schistosomal nephropathy? I. Preliminary studies of a patient with schistosomiasis mansoni and glomerulonephritis in Puerto Rico. *Bol. Assoc. Med. PR* 67 :339-344.
- HILLYER, G.V. & LEWERT, R.M., 1974. Studies on renal pathology in hamsters infected with *Schistosoma mansoni* and *S. japonicum*. *Amer. J. Trop. Med. & Hyg.*, 23 :404-411.
- HOSHINO-SHIMIZU, S.; BRITO, T.; KANAMURA, H.Y.; CANTOAL SILVA, A.O.; CAMPOS, A.R.; PENNA, D.O. & SILVA, L.C., 1976. Human schistosomiasis *Schistosoma mansoni* antigen detection in renal glomeruli. *Trans. R. Soc. Trop. Med. Hyg.*, 70 :492-496.
- HOUBA, V., 1979. Experimental renal disease due to schistosomiasis. *Kidney Internat.*, 16 :30-43.

- HOUBA, V.; STURROCK, R.F. & BUTTERWORTH, A.E., 1977. Kidney lesions in baboons infected with *Schistosoma mansoni*. *Clin. exper. Immunol.* 30 :439-449.
- LEHMAN, J.S.JR.; MUTT, K.E.; DE SOUZA, C.A.M.; LEBOREIRO, O. & MUNIZ, T.M., 1975. The association of schistosomiasis mansoni and proteinuria in an endemic area. *Am. J. Trop. Med. Hyg.*, 24 :616-618.
- MORIEARTY, P.L. & BRITO, E., 1977. Elution of renal antischistosome antibodies in human schistosomiasis mansoni. *Am. J. Trop. Med. Hyg.*, 26 :717-722.
- NASH, T.E., 1974. Localization of schistosome antigen in *Schistosoma mansoni*. *Am. J. Trop. Med. Hyg.*, 23 :1085-1088.
- NATALI, P.G. & CIOLI, D., 1976. Immune complex nephritis in *Schistosoma mansoni* infected mice. *Eur. J. Immunol.*, 6 :359-364.
- OMER, H.O. & WAHAB, S.M.A., 1976. Secondary amyloidosis due to *Schistosoma mansoni* infection. *Brit. Med. J.* 1 :375-377.
- QUEIROZ, F.P.; BRITO, E.; MARTINELLI, R. & ROCHA, H., 1973. Nephrotic syndrome in patients with *Schistosoma mansoni* infections. *Am. J. Trop. Med. Hyg.*, 22 :622-628.
- ROBINSON, A.; LEWERT, R.M. & SPARGO, B.H., 1982. Immune complex glomerulonephritis and amyloidosis in *Schistosoma japonicum* infected rabbits. *Trans. Roy. Soc. Trop. Med. Hyg.*, 76 :214-226.
- ROCHA, H.; CRUZ, T.; BRITO, E. & SUSIN, M., 1976. Renal involvement in patients with hepatosplenic schistosomiasis mansoni. *Am. J. Trop. Med. Hyg.*, 25 :108-115.
- SADIGURSKY, M. & ANDRADE, Z.A., 1978. Esquistossomose e amiloidose renal. *Rev. Inst. Med. trop. São Paulo*, 20 :67-69.
- SILVA, J.R., 1949. Estudo clínico da esquistossomose mansoni. *Rev. Ser. Esp. Saúde Públ.*, 3 :3-352.
- SILVA, L.C.; BRITO, T.; CAMARGO, M.E.; BONI, D.R.; LOPES, J.D. & GUNJI, J., 1970. Kidney biopsy in hepatosplenic form of infection with *Schistosoma mansoni* in man. *Bull WHO* 42 :907-910.
- TADA, T.; KONDO, Y.M.; OKUMURA, K.; SANO, M. & YOKOGAWA, M., 1975. *Schistosoma japonicum*: Immunopathology of nephritis in *Macaca fascicularis*. *Exp. Parasitol.*, 38 :291-302.
- THEOFILOPOULUS, A.N. & DIXON, F.J., 1980. Immune complexes in human diseases. A Review. *A.J. Path.* 100 :531-594.
- VAN MARCK, E., 1975. Presence of circulating polysaccharide antigen in the liver of mice infected with *Schistosoma mansoni*. *Ann. Soc. Belg. Med. Trop.* 55 :373-377.
- VAN MARCK, E., 1983. The glomerulopathy associated with *Schistosoma mansoni* infection. An experimental study in the mouse. Thesis, Prince Léopold Institut of Tropical Medicine. Antwerp, Belgium.
- VAN MARCK, E.; DEELDER, A.M. & GIGASE, P.L.J., 1977. Effect of partial porta vein ligation of immune glomerular deposits in *Schistosoma mansoni* infected mice. *Br. J. Exper. Path.* 58 :412-417.
- VON LICHTENBERG, F.; BAWDEN, M.P. & SHEALEY, S.M., 1974. Origin of circulating antigen from the schistosome got. An immunofluorescence study. *Amer. J. Trop. Med. & Hyg.* 23 :1089-1091.
- VON LICHTENBERG, F.; SADUN, E.H. & BRUCE, J.I., 1972. Renal lesion in *Schistosoma japonicum* infected rabbits. *Trans. Royal Soc. Trop. Med. & Hyg.*, 66 :505-507.
- VON LICHTENBERG, F.; SADUN, E.H.; CHEEVER, A.W.; ERICKSON, D.G.; JOHNSON, A.J. & BOYCE, H.W., 1971. Experimental infection with *Schistosoma japonicum* in chimpanzees: Parasitologic, clinical serologic and pathological observations. *Am. J. Trop. Med. Hyg.*, 20 :850-893.