

CANINE VISCERAL LEISHMANIASIS IN RIO DE JANEIRO, BRAZIL.  
CLINICAL, PARASITOLOGICAL, THERAPEUTICAL AND  
EPIDEMIOLOGICAL FINDINGS (1977-1983)

MAURO C.A. MARZOCHI\*, SERGIO G. COUTINHO\*, WILSON J.S. DE SOUZA\*,  
LUCIANO M. DE TOLEDO\*, GABRIEL GRIMALDI JR.\*\*\*, HOOMAN MOMEN\*\*\*\*,  
RAQUEL DA S. PACHECO\*\*\*, PAULO C. SABROZA\*\*\*\*, MIGUEL A. DE SOUZA\*\*\*\*,  
FRANCISCO B. RANGEL JR.\*\*\*\*\* & NEIDE C. TRAMONTANO\*\*\*\*\*

*Forty dogs from the periphery of the city of Rio de Janeiro were studied. All dogs were diagnosed as positive for leishmaniasis either parasitologically and/or serologically. Among them, 19 came from areas where only Visceral Leishmaniasis (VL) occurs (Realengo, Bangu, Senador Camará). Clinical signs of the disease were seen in 36.8% of the cases, including emaciation – 100%, lymphadenopathy and depilation – 85.7%. The other 21 dogs came from an area (Campo Grande) where both diseases (VL, and American Cutaneous Leishmaniasis – ACL) occur. Clinical signs of the disease, mainly cutaneous or mucocutaneous ulcers were seen in 76.2% of the cases. Leishmania parasites were found in 39 cases: 22% in viscera, 42.5% in viscera and normal skin and 35% in cutaneous or mucocutaneous ulcers. All the Leishmania stocks isolated from dogs which came from Realengo, Bangu, Senador Camará (VL area), and from Campo Grande (VL + ACL area) were characterized as L. donovani (except in one case) according to their schizodeme, zymodeme and serodeme. The only stock characterized as L. b. braziliensis, was isolated from the lymph node of a dog from Campo Grande with visceral disease and without skin lesions. Antimony therapy attempted in eight Leishmania donovani positive dogs was unsuccessful.*

In each known endemic area of Visceral Leishmaniasis (VL) in Brazil, canine Visceral Leishmaniasis has always been found to occur simultaneously with the human disease. However the prevalence of canine VL is always higher and it generally precedes the occurrence of the human disease (Alencar, 1959). The clinical picture of American canine VL (caused by *L. donovani chagasi*) is similar to Mediterranean canine kala-azar which ranges from apparently healthy animals to the severe final stages of the disease. The incubation and prepatent periods vary from three to six months until several years in experimentally infected dogs as well as in the natural infection. Parasitism can be latent and patent producing an acute, sub acute, chronic or regressive form of the disease after a period that may last from weeks to years (Cunha, 1938; Alencar, 1959; Lanotte et al., 1979). The clinical picture as a whole is similar to that of the human disease. In both cases, irregular fever for large periods, colorless mucous membranes, progressive loss of weight and cachexia occur at the final stage of the disease. Hepatosplenomegaly and generalized enlargement of lymph glands with hypertrophy of the phagocytic mononuclear system (PMS) seem to occur more often than has been described previously. However, the clinical signs which have been described most frequently are: localized or generalized loss of hair, desquamation and eczema, opaque hair, single or confluent small crusted ulcers, mainly on the snout and ear; hepatrophy of claws (onychogryphosis); opacification of the cornea (keratoconjunctivitis) which appears after episodes of conjunctivitis. Other clinical signs have also been noted, such as apathy, diarrhoea and intestinal bleeding; hind legs paraplegia, oedema and vomiting (Donatien & Lestoquard, 1938; Cunha, 1938; Alencar, 1959; Lanotte et al., 1979).

---

Partially supported by the National Council for Scientific Development (CNPq).

Instituto Oswaldo Cruz, \*Departamento de Protozoologia, \*\*Departamento de Ultraestrutura e Biologia Celular, \*\*\*Departamento de Bioquímica e Biologia Celular, Caixa Postal 926, 20000 Rio de Janeiro, RJ, Brazil.

\*\*\*\*Escola Nacional de Saúde Pública – FIOCRUZ – Rio de Janeiro.

\*\*\*\*\*Universidade Federal Rural do Rio de Janeiro.

\*\*\*\*\*SUCAM (Ministry of Health) – Rio de Janeiro.

Received for publication February 21st and accepted May 15th, 1985.

Alterations in the blood patterns have been described in *L. donovani* infected dogs. Dedet (1979) mentioned anemia mainly of the normochromic type (62%), mild leucopenia (33%), and haemorrhagic events related to thrombocytopenia in a few cases.

Serum protein electrophoresis has shown hypergammaglobulinemia in 70.5% of the cases (Dedet, 1979) with inverted albumin/globulin index and according to Alencar (1959) an increased beta fraction.

A correct diagnosis of leishmaniasis is based on the detection of the parasite in the tissues, including the apparently healthy skin, since parasites can be easily found in cells from the PMS. According to Lanotte et al. (1974) attempts to isolate the parasite (culture in NNN medium) from biopsy samples collected from spleen, liver, bone marrow, lymph nodes, lead to high ratios of positivity.

Several methods have also been used for the detection of serum antibodies to *Leishmania*, e.g., the Complement Fixation Test – CFT (Nussensweig, Nussensweig & Alencar, 1957; Brener, 1957; Alencar, 1959); the indirect immunofluorescent test – IFT (Lanotte et al., 1974; Iverson et al., 1983; Coutinho et al., 1985); counter immunoelectrophoresis and ELISA (Monsueto, Miceli & Quartaraso, 1982). In Brazil, the CFT (Pellegrino & Brener, 1958; Cunha, Alencar & Andrade, 1963; Alencar et al., 1974; Magalhães et al., 1980) and recently the IFT on eluate blood from filter paper (Coutinho et al., 1985) have been used for epidemiological surveys.

In contrast to the situation in human VL, antimony therapy in canine VL has proven infective (Pigoury, 1938; Alencar, 1959; Dedet, 1979; Lanotte et al., 1979; Di Leo et al., 1981).

From the epidemiological point of view, canine VL has been considered more important than the human disease since the former has a higher prevalence, and many asymptomatic animals with parasites in the skin have been detected in endemic areas. Dogs with or without clinical signs, have been considered as a better source for vector infection (*Lutzomyia longipalpis*) than human cases of VL (Deane & Deane, 1955). Parasites in the skin of the dog may also permit the direct intercanine transmission of the disease without phlebotomine participation. In this case, bites during animal fighting, copulation and probably also ingestion of mites can play a role in the transmission of the parasite (Alencar, 1959).

Foxes (*Lycalopex vetulus*) in Ceará state (Deane & Deane, 1954) and another canine, *Cerdocyon thous*, in Pará state (Lainson, Shaw & Luis, 1969) have also been suggested as wild hosts of *L. donovani*.

The first autochthonous human case of kala-azar in the periphery of the city of Rio de Janeiro was diagnosed in 1977. This patient lived in the area of Bangu, on the northern border of the Pedra Branca mountain chain, where the vector *Lutzomyia longipalpis* has been captured mainly at altitudes higher than 100 meters (Souza et al., 1981). A preliminary search for canine VL was undertaken by a team from FIOCRUZ. Twenty four of 30 dogs from that area were examined: a skin biopsy from the animal ear was taken for parasitological (“imprints”) and histopathological examination. Amastigote forms of the parasite were seen in the ear sample (histopathological examination) from only one dog. This was a very thin animal which at that time had a few skin ulcers in the ears and slightly elongated nails. It recovered spontaneously after being fed properly for three months, but was sacrificed for histopathological and parasitological examination. *Leishmania* parasites were not found in the viscera, lymph nodes or bone marrow even after culture in NNN medium and inoculation in hamsters (data not published). Later, Marzochi et al. (1981a) were able to isolate *Leishmania* parasites from two out of five other dogs examined from another area (Realengo) near Bangu, where human cases of VL were also diagnosed. The five dogs had clinical signs of kala-azar.

A survey for canine VL was done in 1980 by the Ministry of Health (SUCAM) among dogs from Realengo, Bangu and Senador Camará using parasitological examination (“imprint”) from ear cuts and CFT for serum antibodies to *Leishmania*. The serology performed in the University of Minas Gerais (Dr. W. Mayrink) showed ten positive dogs (1.96%) among the 526 examined. Another ten dogs had positive “imprints” for amastigote forms of *Leishmania* but had negative CFT. *Leishmania* stocks isolated from five out of the ten CFT positive animals were characterized as *Leishmania donovani* according to their zymodeme and schizodeme which were similar to those of the stocks isolated from human cases in the same area (Marzochi et al., 1981a; Momen, Grimaldi Jr. & Marzochi, 1983; Lopes et al., 1984).

Another survey for canine Leishmaniasis was done by SUCAM and FIOCRUZ in 1982 using the IFT. According to Coutinho et al. (1985) 4.3% of IFT positive dogs were found in areas where only VL occurs (Realengo, Bangu and Senador Camará); 12.7% in Campo Grande where

both diseases (VL and American Cutaneous Leishmaniasis – ACL) are present; and 8.6% in another area (Pau da Fome – Jacarepaguá) where only cases of ACL were found in humans.

Previous results had shown that *L. braziliensis braziliensis* was always the parasite isolated from human or canine cases of ACL from Pau da Fome – Jacarepaguá which is an area located on the Northeastern border of the Pedra Branca mountain chain (Marzochi et al., 1982).

The present results show the clinical, parasitological and therapeutical findings in infected dogs captured during epidemiological surveys for kala-azar in Rio de Janeiro.

## MATERIALS AND METHODS

**The area:** in Rio de Janeiro, human or canine cases of VL have occurred in the North (Realengo and Bangu), Northeast (Senador Camará) and West border (Campo Grande) of the Pedra Branca mountain chain, between parallels 22°50' and 23°05' S, and meridians 43°35' and 43°20' W, around 100 m above sea level (Fig. 1).

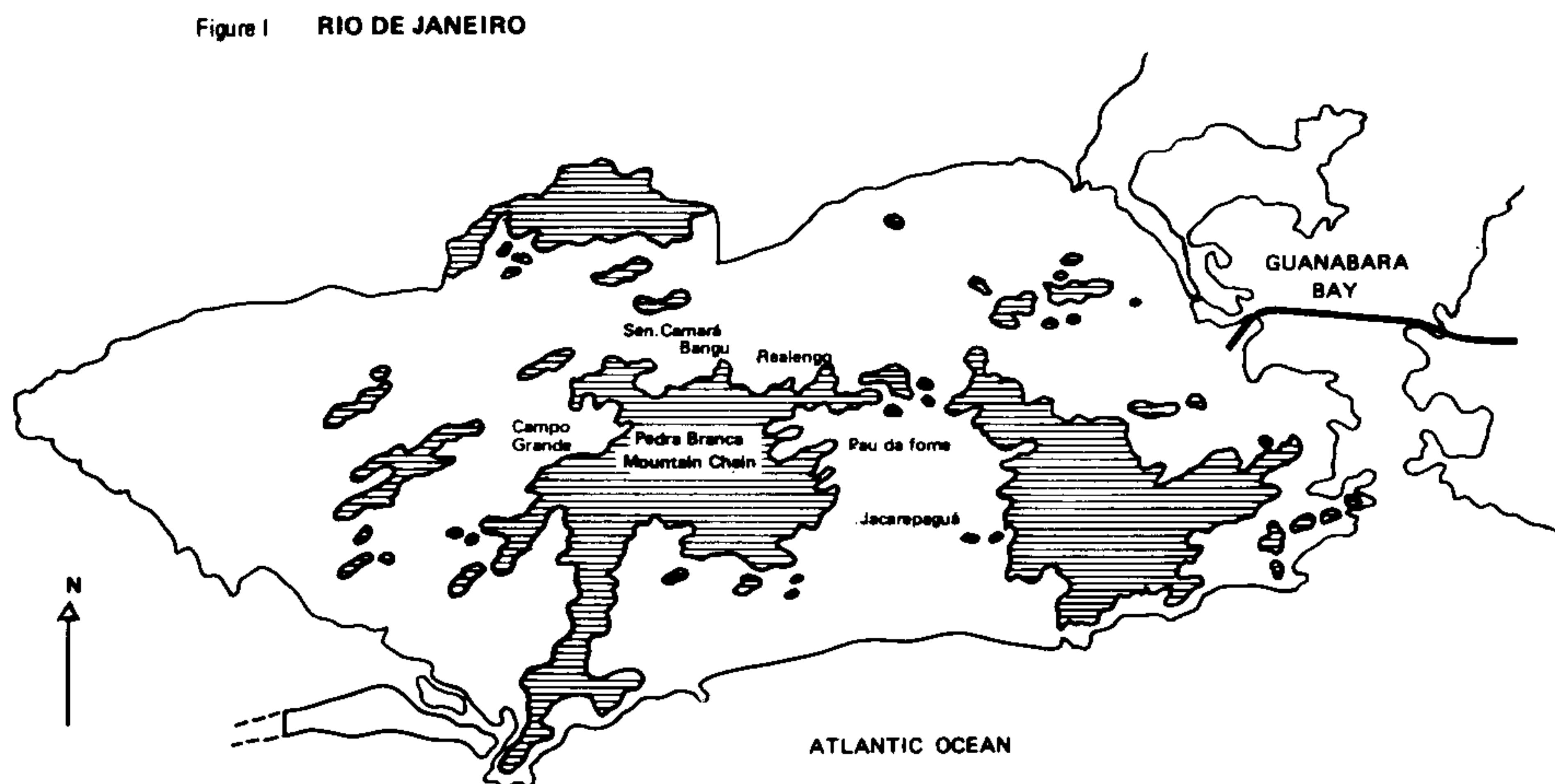


Fig. 1: municipality of Rio de Janeiro, showing sites mentioned in the text.

This region has a predominantly Aw (Köppen) type of climate, the annual mean temperature being 27.7°C, the annual rainfall more than 1,400 mm (less than 60 mm in the dry season from July to August) and the relative humidity around 70% (Rio de Janeiro, 1979). The mountain chain rises to a peak of 1024 m. The peri-urban human population living on the borders of the mountains has a low income and is predominantly engaged in rural activities (Marzochi et al., 1985). Neither human or animal Chagas' disease nor its vector (*Triatominae*) have ever been detected in this region.

**The dogs:** during the epidemiological surveys in Rio de Janeiro, 40 dogs which were found to have a positive parasitological and/or serological test for Leishmaniasis, were either sacrificed or kept for clinical and laboratorial studies in areas at risk for transmission of VL.

The origin of the dogs was as follows: six from Realengo, six from Bangu, seven from Senador Camará (areas where only VL occurs) and 21 from Campo Grande where VL + ACL are found. Their age was estimated between one and five years. The proportion of males was 60%. All 40 dogs were submitted to: a) a thorough clinical examination; b) biopsy of skin or mucosal lesions if present; c) biopsy of normal skin at the inner side of the thigh; d) collection of peripheral blood samples for serology and biochemistry.

The biopsy samples were subdivided for parasitological examination as follows: Giemsa stained imprints; culture in NNN medium after washing in Hank's solution containing antibiotics (Lopes et al., 1984) and inoculation in hamsters in a few cases. Histopathological examination was also done on each biopsy sample.

Since 1982 the indirect immunofluorescent test (IFT) has been utilized in this laboratory for detection of serum antibodies to *Leishmania* (Coutinho et al., 1985). The anti-dog Ig total fluorescent labelled antibodies were kindly provided by Dr. Mario Camargo from the University of São Paulo (Dept. of Tropical Medicine).

Later, 39 out of the 40 dogs were sacrificed for macroscopical and histopathological examination of spleen, liver, lymph nodes, bone marrow, skin and genitalia. Necropsy samples from spleen, liver, lymph node and bone marrow were pooled together in attempts to isolate the parasite in culture medium (Marzochi et al., 1983; Lopes et al., 1984). Hamster inoculation was also done in a few cases.

**Characterization of *Leishmania* parasites:** some of the *Leishmania* stocks isolated from the dogs were characterized using biochemical and immunological techniques. Full details about the strains of *Leishmania* used in the study are shown in Table III. After *in vitro* cultivation the parasites were examined by the following techniques: 1) restriction analysis of kinetoplast DNA (kDNA) also known as schizodeme analysis using the following endonucleases: MspI, RsaI, TaqI and MboI (Lopes et al., 1984; Pacheco et al., 1984); 2) isoenzyme characterization or zymodeme analysis by agarose gel electrophoresis using the following enzymes: malate dehydrogenase (MDH), alanine aminotransferase (ALAT), aspartate aminotransferase (ASAT), glucose phosphate isomerase (GPI), phosphoglucomutase (PGM) and glucose-6-phosphate dehydrogenase (GGPDH) (Momen, Grimaldi & Marzochi, 1983; Lopes et al., 1984); 3) serodeme analysis based on the parasite characteristic reactivities with a panel of *Leishmania* species and sub species-specific monoclonal antibodies using either an indirect radio-immune binding assay or immunofluorescence and immunoperoxidase techniques (Grimaldi & McMahon-Pratt, 1984). The monoclonal antibodies used in the specific study for members of the *L. donovani*, *L. braziliensis* and *L. mexicana* complexes have already been described in part (McMahon-Pratt, Jafee & Grimaldi, 1984; Jaffe et al., 1984).

**Therapy:** eight IFT and parasite positive dogs (*L. donovani*) were submitted to antimony therapy (Glucantime), 100mg/kg/day for 20 days. The dogs (one Doberman and seven street dogs) did not have important clinical signs of the disease before therapy, except slight emaciation and a few skin crusted ulcerations.

## RESULTS

**Clinical findings:** *Leishmania* positive biopsy samples and/or positive IFT were observed in all 40 dogs. Clinical signs of VL were detected in only seven (36.2%) out of 19 dogs from areas where only VL occurs, while clinical findings (mainly skin ulcers) were seen in 16 (76.2%) out of 21 dogs from Campo Grande, where VL + ACL are present.

The concomitance of two or more signs in the same animal was seen in the majority of the dogs from VL areas.

Table I shows the frequency of each clinical signs observed in the dogs from both areas. The histopathological, haematological and biochemical findings will be published elsewhere.

**Indirect Immunofluorescent Test:** the IFT was done in 31 dogs. Anti-*Leishmania* positive titers higher than 1:40 were observed in 30. The only IFT negative animal had only skin ulcers, where parasites were detected. *Leishmania* was not isolated from viscera at necropsy, in this case.

**Parasitological findings:** *Leishmania* parasites were detected in 39 out of the 40 dogs examined. However, the only parasite negative case had a positive IFT. Table II shows the frequency of parasite detection according to the origin of samples obtained at biopsy (77.2%) and necropsy (85.0%). Most of the samples from skin or mucosal ulcers were obtained from dogs of Campo Grande (VL + ACL area), where four dogs were positive in biopsies and ten at necropsy.

Inoculation of hamsters was done in only a few cases. The results can not be compared, therefore, to the other diagnostic methods. However, each inoculated hamster developed visceral infection which led to death within six months.

Eleven *Leishmania* stocks isolated from 11 dogs were analysed according to their zymodeme, schizodeme and serodeme, as shown in Table III.

From the ten *Leishmania* stocks characterized as *L. donovani*, nine were isolated from viscera and/or normal skin, and one from a skin ulcer on the ear (Table III, case No. 1). The only *Leishmania* stock characterized as *L. b. braziliensis* was isolated, surprisingly, from a lymph node from Campo Grande (VL + ACL area) which had an enlarged liver and spleen. Amastigote forms of the parasite were easily detectable in those viscera and also in the bone marrow, by microscopical examination.

**Therapy:** eight dogs were submitted to antimony therapy. All showed a severe deterioration of health, which started during or just after therapy. Demonstration of *Leishmania* parasites in normal skin and positive IFT were also consistently observed after therapy. A Doberman dog submitted to therapy died 30 days after the last injection of antimony, showing decrease in weight, severe illness, depilation, eczema, paraplegy, apathy and a high parasite load (Dog No. 2).

TABLE I

Clinical findings observed in 19 dogs from areas where only visceral leishmaniasis (VL) occurs and in 21 dogs from areas where both visceral and american cutaneous leishmaniasis (ACL) are present.

Clinical Signs	Areas of Visceral Leishmaniasis		Areas of Visceral and Cutaneous Leishmaniasis	
	Frequency	%	Frequency	%
Emaciation	7	100	9	56.3
Lymphadenopathy	6	85.7	6	37.5
Depilation	6	85.7	5	31.3
Apathy	5	71.4	5	31.3
Ulcers	3	42.9	14	81.5
Desquamations and Eczema	3	42.9	3	18.8
Onychogryphosis	3	42.9	5	31.3
Intestinal bleeding	1	14.3	1	6.3
Keratoconjunctivitis	1	14.3	1	6.3
Paraplegia	1	14.3	1	6.3
One or More Clinical Signs	7	36.8	16	76.2
Without Clinical Signs	12	63.2	5	23.8

TABLE II

Demonstration of *Leishmania* amastigotes among 40 dogs from endemic areas of visceral and mucocutaneous leishmaniasis in Rio de Janeiro, submitted to biopsy and later, to necropsy

Skin and Mucosal biopsies	Aspect of skin and mucosae	Number and (%) of dogs examined	Amastigotes in Viscera (Necropsy)			Number and (%) of dogs with amastigotes found by biopsy or necropsy
			Present (%)	Absent (%)	Not Examined	
Positive	Apparently normal	17 (42.5)	17 (42.5)	0 (0)	—	17 (42.5)
	with lesions	14 (35.0)	9 (22.5)	4* (19.0)	1 (2.5)	14 (35.0)
Negative	Normal or with lesions	9 (22.5)	8 (20.0)	1** (2.5)	—	8 (20.0)
Total		40 (100)	34 (85.0)	5 (12.5)	1 (2.5)	39 (97.5)

\*One dog negative by the immunofluorescent test

\*\*Dog with a positive immunofluorescent test

TABLE III

Origin, clinical manifestation and results of parasite identification of the *Leishmania* stocks isolated from dogs in endemic areas of kala-azar in Rio de Janeiro

Dog. No.	Strain Designation	Reference Number	Where Isolated	Clinical Manifestation	Parasite characterization		
					By serodeme analysis W/Monoclonal antibodies	By schizodeme Analysis	By zymodeme Analysis
1	MCAN/BR/81/CCG1	IOC-L25	C. Grande-RJ	CL	<i>L. donovani</i>	ND	<i>L. donovani</i>
2	MCAN/BR/82/DOB19	IOC-L38	C. Grande-RJ	KA	<i>L. donovani</i>	<i>L. donovani</i>	<i>L. donovani</i>
3	MCAN/BR/82/CCG3	IOC-L39	C. Grande-RJ	KA	<i>L. donovani</i>	<i>L. donovani</i>	<i>L. donovani</i>
4	MCAN/BR/80/CR1	IOC-L44	Realengo-RJ	KA	<i>L. donovani</i>	<i>L. donovani</i>	<i>L. donovani</i>
5	MCAN/BR/80/CR3	IOC-L45	Realengo-RJ	KA	<i>L. donovani</i>	<i>L. donovani</i>	<i>L. donovani</i>
6	MCAN/BR/80/CR9	IOC-L46	S. Camará-RJ	KA	<i>L. donovani</i>	<i>L. donovani</i>	<i>L. donovani</i>
7	MCAN/BR/80/CR10	IOC-L47	S. Camará-RJ	KA	<i>L. donovani</i>	<i>L. donovani</i>	<i>L. donovani</i>
8	MCAN/BR/81/CCG2	IOC-L148	C. Grande-RJ	VI	<i>L. donovani</i>	<i>L. donovani</i>	<i>L. donovani</i>
9	MCAN/BR/80/CR11	IOC-L153	S. Camará-RJ	KA	<i>L. donovani</i>	<i>L. braziliensis</i> sp	<i>L. braziliensis</i>
10	MCAN/BR/83/Buzuca	IOC-L250	C. Grande-RJ	KA	<i>L. donovani</i>	<i>L. donovani</i>	<i>L. donovani</i>
11	MCAN/BR/82/Tigre	IOC-L318	C. Grande-RJ	KA	<i>L. donovani</i>	ND	ND

CL = Cutaneous Leishmaniasis; KA = Kala-azar (parasite isolated from spleen and/or "normal" skin); VI = visceral infection (parasite isolated from lymph node); ND = not determined

## DISCUSSION

The focus of human and canine visceral leishmaniasis in Rio de Janeiro is apparently the most recent and meridional endemic area detected in Brazil (Marzochi et al., 1981b). Forty-three human cases have been diagnosed so far (July 1984 – data from SUCAM, M.H.). *Lutzomyia longipalpis* and infected dogs have also been found in the area. The prevalence of canine infection was higher than the human infection (Coutinho et al., 1985) as has been described in other endemic areas in Brazil.

Despite the fact that different diagnostic methods were used, the observation that infected animals were hardly detected from 1977 to 1979 in contrast to what occurred after 1979, points to the possibility of a recent introduction of the parasite in that region. However, the recent disease control activities carried out by SUCAM seem to have had a significant influence in the decreasing incidence of human VL (Marzochi et al., 1985). In Senador Camará cases of human VL have never been diagnosed till now, in spite of the presence of canine infection.

The clinical picture of canine kala-azar in Rio de Janeiro is similar to the dog disease observed in Northeast Brazil (Deane, 1956; Alencar, 1959; Alencar & Cunha, 1963), and in the Mediterranean areas of South Europe and North Africa (Adler & Theodor, 1935; Malamos, 1947; Lanotte et al., 1979; Dedet, 1979; Pozio et al., 1981).

The proportion of asymptomatic infected dogs from areas in Rio de Janeiro where only VL occurs (63.2%) is similar to that observed in Malta – 60% (Adler & Theodor, 1935), Greece – 50% (Malamos, 1947), Toscana (Italy) – 50% (Pozio et al., 1981) but lower than the proportion found by Alencar & Cunha (1963) in Northeast of Brazil (Ceará state) – 86%.

Lanotte et al. (1979) have studied natural infection of dogs in Southeast France (Cévennes). They described two kinds of clinical forms for canine VL: patent and latent; the latter could be “pre-clinical” (90%) or in the process of healing (10%).

Pozio et al. (1981) have carried out a canine VL longitudinal study on the West Cost of Italy (Toscana). They found symptomatic and asymptomatic animals. One year later 88% of the symptomatic animals had died and 12% maintained a patent disease. On the other hand, 52% of the asymptomatic animals had apparently recovered with negativation of the IFT, 12% remained asymptomatic, 18% had changed to a patent disease and 18% had died over a one year period.

Our previous observations showed only one case of VL with spontaneous healing (resolutive clinical form) in 1977, probably because most of the positive dogs were killed by SUCAM or at the laboratory for necropsy as soon as they were diagnosed.

The physio-pathology of canine kala-azar has not been studied in depth despite recent progress in the immunopathological field. According to Hommel (1978) hair loss has been explained by a direct effect of *Leishmania* on the hair follicle or by a panthogenic acid metabolic disturbance due to the severe hepatic lesions or, finally, by the deposition of immunocomplexes on the basal membrane of the skin.

The abnormal growing claws have been explained by a direct parasite stimulation on the nail's matrix (Lestoquard & Donatien, 1938). It should also be considered that the hypertrophy of claws can also be the result of a diminished usage of the nail by sick, apathic dogs.

According to Catarsini (1981), the dog leanness is caused by the parasites present all over the mucous membrane of the digestive tract. According to Adler (1964) the leanness could be explained by a proteic disbalance which led to severe albuminuria, reversible by fresh meat feeding.

As Catarsini, Ferlazzo & Omero (1979) have showed, canine infection is followed by a significantly severe altered free amino acids seric pattern, related to the higher levels of alanine, histidine and carnosine in contrast to the lower levels of tryptophan. The explanation for fever, eczema, skin and mucous membrane ulcers, sub-cutaneous nodules, keratites and neurological signs are less conclusive (Hommel, 1978).

The clinical signs observed in canine VL in Rio de Janeiro have been relatively constant. Coutinho et al. (1985) observed 12.7% of IFT positive dogs in Campo Grande, where both diseases (VL and ACL) occur. Dogs from that area also had a proportionally greater number of skin ulcers. *Leishmania* was detected in 14 cases in skin ulcers but not in the viscera. Sherlock & Almeida (1970) had already commented on the possibility of concomitant cases of VL and ACL in localities from the state of Bahia.

As a whole, a close correlation between type and intensity of the clinical signs, and the evidences of parasites in the normal skin and/or viscera was not observed.

The present results show that the highest antibody titres occurred in the animals with a visceral involvement. In all IFT positive dogs, including the asymptomatic animals, the parasite was detected in the skin and/or viscera, while Pozio et al. (1981) in Italy have found the parasite in only 31.9% of the IFT positive animals.

The characterization of five *Leishmania* stocks isolated from areas of VL and ACL by the schizodeme, zymodeme and serodeme analysis showed an homogeneous pattern similar to the *Leishmania donovani* stocks from human patients in those same areas (Momen, Grimaldi & Marzochi, 1983; Lopes et al., 1984; Pacheco et al., 1984).

Surprisingly, *L. donovani* was isolated from the skin ulcers of a dog (No. 1, Table III) captured in the area of VL and ACL. It did not have any clinical sign of kala-azar.

Two *Leishmania* stocks obtained through NNN culture medium and hamster inoculation, respectively, were isolated from the lymph nodes of another dog also from Campo Grande (area of VL and ACL). A great number of parasites in the viscera of this dog were seen in the necropsy samples. The *Leishmania* stocks isolated in NNN medium were characterized as *L. b. braziliensis* (IOC-L 148). They had a pattern similar to the *L. b. braziliensis* stocks isolated from human cases of ACL from that same area (Lopes et al., 1984). The *Leishmania* stocks (CGD = CCG2) isolated from the same lymph node inoculated in hamster as referred to above, was considered similar to the *Leishmania donovani* stocks isolated from human cases of VL in Bangu (area of VL) (Leplay, Nogueira & Cohn, 1983). The possibility of a double infection by *L. b. braziliensis* and *L. donovani* in a single animal can not be rejected.

Furthermore, the evidence of canine visceral infection by *L. b. braziliensis* points to the necessity of a more accurate study of the dog disease in areas where ACL occurs (Marzochi et al., 1983).

In the studied areas of VL and ACL, the concomitance of skin (scrotum, prepuce) and mucosal ulcers (nose) was observed.

Previous attempts at canine therapy using higher doses of antimony as compared to the human therapy have been unsuccessful (Adler & Theodor, 1932; Pigoury, 1938; Alencar, 1959; Dedet, 1979; Di Leo, 1981; Pozio et al., 1981).

Cutaneous alterations (desquamation, opaque hair, depilation and ulcers) appeared on a previously normal skin in the dogs under antimony therapy. According to Ranque & Cabassu (1948) and Alencar (1959) that type of lesion could be related to a Herxheimer reaction provoked by a high load of released antigens due to parasite killing.

The unsuccessful dog antimony therapy could also be explained by a higher antimony renal excretion, by a different liver antimony metabolism, or by an unusual immune response, in the sick dogs. All these hypotheses could be investigated.

The evidence for a large spreading canine enzootic kala-azar which starts in Bangu, a great proportion of infected asymptomatic dogs and the lack of an efficient therapy, emphasize the importance of serological or parasitological surveys for the early detection of the canine disease. The elimination of each positive dog must be included in the framework of all other control activities.

The availability of a vaccine for canine leishmaniasis would provide an efficient tool toward prophylaxis of both canine and human diseases. The development of such a vaccine should nowadays be technically possible; application of it would be ethically feasible and economical, since it could be injected simultaneously with the canine rabies vaccine, of which the control program is already well organized in Brazil.

## RESUMO

Durante inquéritos caninos realizados na periferia da cidade do Rio de Janeiro, foram estudados clínica e laboratorialmente 40 cães. Todos apresentavam diagnóstico parasitológico e/ou sorológico de leishmaniose. Dentre esses, 19 procediam de áreas de ocorrência de leishmaniose visceral (LV) — Realengo, Bangu e Senador Camará. Sinais clínicos sugestivos da infecção foram observados em 36,8% deles (incluindo emagrecimento — 100%, linfadenopatia e depilação — 85,7%). Outros 21 cães procediam da área de Campo Grande onde tanto a LV como a leishmaniose tegumentar americana (LTA) ocorrem. Sinais clínicos da infecção por *Leishmania*, principalmente ulcerações cutâneas e mucocutâneas, foram observadas em 76,2% deles. Em 39 cães foram encontrados leishmanias: 22% em vísceras, 42,5% em vísceras e pele normal e 35% em ulcerações cutâneas ou mucocutâneas. Todos os estoques de *Leishmania* isolados de cães provenientes das áreas de LV e da área de LV + LTA foram caracterizados como *L. donovani* (exceto em um caso) conforme seus esquisodemas, zimodemas e serodemas. O único estoque caracterizado como *L. brazi-*

*liensis braziliensis* foi isolado de linfonodo de um cão de Campo Grande, com leishmaniose visceral e sem alterações cutâneas. A tentativa de tratamento pelo antimonial em oito cães positivos para *Leishmania donovani* não reverteu o curso da doença e um deles apresentou intenso agravamento, morrendo em curto período.

#### ACKNOWLEDGEMENTS

We would like to thank Prof. Luiz Fernando Ferreira da Silva for the facilities provided by the Department of Biological Sciences – National Public Health School, FIOCRUZ (animal house and necropsy of several dogs). We would also like to thank Mr. Edilson de Souza, Gentil Dutra and Valmir Laurentino Silva for technical support during the necropsy of the animals and the isolation and culture of the *Leishmania* parasites.

#### REFERENCES

- ADLER, S., 1964. *Leishmania* in "Advances in Parasitology". Vol. 2 (B. Dawes). Academic Press, New York, p. 35-96.
- ADLER, S. & THEODOR, O., 1932. Investigations on Mediterranean Kala-azar. III – Canine visceral leishmaniasis. *Proc. Roy. Soc. London Ser B*, 110 :402-412.
- ADLER, S. & THEODOR, O., 1935. Mediterranean Kala-azar. VII – Further observations on canine visceral leishmaniasis. *Proc. Roy. Soc. London Ser B*, 116 :494-504.
- ALENCAR, J.E., 1959. Calazar canino. Contribuição para o estudo da epidemiologia do calazar no Brasil. Tese. Univ. Fed. Ceará, Imprensa Oficial, Fortaleza.
- ALENCAR, J.E.; ALMEIDA, Y.M.; SILVA, Z.F.; PAIVA, A.S. & FONSECA, M.F., 1974. Aspectos atuais do Calazar no Ceará. *Rev. Bras. Malariol. D. Trop.*, 26 :27-53.
- ALENCAR, J.E. & CUNHA, R.V., 1963. Inquéritos sobre calazar canino no Ceará – Novos resultados. *Rev. Bras. Malariol. D. Trop.*, 15 :391-403.
- BRENER, Z., 1957. Calazar canino em Minas Gerais. Tese, Belo Horizonte, Brazil.
- CATARSINI, O., 1981. Epidemiologia e manifestazione cliniche della leishmaniosi del cane. *Rev. Parasitol.*, 44 :83-87.
- CATARSINI, O.; FERLAZZO, A. & OMERO, A., 1979. Comportamento degli aminoacidi liberi del siero nel cane affetto da leishmaniosi. *Rev. Clin. Vet.*, 102 :25-30.
- COUTINHO, S.G.; NUNES, M.P.; MARZOCHI, M.C.A. & TRAMONTANO, N.C., 1985. A survey for american cutaneous and visceral leishmaniasis among 1.342 dogs from areas in Rio de Janeiro (Brazil) where the human disease occurs. *Mem. Inst. Oswaldo Cruz*, 80 :17-22.
- CUNHA, A.M., 1938. Infecções experimentais na leishmaniose visceral americana. *Mem. Inst. Oswaldo Cruz*, 33 :382-598.
- CUNHA, R.V.; ALENCAR, J.E. & ANDRADE, F.B., 1963. Uso da reação de fixação de complemento para diagnóstico do Calazar canino em inquérito de massa. *Rev. Bras. Malariol. D. Trop.*, 15 :405-410.
- DEANE, L.M., 1956. Leishmaniose visceral no Brasil: estudos sobre reservatórios e transmissores realizados no Estado do Ceará. Tese. Universidade de São Paulo. Serviço Nacional de Educação Sanitária, Rio de Janeiro.
- DEANE, M.P. & DEANE, L.M., 1954. Encontro de leishmanias nas vísceras e na pele de uma raposa em zona endêmica de calazar, nos arredores de Sobral, Ceará. *O Hospital*, Rio de Janeiro, 45 :419-421.
- DEANE, L.M. & DEANE, M.P., 1955. Observações preliminares sobre a importância comparativa do homem, do cão e da raposa (*Lycalopex vetulus*) como reservatórios de *Leishmania donovani* em área endêmica de Calazar no Ceará. *O Hospital*, Rio de Janeiro, 48 :61-70.
- DEDET, J.P., 1979. Les leishmanioses en Afrique du Nord. *Bull. Inst. Pasteur*, 77 :49-82.
- DI LEO, R.; CASSANDRA, F.; MANISCALCO, N. & NAPALI, G., 1981. Indagine sulla leishmaniosi canina nel Comune di Sciacca. *Rev. Parasitol.*, 42 :153-156.
- DONATIEN, A. & LESTOQUARD, F., 1938. Remarques sur l'évolution de la leishmaniose générale du chien. *Bull. Soc. Path. Exot.*, 31 :214-216.
- GRIMALDI JR., G. & McMAHON-PRATT, D., 1984. Immunological characterization of New World *Leishmania* stocks by means of monoclonal antibodies. *XI Reunião Anual de Pesquisa Básica em Doença de Chagas*, Caxambu – Brasil, Abstract I-55, p. 120.
- HOMMEL, M., 1978. The genus *Leishmania*. Biology of the parasite and clinical aspects. *Bull. Inst. Pasteur*, Paris, 75 :5-102.
- IVERSON, L.B.; CAMARGO, M.E.; VILLANOVA, A.; REICHMANN, M.L.A.B.; ANDRADE, E.A. & TOLEZANO, J.E., 1983. Inquérito sorológico para pesquisa de leishmaniose visceral em população canina-urbana do município de São Paulo – Brasil (1979-1982). *Rev. Inst. Med. trop. São Paulo*, 25 :310-317.
- JAFFE, C.L.; BENNET, E.; GRIMALDI JR., G. & McMAHON-PRATT, D., 1984. Production and characterization of species-specific monoclonal antibodies against *Leishmania donovani* for immunodiagnosis. *J. Immunol.*, 133 :440-447.



- LAINSON, R.; SHAW, J.J. & LUIS, Z.C., 1969. Leishmaniasis in Brazil. IV – The fox, *Cerdocyon thous* (L) as a reservoir of *Leishmania donovani* in Pará state, Brazil. *Trans. R. Soc. Trop. Med. Hyg.*, 63 :741-745.
- LANOTTE, G.; RIOUX, J.A.; CROSET, H. & VOLLHARDT, Y., 1974. Écologie des leishmanioses dans le sud de la France. 7 – Dépitage de l'enzootie canine par les méthodes immunosérologiques. *Ann. Parasitol. (Paris)*, 49 :41-62.
- LANOTTE, G.; RIOUX, J.A.; PERIERS, J. & VOLLHARDT, Y., 1979. Écologie des leishmanioses dans le sud de la France. 10 – Les formes évolutives de la leishmaniose viscérale canine. Elaboration d'une typologie bio-clinique à finalité épidémiologique. *Ann. Parasit. Hum. Comp.*, 54 :277-295.
- LEPLAY, D.A.; NOGUEIRA, N. & COHN, Z., 1983. Surface antigens of *Leishmania donovani* promastigotes. *J. Exp. Med.*, 157 :1562-1572.
- LESTOQUARD, F. & DONATIEN, A., 1938. Parasitisme de la matrice unguéale dans la leishmaniose générale du chien. *Bull. Soc. Path. Exot.*, 31 :483-487.
- LOPES, V.G.; MOMEN, H.; GRIMALDI JR., G.; MARZOCHI, M.C.A.; PACHECO, R.S. & MOREL, C.M., 1984. Schizodeme and zymodeme characterization of *Leishmania* in the investigation of foci of visceral and cutaneous leishmaniasis. *J. Parasitol.*, 70 (1) :89-98.
- MAGALHÃES, P.A.; MAYRINK, W.; DA COSTA, C.A.; MELO, N.M.; DIAS, M.; BATISTA, S.M.; MICHALICK, M.S.M. & WILLIAMS, P., 1980. Calazar na zona do Rio Doce – Minas Gerais. Resultado das medidas profiláticas. *Rev. Inst. Med. trop. São Paulo*, 22 :197-202.
- MALAMOS, B., 1947. Leishmaniasis in Greece. *Trop. Dis. Bul.*, 44 :1-7.
- MARZOCHI, M.C.A.; COUTINHO, S.G.; SOUZA, W.J.S. & AMENDOEIRA, M.R.R., 1981b. Leishmaniose visceral – Calazar. *J. Bras. Med.*, 41 :69-84.
- MARZOCHI, M.C.A.; GRIMALDI JR., G.; MOMEN, H. & McMAHON-PRATT, D., 1983. Visceral *Leishmania braziliensis braziliensis* in a dog in Rio de Janeiro (Brazil). *X Reunião Anual de Pesquisa Básica em Doença de Chagas, Caxambu – Brazil, Abstract, BI-30, p. 3-15.*
- MARZOCHI, M.C.A.; SABROZA, P.C.; TOLEDO, L.M.; MARZOCHI, K.F.B.; TRAMONTANO, N.C. & RANGEL, F., 1985. Leishmaniose visceral na cidade do Rio de Janeiro. *Cad. Saúde Públ. Rio de Janeiro*, 1 :5-17.
- MARZOCHI, M.C.A.; SOUZA, W.J.S.; COUTINHO, S.G.; GRIMALDI JR., G. & MOMEN, H., 1981a. Leishmaniose visceral no Rio de Janeiro. I – Infecção canina em áreas de procedência de casos humanos autóctones. Cepas isoladas. *VI Congresso Brasileiro de Parasitologia, Belo Horizonte, Brazil, p. 73.*
- MARZOCHI, M.C.A.; SOUZA, W.J.S.; COUTINHO, S.G.; TOLEDO, L.M.; GRIMALDI JR., G. & MOMEN, H., 1982. Evaluation of diagnostic criteria in human and canine mucocutaneous leishmaniasis in a Rio de Janeiro district where *Leishmania braziliensis braziliensis* occurs. *IX Reunião de Pesquisa Básica em Doença de Chagas, Caxambu – Brazil. Abstract 46, p. 63.*
- McMAHON-PRATT, D.; JAFFE, C.L. & GRIMALDI JR, G., 1984. Application of monoclonal antibodies to the classification of *Leishmania* species. In: Morel, C.M., ed. "Genes and Antigens of parasites. A laboratory Manual". 2nd Edit. UNDP/WORLD BANK/WHO Special Programme for Research and Training in Tropical Diseases FINEP/CNPq/FIOCRUZ, Fundação Oswaldo Cruz, Rio de Janeiro, Brazil, pp. 121-135.
- MOMEN, H.; GRIMALDI JR., G. & MARZOCHI, M.C.A., 1983. Identification of New World *Leishmania* isolates by agarose gel electrophoresis and polyacrylamide gel isoelectrofocusing. *J. Cell. Biochem.*, 7A, 70 :29.
- MONSUETO, S.; MICELI, M.D. & QUARTARARO, P., 1982. Counterimmunoelectrophoresis (CEIP) and ELISA test in the diagnosis of canine leishmaniasis. *Ann. Trop. Med. & Parasit.*, 76 :229-231.
- NUSSENZWEIG, U.; NUSSENZWEIG, R.G. & ALENCAR, J.E., 1957. Leishmaniose visceral canina: reação de fixação de complemento com antígeno extraído do bacilo da tuberculose. *O Hospital*, 51 :325-332.
- PACHECO, R.S.; MOMEN, H.; GRIMALDI JR., G.; MARZOCHI, M.C.A.; MOREL, C.M. & BADARÓ, R., 1984. A comparative biochemical analysis of isolates of visceral leishmaniasis from the states of Bahia and Rio de Janeiro. *Proceedings of the IV Japan-Brazil Symposium on Science and Technology, CNPq, Academia de Ciências do Estado de São Paulo, Vol. 2 :58-83.*
- PELLEGRINO, J. & BRENER, Z., 1958. Reação de fixação de complemento com sangue dessecado no diagnóstico do calazar canino. *Rev. Bras. Malariol. D. Trop.*, 10 :39-44.
- PIGOURY, L., 1938. Réviviscence de lésions cutanées ou ecthyma stibié au cours du traitement de la leishmaniose canine par les antimoniaux. *C.R. Soc. Biologie*, 127 :105-109.
- POZIO, E.; GRANDONI, L.; BETTINI, S. & GRANICIA, M., 1981. Leishmaniasis in Tuscany (Italy): VI Canine Leishmaniasis in the focus of Monte Argentario (Grosseto). *Acta Tropica*, 38 :383-393.
- RANQUE, J.M. & CABASSU, H., 1948. Le diagnostic précoce de la leishmaniose canine par la ponction ganglionnaire. Réflexions à propos de soixante examens positifs obtenus en dix mois dans la région marseillaise. *Bull. Ac. Nat. Med.*, 132 :339-341.
- RIO DE JANEIRO, 1979. Secretaria Municipal de Planejamento e Coordenação Geral. Informações básicas da cidade do Rio de Janeiro. Rio de Janeiro.
- SHERLOCK, I.A. & ALMEIDA, S.P., 1970. Notas sobre leishmaniose canina no Estado da Bahia. *Rev. Bras. Malariol. D. Trop.*, 22 :231-242.
- SOUZA, M.A.; SABROZA, P.C.; MARZOCHI, M.C.A.; COUTINHO, S.G. & SOUZA, W.J.S., 1981. Leishmaniose visceral no Rio de Janeiro. 1. Flebotomíneos da área de procedência de caso humano autóctone. *Mem. Inst. Oswaldo Cruz*, 76 :161-168.