

EXPERIMENTAL INFECTION WITH *LEISHMANIA* (*VIANNIA*) *BRAZILIENSIS*  
AND *LEISHMANIA* (*LEISHMANIA*) *AMAZONENSIS* IN THE MARMOSET,  
*CALLITHRIX PENICILLATA* (PRIMATES: CALLITHRICIDAE)

CÉSAR A. CUBA CUBA; VERA FERREIRA; MARIA BAMPI; ALBINO MAGALHÃES;  
PHILIP D. MARSDEN; ALEJANDRO VEXENAT; MILTON THIAGO DE MELLO

Laboratório de Parasitologia, Faculdade de Ciências da Saúde, Universidade de Brasília, Núcleo de Medicina  
Tropical e Nutrição, Caixa Postal 53031, 70910 Brasília, DF, Brasil

*Fourteen marmosets (Callithrix penicillata) were inoculated intradermally with promastigotes and/or amastigotes of Leishmania (Viannia) braziliensis (L. (V) b.) strains MHOM/BR/83/LTB-300 MHOM/BR/85/LTB-12 MHOM/BR/81/LTB-179 and MHOM/BR/82/LTB-250. The evolution of subsequent lesions was studied for 15 to 75 weeks post-inoculation (PI).*

*All but 3 of the L. (V) b. injected marmosets developed a cutaneous lesion at the point of inoculation after 3 to 9 weeks, characterized by the appearance of subcutaneous nodules containing parasites. Parasites were isolated by culture (Difco Blood Agar) from all 11 positive animals. The maximum size of the lesions was variable and ranged between 37 mm<sup>2</sup> to 107 mm<sup>2</sup>. Ulceration of primary nodules became evident after 3 to 12 weeks in all infected marmosets, but was faster and larger in 5 of the 11 animals. The active lesions persisted in 9 out of 11 Callithrix until the end of the observation period, which varied from 15-75 weeks. In 3 animals spontaneous healing of their lesions (13 to 25 weeks, PI) was observed but with cryptic parasitism.*

*In another 2 infected animals there was regression followed by reactivation of the cutaneous lesions. The appearance of smaller satellite lesions adjacent to primary ones, as well as metastatic lesions to the ear lobes, were documented in 2 animals.*

*Promastigotes of L. (Leishmania) amazonensis (L. (L) a.) MHOM/BR/77/LTB-16 were inoculated in 1 marmoset. This animal remained chronically infected for 6 months and the lesion developed in a similar manner to L. (V) b. infected marmosets.*

*No significant differences in clinical and parasitological behaviour were observed between promastigote or amastigote derived infections of the 2 species. Both produced chronic, long lasting lesions which eventually healed. The same was true for parameters of size and ulceration. Skin tests converted to positive in 11 of 15 injected marmosets and in 10 of 12 parasite positive animals. Moderate levels of circulating antibodies were also observed by IFAT/IgG assays.*

*In spite of the failure to reproduce the mucosal form of the disease, an important aspect of the Callithrix model in experimental cutaneous leishmaniasis lies in the reproduction of 2 clinical events that are common in humans, namely, the chronic ulceration and spontaneous healing of the lesions.*

Key words: experimental *Leishmania* (*Viannia*) *braziliensis* infections – marmosets *Callithrix penicillata*

---

This investigation received financial support from the UNDP/World Bank/WHO-TDR, CNPq Proc. 401036/85-PIDE VI and Cornell University – Universidade de Brasília, Research Grant AI-16282-03.

Received 17 May 1990.  
Accepted 2 October 1990.

The search for new animal models for leishmaniasis has now been expanded to include various primates. *Callithrix* species seem to be useful and we have reported on *Callithrix jacchus jacchus* as an model for studies of coagulation factors in *Leishmania* (*Leishmania*) *chagasi* infections (Marsden et al., 1981).

TABLE I

Details of strains of *Leishmania* (V) *braziliensis* and *L.* (L) *amazonensis* used to study experimental infection in the marmoset, *Callithrix penicillata*

Strain code	Identification				Skin test Montenegro/ Patient lesion
	B	I	Mabs	k-DNA	
MHOM/BR/85/LTB-12 (L. (V) b.)	+	+	+	+	+/Mucosal
MHOM/BR/81/LTB-179 (L. (V) b.)	+	+	+	ND	-/Cutaneous
MHOM/BR/82/LTB-250 (L. (V) b.)	+	+	+	+	+/Cutaneous
MHOM/BR/83/LTB-300 (L. (V) b.)	+	+	+	+	-/Mucosal
MHOM/BR/77/LTB-16 (L. (L) a.)	+	+	+	ND	+/Cutaneous

B: biological (behaviour in hamster, culture and sandfly); I: isoenzymes; Mabs: monoclonal antibodies; k-DNA: hybridization; ND: not done.

Limited studies have been done on the susceptibility of non-human primates to *Leishmania* of the New World. Some species, including the rhesus, *Macaca mulatta* (Lainson & Bray, 1966), *Cebus apella apella* and squirrel monkeys, *Saimiri sciureus* (Lainson & Shaw, 1977; Pung & Khun, 1987) have varying degrees of susceptibility to *L.* (V) b. or *L.* (L) *mexicana*. The owl monkey *Aotus trivirgatus* has been shown to develop cutaneous lesions following the intradermal inoculation of both *L.* (V) *panamensis* and *L.* (L) *mexicana* (Christensen & Vásquez, 1981; Walton et al., 1983). Further studies with *A. trivirgatus* (Lujan et al., 1986), showed development of primary and satellite lesions following infection with *L.* (V) *panamensis*.

The present studies on infections with *L.* (V) b. in *C. penicillata* marmosets were made to characterize the evolution of 4 different isolates of *L.* (V) b. and 1 of *L.* (L) a. in this experimental host.

#### MATERIALS AND METHODS

*The parasites* – The strains of *Leishmania* used in the present experiments are shown in Table I. All these strains come from our study area of Três Braços, Bahia state, Brazil and are well characterized and identified by isoenzyme patterns, kinetoplast DNA and monoclonal antibody testing (Cuba et al., 1985). The strains are deposited in our cryobank as amastigotes and promastigotes.

Cultures in Schneider's *Drosophila* Medium supplemented with 20% inactivated foetal calf serum were employed for mass production of promastigotes for skin test antigen. Marmosets were inoculated intradermally with initial stationary phase promastigotes (6th day growth blood agar cultures).

Amastigotes of *L.* (V) b. from experimentally infected hamsters (*Mesocricetus auratus*) were isolated from subcutaneous non-ulcerated nodules. Smears were stained with Giemsa to find parasites and tissues were homogenised in a "Ten Broeck" tissue grinder.

*Animals* – Fifteen marmosets, 8 wild-caught and 7 reared in captivity (7 males and 8 females) weighing 185-482 g, were used in the experiments. Two other animals acted as controls. The wild marmosets were obtained from Felixlândia, Minas Gerais State, Brazil and adapted to laboratory conditions for at least 2 to 3 months before inoculation.

The monkeys were housed in aluminium cages, each containing 2 animals at room temperature ( $24^{\circ} \pm 2^{\circ}\text{C}$ ) and relative humidity 55%. They were fed with daily diets (Wirth & Buselmaier, 1982; Pereira et al., 1984) complemented with vitamins A, B complex, C and D<sub>3</sub> twice a week.

The marmosets were anaesthetised with 25 mg/kg/body weight of intramuscular Vetalar (Ketamine HCl, Parke Davis, USA). The hair

TABLE II

Details of experimental inoculations of *Callithrix penicillata* with *Leishmania* strains: host characteristics, dose inocula and inoculation sites

Experiment No.	No. of animals	Weight range	<i>Callithrix</i> <sup>a</sup> No.	Sex	Infecting strain of <i>Leishmania</i>	No. of organisms per inoculum/inoculation sites
1	4	185-385g	05	♂	MHOM/BR/83/LTB-300 (L(V)b) <sup>b</sup>	Amastigote (A) <sup>c</sup>
			06	♀	MHOM/BR/83/LTB-300	Amastigote (A)
			15	♂	MHOM/BR/85/LTB-12 (L(V)b)	Amastigote (A)
			16	♂	MHOM/BR/85/LTB-12	Amastigote (A)
2	8	220-350g	03	♀	MHOM/BR/83/LTB-300	P, 5x10 <sup>6</sup> /L.E.; (A) - R.E.
			42*	♂	MHOM/BR/83/LTB-300	P, 5x10 <sup>6</sup> /L.E.; (A) - R.E.
			47*	♀	MHOM/BR/82/LTB-250 (L(V)b)	P, 5x10 <sup>6</sup> /L.E.; (A) - R.E.
			48*	♀	MHOM/BR/82/LTB-250	P, 5x10 <sup>6</sup> /L.E.; (A) - R.E.
			44*	♀	MHOM/BR/81/LTB-179 (L(V)b)	P, 5x10 <sup>6</sup> /L.E.; (A) - R.E.
			46*	♂	MHOM/BR/81/LTB-179	P, 5x10 <sup>6</sup> /L.E.; (A) - R.E.
			12	♀	MHOM/BR/85/LTB-12 (L(V)b)	P, 5x10 <sup>6</sup> /L.E.; (A) - R.E.
14	♀	MHOM/BR/85/LTB-12	P, 5x10 <sup>6</sup> /L.E.; (A) - R.E.			
3	3	383-482g	100	♀	MHOM/BR/83/LTB-300	P, 5x10 <sup>5</sup> /L.E.; R.E.; B.T.
			101*	♂	MHOM/BR/81/LTB-179	P, 5x10 <sup>5</sup> /L.E.; R.E.; B.T.
			102*	♂	MHOM/BR/77/LTB-16(L(L)a)	P, 5x10 <sup>5</sup> /L.E.; R.E.; B.T.

a: specimens conceived, born and reared in captivity; \* = sylvatic specimens trapped in localities in Minas Gerais State.

b: L(V)b, *Leishmania* (Viannia) *braziliensis*; L(L)a, *Leishmania* (*Leishmania*) *amazonensis*.

c: (A) Triturated tissues from infected *Mesocricetus auratus*; parasites not counted; P = Promastigotes from 6 days Blood Agar cultures; L.E. = left ear; R. E. = right ear; B.T. = base of tail.

was removed from the area over the base of the tail before infection and there after weekly. The other inoculation sites of the ear and nose were not shaved. Prior to inoculation with *Leishmania* all marmosets were skin tested with leishmanin antigen (a suspension of 3 x 10<sup>6</sup> promastigotes of L. (V) b./ml.) on the abdomen and sera tested with IFAT/IgG (Antimonkey conjugate, Cappel Labs).

Table II shows the experimental schedules of *Callithrix* infection. As shown, the marmosets were divided in 3 groups and inoculated at different sites and with different types of inocula. Groups 2 and 3 received 0.1 ml promastigotes suspension adjusted to 5 x 10<sup>6</sup>/cell and 5 x 10<sup>5</sup> cells. The amastigote inoculum consisted of a suspension of tissues containing an unknown number of parasites.

Simultaneously, individual hamsters were inoculated into the dorsal surface of the hind feet with the same dose as a control of infectivity. Two control hamsters received culture medium alone. Clinical (weekly) and parasitological (every 2 weeks) observations were recorded. Lesions (nodules and ulcers) were evaluated by measuring the major and minor

diameters with the aid of a manostat Swiss calliper. The area was calculated using the formula:  $A = \pi R_1 \cdot R_2$  (Wilson et al., 1979).

The presence of parasites in suspected lesions was confirmed by the culture of needle aspirates in Difco Blood Agar Medium (3 tubes per lesion). The tubes were examined for the presence of *Leishmania* promastigotes every 3 days for a month.

Blood was drawn from the femoral vein and was allowed to clot before centrifugation at 1000 x g for 15 min, and the serum collected. Parasite specific IgG was measured with an indirect immunofluorescence technique (IFAT/IgG) using promastigote or amastigote antigen. Goat anti-monkey IgG fluorescein conjugate (Cappel, Cooper Biomedical, USA) was employed at a dilution of 1:40.

At intervals, skin tests were made with leishmanin antigen. The efficacy of the leishmanial antigen was checked by observing the skin-test reaction of infected patients at our hospital. The marmoset skin reactions were measured at 48-72 h after injection. A diameter of induration of  $\geq 5$  mm regarded as positive.



TABLE III

Evolution of lesions due to experimental infection of *Callithrix penicillata* with *Leishmania* (*Viannia*) *braziliensis* and *L.* (*Leishmania*) *amazonensis* and details of clinical and parasitological findings

<i>Callithrix</i> No.	Incubation <sup>a</sup> period	Parasites <sup>b</sup> in lesions	Skin test <sup>c</sup> (weeks P.I.)	Maximum size of lesion (weeks P.I.)	Ulceration mm <sup>2</sup> , V (weeks P.I.)	Regression of cutaneous lesions: self-healing (weeks)
C-05	4-5	+	+(10)	63 mm <sup>2</sup> (8)	3.1 (8)	15-37
C-06	4	+	+(10)	50 mm <sup>2</sup> (11)	Mc (11)	13
C-15	—	—	—	—	—	—
C-16	—	—	—	—	—	—
C-03	7	+	+(4)	23 mm <sup>2</sup> (10)	Mc (16)	19-23-25
C-42	4	+	+(4)	53 mm <sup>2</sup> (19)	2 (3); 12.5 (17)	—
C-47	7	+	+(10)	39 mm <sup>2</sup> (10)	15.8 (10) V	24 (amastigote) D
C-48	3	+	—	37 mm <sup>2</sup> (7)	21.9 (7) V	12 D
C-44	9	+	+(4)	107 mm <sup>2</sup> (19)	0.8 (10)	—
C-46	7	+	+(10)	63 mm <sup>2</sup> (22)	56.5 (10) V	14 (promastigote)
C-12	—	—	+(4)	—	—	—
C-14	9	+	+(10)	29 mm <sup>2</sup> (11)	1.7 (17)	25
C-100	5	+	+(9)	63 mm <sup>2</sup> (14)	12.5 (10); 23.7 (11) V	—
C-101	5	+	+(26)	29 mm <sup>2</sup> (18)	4.9 (9); 15.8 (11)	—
C-102	7	+	—	17 mm <sup>2</sup> (15)	13.1 (12) V	23 (tail remained active)

a: weeks post-infection; b: culture; c: time when Montenegro skin test converted to positive; V: virulent; Mc: micro-ulceration; D: died under anaesthesia.

## RESULTS

Eleven of the 14 marmosets inoculated with 4 different strains of *L.* (V) b. developed skin lesions both with promastigote or amastigote inocula (Table III). Marmosets C-12 (promastigotes), C-15 and C-16 (amastigotes) did not develop skin lesions although control hamsters developed parasite positive lesions. Marmoset C-12 inoculated with promastigotes, demonstrated skin-test positivity and showed circulating antibodies in spite of failure to develop a clinical lesion. In a single marmoset (C-102) *L.* (L) a. promastigotes produced well developed lesions.

Two developmental patterns were noted after intradermal inoculation: A) *Persistent chronic skin lesions* (Figs 1A, 1B) — Both inocula produced long lasting ulcerative skin lesions in 8 animals, which still persisted at the end of the experimental observation (25-75 weeks post-inoculation); B) *Self-healing skin lesions* (Figs 2A, 2B) — These occurred in 3 marmosets (C-06, C-14 and C-46) infected with *L.* (V) b. strains. The macroscopic aspect of the initial lesions was similar to pattern A but the lesions gradually decreased in size, became covered with a crust, formed scabs and then healed leaving typical scars. When this happened was variable (13, 15 and 25 weeks, P. I.). In the marmosets healing at 14th and 15th weeks,

living parasites were recovered after lesion closure and scar formation, demonstrating parasite persistence.

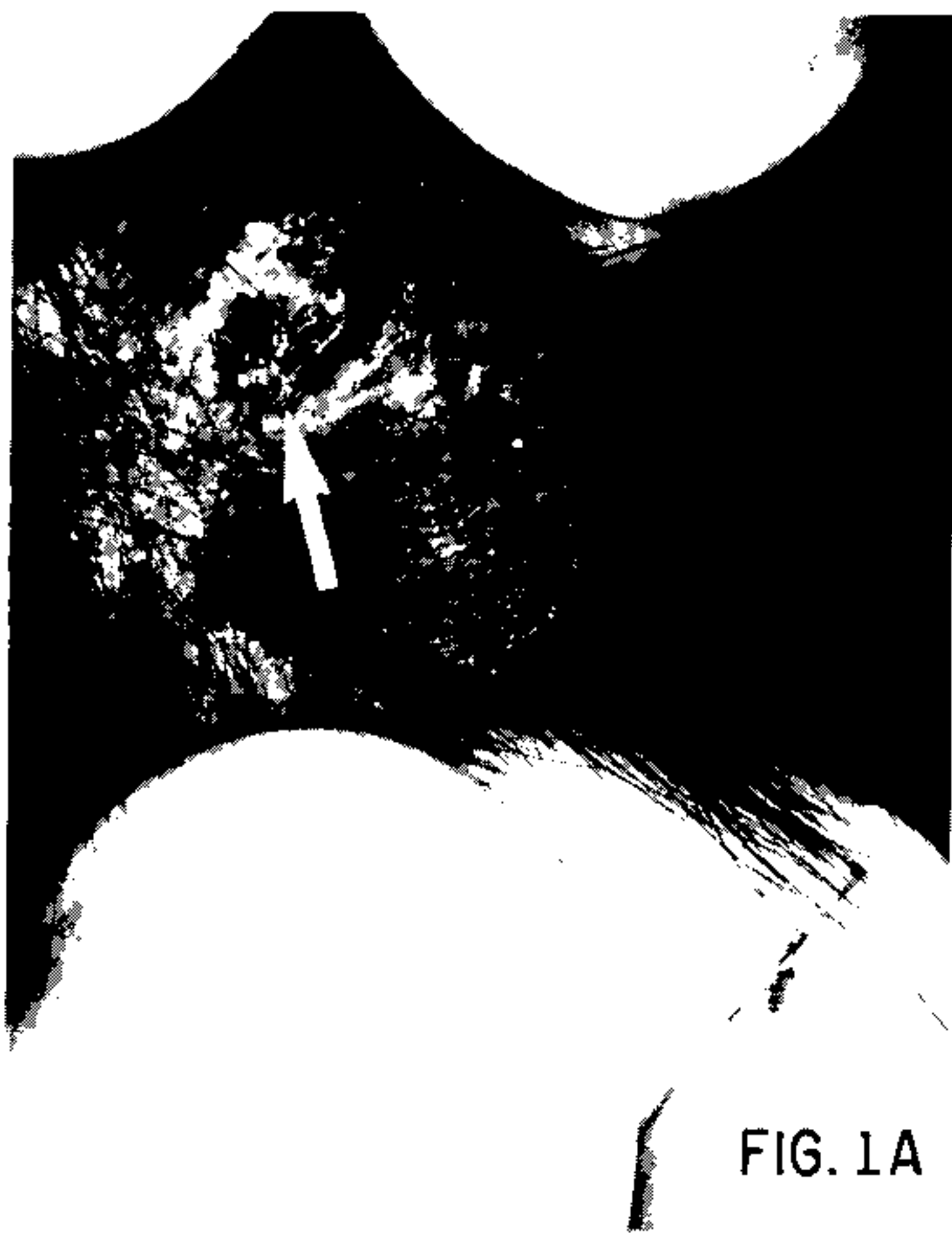

Fig. 1A: marmoset C-46. A 23 week old chronic lesion (arrow) due to aurally inoculated *Leishmania* (*V*) *braziliensis* amastigotes.

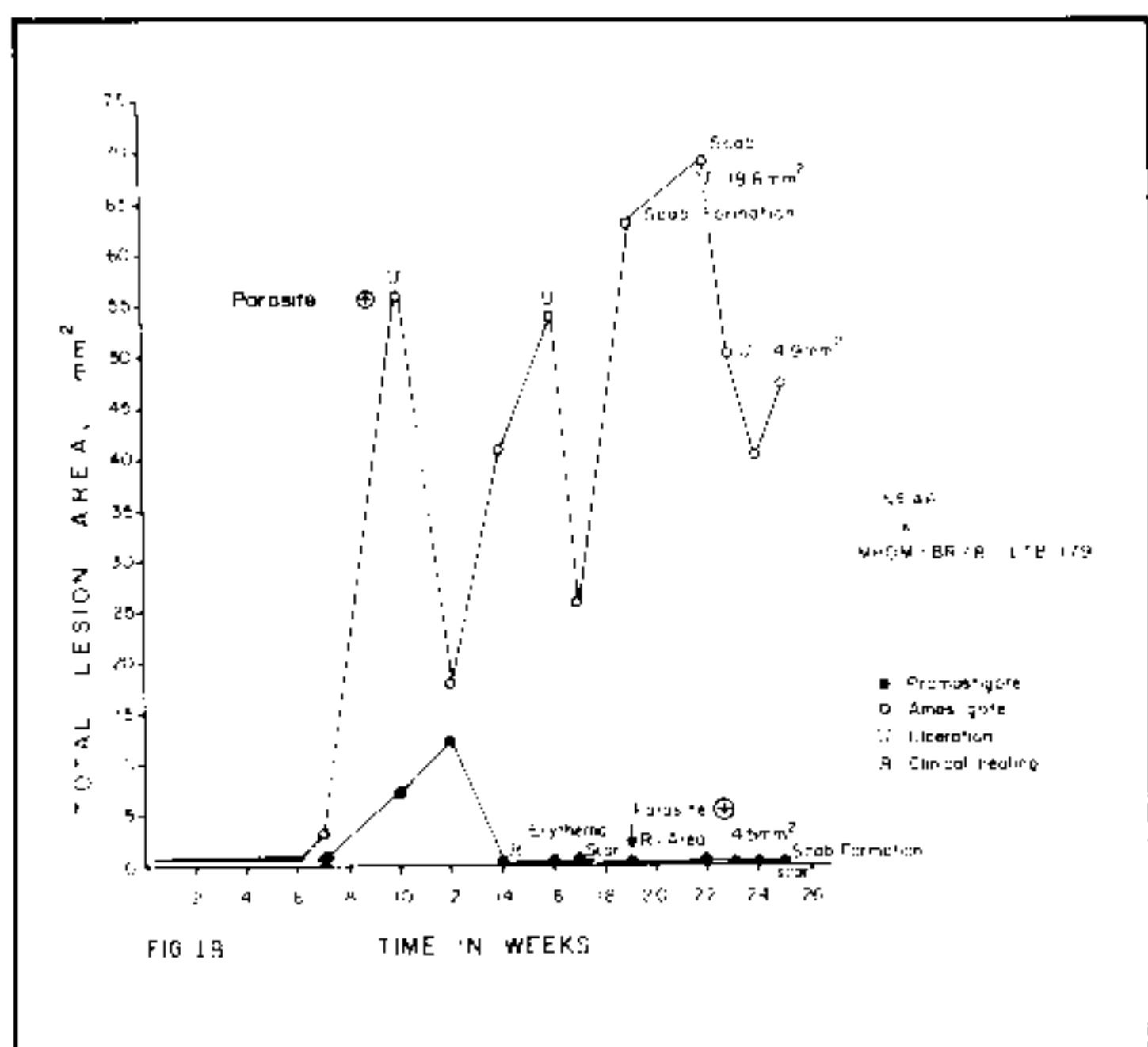


Fig. 1B: total area of cutaneous lesions produced by amastigotes (left ear) and promastigotes (right ear) of *Leishmania (V) braziliensis*. The arrow indicates a parasite-positive culture from a healed lesion.

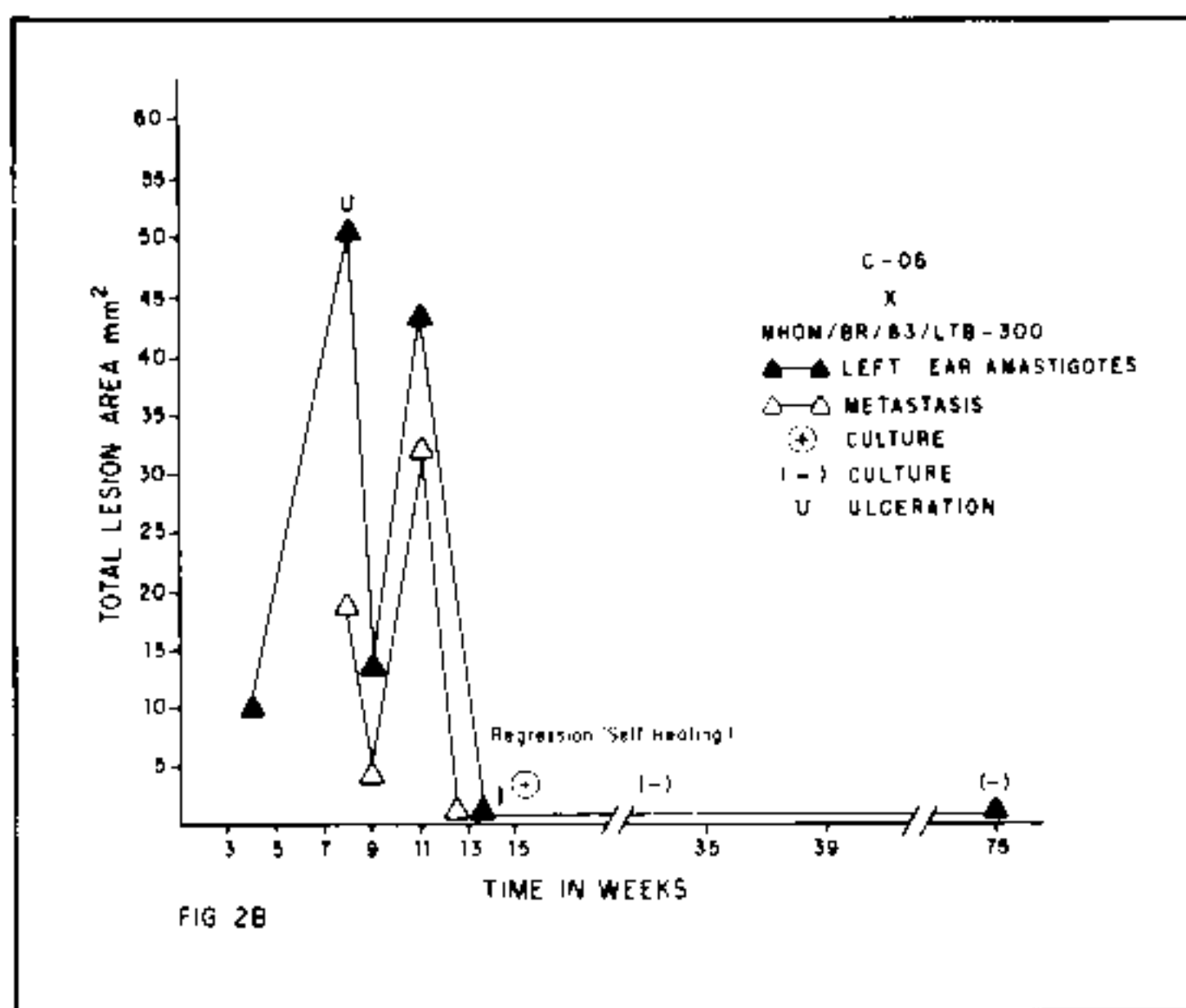


Fig. 2B: marmoset C-06. Total area of cutaneous lesions produced by aural inoculation of *Leishmania (V) braziliensis* amastigotes.

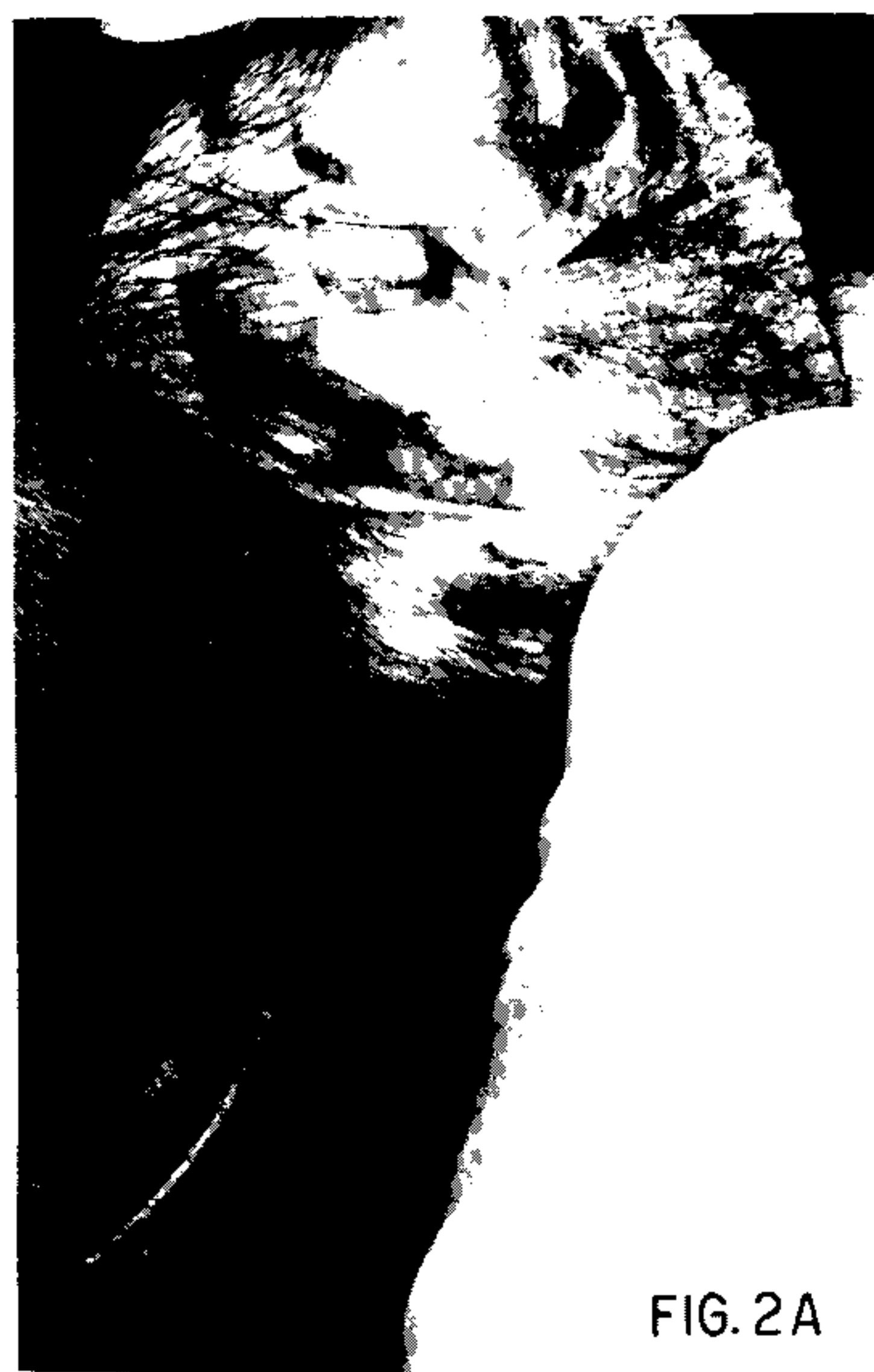

FIG. 2A

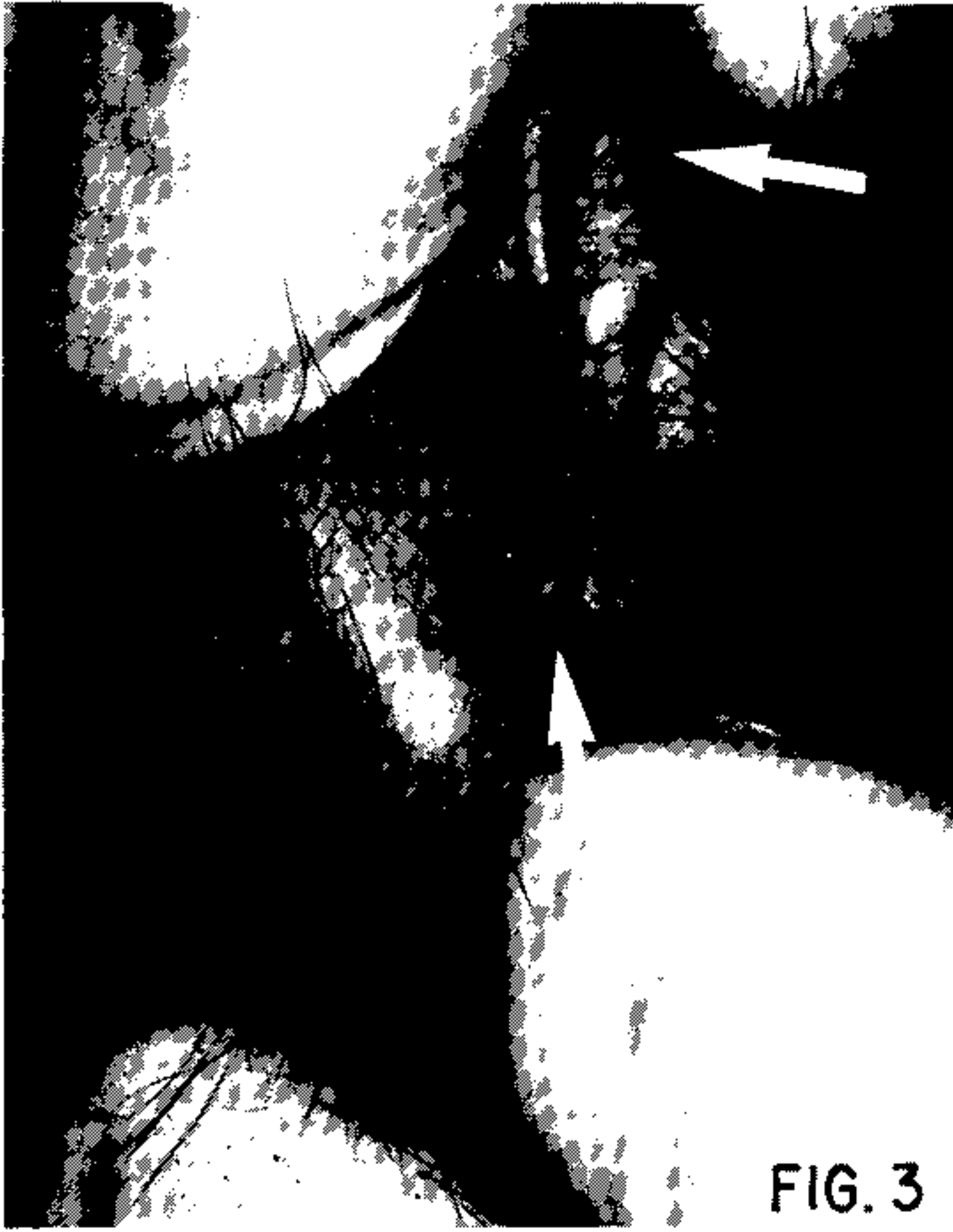Fig. 2A: marmoset C-46. Self-healing lesion (arrow) 14 weeks after aural inoculation of *Leishmania (V) braziliensis* promastigotes.

Marmosets were regarded as recovered on complete disappearance of the skin lesion and failure to isolate parasites at the site of primary lesion, in Difco Blood Agar, carried out on 4 different occasions. Patterns of the infection did not seem to depend on the type of inoculum used.

Table III shows the lesion characteristics after infection of the marmosets with the different strains and types of inocula. No signs of visceralization were seen in 2 dead marmosets C-47 and C-48 examined by smears and cultures (accidental deaths from anaesthesia at 48th and 12th weeks P. I.). The average incubation period for lesions was 5.9 weeks P. I. (range: 3 to 9 weeks). For amastigote inoculum the incubation period was 8.3 weeks, and for promastigote, 7.4 weeks.

The average (maximum) size of the lesions observed in all 12 infected marmosets was 47.7 mm<sup>2</sup> (range: 17-107; 39.1 mm<sup>2</sup>, for amastigotes and 19.5 mm<sup>2</sup>, for promastigotes). The average time to achieve maximum size was, amastigote – produced lesions 13.3 weeks (range: 8-22 weeks P.I.), promastigote – produced lesions 14.7 weeks (range: 7-24).

Satellite, metastatic skin lesions on the ear lobe and ear pinna were seen following both promastigote and amastigote inoculum in marmosets C-06, C-42 and C-48 (at 11,9 and 7 weeks P. I., respectively), but only on the ear pinna of C-03 inoculated with promastigotes (Fig. 3).



**FIG. 3**

Fig. 3: marmoset C-06. Metastatic cutaneous lesion on the pinna, 11 weeks after amastigote inoculation with *Leishmania (V) braziliensis*.

Ulceration was a constant feature in all of the infected animals. Within 7 to 24 weeks, the lesions (nodules) had ulcerated, forming a oval lesion with raised borders and central ulceration.

All lesions had positive cultures when sampled via needle aspiration. Recovered promastigotes were cryopreserved.

Strains MHOM/BR/83LTB-300, MHOM/BR/82/LTB-250, MHOM/BR/81/LTB-179 and MHOM/BR/77LTB-16 seem to be more virulent in terms of their short incubation period, larger lesions and ulceration (Table III).

Histological sections of a 9-week active lesion (marmoset C-48) showed a cellular infiltrative exudate formed of lymphocytes, histiocytes and plasma cells. This infiltrate was found close to the cartilage of the ear pinna. A small number of parasites were seen inside histiocytic phagosomal vacuoles. The histological picture above was similar to the basic reaction observed in human skin leishmaniasis and could be classified as an exudative cellular reaction.

The histopathological appearance of self-healing lesions (marmoset C-48) showed an histiocytic-lymphocytic infiltration of the scar, with some mixed plasma cells and polymorphs. Both connective tissue and vessels showed proliferation. The ear cartilage was not invaded. Epidermal tissues were preserved. No parasites were found in tissue sections. The above histological picture was comparable to human self-healing lesions of *L. (V) b.*

None of the *L. (V) b.* infected animals, nor the single marmoset infected with *L. (L) a.*, developed mucosal metastatic lesions during the observation period (15-75 weeks P. I.). Two animals (C-05 and C-03) showed reactivation of their lesions at 20 and 22 weeks after healing.

*Skin test assays* — Prior to experimental infection all marmosets were negative to an intradermal test with *L. (V) b.* antigen. The skin test converted in 11 of the 15 marmosets and in 10 of 12 who showed parasites. The test was positive 4 weeks after inoculation of *Leishmania* in 4 animals, including the C-12 marmoset without a lesion. Most of the animals developed delayed hypersensitivity reactions 10 weeks post-inoculum. Decreased reactivity was observed in 1 animal (C-06) at 79 weeks post-inoculum (Table III).

*Circulating antibodies* (IFAT IgG) Were demonstrated in the marmosets between 5 and 22 weeks after inoculation. Titres varied from 1:20 to 1:320 and remained positive both during the active phase and 24 weeks after spontaneous resolution of lesions (Figs 4A and 4B). The single marmoset infected with *L. (L) a.* showed positive titres (1:40 or 1:60) 8 weeks post-infection.

## DISCUSSION

The present work demonstrates that *C. penicillata* is susceptible to experimental infection with diverse strains of *L. (V) b.* and to one strain of *L. (L) a.* and serves as a useful experimental model for the study of cutaneous leishmaniasis.

Both amastigote and promastigote stages were infective for the marmosets but, as established by Sacks & Perkins (1985), stationary phase culture promastigote inocula were more effective.



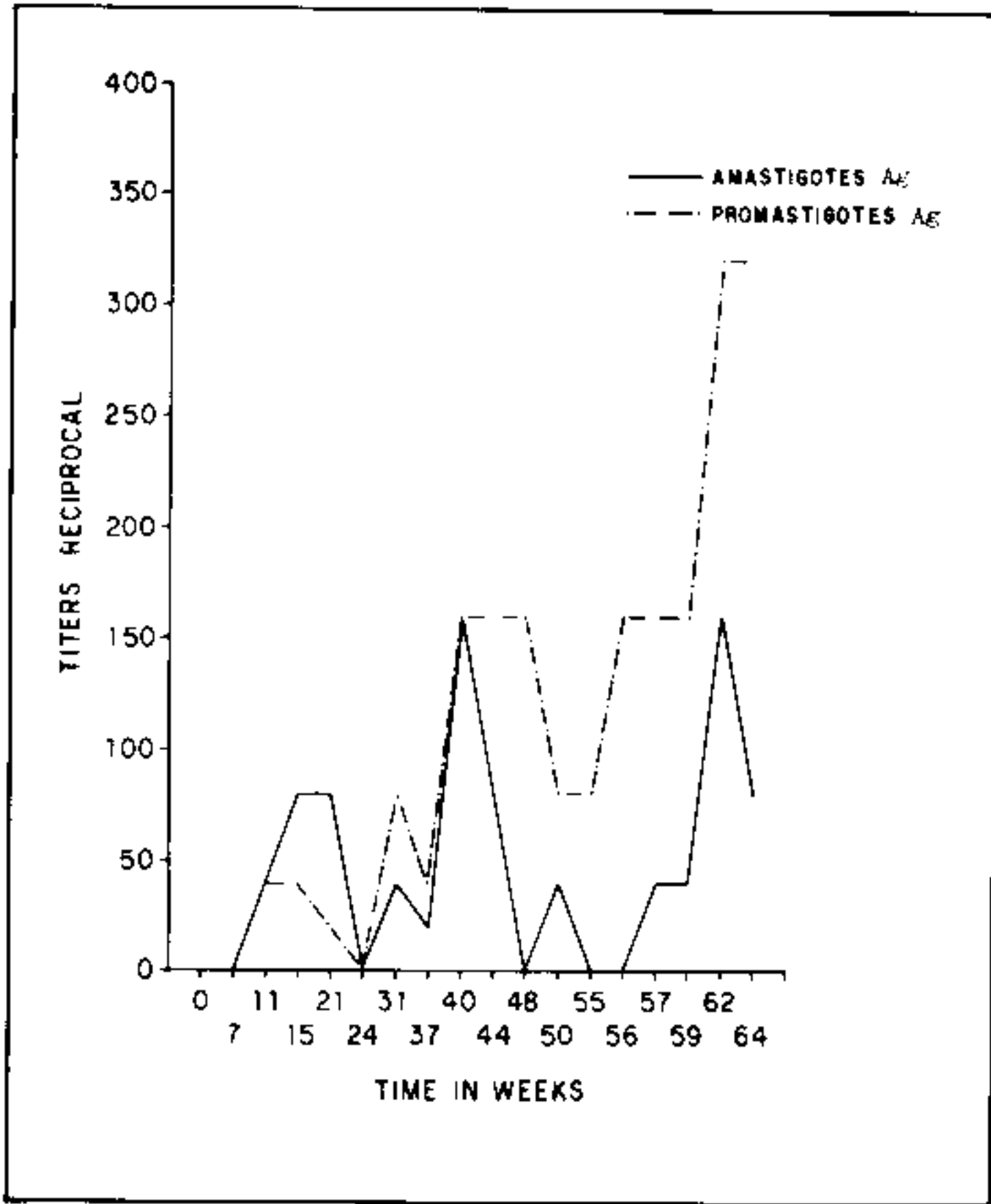


Fig. 4A: serological profile of antibody titres by Indirect Immunofluorescence antibody assay (IFAT/IgG) in *Callithrix penicillata* infected with *Leishmania (V) braziliensis* Marmoset C-44).

Variation observed in the clinical course of infection could be due to differences of strain virulence. It is well established that the genetic condition of the host exerts a profound influence on both susceptibility to *Leishmania* and the outcome of the infection (Howard, 1985). Thus, if genetically inbred mice are used, their response is so uniform that the severity and profile of the infection induced are reproducible characteristics of each parasite/host/strain combination (Bradley, 1982).

Marked variation in the outcome of the disease was observed when outbred mice and different rodent species were examined for susceptibility to *L. (V) panamensis* (Childs et al., 1984).

The experiments recorded here show two clinical patterns of disease in *C. penicillata*: namely A) a self-healing cutaneous leishmaniasis, with complete resolution of the lesions and B) chronic ulcerative lesions. Both patterns are comparable to the clinical human situation extensively documented in man (Llanos Cuentas et al., 1984; Jones et al., 1987).

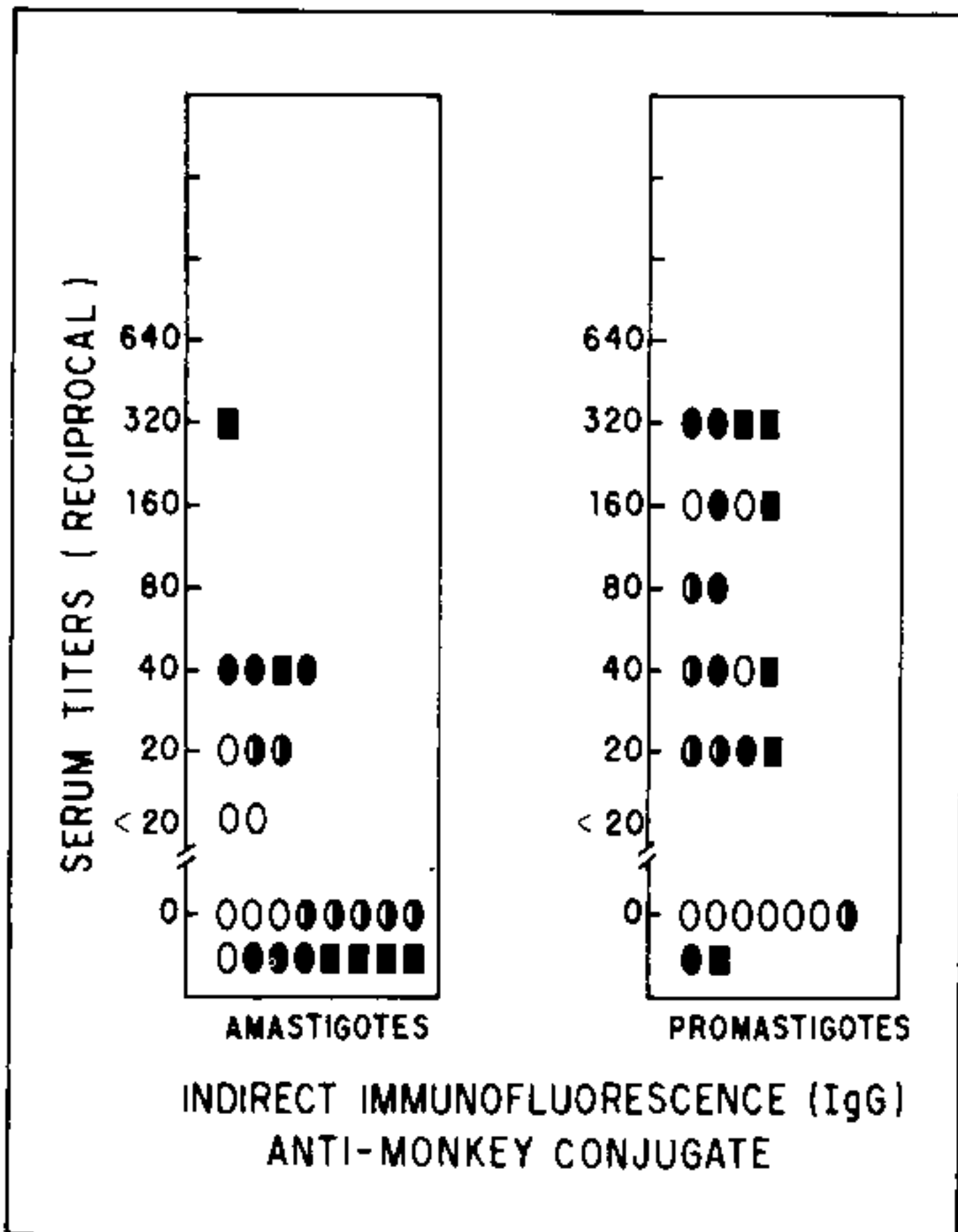


Fig. 4B: antibody response of *Callithrix penicillata* infected with *Leishmania (V) braziliensis*. Infection times: O = 5 weeks; ● = 9 weeks; ◐ = 12 weeks; ■ = 22 weeks; all animals IFAT negatives prior infection by *L. (V) b.*

A self-healing phenomenon in marmosets is indicative of the development of an acquired immunity. Our field clinic observations have shown eventual self-cure in 22 patients infected with *L. (V) b.* who received no specific treatment (Costa et al., 1987).

As described by Lujan et al. (1986), in the owl monkey *A. trivirgatus*, satellite lesions developed adjacent to the primary ear pinna lesions in our experimental marmosets. Metastatic spread to the ear lobes was seen in 2 marmosets infected with *L. (V) b.* This is unlike the situation in man.

The histology of the lesions in this model were similar to human cutaneous lesions (Magalhães et al., 1986). As in patients, the course of the infection was over a variable time scale; 2 marmosets (C-03 and C-05) showed relapses and lesion reactivation (25-37 weeks post-inoculation). In a recent paper we showed that, over 4 years, mucosal relapse only occurred in 3% of infected patients (Netto et al., 1990).

Mucosal disease was not observed in the infected animals but the period of study is very short.

Ulceration in infected marmosets has been a common feature after L. (V) b. and L. (L) a. infection. Curiously, the same strain (MHOM/BR/83/LTB-300) used in our experiments did not cause ulcerated lesions in the squirrel monkey *S. sciureus* model as studied by Pung & Kuhn (1987).

No systemic infection with L. (V) b. was observed in one actively infected marmoset and other recovered monkey, both of which died under the anaesthetic (12th and 48th weeks P. I., respectively).

Infection of *C. penicillata* with a L. (L) a. strain followed a similar clinical pattern to that of L. (V) b. infected marmosets. This infection may produce a non-healing ulcerated lesion or a self-resolving ulcer. No metastasis to other parts of the integument were noted.

Observations on *C. penicillata* suggest that this animal could be an appropriate model for cutaneous leishmaniasis because humoral and cellular immunity are elicited. The appearance of circulating antibody has an evolutionary curve similar to that seen in man (Jones et al., 1987). The persistence of long lasting, significant titres of antibodies in marmosets which have healed lesions has been documented in this model (Netto, et al., 1987).

The delayed hypersensitivity skin reaction evoked with leishmanial antigen showed a pattern similar to human skin-test response behaviour. However, most of the positive reactions were demonstrated 10 weeks after infection of the marmosets, i. e. somewhat longer than in man.

#### REFERENCES

- BRADLEY, D. J., 1982. Genetics of resistance to infection with special reference to Leishmaniasis. *Trans. R. Soc. Trop. Med. Hyg.*, 76: 143-146.
- CHILDS, G. E.; LIGHTNER, L. K.; Mc KINNEY, L.; GROVES, M. G.; PRICE, E. E. & HENDRICKS, L., 1984. Inbred mice as models for cutaneous Leishmaniasis. I. Resistance and susceptibility to infection with *Leishmania braziliensis*, *L. mexicana* and *L. aethiops*. *Ann. Trop. Med. Parasitol.*, 78: 25-34.
- CHRISTENSEN, A. & VASQUEZ, 1981. Susceptibility of *Aotus trivirgatus* to *Leishmania braziliensis* and *L. mexicana*. *Am. J. Trop. Med. Hyg.*, 30: 54-56.
- COSTA, J. M. L.; NETTO, E. M.; VALE, C.; OSAKI, N. K.; TADA, M. S. & MARSDEN, P. D., 1987. Spontaneous healing of cutaneous *Leishmania braziliensis braziliensis* ulcers. *Trans. R. Soc. Trop. Med. Hyg.*, 81: 606-609.
- CUBA CUBA, C. A.; BARRETO, A. C. & MARSDEN, P. D., 1984. *Leishmania mexicana*: aspectos taxonómicos y rareza de la infección humana en Três Braços, Bahia, Brasil. *Rev. Soc. Brasil. Med. Trop.*, 17: 115-122.
- CUBA CUBA, C. A.; MILES, M. A.; VEXENAT, A.; BARKER, D. C.; Mc MAHON PRATT, D.; BUTCHER, J.; BARRETO, A. C. & MARSDEN, P. D., 1985. A focus of mucocutaneous leishmaniasis in Três Braços, Bahia, Brazil: characterization and identification of leishmanial stocks isolated from man and dogs. *Trans. R. Soc. Trop. Med. Hyg.*, 79: 500-507.
- HOWARD, J. G., 1985. Host immunity to Leishmaniasis, p 139-160. In Chang & Bray (eds), *Leishmaniasis*. Elsevier Science Publishers B. V. Biomedical Division. Vol 1, New York.
- JONES, T. C.; JOHNSON, W. D.; BARRETO, A. C.; LAGO, E.; BADARO, R.; CERF, B.; REED, S. G.; NETTO, E. M.; TADA, M. S.; FRANÇA, F.; WIESE, K.; GOLIGHTLY, L.; FIKRIG, F.; COSTA, J. L. M.; CUBA CUBA, C. & MARSDEN, P. D., 1987. Epidemiology of American Cutaneous Leishmaniasis due to *Leishmania braziliensis braziliensis*. *J. Infect. Dis.*, 156: 73-83.
- LAINSON, R. & BRAY, R. S., 1966. Studies on the immunology and serology of leishmaniasis. II. Cross-immunity experiments among different forms of American Cutaneous Leishmaniasis in monkeys. *Trans. R. Soc. Trop. Med. Hyg.*, 60: 526-532.
- LAINSON, R. & SHAW, J. J., 1977. Leishmaniasis in Brazil: XII. Observations on cross-immunity in monkeys and man infected with *Leishmania mexicana mexicana*, *L. m. amazonensis*, *L. braziliensis* *L. (b) guyanensis* and *L. (b) panamensis*. *J. Trop. Med. Hyg.*, 80: 29-35.
- LLANOS CUENTAS, E. A.; MARSDEN, P. D.; LAGO, L.; BARRETO, A. C. & CUBA CUBA, C. A., 1984. Human mucocutaneous leishmaniasis in Três Braços, Bahia, Brazil, an area of *Leishmania braziliensis braziliensis* transmission. II. Cutaneous disease: presentation and evolution. *Rev. Soc. Brasil. Med. Trop.*, 17: 169-177.
- LUJAN, R.; CHAPMAN, W. L.; HANSON, L. & DENNIS, V. A., 1986. *Leishmania braziliensis*: development of primary and satellite lesions in the experimentally infected owl monkey *Aotus trivirgatus*. *Exp. Parasitol.*, 61: 348-358.
- MAGALHÃES, A. V.; MORAES, M. A. P.; RAICK, A. N.; LLANOS CUENTAS, A.; COSTA, J. M. L., CUBA CUBA, C. & MARSDEN, P. D., 1986. Histopatologia da leishmaniose tegumentar por *Leishmania braziliensis braziliensis* IV. Classificação histopatológica. *Rev. Inst. Med. Trop. São Paulo*, 28: 421-430.
- MARSDEN, P. D.; CUBA, C. C.; VEXENAT, A.; COSTA E SILVA, M.; COSTA E SILVA, A. & BARRETO, A. C., 1981. Experimental *Leishmania chagasi* infections in the marmoset *Callithrix jacchus jacchus*. *Trans. R. Soc. Trop. Med. Hyg.*, 75: 314-315.
- NETTO, E. M.; BADARO, R.; CUBA, C. C.; JONES, T. C.; JOHNSON, W. D.; ORGE, M. G. & MARSDEN, P. D., 1987. The predictive value of persistence of IgG antibody to develop mucosal leishma-



- niasis: A prospective study in Três Braços, Bahia, Brazil. *Mem. Inst. Oswaldo Cruz*, Rio de Janeiro, 82 Suppl. I, p. 163.
- NETTO, E. M.; MARSDEN, P. D.; LLANOS, CUENTAS, E. A.; COSTA, J. M. L.; CUBA, C. C.; BARRETO, A. C.; BADARO, R.; JOHNSON, W. D. & JONES, T. C., 1990. Long-term follow-up of patients with *Leishmania* (Viannia) *braziliensis* infection and treated with Glucantime. *Trans. R. Soc. Trop. Med. Hyg.*, 84: 367-370.
- PEREIRA, L. H.; MELO, A. L. & RESENDE, D. M., 1984. Alimentação de sagüis em cativeiro. Emprego de gelatina como veículo para a administração de alimentos polivitamínicos e medicamentos. *Abstracts XI Congresso Brasileiro de Zoologia*, Belém, Pará, p. 391-392.
- PUNG, O. J. & KUHN, R. E., 1987. Experimental leishmaniasis in the brazilian squirrel monkey (*Saimiri sciureus*) lesions, hematology, cellular and humoral immune responses *J. Med. Primatology*, 16: 165-174.
- SACKS, D. L. & PERKINS, P. V., 1985. Development of infective stage *Leishmania* promastigotes within phlebotomine sandflies: *Am. J. Trop. Med. Hyg.*, 34: 456-459.
- WALTON, B. C.; HARPER, J. & NEAL, R., 1983. Effectiveness of allopurinol against *Leishmania braziliensis panamensis* in *Aotus trivirgatus*. *Am. J. Trop. Med. Hyg.*, 32: 46-50.
- WILSON, H. R.; DIECKMANN, B. S. & CHILDS, G. E., 1979. *Leishmania braziliensis* and *Leishmania mexicana*. Experimental cutaneous infections in golden hamsters. *Exp. Parasitol.*, 47: 270-283.
- WIRTH, H. & BUSELMAIER, W., 1982. Long-term experiments with a newly developed standardized diet for the New World primates *Callithrix jacchus* and *Callithrix jacchus penicillata* marmosets. *Laboratory Animals.*, 16: 175-181.