

RESEARCH NOTE

Intestinal Parasites of Some Diarrhoeic HIV-Seropositive Individuals in North Brazil, with Particular Reference to *Isoospora belli* Wenyon, 1923 and *Dientamoeba fragilis* Jepps & Dobell, 1918

Ralph Lainson/⁺, Beatriz AM da Silva/*

Seção de Parasitologia, Instituto Evandro Chagas, Av. Almirante Barroso 492, 66090-000 Belém, PA, Brasil

*Unidade de Referência-Aids, Secretaria Estadual de Saúde Pública, Rua Barão de Mamoré 271, Belém, PA, Brasil

Key words: *Isoospora belli* - *Dientamoeba fragilis* - *Cryptosporidium* - HIV seropositives - Pará - Brazil

Faecal samples were examined from 34 adult HIV-seropositive individuals suffering from persistent diarrhoea in Belém, Pará, north Brazil. They were screened using a combination of direct microscopic examination (with and without Lugol's iodine), bright-field and phase-contrast microscopy of zinc sulphate flotation concentrates, and Giemsa-stained faecal smears.

Of the protozoal parasites known to be causative agents of human diarrhoea, *Isoospora belli* was detected in eleven individuals (32.3%), and *Cryptosporidium parvum*, *Dientamoeba fragilis*, *Entamoeba histolytica*, and *Giardia lamblia* each on single occasions (3%). Yeast cells were present in eight faecal samples (33%). The combinations of different protists and helminths found in the 34 patients were as follows: seven with oocysts of *I. belli*, only; three with *I. belli* and yeast cells; one with *I. belli*, *D. fragilis* and eggs of *Ancylostoma/Necator*; one with *G. lamblia* and eggs of *Trichuris trichiura*; one with *E. histolytica*, *Entamoeba coli*, *Endolimax nana*, *G. lamblia* and oo-

cysts of *C. parvum*; three with *T. trichiura*, only; one with *T. trichiura* and yeast cells; one with *Ancylostoma/Necator*, only; one with larvae of *Strongyloides* sp., only; one with larvae of *Strongyloides* sp., eggs of *Ascaris lumbricoides* and *Ancylostoma/Necator*; four with abundant yeast cells, only. Ten had no detectable parasites.

Diarrhoea in Aids patients has been attributed most frequently to *C. parvum*, and less frequently to *I. belli*. Cryptosporidiosis is a zoonotic disease, with reservoirs of *C. parvum* in domestic and wild animals: man-to-man transmission is of great importance, however, and oocyst-contaminated water can be a major source of infection. Among immunocompetent persons the prevalence of this coccidian has been shown to be highest (3-20%) in developing countries, whereas in Europe and North America it is in the region of only 1-2% and 0.6-4.3% respectively (R Fayer & PLB Ungar 1986 *Microbiol Rev* 50: 458-483). In Aids patients with diarrhoea in Maryland, USA, however, the figure reached 15-16% (BE Laughton et al. 1988 *Gastroenterology* 94: 984-993, PD Smith et al. 1988 *Ann Intern Med* 108: 328-333), and in São Paulo, Brazil, oocysts were detected in 19.1% of 131 Aids patients examined (FC Sauda et al. 1993 *J Parasitol* 79: 454-456).

The coccidian *I. belli* is known only in man and was once regarded as an uncommon and non-pathogenic intestinal parasite. It is now established, however, that even in the immunocompetent individual the infection may be associated with gastrointestinal disturbances, and the advent of Aids has shown us that infection is much more common than previously supposed, particularly in the tropics. In São Paulo, for example, *I. belli* infection was recorded in 9.9% of the 131 Aids patients examined (FC Sauda et al. *loc. cit.*). Symptoms in Aids patients include fever, persistent diarrhoea and weight loss. A fatal outcome has been recorded in some cases (JP Dubey 1998 p. 325-326. In FEG Cox, JP Kreir, D Wakelin (eds). *Topley & Wilson's Microbiology and Microbial Infections Vol 5, Parasitology*, 9th ed. Arnold, London)

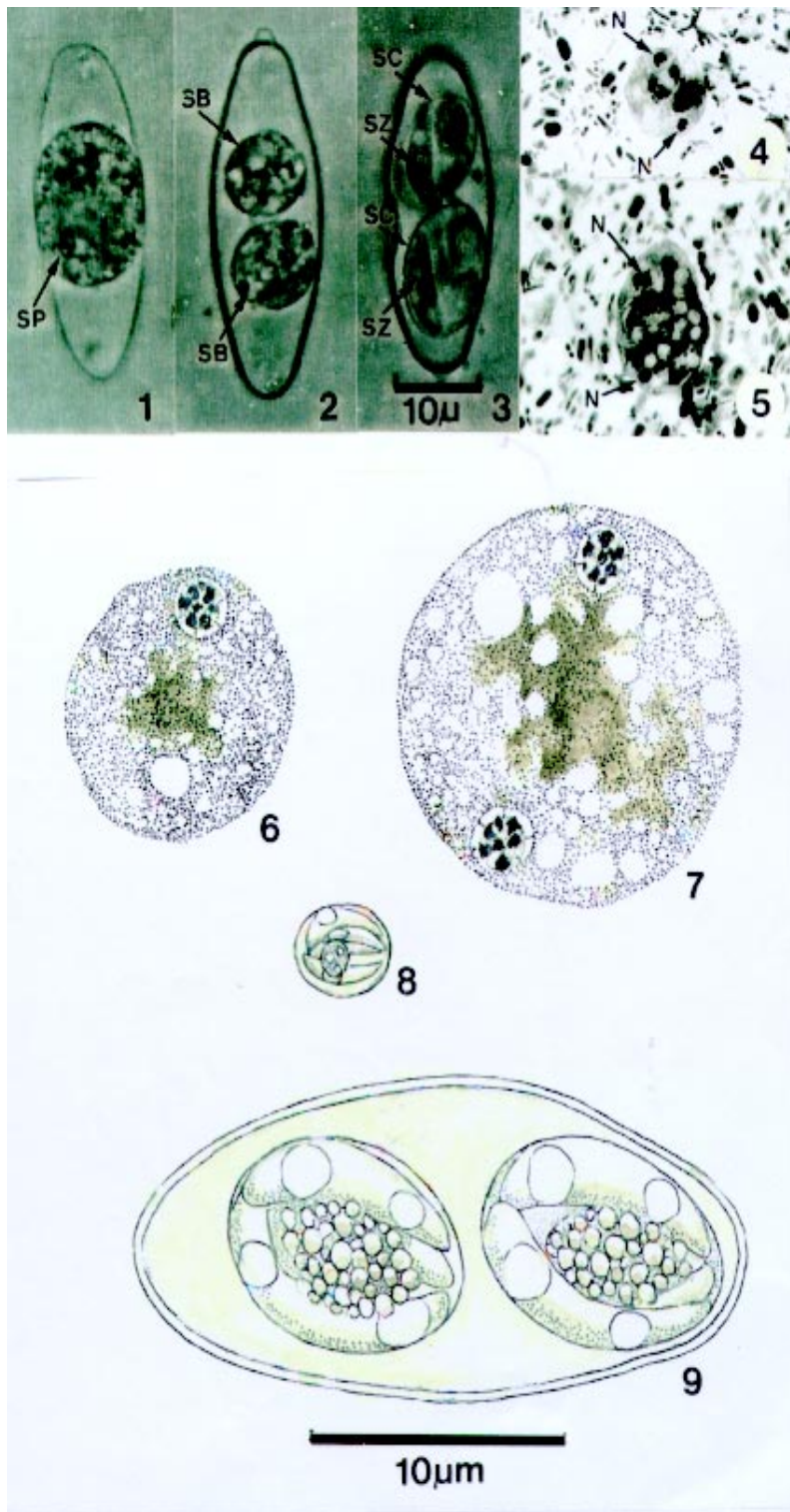
Due to its amoeboid movement, lack of flagella and absence of cysts in its life-cycle, *D. fragilis* was originally included as an atypical member of the family Endamoebidae (Order Amoebida). It maintained this precarious position for many years, until RR Camp et al. (1974 *J Protozool* 21: 69-82) studied the organism's ultrastructure and, as a result, transferred it to the order Trichomonadida, to accompany the genera *Trichomonas* and *Histomonas*. *D. fragilis* appears to be restricted to man and was for long regarded as an uncommon and harmless inhabitant of the colon lumen. More recent observations, however, recorded an infection-rate

Supported by grant 049426 of the Wellcome Trust, London (RL).

⁺Corresponding author. Fax: +55-91-226.1284.

Received 30 October 1998

Accepted 13 May 1999



Pathogenic protozoa in the diarrhoeic faeces of some HIV-seropositive individuals. Figs 1-3, 9 - *Isospora belli*. Fig. 1: newly passed, unsporulated oocyst. Fig. 2: oocyst with two sporoblasts, one day later. Figs 3, 9: mature oocysts, after two days. Figs 4 -7: *Dientamoeba fragilis*. Figs 4, 5: binucleate forms in Giemsa-stained faecal smears. Figs 6,7: uninucleate and binucleate forms in iron haematoxylin stained smears. Fig. 8: mature oocyst of *Cryptosporidium*. SP: sporont; SB: sporoblasts; SC: sporocysts; SZ: sporozoites; N: nuclei. In the photomicrographs the 10 µ bar applies to Figs 1-5: in the line drawings the 10 µm bar applies to Figs 6-9.

of 115/219 (53%) in a religious community in Los Angeles, USA (V Millet et al. 1983 *Digest Dis Sci* 28: 335-339), and that 79% of 237 cases of *D. fragilis* infection in Washington, USA, were symptomatic and mostly with diarrhoea or loose stools (JH Grendon et al. 1995 *J Trop Med Hyg* 98: 309-315). On the other hand, workers in the University Hospital of Fortaleza, Ceará, Brazil detected only a single infection with *D. fragilis* among 2,605 patients showing other intestinal parasites (OO Riedal et al. *Rev Med Univ Fed Ceará* 26/27: 29-33). There are reports of *D. fragilis* present in the diarrhoeic faeces of Aids patients although, as is the case with *Giardia* and the intestinal amoebae, there is no conclusive evidence that it is any more pathogenic in these patients than it is in normal individuals.

The yeast cells detected in eight of the faecal specimens in the present study were morphologically similar and budding was observed in all cases. Although the number of cells was low in the faeces of four individuals, the elevated number of yeast cells in four other individuals, in the apparent absence of other parasites, raised the suspicion that the fungus might be a cause of diarrhoea. Taxonomy of the yeast remained undetermined.

The number of individuals examined in this survey is small, but we feel it important to draw attention to the high prevalence (32.3%) of *I. belli* compared with the low figure (3%) for *C. parvum*. Of the eleven *I. belli* infections, eight were diagnosed only after concentration of the oocysts by zinc sulphate flotation, an indication that this technique should always accompany other methods of examination.

Whether or not the diarrhoea of the patient with *D. fragilis* was due to this parasite or *I. belli* is questionable. We feel it likely, however, that *D. fragilis*

was at least a contributory cause, in view of the very large numbers of this parasite present in the faeces, and because *D. fragilis* may produce severe diarrhoea in immunocompetent persons. For these reasons, clinicians should include *D. fragilis* in the list of possible causes of diarrhoea in HIV-seropositive individuals and Aids patients. Many laboratory technicians, however, are unfamiliar with the appearance of this parasite, either living or in stained preparations, and it is still frequently mis-diagnosed as an amoeba. Furthermore, degenerating forms become motionless and full of small vacuoles which coalesce into a single large vacuole surrounded by a thin layer of protoplasm containing the two nuclei: such forms bear a striking resemblance to *Blastocystis*. Living *D. fragilis* are distinguished from trophozoites of *E. histolytica* by their smaller size (4-12 µm for rounded forms), absence of ingested erythrocytes, and 'snail-like' locomotion. In stained smears they may appear larger, due to flattening. The most characteristic feature of *D. fragilis* is the predominance of bi-nucleate forms. Following iron-haematoxylin staining the nuclei are seen as spherical bodies, from 1-2.5 µm in diameter, with a central group of granules surrounded by a delicate nuclear membrane.

The absence of a protective cyst means that *D. fragilis* is usually destroyed or severely distorted by flotation concentration methods – one reason why fresh, Giemsa stained faecal smears are of utmost importance in diagnosis. Normal Giemsa staining (as for a blood film) is usually adequate for identification of *D. fragilis* by the experienced eye, but better results are obtained following fixation with aqueous Bouin's fluid and the use of a modified Giemsa method (R Lainson 1958 *Trans R Soc Trop Med Hyg* 52: 396-407).

