

Report of the Second Satellite Symposium on Ultrasound in Schistosomiasis

Joachim Richter/⁺, Ana Lúcia Coutinho Domingues*, Cristina H Barata**, Aluizio R Prata**, José Roberto Lambertucci***

Heinrich-Heine-Universitaet Duesseldorf, Tropenmedizinische Ambulanz, Geb.11.93, Moorentr. 5, D-40225 Duesseldorf, FR Germany *Universidade Federal de Pernambuco, Recife, PE, Brasil **Faculdade de Medicina do Triângulo Mineiro, Uberaba, MG, Brasil ***Faculdade de Medicina da Universidade Federal de Minas Gerais, Belo Horizonte, MG, Brasil

A group of experts on schistosomiasis and ultrasonography discussed the experiences and results obtained with the Niamey-Belo Horizonte Protocol on Ultrasonography in Schistosomiasis. A series of recommendations about qualitative and quantitative data obtained by ultrasound in studies performed in Africa and Brazil are presented. Immunological, genetic and epidemiological studies must rely on ultrasound for the identification of patients with periportal thickening/fibrosis.

Key words: schistosomiasis - schistosomiasis mansoni - ultrasound - periportal fibrosis

Ultrasonography (US) is the tool of first choice for assessing liver and spleen changes induced by *Schistosoma* spp. in endemic regions; it is the most economic imaging technique which permits the assessment of abdominal organs. Another advantage is that US can be performed using portable devices which allow its application in remote areas. In areas without electricity network US devices can be powered by portable generators.

The specificity of the characteristic US features of periportal fibrosis has been proven in several endemic areas like Brazil (Cerri et al. 1984), Sudan (Homeida et al. 1988) and Egypt (Abdel Wahab et al. 1989). Since in these studies different methodologies have been applied, data obtained were not directly comparable on an international scale. This prompted the World Health Organization to sponsor and assemble an International Expert Meeting in Cairo in 1991. A standardized protocol was developed and published (Cairo Working Group 1992). This protocol was revised by an expert group in Niamey, Niger in 1996, and during the previous First Satellite Symposium on Ultrasonography in Schistosomiasis in Belo Horizonte 1997 (Niamey Working Group 2000). The aim of the present Satellite Symposium was to discuss the practical experiences and results obtained with the Niamey-Belo Horizonte US protocol.

ACTUAL EXPERIENCES

The protocol has been applied in Uganda, Senegal, Brazil and Cambodia (to assess *Schistosoma mekongi*-associated morbidity (Christoph Hatz, pers. commun., 1999; this latter study is not reported here). Approximative figures are given because data analysis has not yet been completed (Table).

The following criteria of the usefulness of the various parameters of the Niamey-Belo Horizonte protocol were chosen: simplicity, reproducibility, time spent, relation to clinical status, power to differentiate between patients and control subjects (Minas Gerais study)

PRELIMINARY RESULTS - CORE PROTOCOL

Measurement of segmental portal branch wall thickness

After some training measurements are generally easy to perform by experienced ultrasonographers but this is not the case with less experienced examiners (Uganda, Senegal studies).

Reproducibility has been found unacceptably low in sub-samples of patients in Uganda and Senegal. Interobserver variance appears to decrease after training. However, even when performed by experienced ultrasonographers, reproducibility of measurements was unsatisfactory (Senegal).

Although the measurements of the portal branch walls take relatively long time this would be acceptable if the other criteria above were fulfilled.

Measurements were not found to reflect adequately the clinical status (hematemesis due to variceal bleeding, for example) in advanced cases in Senegal.

⁺Corresponding author. E-mail: joachim.richter1@uni-duesseldorf.de

Received 14 May 2001

Accepted 25 July 2001

TABLE
Countries and areas where the WHO-Niamey protocol has been applied

Country/area	Approximate number of patients	Patient selection	Assessment of interobserver variance
Uganda/Lake Albert	400	Community based	Yes
Senegal/Richard Toll	300	Community based and hospitalized cases	Yes
Brazil/Pernambuco	50	Hospitalized cases	No
Brazil/Minas Gerais	350/350	Community based; patients and control subjects	No

Image patterns (IP)

IP (Figures 1-8) are easily understood by experienced and less experienced examiners.

Interobserver variance was low when training of the different examiners had taken place before (Uganda, Senegal). It is sometimes difficult to discern a pattern D from slight thickening of the wall of the main portal vein. Therefore a measurement should be introduced which allows objectivation of the finding. The best way of assessing “central periportal thickening” appears to be to measure the wall at portal bifurcation in front of the portal trunk in a oblique liver scan. In the

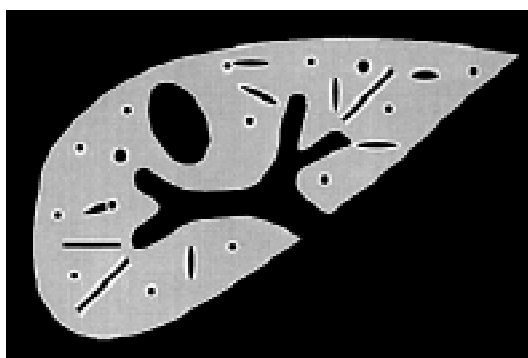


Fig. 3: image pattern C (peripheral periportal thickening)

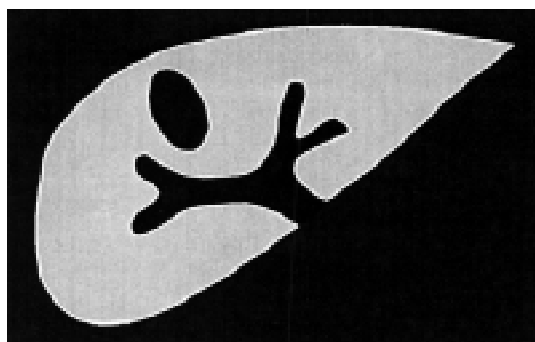


Fig. 1: image pattern A (normal sonographic liver appearance)




Fig. 4: image pattern D (central periportal thickening)



Fig. 2: image pattern B (pronounced peripheral portal branch echogenicity: ‘starry sky pattern’)

Minas Gerais study normal values of this measurement have been established (up to 5 mm in individuals with a weight up to 40 kg, and 6 mm in subjects weighing more than 40 kg). Data will be reanalyzed in function of body height.

IP assignment does not take much time. Contrary to measurements, when the examiner is looking for IP, he or her concentrates on parenchyma changes.

IP A, Dc-F reflected adequately the clinical status of all patients examined. IP B was found to be non-specific as it may be observed in children, after starvation, and in viral infections (e.g. a measles case

in Germany). IP Dc (mild periportal thickening around the portal stem and the peripheral branches) seems to have a worse clinical prognosis than D alone (central periportal thickening alone without peripheral thickening (Gerspacher-Lara et al. 1997). Most of the complicated cases have patterns E, Ec or F (advanced periportal thickening).

Liver measurements

Left liver lobe measurement is easily and rapidly performed. Right liver lobe measurement takes longer because the right liver lobe usually exceeds the dimensions of the US probe and measurement has to be done by adding partial diameters.

For the same reason left liver lobe measurement is less subjected to intra-and inter-observer variance than that of the right liver lobe.

Measurement of the right liver lobe takes almost twice the time as compared to left lobe measurement.

Relation of liver measurements to clinical status has not yet been assessed systematically in the above study.

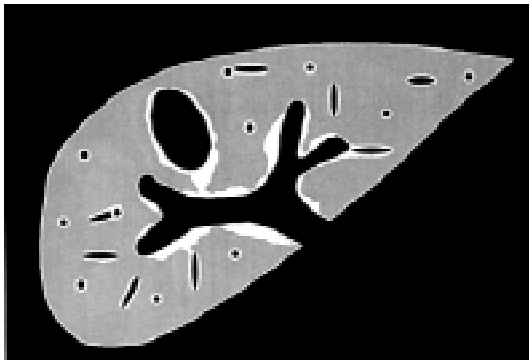


Fig. 5: image pattern Dc (peripheral periportal thickening + central periportal thickening)

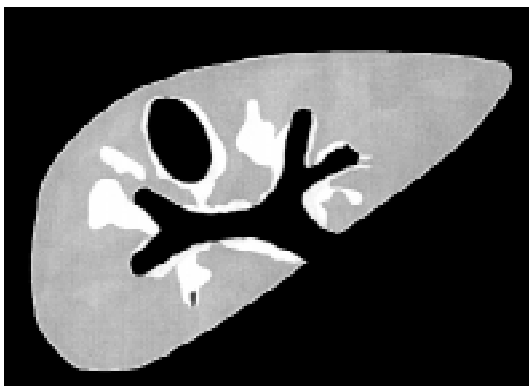


Fig. 6: image pattern E (central periportal thickening with echogenic patches expanding into the parenchyma)

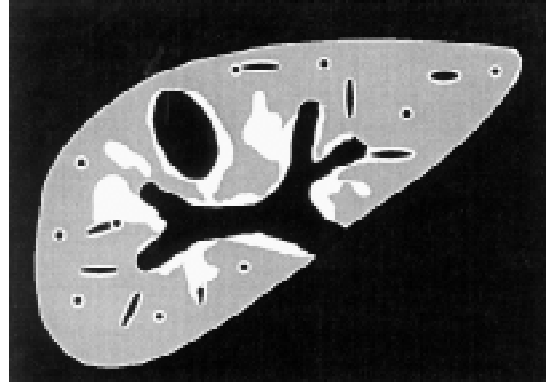


Fig. 7: image pattern Ec (advanced peripheral periportal thickening + central periportal thickening)

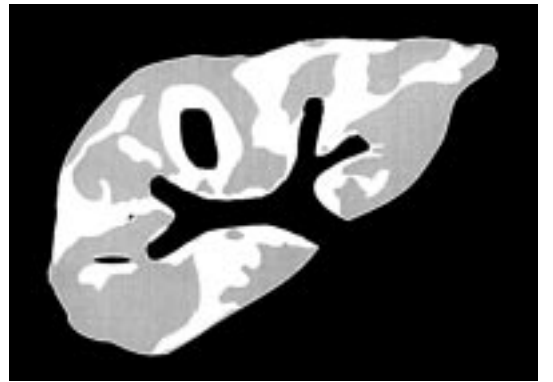


Fig. 8: image pattern F (very advanced central and peripheral periportal thickening)

Portal hypertension assessment

Whereas the measurement of portal vein diameter at the liver hilus and detection of ascites do not require exceptional skills, the capacity in detecting collaterals largely depends on the experience of the examiner and the preparation of the patient.

Reproducibility of portal vein measurements has been found excellent in Senegal and Uganda. Once the ultrasonographer is well trained in taking the measurement neither different experience of the examiner nor different quality of US devices interfered with measurement results. In hospitalized patients Doppler examination can be performed. However, reproducibility of Doppler measurements has never been investigated in schistosomiasis patients

Portal vein measurement is rapid. In hospitalized patients in Pernambuco, the measurement of the splenic vein behind the pancreas correlated better with portal and intravariceal pressure than portal vein diameter. Splenic vein measurement behind the pancreas requires a good preparation of

the patient. The high respiratory variation of this vessel (50%) in healthy subjects may be a confounding factor. It was therefore felt that this measurement including the assessment of respiration variation is recommended in hospitalized patients but was less useful in the field. The Niamey-Belo Horizonte Portal Hypertension score was found to reflect more the clinical status of four Senegalese patients with complicated periportal fibrosis than other scores tested in the past (Abdel-Wahab et al. 1993, Richter et al. 1998).

Additional investigations

Gall-bladder wall assessment should be integrated into the core protocol. Measurement is rapidly performed and adjustment to other biometric data is simple (up to 3 mm in individuals with a weight <= 30 kg, up to 4 mm in individuals > 30 kg). Characteristic changes (hyperechoic protrusions from the gall-bladder wall into the parenchyma) should be reported. Gall-bladder changes may precede periportal changes in a part of infected individuals and may therefore have an independent prognostic significance (Pinto da Silva et al. 1994).

In non-malarious areas spleen length should be always assessed. Spleen measurements may be also useful in areas of low levels of malaria endemicity. Data obtained in a holoendemic area (Uganda) are yet to be analyzed.

COMPARISON OF DATA OBTAINED BY ULTRASONOGRAPHY AND BY OTHER MEANS

The gold standard for the assessment of the specificity of US in vivo is liver biopsy. However, it must be stressed that the way of taking liver biopsies and the volume of the biopsy sample may interfere with biopsy results. A deep wedge liver biopsy of the left liver lobe obtained during surgery or laparoscopy has the highest sensitivity. For ethical reasons this invasive procedure can not be performed in patients with early lesions. Blind liver puncture does usually not yield enough material and fibrotic material is frequently not easily aspirated. Classification criteria have to be uniform discerning between an egg granuloma and periportal fibrosis. Classifications must be standardized

(Coutinho-Domingues 1998). Inter-observer variance in judging the sample must also be assessed.

“*Hepatosplenic schistosomiasis*” is a *clinical* definition which is *not synonymous* with periportal thickening as assessed by US. This is crucial when judging any kind of studies (genetic, immunological, epidemiologic), classifying patients by one of these or both methods (Lambertucci et al. 2000).

1 - *Hepatosplenic schistosomiasis* is also *not synonymous* with *hepato-splenomegaly*. Frequently the liver is not enlarged or even shrunken in patients with hepatosplenic schistosomiasis. The clinical definition of hepatosplenic schistosomiasis adopted by Aluizio Prata is the presence of a firm liver (left liver lobe) and a firm spleen palpable without breathing in a subject with parasitologically proven schistosomiasis. This definition is subject to high inter-observer-variance as it has been observed in Brazil, Uganda and Senegal (Lambertucci et al. 1996).

2 - Periportal fibrosis may occur without splenomegaly. Hyper-reactive splenomegaly may not be accompanied by ultrasonographically detectable periportal fibrosis. The relation between the different case definitions are illustrated in Fig. 9. The relation between the two case definitions (ideally maximal overlap percentage) has to be assessed in each endemic region and for each examination team.

3 - If US is applied to assess the value of clinical examination (to allow assessment of a high number of individuals in epidemiological surveys, when resources are limited) other parameters have to be included into the examination protocol. In the first phase, training of clinical examiners should be done with simultaneous ultrasound examination (“clinical hepatomegaly” was not associated to organ enlargement in a Senegalese sub-sample). Inter-observer variance should be reduced by intensive group training and ultrasound control in order to eliminate equivocal results.

4 - To allow direct comparison between clinical examination and US results, splenic measurements should include also the extension of the spleen

CHSS+ PPF- splenomegaly %?	CHSS+ PPF+ %?	CHSS- PPF+ (PPF without splenomegaly) %?
Doubtful cases	Borderline cases	Borderline cases

Fig. 9: relation between the definitions clinical hepatosplenic schistosomiasis (CHSS) and periportal fibrosis (PPF) as assessed by ultrasonography

below the costal margin in patients who do breathe quietly (not in deep inspiration). In huge splenomegaly palpation using the Hackett classification may be more adequate than ultrasonographic measurement, and could be reported on the US sheet.

Improvement of US in detecting early liver pathology:

1 - Comparative Necropsy-US studies in subjects infected with schistosomiasis but who died of other causes may be helpful in the identification of characteristic early US features. Here it is particularly important to use an unequivocal pathological definition of periportal fibrosis and to define and measure macroscopic lesions.

2 - Animal studies.

NOVEL TECHNIQUES FOR THE IDENTIFICATION OF EARLY PATHOLOGY

Actual US technology (portable devices) does not allow a clear-cut definition of early pathology.

High-tech US devices (e.g. with harmonic tissue imaging facility, examination of peripheral liver parenchyma with high frequency transducers, Doppler-US, contrast-Doppler-US)

Computed tomography (Cesmeli et al. 1997)

Helicoidal computed contrast-tomography

Magnetic resonance imaging (proved useful in neuroschistosomiasis)

INTERFERENCE OF OTHER LIVER DISEASES

Chronic hepatitis and alcoholic diseases are the major confounders when assessing US results in patients with schistosomiasis. Mixed hepatitis C and schistosomiasis is particularly frequent in Egypt, but periportal fibrosis and post-necrotic and/or alcoholic liver cirrhosis occur frequently also in some areas of Brazil. In epidemiological studies on hepatic morbidity alcoholism must be ruled out by careful medical history. Hepatitis B and C must be ruled out by the determination of at least HBsAg, and anti-HCV antibody.

ACUTE SCHISTOSOMIASIS

Reports on abdominal ultrasound studies in patients with acute schistosomiasis are still scarce and limited data are available on changes of liver texture in this stage of the disease (Lambertucci et al. 1994). More recently, 26 patients with acute *S. mansoni* infection were submitted to clinical and ultrasonographic examination by Barata et al. (1999). For comparison of ultrasound features, each patient was matched by age, gender, weight and height to a non-infected individual. In most patients (21/26) non-specific hepatosplenomegaly was observed without liver texture abnormalities which was frequently accom-

panied by intraabdominal lymph node swelling, especially around the portal hilus. Periportal thickening was observed in 5/26 patients. Three of these patients underwent percutaneous liver biopsy, which showed dense inflammatory infiltration of neutrophils, macrophages and eosinophils in the portal tracts associated with discrete fibrous tissue formation. Periportal thickening regressed six months after chemotherapy. Twenty four months post-therapy liver and spleen volumes had regressed to normal, whereas lymph nodes, although reduced in size were still easily recognized.

Intraabdominal lymph nodes may be seen also in healthy individuals, and lymphadenopathy can be observed in a variety of diseases other than schistosomiasis. The predictive value of particular hilar lymph node morphology changes observed in acute schistosomiasis but not in other disease (acute hepatitis, acute HIV-infection, acute EBV-infection etc.) is underway in Minas Gerais.

CONCLUSIONS AND RECOMMENDATIONS

The preliminary data obtained with the Niamey-Belo Horizonte protocol since 1997 do not yet permit to formulate definite recommendations. The protocol needs to be tested further in different endemic areas and by different research groups.

Periportal branch wall measurements appear not to be reliable indicators of periportal fibrosis when analyzed alone, but should still be performed to evaluate this parameter.

It is emphasized that measurements in general must not be abandoned. Measurements increase the objectivity of the results if these fulfill the following criteria: (1) measurements must be reproducible among different examiners; (2) reflect the clinical status; (3) must be adjusted to individual biometric data (body height and/or weight). Best reproducibility is obtained for measurements between 5 mm and 5 cm, and structures which are not too close to the transducer (because convex transducers distort the image).

Gallbladder assessment should be included into the core protocol.

Adequate training is crucial not only of the ultrasonographer but also of examiners foreseen for clinical assessment in epidemiological studies. Quality assessment and training of palpation should rely also on simultaneous ultrasonography.

Scientific studies (immunological, genetic and epidemiological) must rely on US criteria for periportal fibrosis. The clinical definition of hepatosplenic schistosomiasis is not sufficient to differentiate patients with periportal fibrosis from intestinal schistosomiasis.

ACKNOWLEDGEMENTS

To the Organizing Committee of the VII International Symposium on Schistosomiasis, and in particular Dr Miriam Tendler for giving the opportunity and infrastructure for this Satellite Symposium. Hospitality, logistic and travel costs of Dr Richter were covered by Fiocruz, Rio de Janeiro, and Danish Bilharziasis Laboratory, Denmark. Dr Prata and Dr Lambertucci wish to thank CNPq, WHO and the National Health Foundation for sponsoring the work that has been developed in Brazil.

REFERENCES

- Abdel-Wahab MF, Esmat G, Milad M, Abdel-Razek S, Strickland GT 1989. Characteristic sonographic pattern of schistosomal hepatic fibrosis. *Am J Trop Med Hyg* 40: 72-76.
- Abdel-Wahab MF, Esmat G, Farrag A, El-Boracy Y, Strickland GT 1993. Ultrasonographic prediction of esophageal varices in schistosomiasis mansoni. *Am J Gastroenterol* 88: 560-563.
- Barata CH, Pinto-Silva RA, Lambertucci JR 1999. Abdominal ultrasound in acute schistosomiasis mansoni. *Brit J Radiol* 72: 949-952.
- Cairo Working Group 1992. The use of diagnostic ultrasound in schistosomiasis - attempts at standardization of methodology. *Acta Trop* 51: 45-63.
- Cerri GG, Alves VAF, Magalhães A 1984. Hepatosplenic schistosomiasis mansoni: ultrasound manifestations. *Radiology* 153: 777-780.
- Cesmeli E, Vogelaers D, Voet D, Duyck P, Peleman R, Kunnen M, Afschrift M 1997. Ultrasound and CT changes of liver parenchyma in acute schistosomiasis. *Br J Radiol* 70: 758-760.
- Coutinho-Domingues AL 1998. *Ultra-sonografia na Esquistossomose Mansônica Hépatoesplênica: Avaliação da Intensidade da Fibrose Periportal e da Hipertensão Porta*. PhD Thesis, Federal University of Recife, Brazil.
- Gerspacher-Lara R, Pinto-Silva RA, Rayes AAM, Drummond SC, Lambertucci JR 1997. Ultrasonography of periportal fibrosis in schistosomiasis mansoni in Brazil. *Trans R Soc Trop Med Hyg* 91: 307-309.
- Homeida MA, Abdel-Gadir AF, Cheever AW, Bennett JL, Arbab BMO, Ibrahim SZ, Abdel-Salam IM, Dafalla AA, Nash TE 1988. Diagnosis of pathologically confirmed Symmer's periportal fibrosis by ultrasonography: a prospective blinded study. *Am J Trop Med Hyg* 38: 86-91.
- Lambertucci JR, Gerspacher-Lara R, Pinto-Silva RA, Barbosa MM, Teixeira R, Barbosa HF, Serufo JC, Rezende SC, Rayes AM 2000. The Queixadinha Project: a study on morbidity and schistosomiasis control in the northeast of the state of Minas Gerais, in Brazil. *Rev Soc Bras Med Trop* 29: 127-135.
- Lambertucci JR, Pinto-Silva RA, Gerspacher-Lara R, Barata CH 1994. Acute Manson's schistosomiasis: sonographic features. *Trans R Soc Trop Med Hyg* 88: 76-77.
- Lambertucci JR, Serufo JC, Gerspacher-Lara R, Rayes AA, Teixeira R, Nobre V, Antunes CM 2000. *Schistosoma mansoni*: assessment of morbidity before and after control. *Acta Trop* 77: 101-109.
- Niamey Working Group 2000. Ultrasound in schistosomiasis. A practical guide to the standardized use of ultrasonography for the assessment of schistosomiasis-related morbidity. World Health Organization/TDR/SCH/ULTRASON/document, Geneva, Switzerland, in press.
- Pinto-Silva RA, Abrantes WL, Antunes CM, Lambertucci JR 1994. Sonographic features of portal hypertension in schistosomiasis mansoni. *Rev Inst Med Trop São Paulo* 36: 355-361.
- Richter J, Correia Dacal AR, Vergetti de Siqueira JG, Poggensee G, Mannsmann U, Deelder AM, Feldmeier H 1998. Sonographic prediction of variceal bleeding in patients with liver fibrosis due to *Schistosoma mansoni*. *Trop Med Intern Health* 3: 728-735.