

SHORT COMMUNICATION

Capillariidae Eggs Found in the Urine of a Free Ranging Maned Wolf from Argentina

Pablo Martín Beldomenico/⁺, Daniel Hunzicker*, Julio Lopez Taverna*, Paula K Rejf

Facultad de Ciencias Veterinarias, Universidad Nacional del Litoral, P. Kreder 2805 (3080) Esperanza, Santa Fe, Argentina

*Estación Zoológica Experimental "Granja La Esmeralda", Santa Fe, Argentina

The first finding of a Capillariid in the urinary tract of a free ranging maned wolf (Chrysocyon brachyurus) is described. The individual was an adult male attacked by dogs in the locality of Cayastacito (Santa Fe, Argentina, 31°05' S, 60° 34' W). Eggs found in urine measured 64.6-66.9µm (mean 65.4µm) x 26.9-31µm (mean 29µm). Further studies are needed to determine whether this finding corresponds to a new Capillariid species, related to C. brachyurus, or it is an already described species that has been introduced by domestic dogs.

Key words: *Chrysocyon brachyurus* - maned wolf - Capillariidae - urinary tract - Argentina

The family Capillariidae includes several species parasitizing an enormous variety of domestic and wild animals worldwide. Species like *Capillaria plica*, *C. feliscati* and *C. mucronata*, among others, have been found in the urinary bladder, ureters or kidney pelvis of wild and domestic carnivores (Soulsby 1982). However, literature on urinary Capillariids of neotropical canids is scarce.

Santa Fe province habitats, heart of the rich and productive Argentine Pampas, are highly modified by human activities, mainly agriculture and cattle farming. Thus, wild canids, such as Pampa's grey fox (*Pseudalopex gymnocercus*), crab-eating fox (*Cerdocyon thous*) and maned wolf (*Chrysocyon brachyurus*), experience extensive contact with human beings and their domestic animals.

Although the endangered maned wolf has been shown to harbor *Dioctophyma renale* in its kidneys (Kumar et al. 1972, Carvalho & Vasconcelos 1995); no previous records exist of any Capillariid parasitizing the urinary tract of this species.

On September 8th, 2000, an adult maned wolf was rescued after being attacked by dogs in Cayastacito (31°05' S, 60°34' W), Santa Fe province. The wolf was taken to Estación Zoológica Experimental "Granja La Esmeralda" in Santa Fe. At physical examination, apart from the wounds produced by the dogs, the individual seemed healthy. The animal was male and, according to its teeth, older than 3 years. Urine, blood and fecal samples were collected. Urine was centrifuged and the sediment examined by optic microscopy. Findings included Capillariidae eggs (Figure), measuring 64.6-66.9 µm (mean 65.4 µm - n: 6) x 26.9-31.0 µm (mean 29 µm - n: 6). Moderate quantity of leukocytes, together with scarce erythrocytes and squa-

mous cells were also found in the urine sediment. Physical analysis of urine revealed a dark yellow color, turbid aspect, with a pH of 6 and a density of 1020. Chemical analysis was conducted by urine reagent strips (Roche Chemstrip® 10SG), revealing protein concentrations of 30 mg/kg, Urobilinogen concentrations of 1 mg/dl and 250 erythrocytes/µl. Bilirubin was valued as ++ and glucose was negative. Hemogram results showed slight eosinophilia (768 cells/µl - 12%). Coproparasitologic analyses (flotation - sedimentation) were negative.

Genera of Capillariidae are controversial. Moravec (1982) proposed a systematic arrangement recognizing 22 genera as valid. Romashov (1985) differentiated six taxonomic groups of capillariids according to the architecture of the shell of eggs taken from females of 18 species of Capillariidae: shell ridged, *Capillaria*; honeycomb shell, *Eucoleus*; rough egg surface with few, irregular depressions, *Calodium*; shell with relatively large, elongated craters with uneven edges, *Liniscus*; rough egg surface with relatively short, low ridges, *Thominx*; and eggs with thin, smooth shell and larvae developing in eggs in utero, *Capillaria* and *Skrjabinocapillaria*. According to this classification, our eggs might belong to *Capillaria* genus. However, the taxonomic classification of capillariids parasitizing urinary bladder of carnivorous is not uniform. Vicente et al. (1997) consider species like *C. plica* and *C. feliscati* as belonging to the genus *Pearsonema*, criterion that was also adopted in a recent publication (Segovia et al. 2001).

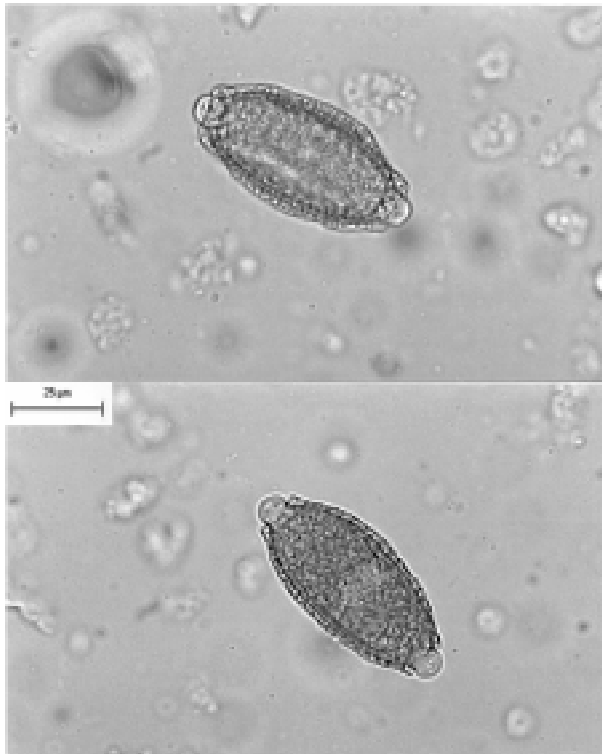
Further studies are needed to determine whether this finding corresponds to a new Capillariid species, related to *C. brachyurus*, or it has already been described as a parasite of other host species, which would share the habitats with the maned wolf. If the latter is the case, our finding could be either an aberrant event or the infection could be spread in the maned wolf population.

Urinary bladder nematodes seldom cause apparent disease. *C. plica* in dogs usually involves only a few worms and causes no obvious illness or discomfort. Pain on urination and during copulation has been ascribed to

Corresponding author. Fax: +54-342-422.733. E-mail: pbeldome@ucdavis.edu

Received 30 May 2001

Accepted 20 February 2002



Eggs of Capillariidae, X450, showing their bipolar knobs and their ridged and rough shell.

C. plica infection as secondary bacterial infection with severe cystitis (Georgi & Georgi 1992). Egnik's (1950) observations led him to conclude that foxes suffer from the effects of *C. plica* more severely than dogs.

Therefore, after species identification, evaluations of prevalence and effects of this nematode parasitism are necessary to assess its impact on the endangered maned wolf population.

ACKNOWLEDGEMENTS

To Drs Scott L Gardner, Sharom Deem, Félix Martinez and Roberto Aguilar for their technical support and Marcela Uhart for manuscript review. To the Histology Department of Facultad de Ciencias Veterinarias, Universidad Nacional del Litoral for sharing the microscopic image digitalizer equipment.

REFERENCES

- Carvalho C, Vasconcelos L 1995. Disease, food and reproduction of the maned wolf – *Chrysocyon brachyurus* (Illiger) (Carnivora, Canidae) in southeast Brazil. *Rev Bras Zool* 12: 627-640.
- Egnik K 1950. Die Biologie von *Capillaria plica* (Trichuroidea: Nematoda). *Z Tropenmed Parasitol* 1: 560-571.
- Georgi J, Georgi M 1992. *Canine Clinical Parasitology*, Lea & Febiger, Philadelphia, 227 pp.
- Kumar V, Vercauysse J, Vandesteene R 1972. Studies on two cases of *Dioctophyma renale* (Goeze, 1782) infection in *Chrysocyon brachyurus* (Illiger). *Acta Zool Pathol Antverp* 56: 83-98.
- Moravec F 1982. Proposal of a new systematic arrangement of nematodes of the family Capillariidae. *Folia Parasitol (Praha)* 29: 119-132.
- Romashov BV 1985. Morphological characteristics of the egg shell of Capillariidae. *Parazitologiya* 19: 399-402.
- Segovia JM, Torres J, Miquel J, Llaneza L, Feliu C 2001. Helminths in the wolf, *Canis lupus*, from north-western Spain. *J Helminthol* 75: 183-192.
- Soulsby E 1982. *Helminths, Arthropods and Protozoa of Domesticated Animals*, 7th ed., Lea & Febiger, Philadelphia, 809 pp.
- Vicente JJ, Rodrigues HO, Gomes DC, Pinto RM 1997. Nematóides do Brasil. Parte V: Nematóides de mamíferos. *Rev Bras Zool* 14: 1-452.