

## On cytoadhesion of *Plasmodium vivax*: *raison d'être*?

Fabio TM Costa<sup>1/+</sup>, Stefanie CP Lopes<sup>1</sup>, Mireia Ferrer<sup>2</sup>, Juliana A Leite<sup>1</sup>, Lorena Martin-Jaular<sup>2</sup>, Maria Bernabeu<sup>2</sup>, Paulo A Nogueira<sup>3</sup>, Maria Paula G Mourão<sup>4</sup>, Carmen Fernandez-Becerra<sup>2</sup>, Marcus VG Lacerda<sup>4</sup>, Hernando del Portillo<sup>2,5/+</sup>

<sup>1</sup>Departamento de Genética, Evolução e Bioagentes, Instituto de Biologia, Universidade Estadual de Campinas, Campinas, SP, Brasil

<sup>2</sup>Barcelona Center for International Health Research, Barcelona, Spain <sup>3</sup>Instituto Leônidas e Maria Deane-Fiocruz, Manaus, AM, Brasil

<sup>4</sup>Fundação de Medicina Tropical Doutor Heitor Vieira Dourado, Manaus, AM, Brasil

<sup>5</sup>Institució Catalana de Recerca i Estudis Avançats, Barcelona, Spain

*It is generally accepted that Plasmodium vivax, the most widely distributed human malaria parasite, causes mild disease and that this species does not sequester in the deep capillaries of internal organs. Recent evidence, however, has demonstrated that there is severe disease, sometimes resulting in death, exclusively associated with P. vivax and that P. vivax-infected reticulocytes are able to cytoadhere in vitro to different endothelial cells and placental cryosections. Here, we review the scarce and preliminary data on cytoadherence in P. vivax, reinforcing the importance of this phenomenon in this species and highlighting the avenues that it opens for our understanding of the pathology of this neglected human malaria parasite.*

Key words: *Plasmodium vivax* - malaria - cytoadherence - severe disease

*Plasmodium vivax: the last malaria parasite?* - The renewed momentum for global malaria eradication has generated the need for further study of *P. vivax* (Alonso et al. 2011). In fact, the burden of *P. vivax* seems to be increasing from 70-80 million to 130-435 million clinical cases per year and threatens 2.6 billion people (Mendis et al. 2001, Hay et al. 2004, Guerra et al. 2010). Frequent relapses of infection with this species and the emergence of chloroquine resistance are two major factors likely responsible for this increasing burden of *P. vivax* malaria (Kochar et al. 2005, Baird 2007, Price et al. 2007). Notably, in South and Southeast Asia, *P. vivax* infections represent more than 50% of malaria cases, whereas in Central and South America infections by *P. vivax* can reach up to 70-90%. Thus, *P. vivax* is most prevalent malaria outside Sub-Saharan Africa.

Notably, the life cycle and biology of *P. vivax* differ from those of *Plasmodium falciparum* (Table). The following differences are worth highlighting: (i) *P. vivax* sporozoites can enter hepatocytes and remain dormant as hypnozoites, which are responsible for clinical relapses (Krotoski 1985), (ii) *P. vivax* preferentially, if not exclusively, invades reticulocytes (Kitchen 1938), and this is arguably the reason why parasitemias are low in natural *vivax* infection, (iii) gametocytes appear in the blood before clinical symptoms are manifest, which compli-

cates and compromises clinical treatment and control of the disease (Boyd & Kitchen 1937), and (iv) mosquito vectors from areas where *P. vivax* is more prevalent are outdoor-biting and anthropophilic, which makes control measures, such as impregnated bed nets, of limited value. Experts therefore agree that due to this unique biology, the present tools used to control *P. falciparum* will not suffice for *P. vivax*, which reinforces the importance of understanding the biology, epidemiology and pathology of *P. vivax* (Mueller et al. 2009).

*Pathology of P. vivax* - Pathogenesis in *falciparum* malaria is multi-factorial and involves numerous host and parasite factors. However, central to this pathogenesis are the phenomena of antigenic variation, rosetting and cytoadherence (Miller et al. 2002). Antigenic variation refers to the capacity of parasites to clonally express variant proteins at the surface of infected red blood cells (IRBCs) and this function to evade the host immune response and allow for the establishment of chronic infection (Brown & Brown 1965). Rosetting is the formation of rosettes resulting from the adhesion of erythrocytes infected with mature forms of the parasite to uninfected erythrocytes and this process has been shown to increase the microvascular obstruction of blood flow (David et al. 1988). Cytoadherence refers to the capacity of IRBC to adhere to host cells. This process has been described for the endothelium and for the placenta and it causes the disappearance of mature trophozoites and schizonts from the peripheral blood (Bignami & Bastianelli 1889, Miller et al. 1994). Remarkably, the original search for genes responsible for these phenomena identified a single subtelomeric multigene variant family named the *var* gene family (Baruch et al. 1995, Smith et al. 1995, Su et al. 1995). *P. falciparum var* genes encode proteins collectively known as PfEMP1 that contain ligand domains for different endothelial receptors, such as CD36, intercellular adhesion molecule-1 (ICAM-1) and chondroitin sulphate

Financial support: FAPESP, CNPq (FTMC and MVGL), CELLEX Foundation, MICINN (CFB and HAP)

FTMC and HdP contributed equally to this work.

+ Corresponding authors: hernando.delportillo@cresib.cat; costaftm@unicamp.br

Received 16 April 2011

Accepted 10 June 2011

TABLE  
Main biological differences between *Plasmodium vivax* and *Plasmodium falciparum*

<i>P. vivax</i>	<i>P. falciparum</i>
Seventy-300 million yearly clinical cases (Mendis et al. 2001, Hay et al. 2004).	Three hundred-500 million yearly clinical cases (Guerra et al. 2007).
Usually non-lethal and non-severe; yet this situation has radically changed recently (Kochar et al. 2009).	Lethal and severe, responsible for close to one million deaths each year mostly in children under five years old.
Sporozoites can remain within hepatocytes in dormant stages known as hypnozoites (Krotoski 1985).	Sporozoites within hepatocytes undergo immediate schizogony with no dormant stages.
Hypnozoites cause clinical relapses.	There are no clinical relapses.
Invades preferentially, if not exclusively, reticulocytes (Kitchen 1938).	Invades all red blood cells.
Requires mainly (Chitnis & Sharma 2008), but not exclusively (Mercereau-Pujalon & Menard 2010), the Duffy Blood Group as the receptor for entrance into reticulocytes.	Has multiple entrance pathways and receptors (Cowman & Crabb 2006).
Surface membrane of infected reticulocytes suffers invaginations called caveola vesicles.	Surface membrane of infected red blood cells suffers protrusions called knobs.
Continuous in vitro culture not available.	Continuous in vitro culture available since 1976 (Trager & Jensen 1976).
Gametocytes appear in peripheral blood before clinical symptoms (Boyd & Kitchen 1937).	Gametocytes appear in peripheral blood after clinical symptoms.
Mosquito vectors are mostly outdoor biting.	Mosquito vectors are mostly indoor biting.
Chloroquine resistance first reported in 1989.	Chloroquine resistance first reported in late 1950s.
Complete genome sequence first reported in 2008 (Carlton et al. 2008).	Complete genome sequence first reported in 2002 (Gardner et al. 2002).

A (CSA). Furthermore, *var* gene expression is associated with various clinical syndromes of severe *falciparum* disease (Pasternak & Dzikowski 2009). In addition to *var* genes, the full genome sequence of *P. falciparum* has revealed additional subtelomeric multigene families that are likely involved in the pathology of malaria (Gardner et al. 2002). These data therefore indicate that expression of *P. falciparum* multigene families, which are clustered in subtelomeric regions, is associated with the pathology of *falciparum* malaria and the phenomena of antigenic variation, rosetting and cytoadherence.

Studies from *P. vivax* patients in Sri Lanka have shown that *P. vivax* undergoes antigenic variation and that the mature forms have the capacity for rosetting (Udagama et al. 1987, Udomsanpetch et al. 1995). Thus, using immune sera from primary-infected or multiply infected *P. vivax* patients, immunofluorescence assays from different isolates have revealed that only patients with multiple infections were able to recognise several different isolates (Udagama et al. 1987). Moreover, rosetting experiments using blood and wild isolates revealed that close to 70% of the isolates showed rosetting (Udomsanpetch et al. 1995). However, approaches similar to those used for studies of cytoadhesion in *P. falciparum* (Hasler et al. 1993) failed to observe the cytoadhesion of *P. vivax*-infected reticulocytes to human umbilical vein endothelial cells, C32 melanoma cells, platelets or to purified CD36. Notably, sequence analysis of a *P. vivax* isolate revealed the presence of a subtelomeric multigene variant super-

family termed *vir* (*P. vivax* variant genes), which is likely involved in antigenic variation in this species (del Portillo et al. 2001). Further analyses have indicated that *vir* genes could have additional functions and it was hypothesised that they mediate adhesion to facilitate the establishment of chronic infection (del Portillo et al. 2004). The complete genome sequence of the Sal I strain revealed the presence of additional subtelomeric gene families (Carlton et al. 2008), which further indicated that *P. vivax*, like *P. falciparum*, has clustered multigene families at its chromosome ends. However, the relationship between these gene families and pathology has been mostly overlooked, as *vivax* malaria had been predominantly accepted to be clinically benign and not to cytoadhere.

In the last 10 years, the severe complications observed in *P. falciparum* infection, which include renal failure, jaundice, acute respiratory distress syndrome, cerebral malaria, seizures, anemia, hyperparasitemia, thrombocytopenia, pulmonary edema, splenic rupture and death, have also been reported worldwide for *P. vivax* (Kochar et al. 2005, 2009, Baird 2007, Price et al. 2007, Alexandre et al. 2010). However, diagnosis was made in most cases using Giemsa staining, which cast reasonable doubts as to the potential for undetectable infection with *P. falciparum*. The use of nested polymerase chain reactions (PCRs) to exclude the possibility of mixed infection, however, has confirmed sole infection with *P. vivax* in some of these reports. In addition, the clinical exclusion of other syndromes, such as those caused by respiratory

pathogens, human immunodeficiency virus, histoplasma, coccidians and paracoccidians, as well as the adoption of World Health Organization criteria used for severe *falciparum* disease, are now being adopted for the reports of new cases of severe *vivax* disease. In Brazil, for instance, a recent study from the city of Manaus, Amazonas, showed an increased number of hospital admissions for *P. vivax*-infected patients (Santos-Ciminera et al. 2007) with increased clinical severity, which were mostly related to jaundice and severe anaemia after *P. falciparum* or other possible causes of disease were excluded (Alexandre et al. 2010). Similar to what has been observed in Brazil, an increasing number of cases with complications have been reported worldwide (Anstey et al. 2009). These data illustrate and confirm that there is indeed an augmentation of the number of severe cases exclusively associated with *P. vivax* infection across different endemic regions of the world. Nevertheless, whether this severity is directly associated with changes in parasite biology, increasing resistance to antimalarial drugs or with the presence of comorbidities is still a matter of debate.

Although it has long been axiomatic that *P. vivax* is less virulent than *P. falciparum* due to its lack of cytoadherence, the existence of subtelomeric variant families in the genome of *P. vivax* and the recent confirmed reports of severe *vivax* disease have led us to question the validity of this view. Moreover, in spite of studies that have documented the presence of all stages of *P. vivax* in the peripheral blood of infected patients, previous studies revealed that the presence of mature forms were disproportionately lower than young stages, indicating a segmentation of these mature forms somewhere else than in peripheral blood (Field et al. 1963).

**Cytoadherence of *P. vivax*-infected reticulocytes** - In an attempt to elucidate whether cytoadhesion is a *P. falciparum*-restricted phenomenon, a recent collaborative study by our groups (Carvalho et al. 2010) demonstrated that *P. vivax*-IRBC (Pv-IRBCs) obtained from Brazilian patients with non-severe disease were able to cytoadhere under static or flow conditions to brain, lung (Fig. 1), placental and endothelial receptors, which have previously been implicated in the binding of *P. falciparum* (Beeson & Brown 2002). Under static conditions, the number per mm<sup>2</sup> of adherent Pv-IRBC was 10-15-fold lower than that of *P. falciparum*-IRBC (Pf-IRBC). However, the percentage of parasites able to bind endothelial receptors under flow conditions did not differ significantly. These results differ from those previously reported in Sri Lanka (Udomsanpetch et al. 1995). One explanation for this discrepancy is that our cytoadhesion assays used percoll-enriched mature forms of the parasite at pH 6.8, whereas this other studies has used forms obtained directly from the blood at pH 7.4.

To identify potential endothelial receptors involved in *P. vivax* adherence, CHO cells expressing different endothelial receptors were used for adhesion assays. We found greater adhesion to ICAM-1-transfected cells in comparison to CD36-transfected or untransfected cells. However, we cannot rule out the role of additional host receptors in Pv-IRBC. Moreover, adhesion of parasites to endothelial cells was significantly inhibited by the addi-

tion of soluble CSA, although treatment of the same cells with chondroitinase-ABC (CaseABC) did not affect adhesion (Carvalho et al. 2010). These results indicated that the CSA backbone was not directly involved in parasite adhesion. As CSA is highly negatively charged due to the presence of sulphate groups, the inhibition of cytoadhesion may be sustained by a charge interaction. Indeed, it has been shown that the binding of several *P. falciparum* VAR2CSA domains to CSA at various salt concentrations is not different from their binding to non-placental domains, which demonstrates that binding to CSA is highly dependent on ionic strength (Resende et al. 2009).

We hypothesised that Vir proteins, due to their variant nature, sub-cellular localisation and genome organisation, could mediate *P. vivax* cytoadherence. By using two different antibodies raised against two different Vir proteins, the specific inhibition of the IRBC-endothelial cell interaction was demonstrated (Carvalho et al. 2010). To perform functional binding assays in the absence of a continuous in vitro culture system for *P. vivax*, 3D7 *P. falciparum* transgenic lines expressing different Vir proteins, motifs, protein domains and secondary structures have been generated (M Bernabeu & C Fernandez-Becerra, unpublished observations). Notably, one of these transgenic lines that expressed Vir proteins on the surface of the IRBC mediated cytoadherence to ICAM-1, VCAM and E-selectin. Moreover, two polyclonal, mono-specific anti-Vir antibodies significantly inhibited this adhesion. Together, these data further support our findings and indicate that *P. vivax*-infected reticulocytes can cytoadhere to a variety of endothelial receptors and that this adherence is at least partially mediated specifically by Vir proteins.

**Cytoadherence and severe *vivax* disease** - The recent findings that infection with *P. vivax* can lead to severe complications in endemic areas worldwide (Kochar et al. 2005, Lomar et al. 2005, Tjitra et al. 2008) have led the scientific community to search for the mechanisms of pathogenesis related to this infection, which have been neglected thus far. One of the major arguments against the severity of *P. vivax* infection was based on the lack of cytoadherence and the formation of knobs by this parasite. However, robust evidence points to the existence of severe *falciparum* disease without the presence of the aforementioned mechanisms, which therefore suggests that these are not the *sine qua non* for severity (Maegraith 1948). As reviewed above, cytoadhesion was demonstrated for *P. vivax* using an in vitro approach (Carvalho et al. 2010) and unpublished data on adhesion to the placenta (FTM Costa & MVG Lacerda, unpublished observations) (Fig. 2), lungs and spleen (MVG Lacerda & H del Portillo, unpublished observations) have recently been obtained. When IRBCs are found inside of blood vessels in human tissues, there is no way to confirm that cytoadhesion has taken place, and this possibility should also be taken into account for previous studies of *P. falciparum*-infected tissues.

There is not much information available on autopsies related to *vivax* infection, which could lend support to cytoadherence during severe *vivax* disease. As reviewed elsewhere (Anstey et al. 2009), however, early XX century autopsies for which *P. vivax* diagnosis was based on

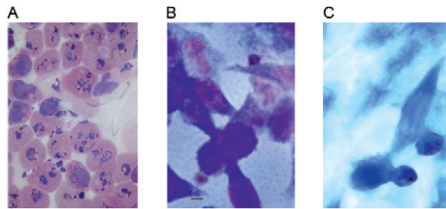


Fig. 1: adhesion of *Plasmodium vivax*-infected erythrocytes maturing forms to endothelial cells. A: Giemsa staining of *P. vivax* mature forms obtained after Percoll enrichment. Representative photomicrographs of *P. vivax*-infected red blood cells adhesion to human lung; B: Saimiri brain; C: endothelial cells.

thick blood smears reported the presence of intracapillary masses of swollen, infected erythrocytes and pigment (Billings & Post 1915). In addition, these autopsies reported the frequent presence of mature malaria parasites within a red blood cell taking up the entire lumen and being in immediate contact with endothelial cells in some vessels in the brain, as well as an unusually large number of infected red cells and young plasmodia and a large amount of pigment in intestinal submucosal vessels (Bruetsch 1932). In these cases, however, comorbidities and mixed infection with *P. falciparum* were not properly discarded. More recently, one autopsy from India, which had confirmed *P. vivax* mono-infection by PCR, found congestion of alveolar capillaries by monocytic infiltrates and diffuse damage to alveolar membranes consistent with acute respiratory distress syndrome. Parasites were observed in lung tissue as well as in other organs without lesions (Valecha et al. 2009). Despite the fact that this is evidence from a single case, this resembles the findings of cytoadhesion in *P. falciparum* pulmonary disease (Corbett et al. 1989). From measurements of gas transfer and lung volume in non-severe *vivax* patients, the progressive alveolar-capillary dysfunction following treatment was found to be consistent with the greater inflammatory response induced by this parasite (Anstey et al. 2007). As a major complication of severe *vivax* disease, the pathogenesis of respiratory distress requires further investigation into the cytoadhesion that takes place, as suggested by studies of in vitro adhesion and endothelial activation of lung microvasculature. In fact, the host inflammatory response, the endothelial Weibel-Palade body release, and the plasma concentrations of angiopoietin-2, ICAM-1, E-selectin, interleukin (IL)-6 and IL-10 are greater in patients with *vivax* compared to *P. falciparum* malaria (Yeo et al. 2010). As the addition of lipopolysaccharide was found to increase the adhesion of IRBCs to human lung endothelial cells in vitro (Carvalho et al. 2010), it is possible that secondary bacterial infections may release endotoxins that could contribute to the enhanced endothelial activation and cytoadhesion. Thus, coinfections and pathogenesis during *vivax* infection require further investigation.

The role of platelets in cytoadhesion is well-documented for severe *falciparum* malaria. Here, platelets participate in strengthening the adhesion of IRBCs to

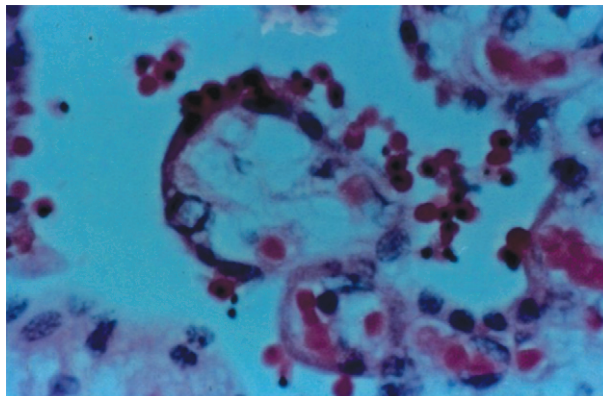


Fig. 2: presence of *Plasmodium vivax*-infected red blood cells attached to the syncytiotrophoblast of a placenta from a patient diagnosed with *P. vivax* in the 36th week of pregnancy (optical microscopy, 1,000X, Thomas' stain).

CD36 (known as glycoprotein IV in platelets), which most likely explains their accumulation in brain microvessels (Grau et al. 2003, Wassmer et al. 2004). Platelets can also participate in tumor necrosis factor (TNF)-induced microvascular pathology (Lou et al. 1997, Wassmer et al. 2006) and platelet-derived microparticles seem to play an important role in endothelial activation (Combes et al. 2006). Despite strong evidence that *vivax* disease triggers greater thrombocytopenia than does *falciparum* disease (Kochar et al. 2010), there are no data available on the ability of these particles to enhance *vivax* cytoadhesion.

As reviewed elsewhere (Clark & Alleva 2009), sequestration in the bone marrow has been shown to cause the dyserythropoiesis observed in *P. falciparum* malaria (Wickramasinghe et al. 1987). Dyserythropoiesis was demonstrated in the bone marrow during *P. vivax* infection, where cytoadhesion was not thought to play a role (Wickramasinghe et al. 1989). As a result, the idea of cytoadhesion as the cause of severe anaemia was abandoned and the presence of increased TNF levels was shown to induce dyserythropoiesis in both species (Clark & Chaudhri 1988). The presence of *P. vivax* parasites in the bone marrow prompts the need for clarification on its implications for disease pathogenesis (Lacerda et al. 2008).

*Perspectives and concluding remarks* - Demonstration of the cytoadherence of *P. vivax* opens new investigational lines of research. First, proteomic analysis of adhesion proteins and Vir proteins on the surface of infected reticulocytes should further the identification of new parasite ligands. In addition, microscopic analyses from autopsies where coinfections have been ruled out will reinforce the presence of parasite cytoadherence. The role of cytoadherence to the spleen, lungs and placenta in the establishment of chronic infection will further reveal the molecular basis of pathology in *P. vivax* malaria and the demonstration of cytoadhesion in other tissues, such as the kidneys and bone marrow will confirm existing observations of severe disease and the association between cytoadhesion and severe disease syn-

dromes. Furthermore, technological breakthroughs in noninvasive imaging will demonstrate whether *P. vivax*-infected reticulocytes adhere to different organs in vivo and whether this adhesion is associated with severe *vivax* malaria. Ultimately, understanding the factors that determine *P. vivax*-associated morbidity and severe disease will contribute to the control, elimination and eradication of malaria worldwide (Bassat & Alonso 2011).

## REFERENCES

- Alexandre MA, Ferreira CO, Siqueira AM, Magalhaes BL, Mourao MP, Lacerda MV, Alecrim MG 2010. Severe *Plasmodium vivax* malaria, Brazilian Amazon. *Emerg Infect Dis* 16: 1611-1614.
- Alonso PL, Brown G, Arevalo-Herrera M, Binka F, Chitnis C, Collins F, Doumbo OK, Greenwood B, Hall BF, Levine MM, Mendis K, Newman RD, Plowe CV, Rodriguez MH, Sinden R, Slutsker L, Tanner M 2011. A research agenda to underpin malaria eradication. *PLoS Med* 8: e1000406.
- Anstey NM, Handojo T, Pain MC, Kenangalem E, Tjitra E, Price RN, Maguire GP 2007. Lung injury in *vivax* malaria: pathophysiological evidence for pulmonary vascular sequestration and posttreatment alveolar-capillary inflammation. *J Infect Dis* 195: 589-596.
- Anstey NM, Russell B, Yeo TW, Price RN 2009. The pathophysiology of *vivax* malaria. *Trends Parasitol* 25: 220-227.
- Baird JK 2007. Neglect of *Plasmodium vivax* malaria. *Trends Parasitol* 23: 533-539.
- Baruch DI, Pasloske BL, Singh HB, Bi X, Ma XC, Feldman M, Taraschi TF, Howard RJ 1995. Cloning the *P. falciparum* gene encoding PfEMP1, a malarial variant antigen and adherence receptor on the surface of parasitized human erythrocytes. *Cell* 82: 77-87.
- Bassat Q, Alonso PL 2011. Defying malaria: fathoming severe *Plasmodium vivax* disease. *Nat Med* 17: 48-49.
- Beeson JG, Brown GV 2002. Pathogenesis of *Plasmodium falciparum* malaria: the roles of parasite adhesion and antigenic variation. *Cell Mol Life Sci* 59: 258-271.
- Bignami A, Bastianelli G 1889. Observations of estivo-autumnal malaria. *Riforma Medica* 6: 1334-1335.
- Billings F, Post W 1915. Fatal malaria due to the tertian parasite. *Trans Chicago Path Soc* 9: 209-215.
- Boyd MF, Kitchen SF 1937. On the infectiousness of patients infected with *Plasmodium vivax* and *Plasmodium falciparum*. *Am J Trop Med Hyg* 17: 253-262.
- Brown KN, Brown IN 1965. Immunity to malaria: antigenic variation in chronic infections of *Plasmodium knowlesi*. *Nature* 208: 1286-1288.
- Bruetsch W 1932. The histopathology of therapeutic (tertian) malaria. *Am J Psychiatry* 12: 19-65.
- Carlton JM, Adams JH, Silva JC, Bidwell SL, Lorenzi H, Caler E, Crabtree J, Angiuoli SV, Merino EF, Amedeo P, Cheng Q, Coulson RM, Crabb BS, Del Portillo HA, Essien K, Feldblyum TV, Fernandez-Becerra C, Gilson PR, Gueye AH, Guo X, Kang'a S, Kooij TW, Korsinczky M, Meyer EV, Nene V, Paulsen I, White O, Ralph SA, Ren Q, Sargeant TJ, Salzberg SL, Stoeckert CJ, Sullivan SA, Yamamoto MM, Hoffman SL, Wortman JR, Gardner MJ, Galinski MR, Barnwell JW, Fraser-Liggett CM 2008. Comparative genomics of the neglected human malaria parasite *Plasmodium vivax*. *Nature* 455: 757-763.
- Carvalho BO, Lopes SC, Nogueira PA, Orlandi PP, Bargieri DY, Blanco YC, Mamoni R, Leite JA, Rodrigues MM, Soares IS, Oliveira TR, Wunderlich G, Lacerda MV, del Portillo HA, Araujo MO, Russell B, Suwanarusk R, Snounou G, Renia L, Costa FT 2010. On the cytoadhesion of *Plasmodium vivax*-infected erythrocytes. *J Infect Dis* 202: 638-647.
- Chitnis CE, Sharma A 2008. Targeting the *Plasmodium vivax* Duffy-binding protein. *Trends Parasitol* 24: 29-34.
- Clark IA, Alleva LM 2009. Is human malarial coma caused, or merely deepened, by sequestration? *Trends Parasitol* 25: 314-318.
- Clark IA, Chaudhri G 1988. Tumour necrosis factor may contribute to the anaemia of malaria by causing dyserythropoiesis and erythrophagocytosis. *Br J Haematol* 70: 99-103.
- Combes V, Coltel N, Faille D, Wassmer SC, Grau GE 2006. Cerebral malaria: role of microparticles and platelets in alterations of the blood-brain barrier. *Int J Parasitol* 36: 541-546.
- Corbett CE, Duarte MI, Lancellotti CL, Silva MA, Andrade Junior HF 1989. Cytoadherence in human *falciparum* malaria as a cause of respiratory distress. *J Trop Med Hyg* 92: 112-120.
- Cowman AF, Crabb BS 2006. Invasion of red blood cells by malaria parasites. *Cell* 124: 755-766.
- David PH, Handunnetti SM, Leech JH, Gamage P, Mendis KN 1988. Rosetting: a new cytoadherence property of malaria-infected erythrocytes. *Am J Trop Med Hyg* 38: 289-297.
- del Portillo HA, Fernandez-Becerra C, Bowman S, Oliver K, Preuss M, Sanchez CP, Schneider NK, Villalobos JM, Rajandream MA, Harris D, Pereira da Silva LH, Barrell B, Lanzer M 2001. A superfamily of variant genes encoded in the subtelomeric region of *Plasmodium vivax*. *Nature* 410: 839-842.
- del Portillo HA, Lanzer M, Rodriguez-Malaga S, Zavala F, Fernandez-Becerra C 2004. Variant genes and the spleen in *Plasmodium vivax* malaria. *Int J Parasitol* 34: 1547-1554.
- Field JW, Sandosham AA, Fong YL 1963. *The microscopic diagnosis of human malaria*, The Government Press, Kuala Lumpur, p. 20-117.
- Gardner MJ, Hall N, Fung E, White O, Berriman M, Hyman RW, Carlton JM, Pain A, Nelson KE, Bowman S, Paulsen IT, James K, Eisen JA, Rutherford K, Salzberg SL, Craig A, Kyes S, Chan MS, Nene V, Shallom SJ, Suh B, Peterson J, Angiuoli S, Pertea M, Allen J, Selengut J, Haft D, Mather MW, Vaidya AB, Martin DM, Fairlamb AH, Fraunholz MJ, Roos DS, Ralph SA, McFadden GI, Cummings LM, Subramanian GM, Mungall C, Venter JC, Carucci DJ, Hoffman SL, Newbold C, Davis RW, Fraser CM, Barrell B 2002. Genome sequence of the human malaria parasite *Plasmodium falciparum*. *Nature* 419: 498-511.
- Grau GE, Mackenzie CD, Carr RA, Redard M, Pizzolato G, Allasia C, Cataldo C, Taylor TE, Molyneux ME 2003. Platelet accumulation in brain microvessels in fatal pediatric cerebral malaria. *J Infect Dis* 187: 461-466.
- Guerra CA, Hay SI, Lucioparedes LS, Gikandi PW, Tatem AJ, Noor AM, Snow RW 2007. Assembling a global database of malaria parasite prevalence for the Malaria Atlas Project. *Malaria J* 6: 17.
- Guerra CA, Howes RE, Patil AP, Gething PW, Van Boeckel TP, Temperley WH, Kabaria CW, Tatem AJ, Manh BH, Elyazar IR, Baird JK, Snow RW, Hay SI 2010. The international limits and population at risk of *Plasmodium vivax* transmission in 2009. *PLoS Negl Trop Dis* 4: e774.
- Hasler T, Albrecht GR, Van Schravendijk MR, Aguiar JC, Morehead KE, Pasloske BL, Ma C, Barnwell JW, Greenwood B, Howard RJ 1993. An improved microassay for *Plasmodium falciparum* cytoadherence using stable transformants of Chinese hamster ovary cells expressing CD36 or intercellular adhesion molecule-1. *Am J Trop Med Hyg* 48: 332-347.
- Hay SI, Guerra CA, Tatem AJ, Noor AM, Snow RW 2004. The global distribution and population at risk of malaria: past, present, and future. *Lancet Infect Dis* 4: 327-336.

- Kitchen SK 1938. The infection of reticulocytes by *Plasmodium vivax*. *Am J Trop Med Hyg* 18: 347.
- Kochar DK, Das A, Kochar A, Middha S, Acharya J, Tanwar GS, Gupta A, Pakalapati D, Garg S, Saxena V, Subudhi AK, Boopathi PA, Sirohi P, Kochar SK 2010. Thrombocytopenia in *Plasmodium falciparum*, *Plasmodium vivax* and mixed infection malaria: a study from Bikaner (Northwestern India). *Platelets* 21: 623-627.
- Kochar DK, Das A, Kochar SK, Saxena V, Sirohi P, Garg S, Kochar A, Khatri MP, Gupta V 2009. Severe *Plasmodium vivax* malaria: a report on serial cases from Bikaner in northwestern India. *Am J Trop Med Hyg* 80: 194-198.
- Kochar DK, Saxena V, Singh N, Kochar SK, Kumar SV, Das A 2005. *Plasmodium vivax* malaria. *Emerg Infect Dis* 11: 132-134.
- Krotoski WA 1985. Discovery of the hypnozoite and a new theory of malarial relapse. *Trans R Soc Trop Med Hyg* 79: 1-11.
- Lacerda MV, Hipolito JR, Passos LN 2008. Chronic *Plasmodium vivax* infection in a patient with splenomegaly and severe thrombocytopenia. *Rev Soc Bras Med Trop* 41: 522-523.
- Lomar AV, Vidal JE, Lomar FP, Barbas CV, Matos GJ, Boulous M 2005. Acute respiratory distress syndrome due to *vivax* malaria: case report and literature review. *Braz J Infect Dis* 9: 425-430.
- Lou J, Donati YR, Juillard P, Giroud C, Vesin C, Mili N, Grau GE 1997. Platelets play an important role in TNF-induced microvascular endothelial cell pathology. *Am J Pathol* 151: 1397-1405.
- Maegraith BG 1948. *Pathological processes in malaria and blackwater fever*, Charles C Thomas, Springfield, 430 pp.
- Mendis K, Sina BJ, Marchesini P, Carter R 2001. The neglected burden of *Plasmodium vivax* malaria. *Am J Trop Med Hyg* 64: 97-106.
- Mercereau-Puijalon O, Menard D 2010. *Plasmodium vivax* and the Duffy antigen: a paradigm revisited. *Transfus Clin Biol* 17: 176-183.
- Miller LH, Baruch DI, Marsh K, Doumbo OK 2002. The pathogenic basis of malaria. *Nature* 415: 673-679.
- Miller LH, Good MF, Milon G 1994. Malaria pathogenesis. *Science* 264: 1878-1883.
- Mueller I, Galinski MR, Baird JK, Carlton JM, Kochar DK, Alonso PL, del Portillo HA 2009. Key gaps in the knowledge of *Plasmodium vivax*, a neglected human malaria parasite. *Lancet Infect Dis* 9: 555-566.
- Pasternak ND, Dzikowski R 2009. PfEMP1: an antigen that plays a key role in the pathogenicity and immune evasion of the malaria parasite *Plasmodium falciparum*. *Int J Biochem Cell Biol* 41: 1463-1466.
- Price RN, Tjitra E, Guerra CA, Yeung S, White NJ, Anstey NM 2007. *Vivax* malaria: neglected and not benign. *Am J Trop Med Hyg* 77: 79-87.
- Resende M, Ditlev SB, Nielsen MA, Bodevin S, Bruun S, Pinto VV, Clausen H, Turner L, Theander TG, Salanti A, Dahlback M 2009. Chondroitin sulphate A (CSA)-binding of single recombinant duffy-binding-like domains is not restricted to *Plasmodium falciparum* erythrocyte membrane protein 1 expressed by CSA-binding parasites. *Int J Parasitol* 39: 1195-1204.
- Santos-Ciminera PD, Alecrim MG, Roberts DR, Quinnan GV Jr 2007. Molecular epidemiology of *Plasmodium vivax* in the state of Amazonas, Brazil. *Acta Trop* 102: 38-46.
- Smith JD, Chitnis CE, Craig AG, Roberts DJ, Hudson-Taylor DE, Peterson DS, Pinches R, Newbold CI, Miller LH 1995. Switches in expression of *Plasmodium falciparum* var genes correlate with changes in antigenic and cytoadherent phenotypes of infected erythrocytes. *Cell* 82: 101-110.
- Su XZ, Heatwole VM, Wertheimer SP, Guinet F, Herrfeldt JA, Peterson DS, Ravetch JA, Wellem TE 1995. The large diverse gene family var encodes proteins involved in cytoadherence and antigenic variation of *Plasmodium falciparum*-infected erythrocytes. *Cell* 82: 89-100.
- Tjitra E, Anstey NM, Sugiarto P, Warikar N, Kenangalem E, Karyana M, Lampah DA, Price RN 2008. Multidrug-resistant *Plasmodium vivax* associated with severe and fatal malaria: a prospective study in Papua, Indonesia. *PLoS Med* 5: e128.
- Trager W, Jensen JB 1976. Human malaria parasites in continuous culture. *Science* 193: 673-675.
- Udagama PV, David PH, Peiris JS, Ariyaratne YG, Perera KL, Mendis KN 1987. Demonstration of antigenic polymorphism in *Plasmodium vivax* malaria with a panel of 30 monoclonal antibodies. *Infect Immun* 55: 2604-2611.
- Udomsanpetch R, Thanikkul K, Pukrittayakamee S, White NJ 1995. Rosette formation by *Plasmodium vivax*. *Trans R Soc Trop Med Hyg* 89: 635-637.
- Valecha N, Pinto RG, Turner GD, Kumar A, Rodrigues S, Dubhashi NG, Rodrigues E, Banaulikar SS, Singh R, Dash AP, Baird JK 2009. Histopathology of fatal respiratory distress caused by *Plasmodium vivax* malaria. *Am J Trop Med Hyg* 81: 758-762.
- Wassmer SC, Lepolard C, Traore B, Pouvelle B, Gysin J, Grau GE 2004. Platelets reorient *Plasmodium falciparum*-infected erythrocyte cytoadhesion to activated endothelial cells. *J Infect Dis* 189: 180-189.
- Wassmer SC, Souza JB, Frere C, Candal FJ, Juhan-Vague I, Grau GE 2006. TGF-beta1 released from activated platelets can induce TNF-stimulated human brain endothelium apoptosis: a new mechanism for microvascular lesion during cerebral malaria. *J Immunol* 176: 1180-1184.
- Wickramasinghe SN, Looareesuwan S, Nagachinta B, White NJ 1989. Dyserythropoiesis and ineffective erythropoiesis in *Plasmodium vivax* malaria. *Br J Haematol* 72: 91-99.
- Wickramasinghe SN, Phillips RE, Looareesuwan S, Warrell DA, Hughes M 1987. The bone marrow in human cerebral malaria: parasite sequestration within sinusoids. *Br J Haematol* 66: 295-306.
- Yeo TW, Lampah DA, Tjitra E, Piera K, Gitawati R, Kenangalem E, Price RN, Anstey NM 2010. Greater endothelial activation, Weibel-Palade body release and host inflammatory response to *Plasmodium vivax*, compared with *Plasmodium falciparum*: a prospective study in Papua, Indonesia. *J Infect Dis* 202: 109-112.