

Male-to-female transsexual surgery: experience at the UFRJ University Hospital

Transgenitalização masculino / feminino: experiência do Hospital Universitário da UFRJ

TALITA FRANCO, ECBC-RJ¹; LUIZ CARLOS DE MIRANDA²; DIOGO FRANCO, TCBC-RJ³; SERGIO ZAIDHAFT⁴; MARCIA ARAN⁵

A B S T R A C T

Objective: To describe the experience of male-to-female sex reassignment surgery conducted at the Transgenitalization Program of the Clementino Fraga Filho University Hospital - UFRJ. **Methods:** The selection of patients for operation followed the evaluation of a multidisciplinary team, meeting the criteria after two years of follow-up: medical diagnosis of transsexualism, patient over 21 years, no physical characteristics unsuitable for change, support at least one close relative. **Results:** From 1997 to 2004 seventeen patients were followed, fifteen of which had confirmed transsexual condition, one was dismissed for bringing false examinations. Of the total of sixteen transsexuals, six operations were performed. The operated patients were in the age range of 25 to 40 years with an average of 31. The surgical procedure was completed without any technical difficulties in all patients. One patient had stenosis of the neo meatus and in another it was necessary to shorten the urethra. **Conclusion:** The technique provides no major difficulties in implementation, but may depend on local conditions and surgeon's creativity. The greatest difficulty is to prepare these patients so that there are neither frustrations, nor too many expectations.

Key words: Transsexualism/surgery. Transsexualism/diagnosis.

INTRODUCTION

The operations for sexual reassignment begun in 1970 when Edgerton¹ published his technique that used tissue from the penis and scrotum to mimetize the female external genitalia, including the glans penis to simulate a cervix. The biggest drawback was the need for two surgical times.

In Brazil, the first sex change operations were performed by Roberto Farina and published in 1975 with the headline: "Transsexualism: from man to normal woman through states of intersexuality and paraphilias"², with very interesting results.

In 1997, the Brazilian Federal Council of Medicine, after an important debate, issued the Resolution No. 1482/97³, authorizing, on an experimental basis at university hospitals, the performance of neocolpovulvoplasty, neophalloplasty and / or additional procedures on the gonads and secondary sexual characteristics as treatments for transsexualism. Five years later, the new Resolution No. 1652/2002⁴ authorized of male to female reassignment surgery in public or private

hospitals as long as they followed a rigid program of screening conducted by a multidisciplinary team. The female to male version remains restricted to university hospitals.

The regulator view of these operations considered them in accordance with the principles of bioethics, namely, the principle of beneficence, as it seeks the integration between body and psychological sexual identity of the person concerned and the principles of autonomy and justice, addressing the right to self-determination in one making use of one's own body and avoiding discrimination in the search for the operation now accessible to the population of middle and upper classes. In this sense, the Brazilian Federal Council of Medicine (CFM) has defined as therapeutic the surgery of the external genitalia and secondary sexual characters in the case of diagnosed transsexuals.

In view of such resolutions and demand existing in our environment towards carrying out such procedures, we decided, in 1997, to begin a program of surgical sexual reassignment. We aimed to describe

Work done at Hospital Universitário Clementino Fraga Filho da Universidade Federal do Rio de Janeiro (HUCFF – UFRJ); winner of The Ivo Pitanguy Award as the best scientific paper presented at the 44th Brazilian Congress of Plastic Surgery, November 2007.

1. Professor, Department of Surgery, Universidade Federal do Rio de Janeiro – UFRJ; Head, Plastic Surgery Service, Hospital Universitário Clementino Fraga Filho – HUCFF – Rio de Janeiro – Brazil; 2. Associate Professor, Department of Surgery, UFRJ; Surgeon, Urology Service, HUCFF – Rio de Janeiro – Brazil; 3. Associate Professor, Department of Surgery, UFRJ Surgeon, Plastic Surgery Service, HUCFF – Rio de Janeiro – Brazil; 4. Assistant Professor, Psychiatry and Forensic Medicine, UFRJ – Rio de Janeiro – Brazil; 5. Psychologist, Department of Psychology and Mental Health – HUCFF – Rio de Janeiro – Brazil.

our experience with this type of surgery with this retrospective study.

METHODS

According to our protocol, the definition of transsexualism meets at least the following criteria: discomfort with the natural anatomical sex; expressed desire to eliminate the genitals, to lose the primary and secondary features of the original gender and to gain the ones of the opposite sex; permanence of these disorders continuously and consistently for at least two years; no other mental disorders. This definition is similar to that proposed in 2000 by the American Psychiatric Association⁵.

The selection of patients for transsexualism operation followed the evaluation of a multidisciplinary team, meeting the criteria after two years: established medical diagnosis of transsexualism; patient over 21 years of age; no physical characteristics unsuitable for the change; support by at least one close relative.

Given the complexity and irreversibility of these procedures, several experts are involved, including psychiatrists, social workers, endocrinologists, geneticists, urologists and plastic surgeons. To be enrolled in the Transgenitalization Program patients should follow the steps listed in Table 1.

Surgical Technique

Patients were hospitalized the day before operation to be submitted to bowel preparation. The procedures were performed under general or epidural anesthesia. Vesical catheterization was performed immediately after anesthesia.

The surgery starts with the delimitation of a perineal flap, of posterior base, located in the projection of the ischial tuberosities. This flap is dissected from the fascial plane and is protected during the maneuvers of resection.

The scrotum is emptied by removing the testicles, but keeping up the spermatic cords and surrounding structures that are useful to give consistency to future labia majora. A circular incision is made in the contour of the glans and the penile skin is detached along its entire length, allowing the externalization of the corpora cavernosa as the corpus spongiosum remains catheterized. The corpora cavernosa are dissected and amputated, preserving small segments to be stitched together and to the pubic aponeurosis to simulate the clitoris (FigureS 1A, 1B, 1C, 1D and 1E).

To create the "vaginal tunnel", we use the technique of access to the prostate by the perineal route described by Young⁶ (1905) and modified by Belt⁷ (1942). Access to the ischium-rectal fossa is done by digital, bilateral dissection followed by incision of the perineal central tendon, preserving the structures of the external anal sphincter. The dissection progresses toward the prostate, keeping the rectum wall folded down. One can deepen the cavity by cutting the rectus-ureteral muscle and, if necessary, opening the Denonvillier's posterior fascia to reach the plan adjacent to the seminal vesicles, below the prostate. This surgical procedure requires care, since, in addition to profuse bleeding, there is the risk of rectal injury (Figures 2A and 2B).

Two stitches with 3-0 mononylon are applied, one at each side of the prostate, at the bottom of this tunnel, and are left fixed for later use in fixating the neovagina.

The empty penis involucrem is incised longitudinally on its ventral surface, resulting in a rectangular patch of upper base to be sutured to the posterior perineal flap base, prepared at the beginning of the operation. At the base of the penile flap is made a small hole through which will pass the corpus spongiosum containing the urethra that has not yet been shortened. The resulting cylinder of sutured skin flaps is reversed and its end inserted into the dissected tunnel in the retro-vesical space. The fixed 3-0 mononylon stitches in the bottom end of the tunnel are

Tabela 1 - Interdisciplinary Care Routine

-
- Triage
 - Spontaneous search or referral for sex reassignment surgery
 - Evaluation in Psychiatric and Mental Health clinic
 - Interview to assess and clarify the features of the Program in accordance with the criteria established by the Brazilian Federal Council of Medicine
 - Opening of the Medical Record
 - Interview with Social Service
 - Evaluation by the Endocrinology Service
 - Referral for Psychotherapy in the Mental Health Clinic
 - Evaluation by the Urology Service
 - Evaluation by the Plastic Surgery Service
 - Agreement and signing of the Instrument of Consent
 - Realization of the sex reassignment surgery
 - Postoperative follow-up for at least six months
-

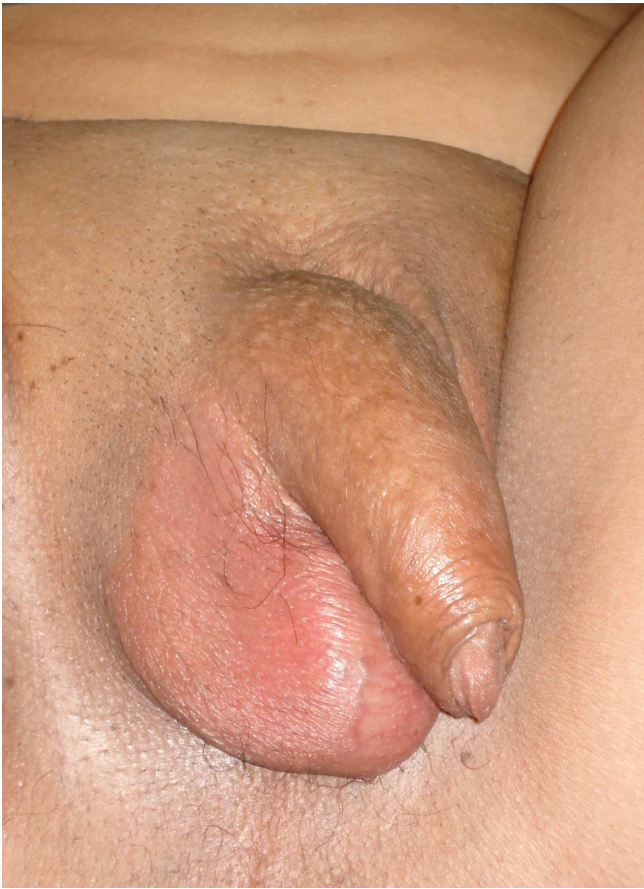

Figure 1-A - Preoperative aspect.

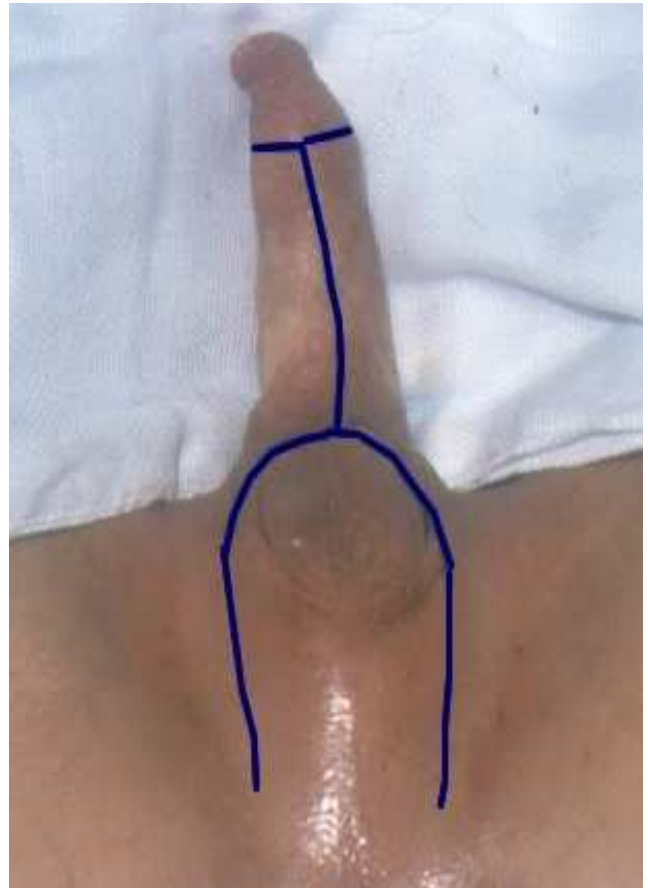


Figure 1-B - Marking of the flaps.

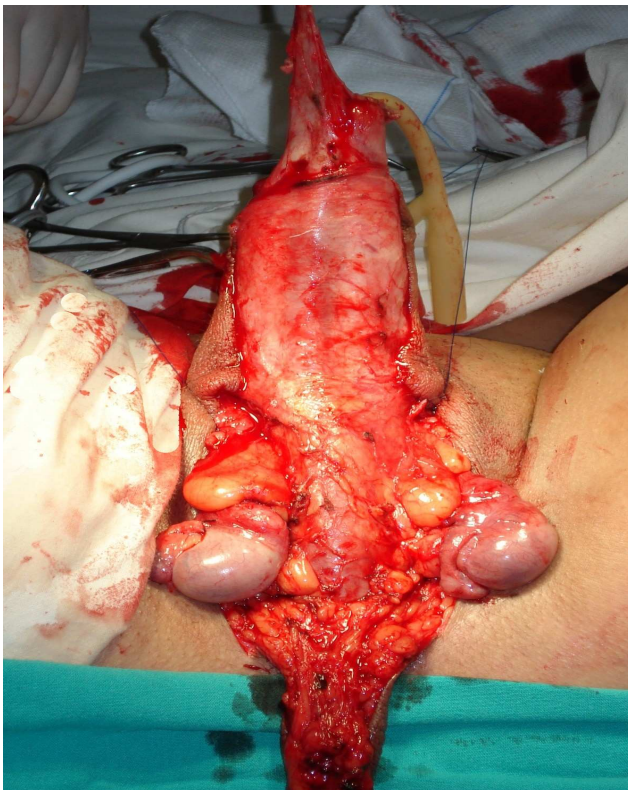

Figure 1-C - Exposure of the testes and the corpora cavernosa and spongiosum before resection.

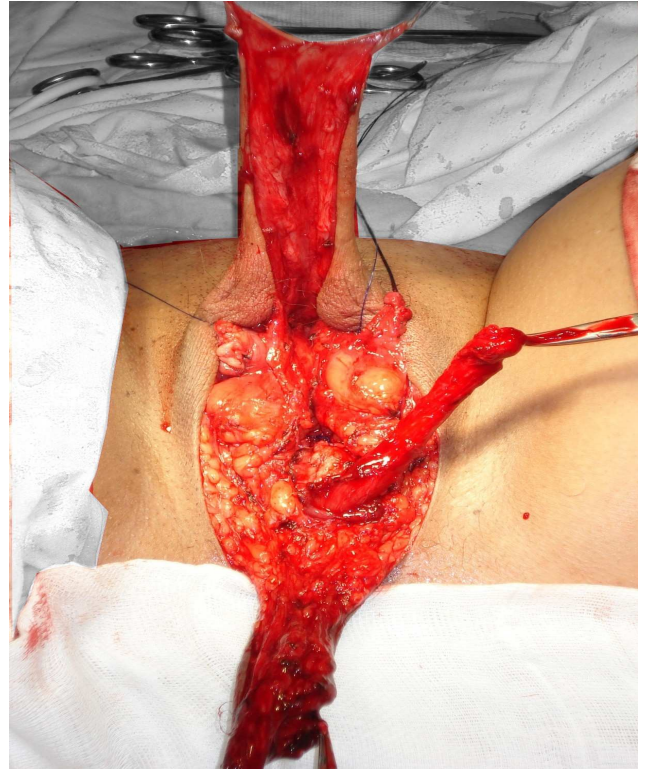


Figure 1-D - Testes and corpora cavernosa have been resected; the urethra is repaired; the front and rear flaps which will be stitched together to form the neovagina.

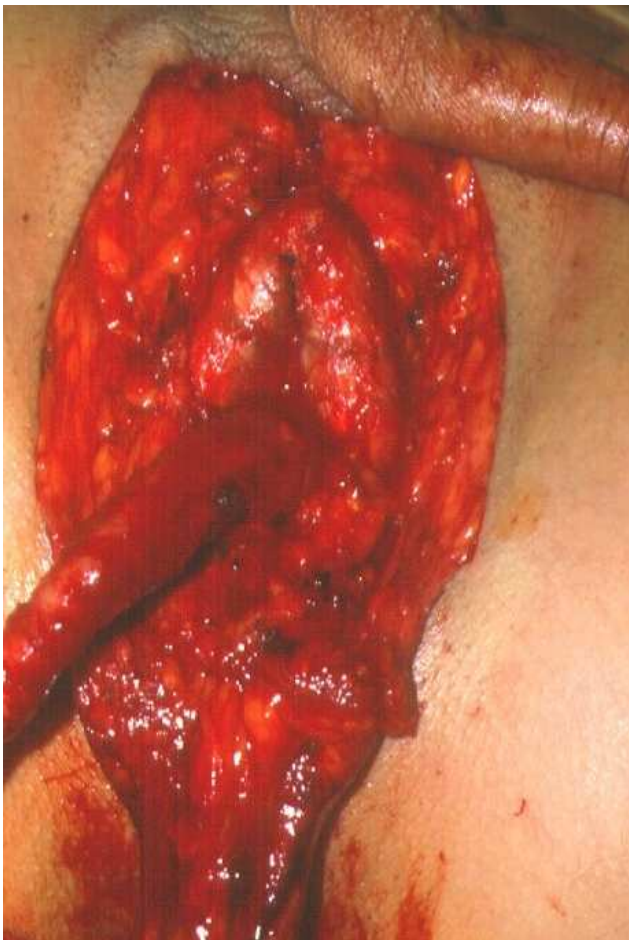


Figure 1-E - Small segments of the cavernous bodies are preserved and fixed to the pubic aponeurosis to simulate a clitoris.

also applied to the inverted flap ensuring adherence and persistence of depth of the neo-vagina. The shortening of the urethra is under slight tension in order to depress the central basis of the superior flap, which will make the soft parts of its contour simulate the labia minora. The skin of the scrotum is modeled to reproduce the labia that are filled with the tissues of the spermatic cords. A horizontal mattress stitch is applied to the skin in the midline at the upper end of the neo-vulva, approaching the deep tissues; it contributes to give form to the anterior commissure. At the end of the procedure a rubber foam mold covered by a condom is placed in the cavity. Local edema is often marked in the first week (Figures 3A, 3B, 3C, 3D and 3E). The catheter is maintained until the seventh day after surgery and the mold should be used for at least two months. Vaginal intercourse is allowed from this period on.

RESULTS

From 1997 to 2004 seventeen people were treated, referred by other Departments of the Hospital

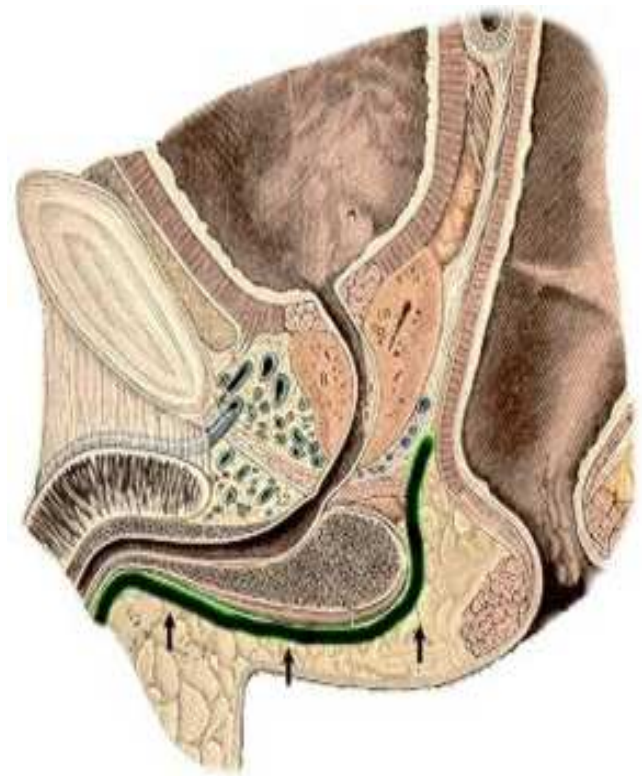


Figure 2-A - Sagittal section showing the path described by dissection for building the neovaginal cavity.

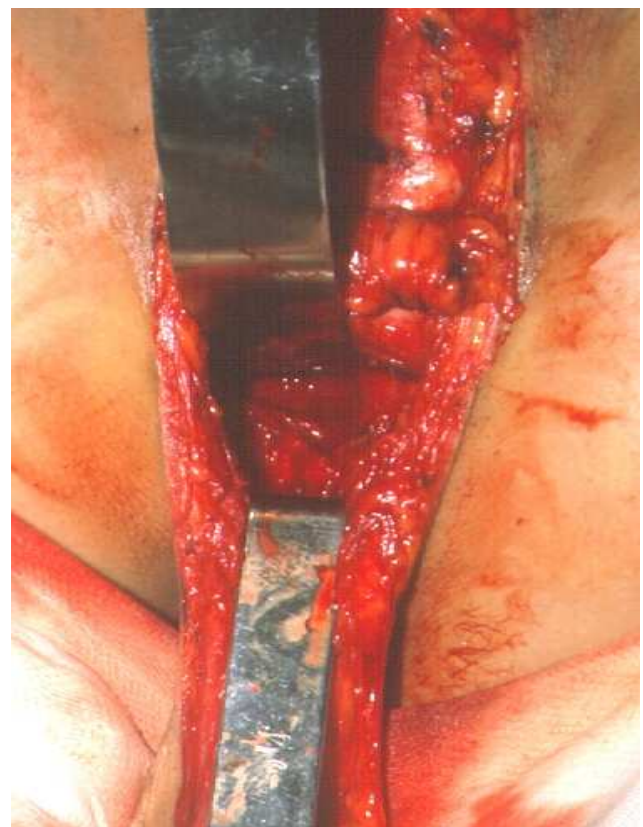


Figure 2-B - Aspect of the wide prepared tunnel.

(Internal Medicine, Endocrinology and Urology) or indicated by patients who were already in attendance. Of these, fifteen had the transsexual condition confirmed and one, referred due to the possibility of hermaphroditism, was dismissed for bringing false exams. Of the total of sixteen transsexuals, six operations were performed, there was a withdrawal, three dropouts, a refusal to be included in the program for being a minor, one individual came to the program already operate in another country (psychiatric assessment in order to change name), and four patients are in the waiting list. The operated patients were in the range of 25 to 40 years with an average of 31 years.

The surgical procedure could be successfully completed without technical difficulties in all patients. The aesthetic result was considered excellent by all of them, who were very satisfied not only with the ablation of male genitalia, but also with the aesthetic appearance of the new one (Figures 4A, 4B and 5A, 5B). In one case it was necessary to shorten the urethra a little more, as it was still protruding between the labia.

There was a need for volume replacement in one patient due to intraoperative blood loss at the surgical time of amputation of the corpora cavernosa; this patient already had low hemoglobin preoperatively.

One patient had traumatic dehiscence of the posterior flap of the neo-vagina in the seventh postoperative day; it was resutured and the patient evolved well. The trauma was due to inadvertent maneuvers during the exchange of the mold. One patient evolved with stenosis of the neo meatus and underwent meatotomy for correction of the stenosis.

DISCUSSION

The term transsexual was first used in 1953 by Harry Benjamin⁸, who examined various aspects of sexuality and concluded that "the homosexual has a sexual problem, the transvestite has a social problem and the transsexual has a gender problem." With the growing acceptance of the right of every man for his sexuality the three "problems" mentioned by Harry Benjamin might be restricted, in the future, only to the third. It will take some time for this type of procedure to be seen with ease, especially for being radical and irreversible. On the one hand it is good to be so. Such a decision requires time and specialized care, so that the good surgical outcome is only part of a general restructuring of the person with a happy ending. The authorization of the CFM⁴ for this operation to be done in private clinics may cause future problems if the steps recommended before reassignment surgery are not followed, especially psychiatric supervision for two years. It is also necessary that the legal issues become more agile, since the change of official documentation is difficult and complicated, leading to embarrassing situations and financial losses.

Paradoxically, it is easier to build an external genitalia of female characteristics during sexual reassignment surgery than to rebuild it in malformations or diseases of female patients. The large amount of tissue remaining after emptying the penis and scrotum offers excellent conditions for the construction of the vagina and vulva, which does not occur in women with genital alterations.

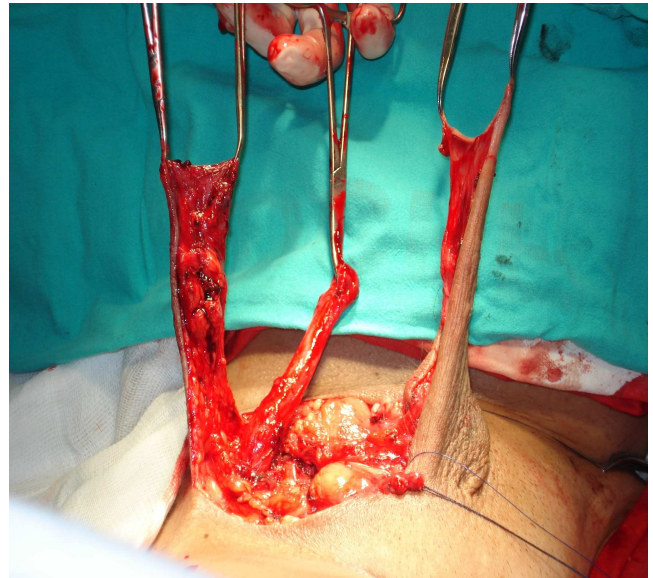


Figure 3-A - After the resection; the penile flap is on the left, perineal the flap on the right and the urethra in the middle.

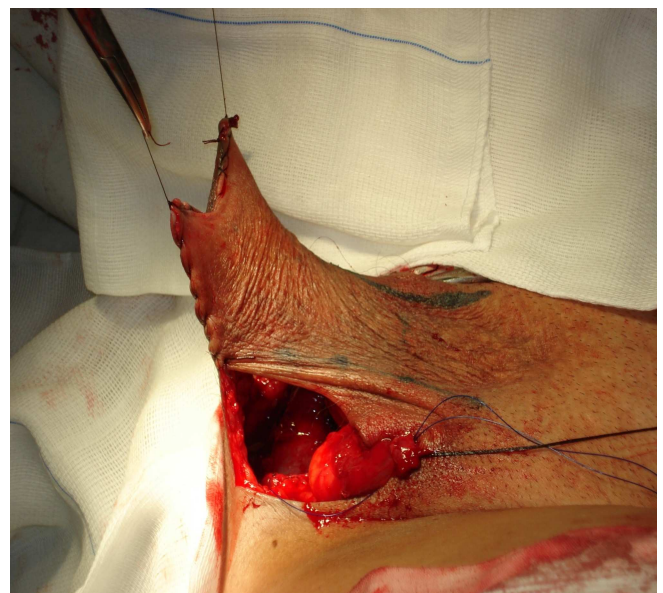


Figure 3-B - The penile flap is sutured to the perineal flap into a dead-end tube, which will be inverted and inserted into the vesico-rectal space to line their walls. The urethra is repaired, awaiting the construction of an orifice at the base of the penile flap to its exteriorization.

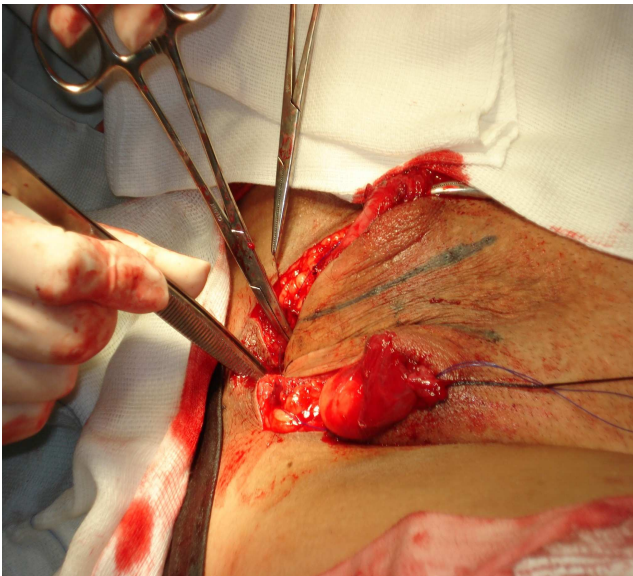


Figure 3-C - The tubular flap is inserted into the tunnel with the aid of two clamps and it will be fixed to the end of it by the two previously prepared stitches.

The technique has some predetermined time periods that do not offer major difficulties in their execution and others entirely dependent on local conditions and the surgeon's creativity.

The removal of the corpora cavernosa and testis shows no major technical problems because the cleavage planes are well marked. The construction of the tunnel in the recto-vesical space requires greater skill and experience of the surgeon, whose practice derives from the radical prostatectomy by the perineal route. The perineal and penile flaps' sutures to form the neo-vagina demand adequate evaluation of its length and width to achieve anatomical and functional dimensions. The length will always be dependent on the location of the prostate, whose removal is not recommended because it increases morbidity and prevents adequate fixation to the bottom of the neo-vagina. It is curious the fantasy of patients in relation to the depth of the normal vagina, known to range between 8 and 10 cm, but mentioned as being expected to be 16 to 24 cm. The complaint of an improper depth to the expectation of the patient is frequent. This must be addressed preoperatively to avoid inconvenience, both emotional and functional, in the postoperative period.

The shortening of the urethra should be enough that there persists a projection that resembles a residual penis, but not so detrimental to proper healing and urination. In one patient, reoperation for further shortening of the urethra was required. As mentioned earlier, the shorter urethra causes a depression in the midline and renders the tissues in its surroundings to resemble the labia minora.

Our series is too small to discuss complications. Edgerton¹ says, rightly, that "only a randomized study of patients followed for 10 to 20 years could determine

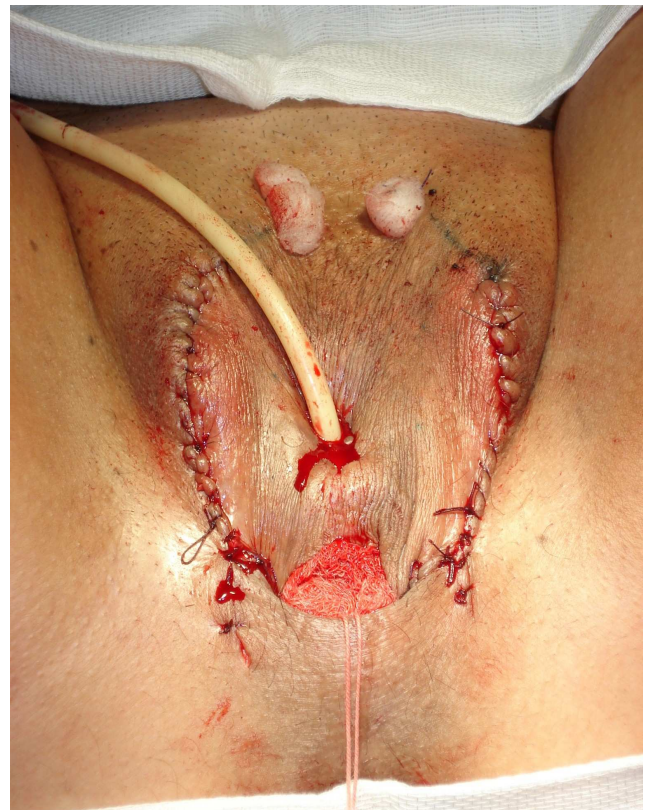

Figure 3-D - Aspect at the end of the procedure.

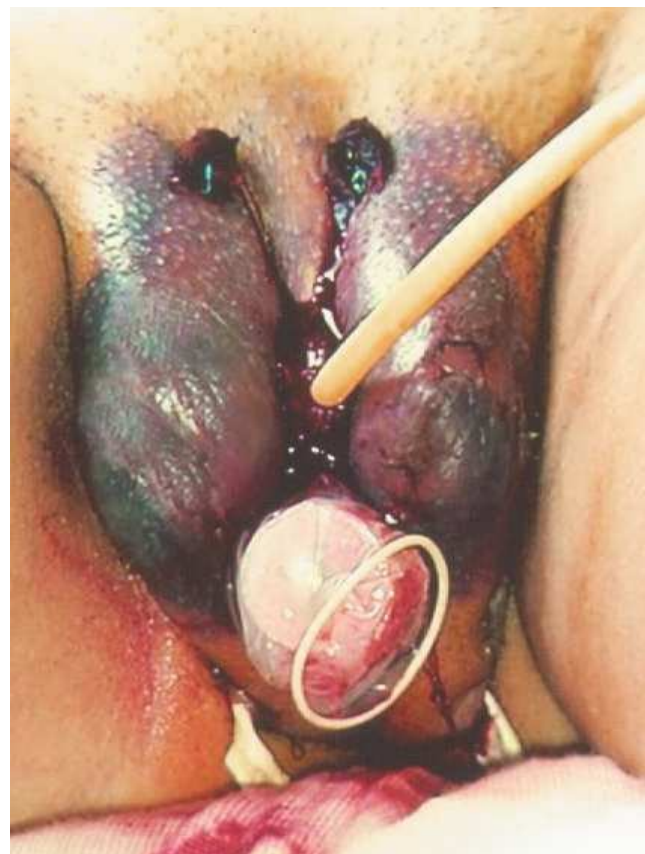

Figure 3-E - Marked edema evident on first postoperative day.

whether this surgical procedure has met the needs of transsexual patients.”

Larger series⁹ reported stenosis of the neo-vagina or urethral opening and growth of the vaginal canal as the most frequent late complications. Stenosis of the neo meatus is predicted, but it occurs in a smaller scale when a circular skin excision is made for implanting the urethra. One patient had stenosis of the neo canal, whose correction, meatotomy at six hours (posterior), was performed at the office under local anesthesia in the second month after the operation.

Fang et al.¹⁰ pointed out that the male sub-pubic angle is more closed than the female and the neovagina is naturally compressed by the pubis. Psychiatric disorders are possible at all pre and post-operative stages and patients should be monitored closely during a long time¹¹.

Post-operative counseling should help patients adapt to their new condition. The relationship, before the operation, with a partner who agreed with the intervention itself may end or change. The passage from routine, satisfying and easier anal intercourse, to a vaginal one without moisture and whose axis is not exactly the one of a normal woman, is not without difficulty. Moreover, such radical a change, even with pre-operative support of the partner, can upset the delicate balance relationships are made of. It is common the end of the relationship or the persistence of anal sex with sporadic use of vaginal intercourse. In one of our patients an impasse ensued: the partner could not get an erection if the intercourse was to be vaginal and she would no more accept the anal one. None of the patients with whom this marital mismatch occurred regretted having been submitted to the procedure. On the other hand, some patients had never had a partner, which confirms the idea that the pursuit of sex reassignment surgery is much more of an issue linked to personal identity than to sexual activity.

Some patients, in order to accentuate the female features, may request breast augmentation, rhinoplasty, liposuction and lowering of the projection of the thyroid cartilage, but these operations can only be done a few months after the reassignment.

The phenotype of patients is becoming increasingly female, with another way to walk, new haircut and more daring dressings. It is important that they be oriented to avoid excesses. Exaggerating in supposedly feminine mannerisms which women do not use in reality renders an opposing effect. The new person who comes after the reassignment need not nor should appear more womanly than normal women. Some remnants of masculinity, as traces of a beard, large hands and feet and a deep voice accentuate the contrast against the stereotyped actions.

The endocrinological monitoring of these patients is of great importance, especially since most typically use estrogen for years without medical supervision. Asscheman et al.¹² reported thromboembolic events in up to 12% of



Figure 4-A - Postoperative period – five years.

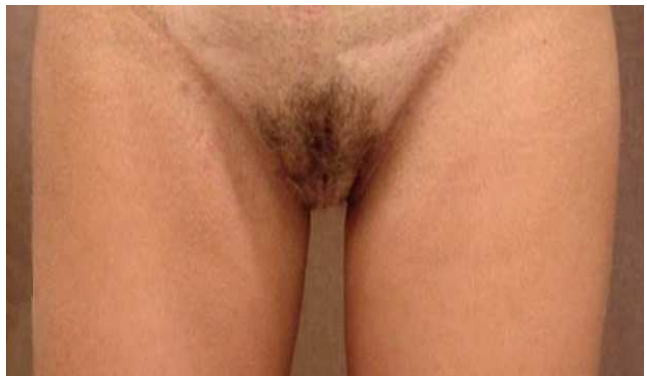

Figure 4-B - Late postoperative aspect: the standing position.

patients over 40 years who underwent reassignment. Hyperprolactinemia is a common finding, although prolactinomas are rare. Moore et al¹³ recommend holding periodic densitometry for control of bone mass after castration, although the use of estrogen compensates for the deprivation of testosterone.

One aspect that should also be discussed with patients is the definitive loss of fertility and the possibility to store frozen sperm before hormonal therapy and surgery.

A very interesting psychological effect occurs when we send patients to a gynecologist in order to guide them in relation to methods of vaginal lubrication and to



Figure 5-A - Preoperative aspect.

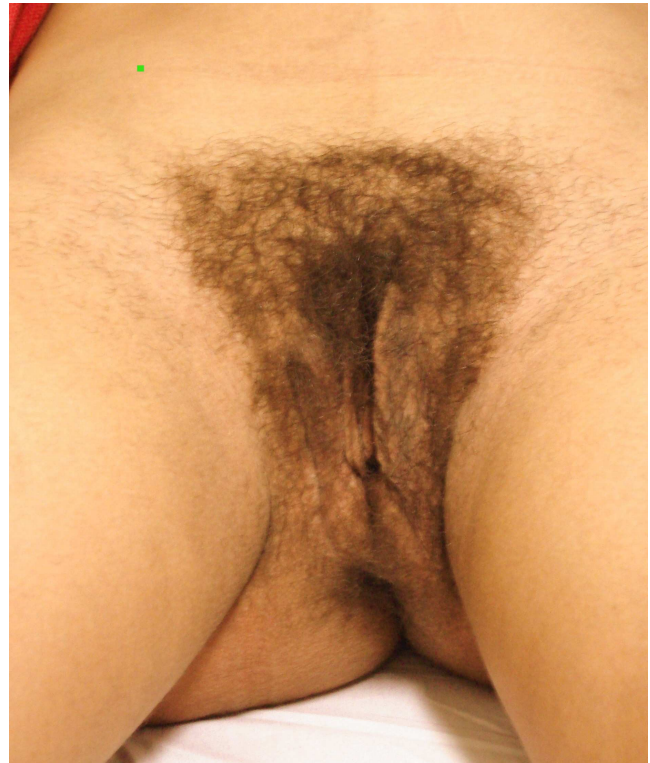

Figure 5-B - Postoperative – 18 months.

control the breast that may have received high doses of estrogen or silicone injections done by laymen. This is the time of her effective acknowledgment as a woman and provides as much satisfaction as the placement of breast implants, only lower than the time the new documentation

of identity and name are registered. In 2009 we resumed operations after a long period of time because of the priorities taken by the new needs of our Hospital. We did not include cases for a short period of observation, but we should follow increasing our sample.

R E S U M O

Objetivo: Mostrar a experiência do tratamento cirúrgico do transexualismo (masculino/feminino) realizado no Programa de Transgenitalização do Hospital Universitário Clementino Fraga Filho, - UFRJ. **Métodos:** A seleção dos pacientes para operação de transexualismo obedeceu à avaliação de equipe multidisciplinar, atendendo aos critérios definidos, após dois anos de acompanhamento conjunto: diagnóstico médico de transexualismo; paciente maior de 21 anos; ausência de características físicas inapropriadas para a mudança; apoio de pelo menos um familiar próximo. **Resultados:** De 1997 a 2004 foram atendidas dezessete, pessoas quinze confirmaram a condição transexual, uma foi afastada por ter trazido exames falsos. Do total de dezesseis transexuais, foram realizadas seis operações. As pacientes operadas situavam-se na faixa de 25 a 40 anos com média de 31 anos. O procedimento cirúrgico foi concluído sem dificuldades técnicas em todas as pacientes. Uma paciente apresentou estenose do neo meato e em outra foi necessário encurtar um pouco mais a uretra. **Conclusão:** A técnica operatória não oferece maiores dificuldades em sua execução, mas pode depender das condições locais e da criatividade do cirurgião. A dificuldade maior está em preparar estes pacientes para que não haja frustrações ou expectativas demasiadas.

Descritores: Transexualismo/cirurgia. Transexualismo/diagnóstico.

REFERENCES

1. Resolução n.º 482/97 do Conselho Federal de Medicina, publicada no D.O.U. de 19 de setembro de 1997, p. 20.944, Brasília.
2. Resolução n.º. 1652/02 do Conselho Federal de Medicina, publicada no D.O.U. de 06 de novembro de 2002, Brasília.
3. American Psychiatric Association. Diagnosis and statistical manual of mental disorders. 4th edition. Washington DC: American Psychiatric Association; 2000.
4. Young HH. The early diagnosis and radical cure of carcinoma of the prostate: being a study of 40 cases and presentation of a radical operation which was carried out in four cases. Bull John Hopkins Hosp. 1905;16:315-22.

5. Belt E. Radical perineal prostatectomy in early carcinoma of the prostate. *J Urol.* 1942;48(2):287-97.
6. Edgerton MT, Bull J. Surgical construction of the vagina and labia in male transsexuals. *Plast Reconstr Surg.* 1970;46(6):529-39.
7. Huang TT. Twenty years of experience in managing gender dysphoric patients: I. Surgical management of male transsexuals. *Plast Reconstr Surg.* 1995;96(4):921-30; discussion 931-4.
8. Fang RH, Chen TJ, Chen TH. Anatomic study of vaginal width in male-to-female transsexual surgery. *Plast Reconstr Surg.* 2003;112(2):511-4.
9. Wolf SR, Knorr NJ, Hoopes JE, Meyer E. Psychiatric aspects of transsexual surgery management. *J Nerv Ment Dis.* 1968;147(5):525-31.
10. Benjamin H. The transsexual phenomenon. IJT Electronic Books: Symposion Publishing; 1953. Available from: www.symposion.com/ijt/benjamin/index.htm
11. Farina R. *Transexualismo: do homem à mulher normal dos estados de intersexualidade e das parafilias.* São Paulo: Novolunar; 1982.
12. Asscheman H, Gooren LJG, Eklund PL. Mortality and morbidity in transsexual patients with cross-gender hormone treatment. *Metabolism.* 1989;38(9):869-73.
13. Moore E, Wiesniewski A, Dobs A. Endocrine treatment of transsexual people: a review of treatment regimens, outcomes, and adverse effects. *J Clin Endocrinol Metab.* 2003;88(8):3467-73.

Received 21/09/2009

Accepted for publication 19/12/2009

Conflict of interest: none

Source of funding: none

How to cite this article:

Franco T, Miranda LC, Franco D, Zaidhaft S, Aran M. Male-to-female transsexual surgery: experience at the UFRJ University Hospital. *Rev Col Bras Cir.* [periódico na Internet] 2010; 37(6). Disponível em URL: <http://www.scielo.br/rcbc>

Correspondence to:

Dr. Talita Franco

E-mail: talita@openlink.com.br