

# Liver and peritoneal biopsy by laparoscopy or notes in pigs: comparison of operative parameters and postoperative evolution

## *Biópsia hepática e peritoneal por laparoscopia ou por notes em suínos: comparação de parâmetros operatórios e evolução pós-operatória*

CHRISTIANO MARLO PAGGI CLAUS<sup>1</sup>; EDUARDO AIMORÉ BONIN, ACBC-PR<sup>1</sup>; MARIA FERNANDA TORRES<sup>2</sup>; ANTONIO CARLOS LIGOCKI CAMPOS, TCBC-PR<sup>3</sup>; ANTONIO MORIS CURY<sup>1</sup>; JULIO CESAR UILI COELHO, TCBC-PR<sup>4</sup>

### A B S T R A C T

**Objective:** To evaluate the impact of NOTES compared to laparoscopic surgery, through the analysis of physiological parameters as well as surgical complications and postoperative outcome, for liver biopsy. **Methods:** 12 female pigs were divided into two groups: laparoscopy group (GLap) and NOTES group (GNote). The animals underwent liver biopsy by peritoneal laparoscopy or transvaginal endoscopy. The respiratory rate, heart rate, O<sub>2</sub> saturation and expiratory concentrations of CO<sub>2</sub> were recorded every 10 minutes. In the seventh postoperative day, the animals underwent laparotomy for evaluation of intra-abdominal complications. **Results:** Most of the animals showed weight loss after the procedure, however in no case more than 5%. There was no difference in percentage change in weight between the groups ( $p = 0.7535$ ). Also, no differences were observed when comparing the averages of ETCO<sub>2</sub> ( $p = 0.4762$ ), and average heart rate ( $p = 0.6035$ ). However, the GLap showed higher respiratory rate than the GNote ( $p = 0.0043$ ), as well as the average O<sub>2</sub> saturation ( $p = 0.0080$ ). However, no animal showed SatO<sub>2</sub> less than 87% and this difference was not considered clinically significant. Only one GNote animal presented with an operative complication. **Conclusion** NOTES is associated with physiological parameters similar to those found in operative laparoscopy. Performing transvaginal peritonioscopy is not associated with increased postoperative complications when compared to laparoscopy.

**Key words:** Biopsy. Natural orifice endoscopic surgery. Natural orifice endoscopic surgery / complications. Laparoscopy. pigs

### INTRODUCTION

The advent of minimally invasive surgery (MIS) represented an important progress in the surgical area. The traditional assumption that large problems require large surgical incisions for adequate treatment is no longer valid. One goal of MIS is to reduce the magnitude of surgical trauma when compared to traditional surgical technique. The reduction of local and systemic response to injury produces physiological, immunological and clinical benefits. The advantages are less postoperative pain and length of hospital stay, lower rate of complications and reduced recovery time, and better cosmetic effect compared to the corresponding open surgery.

Recently, the search for improvements to further reduce surgical trauma brought up the surgery through natural orifices. The concept of the operation

without scarring always fascinated patients and surgeons. It is with this goal that transluminal endoscopic surgery natural orifices (NOTES) – terminology devoted of Natural Orifice Transluminal Endoscopic English Surgery – has developed<sup>1</sup>.

The central principle of NOTES is the passage of a flexible endoscope through natural orifices of the body, perforation of an organ, and performance of the operation without violating the integrity of the abdominal wall. Besides the best aesthetic effect, the absence of incisions in the abdominal wall may be associated with less postoperative pain and reduced risk of complications related to surgical incision, such as wound infection or incisional hernia. Nevertheless, many technical limitations are evident. The main one is the opening intentionally performed in a potentially infected organ or structure, which contradicts the principles of sterile surgery. Thus, NOTES would have

Work done at the Instituto Jacques Perissat (IJP) - Universidade Positivo, Curitiba, Paraná, Brazil.

1. Coordinator, Postgraduate Course in Minimally Invasive Surgery, Instituto Jacques Perissat (IJP), Universidade Positivo - Curitiba - PR-BR; 2. Veterinarian; Assistant Professor, Anatomy and Physiology, Universidade Positivo - Curitiba - PR-BR; 3. Professor; Coordinator, Postgraduation in Clinical Surgery, Universidade Federal do Paraná, Curitiba - PR-BR; 4. Professor; Head, Digestive Surgery, Universidade Federal do Paraná - Curitiba - PR-BR.

infectious and immune consequences that are not present in conventional surgery or laparoscopy. The non appropriate closure or failure in healing of the opening also pose risk of complications<sup>2</sup>.

The objective of this study is to evaluate physiological parameters, postoperative complications and postoperative outcome in pigs undergoing transvaginal endoscopic operation to remove fragments of liver and peritoneal tissues and compare them to laparoscopic operation.

## METHODS

We used 12 female adult pigs (*Sus domesticus scrofa*, *mammalia*) weighing between 40 and 46 kilograms (kg). After 48 hours of acclimatization, pigs were weighed and divided into two groups each, comprising six animals: laparoscopy group (GLap) and transvaginal endoscopic surgery group (GNote).

### Surgical Procedure

All animals were weighed before the procedure, fasted for 12 hours and the water was removed six hours before surgery. Antibiotics were administered intravenously in all animals (1000 mg ampicillin + 500mg sulbactam).

As premedication, an intramuscular injection of 14mg/kg of ketamine, 2mg/kg of xylazine and 0.4 mg / kg acepromazine was administered. After five to ten minutes, anesthesia was induced by intravenous injection of 10mg/kg of 2.5% thiopental. After the total loss of reflexes, the animals received intravenous propofol (1-3mg/kg/EV), followed by endotracheal intubation. Anesthesia was maintained with isoflurane (2%) and oxygen gas (600 ml/min). The O<sub>2</sub> saturation (SatO<sub>2</sub>), end-tidal CO<sub>2</sub> concentration (ETCO<sub>2</sub>), heart rate (HR) and respiratory rate (RR) were analyzed throughout the procedure. The intra-abdominal

pressure was maintained with an automatic insufflator, regulated to maintain intra-abdominal pressure at 10 mmHg.

In the animals of GLap pneumoperitoneum was performed with injection of carbon dioxide per blind puncture technique with Verres needle. After reaching intraperitoneal pressure of 10 mmHg, four trocars were inserted (two 10mm and two 5mm). The optic was placed at the umbilicus. The other trocars tweezers and scissors were used for dissection to perform the biopsies. Two liver fragments were removed, one in each lobe, and four peritoneal fragments (one in each quadrant of the abdomen).

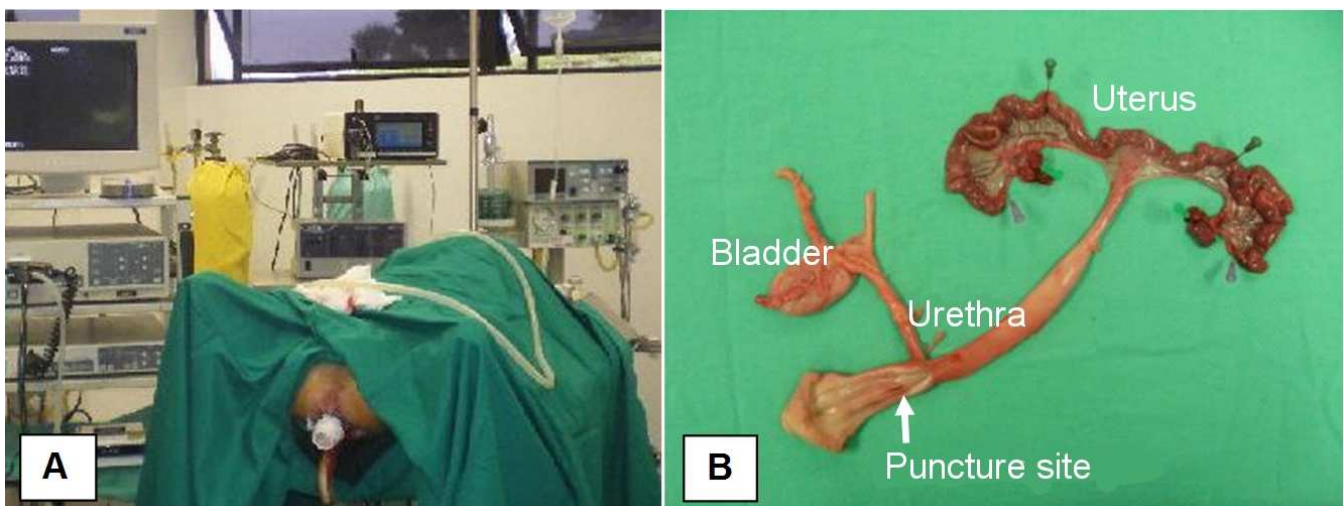
In the animals of GNote access was accomplished by blind puncture with a trocar in anterior vaginal wall, 1 cm above the urethra (Figure 1). An over tube coupled to an inflation system was then introduced, allowing the creation of pneumoperitoneum with CO<sub>2</sub>. Then the flexible endoscope was introduced inside the tube until it reached the upper abdomen. The same liver and peritoneal fragments were resected, but using appropriate instruments for flexible endoscopes.

In order to avoid the influence of anesthetic and surgical times in the results between the two groups, we used track anesthetic technique. The anesthetic and surgical times of each GNote animal was reproduced in GLap.

Chemical disinfection of non-disposable material was performed by immersion technique in hydrogen peroxide for 30 minutes.

### Postoperative Evolution

After surgery, the animals were kept alive for seven days in the vivarium at the Positivo University. During this period they received water and food *ad libitum*. Every day the animals were examined by a veterinarian for evaluation of clinical status (movement, swallowing), classified as good, fair, and poor general health.



**Figure 1** - (a) "Blind" puncture technique vaginal access; (b) Surgical specimen demonstrating vaginal puncture site.

On the seventh postoperative day the animals were weighed and underwent midline laparotomy under sterile conditions. We proceeded to inspect the abdominal cavity to detect bleeding, inadvertent injury to adjacent organs, abscess, complications related to access and presence of adhesions. We considered a complication an intraoperative bleeding greater than 10% estimated blood volume of the animal, difficult access, adjacent organ damage, prolonged hypoxia and hypercapnia (up to 10 minutes).

The peritoneal and liver fragments were sent for histopathology. The specimens were not identified, for the purpose of this analysis was to determine the tissue of origin of the material.

### Statistical Analysis

The data were analyzed descriptively by absolute (n) and relative (%) frequencies. For categorical and continuous variables we used the mean, standard deviation, median, first and third quartile, maximum and minimum values. The Shapiro-Wilk test was used to assess adherence to the normal distribution of data. The Mann-Whitney test was used to compare the weight of animals between the groups before and after the intervention. The sign test was used for the evaluation of the weight percentage change ((PF-PI)/PI\*100) within each group. The anesthetic and operative times were analyzed by Student "t" test. Models of analysis of variance (ANOVA) were set up for repeated measures to assess the effect in group and time on the measures of PCO<sub>2</sub>, PO<sub>2</sub>, RR and HR. We adopted the 5% level of statistical significance.

## RESULTS

There were no differences in anesthetic and surgical times between GNote and GLap. The surgical and anesthetic time averages for each group are presented in table 1.

Most animals in both groups showed weight loss after the procedure; in no case weight loss was greater than 5%. When evaluating the percentage change in weight occurred after the procedure between the groups, there was no statistically significant difference (p = 0.7535).

Only one GNote animal presented an intraoperative complication, difficulty of access with bleeding

of 80 ml. There was no postoperative complication. There was no statistically significant difference in relation to perioperative complications (p = 1.000) between the groups. All animals received daily good evaluation of clinical status in the postoperative period.

When comparing the averages of ETCO<sub>2</sub>, there were no differences between groups (p = 0.4762). However, over time, a statistically significant increase of ETCO<sub>2</sub> in GLap (p = 0.0025), which did not occur in GNote (p = 0.3679), as shown in figure 2.

GLap presented average SatO<sub>2</sub> values higher than the ones observed in GNote (p = 0.0080). However, none of the animals presented SatO<sub>2</sub> less than 87% (Figure 3). There was no significant change in the SatO<sub>2</sub> over time (p = 0.7273). In the course of the operation, both groups exhibited the same pattern of variation SatO<sub>2</sub> (p = 0.3102).

When comparing the mean RR, there were statistically significant differences: the GLap presented higher mean values of RR (p = 0.0043). However, there was no significant variation in RR over time (p = 0.5337) (Figure 4).

There were no differences regarding the mean HR between the groups (p = 0.6035), and there was no significant change in HR over time (p = 0.1721), as shown in figure 5.

During laparotomy adhesions were not observed in any animal.

Considering the quality of the material collected for the diagnosis of histologic tissue biopsy, the pathologist was able to diagnose the origin of the material in all 12 cases, both for the liver and peritoneal samples.

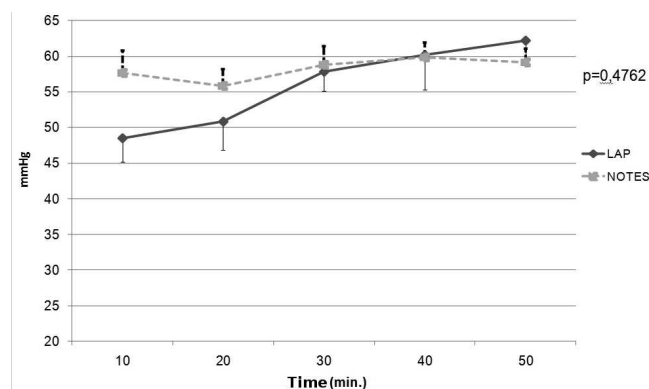


Figure 2 - ETCO<sub>2</sub> by group during time.

Table 1 - Comparison of anesthesia and surgery times (in minutes).

Procedure	GLap	GNotes	P value <sup>§</sup>
	Average (SD) <sup>1</sup>	Average (SD) <sup>1</sup>	
Anesthesia	59 (11,3)	61,2 (10)	0,4009
Operation	39,8 (11,2)	42,8 (9,8)	0,2405

<sup>§</sup> NOTE: Student's t Test

<sup>1</sup> SD = standard deviation

## DISCUSSION

Currently, there is great interest in expanding the frontiers of minimally invasive surgery and to develop new procedures that lead to "ultra-minimally invasive." One of these innovations has been the natural orifices endoscopic surgery (NOTES). For natural orifices it conveys the concept of performing surgery in the abdomen or chest cavity, without violating the abdominal wall, with access made through a natural orifice.

Experimental studies have shown that the open operation results in a greater degree of immunosuppression when compared to laparoscopy<sup>3-5</sup>. However, after minilaparotomy these changes are not significantly different from laparoscopy, suggesting that the degree of immunosuppression is also related to the size and extent of abdominal incision and trauma to the abdominal wall<sup>6</sup>. Proponents of NOTES believe that patients undergo less physiological and immune insult when compared to conventional or laparoscopic operation<sup>7</sup>. The result of this less aggression would be less postoperative pain and faster recovery. Experimental studies in animals have failed to demonstrate a decrease in inflammatory response (markers TNF, IL-1, IL-6 and CRP) of NOTES compared to laparoscopic<sup>8-10</sup>. In the gut wall fewer nerve endings are found than in the skin, fascia and muscles, which suggests a possible reduction of pain in procedures performed by natural orifices. Although case reports in humans describe little or no pain associated with NOTES, there are no controlled studies to confirm this hypothesis.

In studies with experimental animals, movement or physical activity, intake and assessment of weight are important parameters for assessment of postoperative evolution<sup>11,12</sup>. In this study, there were no differences between groups with respect to the return of intake, as well as in postoperative movement. No animal showed nausea/vomiting or diarrhea from the first day after surgery. Although most animals have shown weight loss, in any case it was more than 5% of body weight. There were also no statistically significant differences with respect to weight loss between GNote and GLap.

Anesthetized pigs have a mean  $\text{ETCO}_2$  of 30 to 40 mmHg<sup>13</sup>. In laparoscopic procedures in which carbon dioxide is used for creation and maintenance of pneumoperitoneum, the average values of  $\text{ETCO}_2$  are greater, mainly related to the time of the procedure. Increases in  $\text{ETCO}_2$  above 50% are described after an hour of laparoscopic procedure with intra-abdominal pressure of 10 mmHg<sup>14</sup>. In this study, the average  $\text{ETCO}_2$  ranged between 48 and 62 mmHg. There were no differences in the mean  $\text{ETCO}_2$  between animals undergoing the procedure by laparoscopic or NOTES. However, GLap animals showed  $\text{CO}_2$  retention throughout the procedure, which was not possible to explain, since time and pneumoperitoneum pressure were equivalent. None of the animals showed embolism or hemodynamic changes.

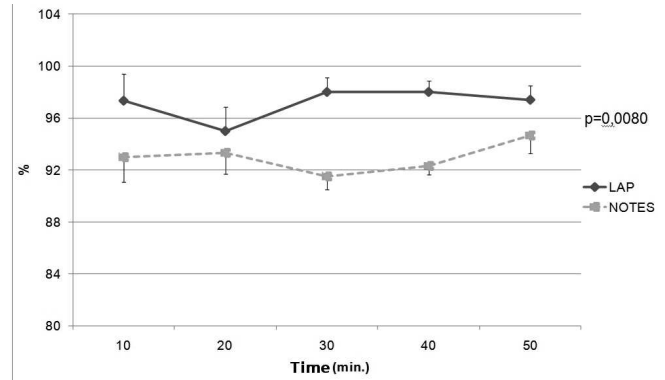


Figure 3 -  $\text{SatO}_2$  by group during the evaluations.

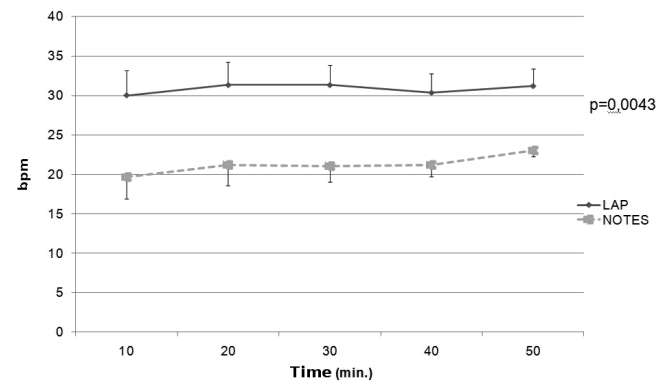


Figure 4 - Respiratory frequency during the evaluations (bpm: breaths per minute).

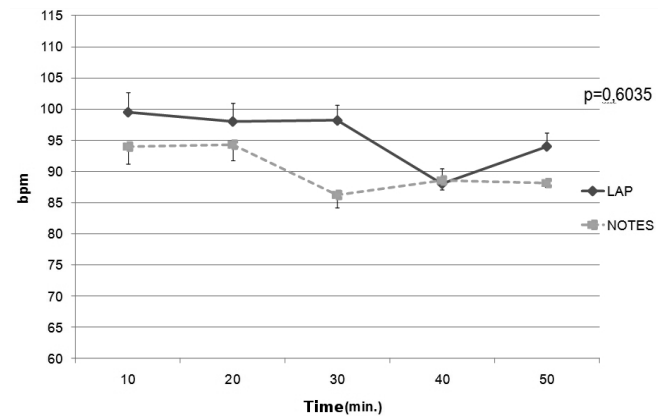


Figure 5 - Heart Rate during the evaluations (bpm: beats per minute).

It is reported that the respiratory function of anesthetized pigs suffer significant reduction<sup>15</sup>, with RR ranging from 8 to 18 breaths per minute<sup>16</sup>. The average RR ranged between 19 and 31 movements per minute. This increase is a compensatory mechanism common to hypercapnia, as occurred in this study. In addition, pneumoperitoneum causes increased intra-abdominal pressure, with consequent elevation of the diaphragm, which can result in hyperventilation<sup>11</sup>. GLap animals had a mean RR statistically superior to the GNote ones, probably compensatory to the accumulation of  $\text{CO}_2$  observed in this group.

The oxygen hemoglobin saturation in anesthetized animals receiving oxygen must be between 96% and 100% to ensure adequate tissue oxygenation<sup>17</sup>. Values between 85% and 92% are observed in pigs under general anesthesia and spontaneous breathing<sup>18</sup>. Although the averages of  $\text{ETCO}_2$  and RR are high in this study, the mean  $\text{O}_2$  saturation was above 90% in all animals, regardless of time. Still, GLap  $\text{SatO}_2$  averages were statistically superior to GNote (ranging between 95% and 98% versus 91% and 94%, respectively). This difference did not have clinical significance, since the values of the two groups are among the normal parameters.

There was also no difference with respect to HR between the groups, as there was no difference in the course of the procedure. The average heart rate of animals during the procedure ranged between 86 and 100 bpm, similar to data in the literature for pigs under general anesthesia<sup>13</sup>.

In only one GNote animal vaginal access presented with difficulty, with bleeding of 80 ml, which caused no hemodynamic effects and ceased spontaneously after access to the cavity. Difficulties to access the vagina in experimental animals have been described by other authors, probably for anatomical reasons, such as size of the animals and anatomical variations of the vagina. Unlike what is described in humans, pigs culdotomy is done "blindly"<sup>19</sup>. There were no intraoperative complications.

It is noteworthy the use of the "pair anesthetic" technique held in the present study, so that there was no influence of the anesthetic stress time, as well as surgical and pneumoperitoneum time in intra-operative and postoperative results. GLap and GNote animals were purposefully submitted to anesthetic procedures with similar average time (61.2 min versus 59 min respectively), as well as average surgical time (42.8 min versus 39.8 min, respectively).

Adhesions are one of the most frequent complications of abdominal operations, with average incidence of more than 80%<sup>20</sup>. Although the pathophysiology of their formation is fairly complex, the type and magnitude of peritoneal trauma seem to play an important role. Since most laparoscopic procedures are associated with less trauma than conventional surgery, laparoscopic has the potential advantage of reducing the formation of adhesions. A literature review<sup>21</sup>, despite the difficulties of diagnosis and different classifications, showed that laparoscopy is associated with lower risk of developing postoperative adhesions when compared to laparotomy. Although dependent on their location, the main consequences of adhesions are infertility, chronic abdominal and pelvic pain and intestinal obstruction. In addition, they contribute to make the access during the reoperations more difficult, causing an increase in surgical time and increased potential for intraoperative complications. It is currently a debate as to whether NOTES result in less intra-abdominal adhesions. There is a lower rate of adhesion

formation after liver biopsy in swine with NOTES (16.7%) compared to laparoscopy (33.3%) and laparotomy (100%)<sup>22</sup>; in this study, we found no difference in adhesion formation between laparoscopic and NOTES. None of the animals had intra-abdominal adhesions in the seventh day after surgery. The explanation for the absence of postoperative adhesions may have been the early evaluation.

Despite the potential benefits of NOTES, the instruments remains a major obstacle to carrying out more complex operations. The inherent flexibility of the endoscope prevents to obtain a stable operative field, as well as the need for retroflexion can create mirror images. The lack of triangulation is also an important technical barrier. Due to technical difficulties and lack of proper instruments to perform procedures entirely by natural orifices, most authors have performed hybrid procedures, i.e., combining the use of the endoscope through natural orifices with portals or traditional laparoscopic microlaparoscopy. In addition, the operation through natural orifices presents potential risk of increased infection rates inherent to the opening of a potentially contaminated organ/structure, as well as the risk of fistula due to inadequate closure or healing of the access site<sup>23,24</sup>.

One of the first steps to the performance of surgery through natural orifices is the choice of the access site. The vagina has been used for many years in gynecological procedures, especially vaginal hysterectomy, as well as for the extraction of abdominal organs in laparoscopic operations (splenectomy, oophorectomy, colectomy). The advantages of the vaginal route are: to allow straightforward access to the abdominal cavity and be closed easily with low risk of complications. However, one important limitation is to comprise only the female population. In addition, the vaginal route, for different reasons, displays restrictions amongst women themselves, with more than 80% of them opting for the transgastric route to remove the gallbladder instead of the vagina<sup>25</sup>.

The results of this study showed that transvaginal NOTES presents intraoperative physiological parameters equivalent to those found in laparoscopic surgery, in addition to being associated with rapid recovery and a satisfactory outcome after the procedure, as after laparoscopic ones.

Since the operations can be performed totally endoscopically (with or without minimum pneumoperitoneum insufflation), there is no need for general anesthesia. Thus, Notes may be made in the endoscopy unit or at the bedside in the ICU, avoiding patient transportation and allowing accurate diagnosis of intra-abdominal diseases<sup>26</sup>. In addition, Notes may be particularly appropriate in some patient groups, such as the obese, to whom conventional or laparoscopy surgery has challenges and limitations<sup>27</sup>.

Even if Notes will not result in significant changes in clinical practice, the technologies being developed as a result of the current enthusiasm may have application in

other areas. For example, the new endoscopic suturing devices, which are currently undergoing clinical evaluation, may be used in the closure of inadvertent perforation of the gastrointestinal tract during routine endoscopy, eliminating the need for surgical treatment.

For these reasons, many authors consider the emergence of NOTES a logical progression of the development of minimally invasive surgery. But some experts do not see significant advantages when compared to laparoscopy, and the advantages in terms of aesthetics would be only marginal.

In conclusion, NOTES should still be considered an experimental technique. For this new technique to be included in the arsenal of treatment options, studies are needed to confirm its effectiveness and demonstrate acceptable rates of morbidity and mortality, at least comparable to standard techniques. This study in animals showed no major physiological changes and complications after transvaginal peritonoscopy compared to laparoscopy. New studies in humans are needed to confirm these results and allow greater use of NOTES in clinical practice.

## R E S U M O

**Objetivo:** Avaliar o impacto do NOTES, comparado à cirurgia laparoscópica, mediante análise de parâmetros fisiológicos além de complicações operatórias e evolução pós-operatória. **Métodos:** Foram utilizados 12 suínos fêmeas, distribuídas em dois grupos: grupo laparoscopia (GLap) e grupo NOTES (GNotes). Os animais foram submetidos à biópsia hepática e peritoneal laparoscópica ou via endoscópica transvaginal. A cada 10 minutos foram anotadas a frequência respiratória, frequência cardíaca, saturação de O<sub>2</sub> e concentração expiratória de CO<sub>2</sub>. No 7º PO, os animais foram submetidos à laparotomia para avaliação de complicações intra-abdominais. **Resultados:** A maioria dos animais apresentou perda ponderal após o procedimento, entretanto em nenhum caso superior a 5%. Não houve diferença na variação percentual do peso entre os grupos ( $p=0,7535$ ). Também não foram observadas diferenças ao se comparar as médias da ETCO<sub>2</sub> ( $p=0,4762$ ), e médias da FC ( $p=0,6035$ ). Entretanto, o GLap apresentou médias de FR superiores ao GNotes ( $p=0,0043$ ) assim como as médias da saturação de O<sub>2</sub> ( $p=0,0080$ ) foram superiores. Porém, nenhum animal apresentou satO<sub>2</sub> inferior a 87% e esta diferença não foi considerada clinicamente significante. Apenas um animal do GNotes apresentou complicação operatória. **Conclusão:** NOTES está associado a parâmetros fisiológicos operatórios semelhantes aos encontrados na cirurgia laparoscópica. A realização de peritonoscopia transvaginal não está associada a aumento das complicações operatórias comparado à laparoscopia.

**Descritores:** Biópsia. Cirurgia endoscópica por orifício natural. Cirurgia endoscópica por orifício natural/complicações. Laparoscopia. Suínos.

## REFERENCES

1. Wagh MS, Thompson CC. Surgery insight: natural orifice transluminal endoscopic surgery - an analysis of work to date. *Nat Clin Pract Gastroenterol Hepatol* 2007; 4(7):386-92.
2. Hazey JW, Narula VK, Renton DB, Reavis KM, Paul CM, Hinshaw KE, et al. Natural-orifice transgastric endoscopic peritoneoscopy in humans: Initial clinical trial. *Surg Endosc* 2008; 22(1):16-20.
3. Walker CB, Bruce DM, Heys SD, Gough DB, Binnie NR, Eremin O. Minimal modulation of lymphocyte and natural killer cell subsets following minimal access surgery. *Am J Surg* 1999; 177(1):48-54.
4. Neuhaus SJ, Watson DI, Ellis T, Rofe AM, Mathew G, Jamieson GG. Influence of gases on intraperitoneal immunity during laparoscopy in tumor-bearing rats. *World J Surg* 2000; 24(10):1227-31.
5. Gupta A, Watson DI. Effect of laparoscopy on immune function. *Br J Surg* 2001; 88(10):1296-306.
6. Allendorf JD, Bessler M, Whelan RL, Trokel M, Laird DA, Terry MB, et al. Postoperative immune function varies inversely with the degree of surgical trauma in a murine model. *Surg Endosc* 1997; 11(5):427-30.
7. Swain P. A justification for NOTES - natural orifice transluminal endosurgery. *Gastrointest Endosc* 2007; 65(3):514-6.
8. McGee MF, Schomisch SJ, Marks JM, Delaney CP, Jin J, Williams CP, et al. Systemic inflammation and physiologic burden of transgastric natural orifice transluminal endoscopic surgery (NOTES) peritoneoscopy: a controlled, prospective comparison between NOTES and laparoscopy. *Gastrointest Endosc* 2007; 65(5):AB127.
9. Bingener J, Krishnegowda NK, Michalek JE. Immunologic parameters during NOTES compared with laparoscopy in a randomized blinded porcine trial. *Surg Endosc* 2009; 23(1):178-81.
10. Trunzo JA, McGee MF, Cavazzola LT, Schomisch S, Nikfarjam M, Bailey J, et al. Peritoneal inflammatory response of natural orifice transluminal endoscopic surgery (NOTES) versus laparoscopy with carbon dioxide and air pneumoperitoneum. *Surg Endosc* 2010; 24(7):1727-36.
11. Pulz RS, Silva Filho APF, Beck A, Stedile R, Schiochet F, Raudales J, et al. Anestesia inalatória ou anestesia balanceada em suínos. *Rev HCPA e Fac Med Univ Fed Rio Gd do Sul* 2009; 29(2):104-8.
12. Damy SB, Camargo RS, Chammas R, Figueiredo LFP. Aspectos fundamentais da experimentação animal - aplicações em cirurgia experimental. *Rev Assoc Med Bras* 2010; 56(1):103-11.
13. Tranquilli WJ, Parks CM, Thurmon JC, Benson GJ, Koritz GD, Manohar M, et al. Organ blood flow and distribution of cardiac output in nonanesthetized swine. *Am J Vet Res* 1982; 43(5):895-7.
14. Liem T, Applebaum H, Herzberger B. Hemodynamic and ventilatory effects of abdominal CO<sub>2</sub> insufflation at various pressures in the young swine. *J Pediatr Surg* 1994; 29(8):966-9.
15. John A. anestesia em suínos. In: Muir-III WW, Hubbel JAE. Manual de anestesia veterinária. 3ª ed. Porto Alegre: ArtMed; 2001. p. 283-7.
16. Massone F. Anestesiologia veterinária - farmacologia e técnicas. Rio de Janeiro: Guanabara Koogan; 1988. Anestesia em suínos; p. 213-4.

17. Tremper KK, Barker SJ. Pulse oximetry. *Anesthesiology* 1989; 70(1):98-108.
18. Hughes HC. Swine in cardiovascular research. *Lab Anim Sci* 1986; 36(4):348-50.
19. Sousa LH, Sousa Filho LH, Sousa VM, Sousa JAG, Tamura S, Chalela Jr D. Colecistectomia endoscópica: proposta de nova técnica totalmente transluminal por orifícios naturais. Resultado inicial de estudo experimental em suínos. *Rev bras videocir* 2007; 5(2):90-102.
20. Diamond MP. Clinical trials of an anti-adhesion adjuvant. 2ª ed. Totowa: Whyte Humana; 2006. Clinical evaluation of medical devices: principles and case studies; p.233-40.
21. Gutt CN, Oniu T, Schemmer P, Mehrabi A, Büchler MW. Fewer adhesions induced by laparoscopic surgery ? *Surg Endosc* 2004; 18(6):898-906.
22. Dubcenco E, Assumpcao LR, Gabrielson K, Dray X, Ruben D, Pipitone LJ, et al. Postoperative adhesion formation after peritoneoscopy with liver biopsy in a survival porcine model: laparotomic vs laparoscopic vs NOTES® transgastric approach. *Gastrointest Endosc* 2009; 69(5):AB161.
23. Pearl JP, Ponsky JL. Natural orifice transluminal endoscopic surgery: a critical review. *J Gastrointest Surg* 2008; 12(7):1293-300.
24. Nesargikar PN, Jaunoo SS. Natural orifice transluminal endoscopic surgery (N.O.T.E.S). *Int J Surg* 2009; 7(3):232-6.
25. Varadarajulu S, Tamhane A, Drelichman ER. Patient perception of natural orifice transluminal endoscopic surgery as a technique for cholecystectomy. *Gastrointest Endosc* 2008; 67(6):854-60.
26. Onders RP, McGee MF, Marks J, Chak A, Rosen MJ, Ignagni A, et al. Natural orifice transluminal endoscopic surgery (NOTES) as a diagnostic tool in the intensive care unit. *Surg Endosc* 2007; 21(4):681-3.
27. Decarli L, Zorron R, Branco A, Lima FC, Tang M, Pionner SR, et al. Natural orifice transluminal endoscopic surgery (NOTES) transvaginal cholecystectomy in a morbidly obese patient. *Obes Surg* 2008; 18(7):886-9.

Received: 09/07/2010

Accepted for publication: 08/09/2010

Conflict of interest: none

Source of funding: none

How to cite this article:

Claus CMP, Bonin EA, Torres MF, Campos ACL, Cury AM, Coelho JCU. Liver and peritoneal biopsy by laparoscopy or notes in pigs: comparison of operative parameters and postoperative evolution. *Rev Col Bras Cir.* [periódico na Internet] 2011; 38(4). Disponível em URL: <http://www.scielo.br/rcbc>

Address correspondence to:

M. Christiano P. Claus

E-mail: [christiano.claus@gmail.com](mailto:christiano.claus@gmail.com)