

# Anatomic study of the double-bundle of the anterior cruciate ligament with the knee in 90° flexion

## *Estudo anatômico das duas bandas do ligamento cruzado anterior com o joelho em 90° de flexão*

EDMAR STIEVEN-FILHO<sup>1</sup>; EDUARDO TOSTA GARSCHAGEN<sup>2</sup>; MARIO NAMBA<sup>3</sup>; JOÃO LUIZ VIEIRA DA SILVA<sup>3</sup>; OSVALDO MALAFAIA, ECBC-PR<sup>4</sup>; LUIZ ANTÔNIO MUNHOZ DA CUNHA<sup>5</sup>

### A B S T R A C T

**Objective:** To anatomically evaluate the femoral origin and tibial insertion of the anteromedial and posterolateral bands of the anterior cruciate ligament. **Methods:** We studied eight cadaver knees as for the following: in the femur, distance from the center of the anteromedial band to the deep cartilage and the ceiling; also in the femur, distance from the center of the posterolateral band to the deep cartilage, to the inferior cartilage and to the superficial cartilage. In the tibia, we measured the distances between the anterior tibial bone edge to the anterior region of the anteromedial band, to the center of the anteromedial band and to the center of the posterolateral band. We also measured the distance between the center of the posterolateral band to the tibial posterolateral bone and the total length of the anteroposterior tibial insertion of the anterior cruciate ligament.

**Results:** In the femur, the distance from the center of the anteromedial band to the deep cartilage was  $6.3 \pm 1.4$  mm, and  $11.2 \pm 2$  mm to the ceiling. Also in the femur, the distance from the center of the posterolateral band to the deep cartilage was  $9 \pm 4$  mm, to the superficial cartilage  $7.6 \pm 1.8$  mm, and to the inferior cartilage  $4.2 \pm 0.9$  mm. In the tibia, the distance from the anterior tibial bone edge to the anterior region of the anteromedial band was  $11.9 \pm 2.8$  mm, to the center of the anteromedial band  $18.8 \pm 2.6$  mm, and to the center of the posterolateral band  $26.5 \pm 2.3$  mm. The distance from the center of the posterolateral band to the tibial posterior bone edge was  $19.6 \pm 4$  mm and the total length of the anteroposterior tibial insertion of the anterior cruciate ligament was  $19.4 \pm 1.8$  mm. **Conclusion:** The center of the tibial insertion of the anteromedial band is approximately 20mm distant from the anterior edge of the tibia, while the center of the posterolateral band is approximately 30mm. The distance between the center of the origin of the anteromedial band to the deep cartilage is 6mm, and to the posterior lateral 10mm.

**Key words:** Anatomy. Anterior cruciate ligament. Knee joint. Tendon injuries. Cadaver.

### INTRODUCTION

The incidence of anterior cruciate ligament (ACL) reconstruction is 100,000 cases per year in the United States of America<sup>1</sup>. Every year there are more cases of injury due to the growing number of practitioners in sports activities<sup>2-4</sup>.

The reconstruction techniques, focusing on the repair of the anteromedial band, are well established with good results, also with regards to the return to high performance physical activities<sup>5,6</sup>.

Despite the wide use of the reconstruction with a single band, the ACL consists of two bands: the anteromedial (AM) and posterolateral (PL). Proponents of the reconstruction of both bands claim that there is residual instability in the conventional reconstruction, which causes degenerative changes<sup>7-12</sup>. Based on the fact that ACL

reconstruction is not effective in preventing the progression to osteoarthritis in the operated knee, questions arose about whether the conventional AM band reconstruction is able of keeping the joint healthy, especially in women<sup>13-15</sup>.

One of the most discussed questions about the surgical technique of reconstruction is the placement of the tunnels. The papers describe ACL anatomy in anatomical position<sup>16</sup> (extension), whereas surgical position is at 90° flexion<sup>17</sup>. This complicates the interpretation of the anatomy by the surgeon during the operation.

In the classic study by Girgis<sup>16</sup> it has been shown that there is change in the anatomical relationship of the ACL with the flexion movement, but it was analyzed as a single unit, regardless of having two bands. The traditional nomenclature – proximal / distal and anterior / posterior – is not easy to apply with the knee at 90°. In order to facilitate anatomical description a specific nomenclature was

Work conducted at the Department of Anatomy, Division of Biological Sciences, Universidade Federal do Paraná – UFPR, Curitiba, Paraná State – PR, Brazil.

1. Volunteer Physician, Universidade Federal do Paraná; 2. Post-Graduate, Sports Traumatology, Universidade Federal do Paraná; 3. Physician, Universidade Federal do Paraná; 4. Professor, Department of Surgery, Universidade Federal do Paraná; 5. Professor, Department of Orthopedics Universidade Federal do Paraná.

proposed for analysis at 90° knee flexion. The new nomenclature suggests that, when the knee is at 90°, the anatomic relationships should be called superficial / deep, superior / inferior<sup>17</sup>.

This applies to the femur, as in the case of the tibia there is no change in the anatomical relationship between the two situations.

The objective of this study is to assess the anatomic relationships of the two macroscopic bands of the ACL in its femoral origin in surgical position and in the tibial insertion.

## METHODS

This work was conducted by the Department of Anatomy, Division of Biological Sciences, Federal University of Paraná. Twenty different cadaver knees were dissected in order to study the anatomy in the surgical position, according to the new nomenclature<sup>17</sup> (Figures 1 A and B), and measurements of anatomic structures and relationships in the ACL femoral origin and tibial insertion were performed.

As inclusion criteria, we used only cadaver knees with intact cruciate ligaments (anterior and posterior), without prior arthrotomy. Eight knees met the criteria. The dissection was anterior, with medial parapatellar approach till proper exposure of the cruciate ligaments was achieved<sup>18</sup>. All knees were preserved in formaldehyde (Figure 2).

For comparison of measurements we used 40x12mm needles in marking the specific points and a metallic caliper. The study was conducted with the knee flexed at 90 degrees for measurement of femoral data.

The measurements of the following distances were performed in the femur (Figure 3): 1) from the center of the anteromedial band to the deep cartilage (AM-CP); 2) from the center of the anteromedial band to the intercondyle ceiling (AM-teto); 3) from the center of the posterolateral band to the deep cartilage (PL-CP); 4) from the center of the posterolateral band to the superficial cartilage (PL-CS); and 5) from the center of the posterolateral band to the inferior cartilage (PL CI).

The measurements of the following distances were performed in the tibia (Figure 4): 1) from the anterior edge to the anterior portion of the anteromedial band (AM-AT-A); 2) from the anterior edge to the center of the anteromedial band (AT-AM); 3) from the anterior edge to the center of the posterolateral band (TA-PL); 4) from the posterior edge to the center of the posterolateral band (PL-PT); and 5) anteroposterior diameter of the ACL (AP).

## RESULTS

The measures, means and standard deviations of the femoral origin of the ACL of the two bands are shown in table 1 and the ones from the tibia in table 2.

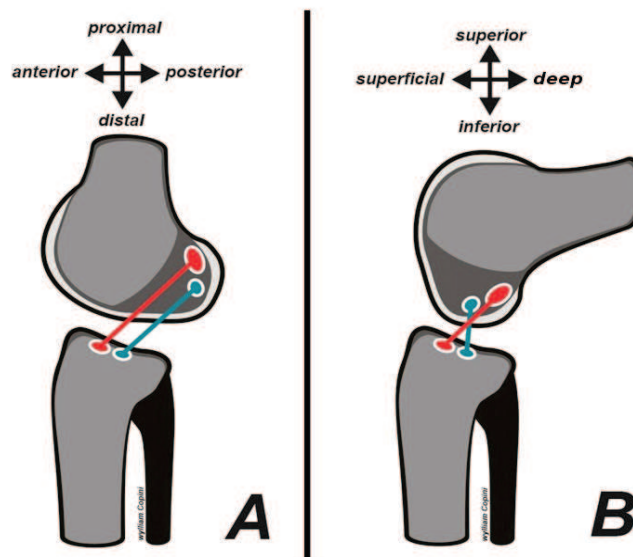


Figure 1 - A) anatomical position and anatomical description, B) surgical position and description proposed by Zantop<sup>17</sup>

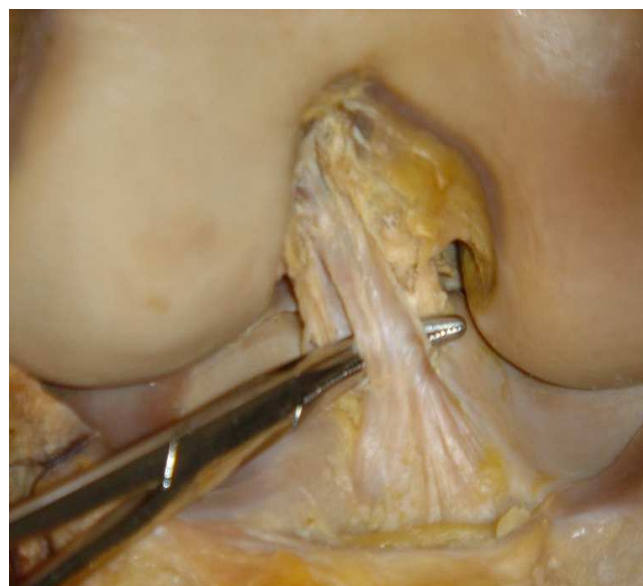
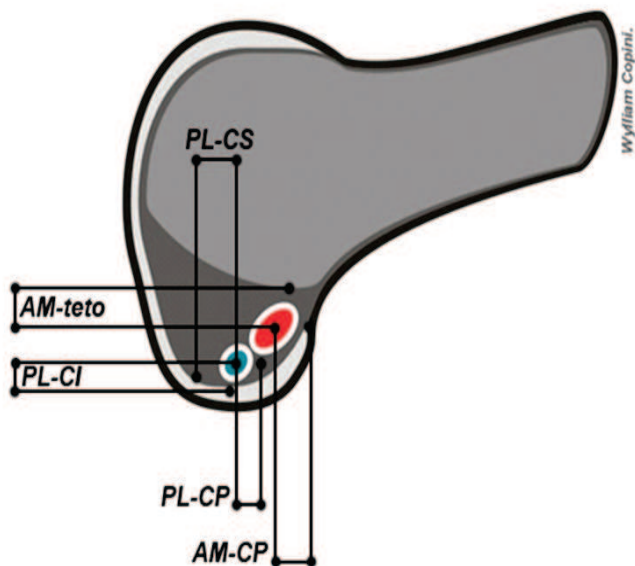


Figure 2 - The two ACL bands, when appropriate for anatomical assessment.

In the femur the measurements were: AM-CP,  $6.3 \pm 1.4$  mm; AM teto,  $11.2 \pm 2$  mm; PL-CP,  $9 \pm 4$  mm; PL-CI,  $4.2 \pm 0.9$  mm; PL-CS  $7.6 \pm 1.8$  mm. In the tibia we found: AT-AM-A,  $11.9 \pm 2.8$  mm; AT-AM,  $18.8 \pm 2.6$  mm; AT-PL,  $26.5 \pm 2.3$  mm; PL-PT,  $19.6 \pm 4$ mm; AP,  $19.4 \pm 1.8$  mm.

## DISCUSSION

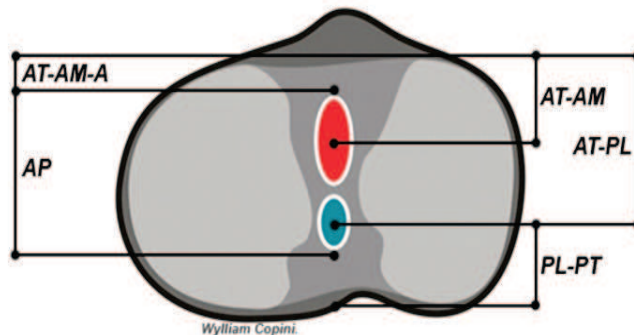
The restoration of the anatomy of the knee to the nearest normal, with the positioning of the tunnels in the most anatomically possible position, is crucial to the success of ACL reconstruction<sup>19-23</sup>.



**Figure 3** - References for measurements of the femur: 1) center of anteromedial band to deep cartilage (AM-CP); 2) center of anteromedial band to the intercondyle ceiling (AM-teto); 3) center of posterolateral band to deep cartilage (PL-CP); 4) center of the posterolateral band to superficial cartilage (PL-CS); and 5) center of posterolateral band to inferior cartilage (PL-CI)

Most articles study the anatomy of the ACL as a whole, not analyzing the bands separately, which constitutes a limiting factor in studying the placement of tunnels with dual band reconstruction.

We found no anatomical description with the femur at 90° flexion, which is the surgical, though non-anatomical, position. Despite the anatomical analysis of



**Figure 4** - References for measurements of the tibia: 1) anterior tibia edge to anterior portion of anteromedial band (AM-AT-A); 2) anterior tibia edge to center of anteromedial band (AM-AT); 3) anterior tibia edge to center of posterolateral band (TA-PL); 4) posterior tibia edge to center of posterolateral band (PL-PT); and 5) antero-posterior diameter of ACL (AP).

the flexed knee does not have a direct influence on the measures, it facilitates the interpretation of surgical data.

The distance between the center of the femoral origin of the posterolateral (PL) band to the inferior cartilage was  $4.2 \pm 0.9$  mm. Petersen *et al.*<sup>24</sup> found a value of 4 to 5mm. This shows that the origin of the PL band almost touches the articular cartilage.

Regarding the measure of the distance between the center of the PL band to the region of the deep femoral cartilage, we obtained  $9 \pm 4$  mm. Yasuda *et al.*<sup>25</sup> reported values of 5 to 8 mm for this length. These numbers help as a location parameter of the origin of this band in the knee. It is known that the PL band is more superficial than the anteromedial (AM), because the distance from the AM band to the deep cartilage was  $6.3 \pm 1.4$  mm.

**Table 1** - Anatomical measures of the femoral origin of ACL (mm).

	AM - CP	AM - teto	PL - CP	PL - CS	PL - CI
Average	6.3	11.2	9	7.6	4.2
Standard deviation	1.4	2	4	1.8	0.9

Legend: AM-CP: center of anteromedial band to deep cartilage; AM-teto: center of anteromedial band to the ceiling of the intercondyle; PL-CP: center of posterolateral band to deep cartilage; PL-CS: center of posterolateral band to superficial cartilage; PL-CI: center of posterolateral band to inferior femur cartilage.

**Table 2** - Anatomical measures of the femoral insertion of ACL (mm).

	AT-AM-A	AT-AM	AT-PL	PL-PT	AP
Average	11.9	18.8	26.5	19.6	19.4
Standard deviation	2.8	2.6	2.3	4.1	1.8

Legend: AT-AM-A: anterior tibia edge to anterior aspect of anteromedial band; AT-AM: anterior tibia edge to center of anteromedial band; AT-PL: anterior tibia edge to center of posterolateral band; PL-PT: center of posterolateral band to tibia posterior edge; AP: antero-posterior diameter.

Another parameter measured was the distance from the superficial cartilage to the center of the PL band and we found  $7.6 \pm 1.8$  mm. There are no values in the literature to compare with the determination of this measure. In an arthroscopic view these numbers mean that the superficial edge of the ACL would touch an imaginary line that cuts the condyle in half.

The anatomical visualization of the ACL on the tibia is not changed between the surgical position and the classical anatomical one; so it is said that the name of the ACL bands is due to its tibial position. But this is only one way to avoid confusion in the interpretation of the surgical anatomy and does not correspond to reality.

According to Petersen *et al.*<sup>24</sup>, the insertion of the ACL begins 10 to 14 mm posterior to the anterior border of the tibia and the diameter of the sagittal plane of the ligament varied from 15 to 19 mm. These numbers have clinical relevance in double band reconstructions, as in the realization of the double tibial tunnel it is essential that the size of the tunnels is adapted to the size of the knee. Small knees require more delicate drills to prevent communication between the tunnels, preserving a bone bridge between them. In this work the distance from the anterior edge of the tibia to the anterior portion of the AM band was  $11.9 \pm 3$  mm, similar to that found by Petersen *et al.*<sup>24</sup>, whereas

the antero-posterior diameter was  $19.4 \pm 2$  mm, greater than the one found by them.

The distance obtained from the center of the AM band to the anterior edge of the tibia is an important finding because it can be used as a parameter for the conventional ACL reconstruction; it is known that an error in this position may bring bad results to the ACL reconstruction<sup>26</sup>. In this work the values of this measure was  $18.8 \pm 3$  mm, and Petersen *et al.*<sup>24</sup> had 13-17mm.

The distance from the center of the PL band to the anterior tibial edge serves as parameter for dual-band reconstructions. We obtained  $26.5 \pm 2$  mm in this study, whilst Petersen *et al.* found 20-25mm<sup>24</sup>.

It is interesting to note that the tibial insertion is long in the antero-posterior plane ( $19.4 \pm 2$  mm), the center of the PL band being closer to the posterior edge of the tibia ( $19.6 \pm 4$ mm) than to the anterior one ( $26.5 \pm 2$ mm).

In conclusion, the distance from the center of origin of the anteromedial band to the deep cartilage of the femur is approximately 6 mm, and to the posterolateral band 10 mm. The center of the tibial insertion of the anteromedial band is approximately 20 mm from the anterior edge of the tibia, and the posterolateral band 30 mm. The distance between the center of the origin of the posterolateral band to the inferior cartilage is about 5 mm.

## R E S U M O

**Objetivo:** Avaliar anatomicamente a origem femoral e inserção tibial das bandas ântero-medial e póstero-lateral do ligamento cruzado anterior. **Métodos:** Estudados oito joelhos de cadáveres, foram feitas as seguintes medidas no fêmur: distância do centro da banda ântero-medial à cartilagem profunda e a ao teto. Ainda no fêmur, do centro da banda póstero-lateral à cartilagem profunda, a cartilagem inferior e à cartilagem superficial. Na tibia, foi aferido do bordo ósseo tibial anterior à região anterior da banda ântero-medial, ao centro da banda ântero-medial e ao centro da banda póstero-lateral. Também foi medido o centro da banda póstero-lateral ao bordo ósseo posterior da tibia e o comprimento ântero-posterior total da inserção tibial do ligamento cruzado anterior. **Resultados:** No fêmur, a distância do centro da banda ântero-medial à cartilagem profunda foi de  $6,3 \pm 1,4$ mm e ao teto  $11,2 \pm 2$ mm. Ainda no fêmur, a medida do centro da banda póstero-lateral à cartilagem profunda  $9 \pm 4$ mm, à cartilagem superficial  $7,6 \pm 1,8$ mm e a cartilagem inferior  $4,2 \pm 0,9$ mm. Na tibia, a distância do bordo ósseo tibial anterior à região anterior da banda ântero-medial foi de  $11,9 \pm 2,8$ mm, ao centro da banda ântero-medial  $18,8 \pm 2,6$ mm e ao centro da banda póstero-lateral  $26,5 \pm 2,3$ mm. A medida do centro da banda póstero-lateral ao bordo ósseo posterior da tibia foi  $19,6 \pm 4$ mm e o comprimento ântero-posterior total da inserção tibial do ligamento cruzado anterior  $19,4 \pm 1,8$ mm. **Conclusão:** O centro da inserção tibial da banda ântero-medial encontra-se a aproximadamente 20mm da extremidade anterior da tibia, enquanto o centro da póstero-lateral se encontra a 30mm. A distância entre o centro da origem da banda ântero-medial até a cartilagem profunda é 6mm e da póstero-lateral 10mm.

**Descritores:** Anatomia. Ligamento cruzado anterior. Articulação do joelho. Traumatismos dos tendões. Cadáver.

## REFERENCES

- Griffin LY, Agel J, Albohm MJ, Arendt EA, Dick RW, Garrett WE, et al. Noncontact anterior cruciate ligament injuries: risk factors and prevention strategies. *J Am Acad Orthop Surg* 2000; 8(3):141-50.
- Stern HP, Bradley RH, Prince MT, Stroh SE. Young children in recreational sports. Participation motivation. *Clin Pediatr* 1990; 29(2):89-94.
- Chen AL, Mears SC, Hawkins RJ. Orthopaedic care of the aging athlete. *J Am Acad Orthop Surg* 2005; 13(6):407-16.
- Filho ES, Sampaio EB, Namba M, Silva JL, Albano M, Rocha LE, et al. Is it possible to predict the length of knee flexor tendons by anthropometry? *Rev Col Bras Cir* 2010; 37(4):274-8.
- Cooley VJ, Deffner KT, Rosenberg TD. Quadrupled semitendinosus anterior cruciate ligament reconstruction: 5-year results in patients without meniscus loss. *Arthroscopy* 2001; 17(8):795-800.
- Freedman KB, D'Amato MJ, Nedeff DD, Kaz A, Bach BR Jr. Arthroscopic anterior cruciate ligament reconstruction: a metaanalysis comparing patellar tendon and hamstring tendon autografts. *Am J Sports Med* 2003; 31(1):2-11.

7. Järvelä T, Paakkala T, Kannus P, Järvinen M. The incidence of patellofemoral osteoarthritis and associated findings 7 years after anterior cruciate ligament reconstruction with a bone-patellar tendon-bone autograft. *Am J Sports Med* 2001; 29(1):18-24.
8. Ristanis S, Giakas G, Papageorgiou CD, Moraiti T, Stergiou N, Georgoulis AD. The effects of anterior cruciate ligament reconstruction on tibial rotation during pivoting after descending stairs. *Knee Surg Sports Traumatol Arthrosc* 2003; 11(6):360-5.
9. Tashman S, Collon D, Anderson K, Kolowich P, Anderst W. Abnormal rotational knee motion during running after anterior cruciate ligament reconstruction. *Am J Sports Med* 2004; 32(4):975-83.
10. Ristanis S, Stergiou N, Patras K, Vasiliadis HS, Giakas G, Georgoulis AD. Excessive tibial rotation during high-demand activities is not restored by anterior cruciate ligament reconstruction. *Arthroscopy* 2005; 21(11):1323-9.
11. Fithian DC, Paxton EW, Stone ML, Luetzow WF, Csintalan RP, Phelan D, et al. Prospective trial of a treatment algorithm for the management of the anterior cruciate ligament-injured knee. *Am J Sports Med* 2005; 33(3):335-46.
12. Roe J, Pinczewski LA, Russell VJ, Salmon LJ, Kawamata T, Chew M. A 7-year follow-up of patellar tendon and hamstring tendon grafts for arthroscopic anterior cruciate ligament reconstruction: differences and similarities. *Am J Sports Med* 2005; 33(9):1337-45.
13. Fithian DC, Paxton LW, Goltz DH. Fate of the anterior cruciate ligament-injured knee. *Orthop Clin North Am* 2002; 33(4):621-36.
14. Fink C, Hoser C, Hackl W, Navarro RA, Benedetto KP. Long-term outcome of operative or nonoperative treatment of anterior cruciate ligament rupture—is sports activity a determining variable? *Int J Sports Med* 2001; 22(4):304-9.
15. Lohmander LS, Ostberg A, Englund M, Roos H. High prevalence of knee osteoarthritis, pain, and functional limitations in female soccer players twelve years after anterior cruciate ligament injury. *Arthritis Rheum* 2004; 50(10):3145-52.
16. Girgis FG, Marshall JL, Monajem A. The cruciate ligaments of the knee joint. Anatomical, functional and experimental analysis. *Clin Orthop Relat Res* 1975; (106):216-31.
17. Zantop T, Petersen W, Fu FH. Anatomy of the anterior cruciate ligament. *Operat Tech Orthop* 2005; 15(1):20-8.
18. Abbott LC, Carpenter WF. Surgical approaches to the knee joint. *J Bone Joint Surg Am* 1945; 27:277-310.
19. Steiner ME, Battaglia TC, Heming JF, Rand JD, Festa A, Baria M. Independent drilling outperforms conventional transtibial drilling in anterior cruciate ligament reconstruction. *Am J Sports Med* 2009; 37(10):1912-9.
20. Buoncristiani AM, Tjoumakaris FP, Starman JS, Ferretti M, Fu FH. Anatomic double-bundle anterior cruciate ligament reconstruction. *Arthroscopy* 2006; 22(9):1000-6.
21. Abebe ES, Moorman CT 3rd, Dziedzic TS, Spritzer CE, Cothran RL, Taylor DC, et al. Femoral tunnel placement during anterior cruciate ligament reconstruction: an in vivo imaging analysis comparing transtibial and 2-incision tibial tunnel-independent techniques. *Am J Sports Med* 2009; 37(10):1904-11.
22. Scanlan SF, Blazek K, Chaudhari AM, Safran MR, Andriacchi TP. Graft orientation influences the knee flexion moment during walking in patients with anterior cruciate ligament reconstruction. *Am J Sports Med* 2009; 37(11):2173-8.
23. Stieven Filho E, Malafaia O, Ribas-Filho JM, Diniz OE, Borges PC, Albano M, et al. Biomechanic analysis of the sewed tendons for the reconstruction of the anterior cruciate ligament. *Rev Col Bras Cir* 2010; 37(1):52-7.
24. Petersen W, Zantop T. Anatomy of the anterior cruciate ligament with regard to its two bundles. *Clin Orthop Relat Res* 2007; 454:35-47.
25. Yasuda K, Kondo E, Ichiyama H, Tanabe Y, Tohyama H. Surgical and biomechanical concepts of anatomic anterior cruciate ligament reconstruction. *Operat Tech Orthop* 2005; 15(2):96-102.
26. Jackson DW, Gasser SI. Tibial tunnel placement in ACL reconstruction. *Arthroscopy* 1994; 10(2):124-31.

Received on 30/09/2010

Accepted for publication 02/12/2010

Conflict of interest: none

Source of funding: none

#### How to cite this article:

Stieven Filho E, Garschagen ET, Namba M, Silva JLV, Malafaia O, Cunha LAM. Anatomic study of the double-bundle of the anterior cruciate ligament with the knee in 90° flexion. *Rev Col Bras Cir*. [periódico na Internet] 2011; 38(5). Disponível em URL: <http://www.scielo.br/rcbc>

#### Address correspondence to:

Edmar Stieven-Son

E-mail: [filho2000@uol.com.br](mailto:filho2000@uol.com.br)