

Surgical treatment of extravasation injuries: experience of the Hospital das Clínicas, Faculty of Medicine, University of São Paulo.

Opções de tratamento cirúrgico em lesões cutâneas por extravasamento acidental de drogas: experiência do Hospital das Clínicas da Faculdade de Medicina da USP.

DIMAS ANDRÉ MILCHESKI¹; WELLINGTON MENEZES MOTA¹; RODOLFO COSTA LOBATO¹; ARALDO AYRES MONTEIRO JÚNIOR¹; ROLF GEMPERLI, TCBC-SP¹

A B S T R A C T

Objective: to report the experience of the Division of Plastic Surgery of the Hospital das Clínicas of the Medical School of the University of São Paulo in the treatment of cutaneous lesions due to accidental extravasation of drugs. **Methods:** we included patients with lesions due to extravasation of drugs over a period of 18 months. We retrospectively evaluated the following parameters: age, diagnoses during hospitalization and comorbidities, serum levels of albumin and hemoglobin, place of hospitalization, drug involved, anatomic segment affected, therapeutic management and death during hospitalization. **Results:** we followed-up 14 patients. The main drug involved was noradrenaline (21%). All patients underwent debridement of tissue necrosis. Three patients were submitted to flaps after preparation of the wound bed with negative pressure therapy, with good results. Seven patients had no definitive treatment of their lesions due to lack of clinical conditions. **Conclusion:** in patients with favorable clinical conditions, the definitive treatment with flaps was adequate for cases of wounds due to extravasation of drugs in the subcutaneous tissue when there was exposure of noble structures.

Keywords: Iatrogenic Disease. Extravasation of Diagnostic and Therapeutic Materials. Ischemia. Necrosis. Surgical Flaps. Surgery. Plastic.

INTRODUCTION

Injury due to extravasation of drugs is the major cause of iatrogenic morbidity in the hospital environment¹. The incidence of this event in the literature varies from 0.1% to 6% in adult patients and from 11% to 70%, in children^{2,3}. Patients at extremes of age, neonates and the elderly, are at greater risk of injury by extravasation, in addition to individuals with altered levels of consciousness or sedated, who are unable to express pain⁴.

This is an event that generates a high cost for the health system, involving expenses of around US\$.66,000.00 due to lawsuits in the United States⁵. In up to 25% of cases of injury due to extravasation of drugs, the morbidity resulting from it is more serious than the underlying cause of the patient's hospitalization. This is due to pain, difficulty in

mobility, limitation of daily activities, permanent nerve damage, loss of limbs and, in some cases, death¹.

The occurrence of such lesions can be avoided with preventive measures. However, when they occur, they need rapid recognition of the event and immediate appropriate treatment to prevent progression. The delay in recognition of the lesion can lead to catastrophic consequences, from unsightly scars, contractures, cellulitis, need for skin grafts and flaps, neurovascular injury, limb shortening, amputations and even death⁶.

This paper aims to report the experience of the Division of Plastic Surgery of the Hospital das Clínicas of the Medical School of the University of São Paulo (HC-FMUSP) in the treatment of cutaneous lesions due to accidental extravasation of drugs.

1 - Faculty of Medicine, University of São Paulo, Discipline of Plastic Surgery, Hospital das Clínicas, São Paulo, SP, Brazil.

METHODS

This is a retrospective, descriptive case series, in which we evaluated all the referrals for the wounds group of the Plastic Surgery Division of the HC-FMUSP from January 2016 to June 2017 (18 months). We included in the study all patients who presented with an injury resulting from inadvertent extravascular extravasation of medication during that period.

We analyzed the following parameters: age of the patient at the time of the event; diagnoses during hospitalization and comorbidities; serum levels of albumin and hemoglobin; place of hospitalization - intensive care unit or ward; drug involved; anatomical segment involved; therapeutic treatment for the wound; occurrence of death during hospitalization.

We performed descriptive data analysis with the Statistical Package for the Social Sciences, version 18.0 (SPSS Inc., Chicago, IL, USA). We described the categorical variables as percentages, and the continuous ones, as mean and standard deviation of the mean, if their distribution was normal, or as median and interquartile range, in case of non-normal distribution.

This work was approved by the Institutional Ethics Committee with the following reference number 76201617.6.0000.0068.

RESULTS

In the study period, 830 referrals for evaluation of wounds in the complex of the HC-FMUSP were analyzed by the Plastic Surgery Service, totaling 14 patients with injuries resulting from extravascular extravasation of drugs, with incidence in our sample of 1.6%

of wounds accompanied by the Plastic Surgery Wound Group.

The mean age of the patients was 44.4 ± 30.2 years, ranging from one month to 69. All the patients studied had at least two associated comorbidities, which can be observed in table 1. The most involved anatomical location was the hand dorsum (50%), with cutaneous lesions of total thickness and without the presence of infectious signs. Patients were treated in the intensive care unit in most cases (78.5%) and 57.1% died during hospitalization due to clinical worsening of comorbidities. In no case was the death due to wound complications. The main drug responsible for the incidents was noradrenaline (21%) administered in peripheral veins in two cases. In six cases, it was not possible to identify the medication involved.

The main treatment applied was debridement of necrotic tissue of the wound bed and daily dressings associated with chemical debriding agent with 10% calcium alginate or papain in 11 cases (78.5%), due to hemodynamic conditions that prevented the performance of surgical procedures. Of these, eight died without definitive skin coverage. The other three that survived and did not receive skin flaps were pediatric patients, who presented good evolution and wound healing with conservative treatment with established dressings (Table 2).

Three patients underwent wound closure by skin flaps. All had hemodynamic stability and were debrided in the operating room with wound bed preparation with negative pressure therapy, in addition to nutritional improvement, accompanied by an increase in serum albumin levels. One patient had a large hand and forearm lesion due to iron III

Table 1. Patients' clinical characteristics and lesion etiology.

Patient	Age (years)	Drug	Location	Comorbidities	In-hospital unit	Death
1	54	50% glucose	Right foot	Surgery for brain stem tumor + ischemic stroke + urinary septic shock + BCP	ICU	Yes
2	1 month	Bicarbonate	Right hand	ARF-peritoneal dialysis + congenital cardiopathy + CHF	ICU	Yes
3	85	Noradrenaline	Left forearm	CHF + cardiogenic shock + ARF	ICU	Yes
4	8 months	Unknown	Right hand	Fallot's tetralogy + imperforate anus	Ward	U
5	51	Unknown	Right hand	CrF + pacemaker + ischemic colitis	ICU	Yes
6	1 month	Bicarbonate	Right hand	Premature	ICU	No
7	65	Unknown	Right hand	Post renal transplant + urinary sepsis	ICU	Yes
8	51	Noradrenaline	Left forearm	Spinal cord injury + urinary sepsis + ARF	ICU	Yes
9	59	Unknown	Left forearm	Pelvic abscess + septic shock	ICU	Yes
10	65	50% glucose	Left foot	Post liver transplantation + ischemic cholangitis + pulmonary sepsis + transplant rejection	ICU	Yes
11	56	Noradrenaline	Right groin	CRF + ischemic cardiomyopathy + DM + AH	ICU	No
12	3 months	Unknown	Right forearm	Fallot's tetralogy + endocarditis + ischemic stroke	ICU	No
13	69	Unknown	Right hand	CRF + post renal transplant + AH + urinary sepsis	Ward	No
14	66	Iron III hydroxide saccharate.	Right hand and forearm	CRF + post renal transplant + pancytopenia + active infection by parvovirus and cytomegalovirus	Ward	No

BCP: Bronchopneumonia; ICU: Intensive Care Unit; ARF: Acute Renal Failure; CHF: Congestive Heart Failure; CRF: Chronic Renal Failure; DM: Diabetes Mellitus; AH: Arterial Hypertension.

Table 2. Type of treatment and patients' nutritional parameters (levels of albumin and hemoglobin).

Patient	Treatment	Albumin (g/dl)	Hemoglobin (g/dl)
1	Debridement in bed + dressing (papain 10%)	2.6	8.6
2	Debridement in bed + dressing (calcium and sodium alginate hydrogel®) → healing	3	12.7
3	Dressings (emollients)	2.9	13.7
4	Debridement in bed + dressing (calcium and sodium alginate hydrogel®) → healing	3.1	13.6
5	Debridement in bed + dressing (papain 10%)	1.5	8.8
6	Debridement in bed + dressing (calcium and sodium alginate hydrogel®) → healing	3.3	11.6
7	Soft silicone dressing with silver (mepilex ag®)	2.7	11.7
8	Debridement in bed + dressing (papain 10%)	1.6	9.2
9	Debridement in bed + dressing (papain 10%)	1.6	7
10	Debridement in bed + dressing (papain 10%)	1.6	6.3
11	Debridement + negative pressure therapy for → tensor fascia lata flap	3	7.7
12	Debridement in bed + dressing (calcium and sodium alginate - hydrogel®) → healing	5.7	14.2
13	Debridement + local rhomboid flap	2.3	7.8
14	Debridement + negative pressure therapy → groin flap to hand + forearm grafting	2.6	10.2

hydroxidesaccharate (Figure 1). The treatment initially adopted was surgical debridement and negative pressure therapy, with evolution to an adequate bed. At that time, we applied a pediculated groin flap based on the superficial iliac circumflex artery to cover the back of the right hand (Figure 2) and grafting on the forearm, obtaining an excellent esthetic and functional result (Figure 3).

The second case, due to noradrenaline extravasation in the right inguinal region, was resolved by means of a tensor fascia lata flap, due to the presence of noble structures in the inguinal region, after seven days of negative pressure

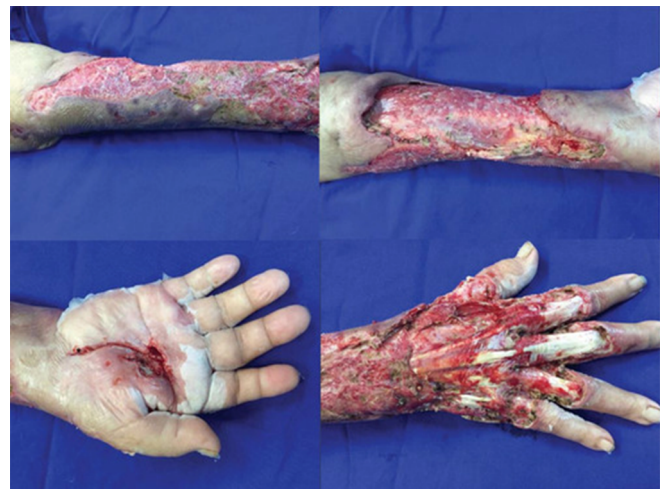

Figura 1. Injury to the back of the hand and forearm: extensive initial lesion with exposure of extensor tendons, requiring cutaneous coverage through a flap.

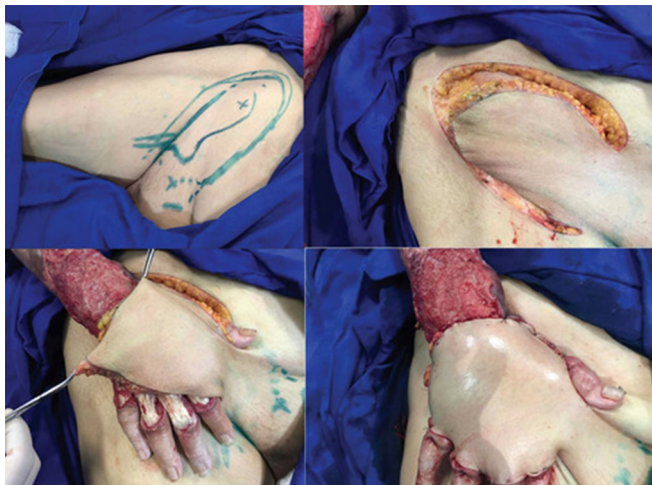

Figura 2. Patient submitted to a pediculated groin flap with adequate coverage of the back of the hand, without tendon or other noble structures exposure.

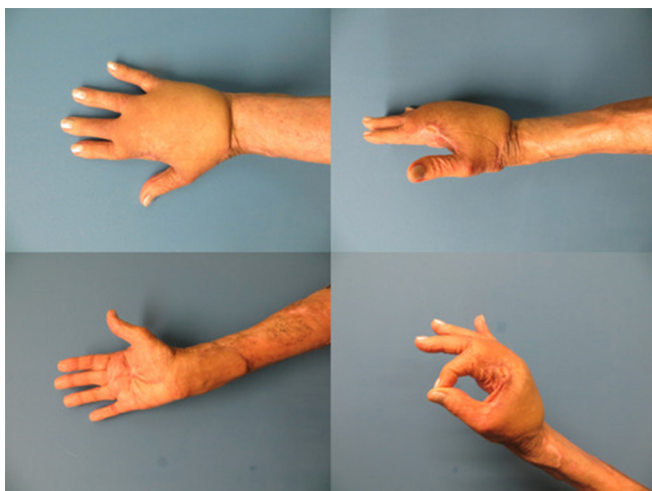


Figura 3. Aesthetic and functional result after six months of the groin flap to the back of the right hand and partial skin graft in the forearm.

therapy (Figure 4). The patient evolved without complications in the surgical wound and without limitations of limb mobilization.

The third case in which a flap was necessary was due to unidentified extravasation on the back of the right hand, receiving a local rhomboid flap following a week of negative pressure therapy (Figure 5). The cutaneous cover was satisfactory for the coverage of the tendons of the back of the hand, without limitations.

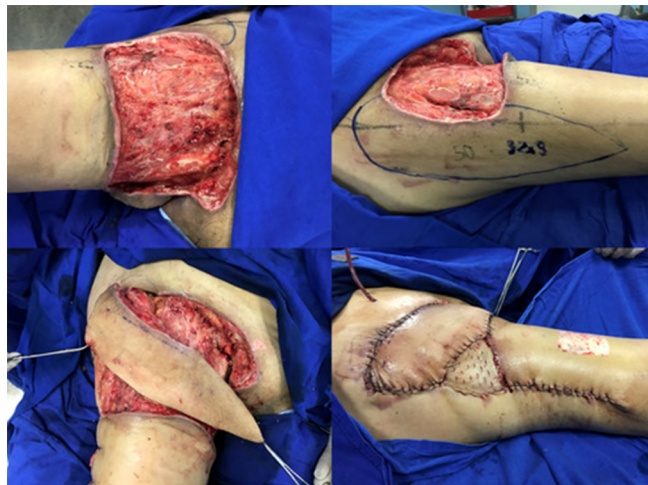


Figura 4. Tensor fascia lata flap to cover the right inguinal region, previously submitted to debridement and negative pressure therapy, requiring a small partial skin graft in the flap donor area.

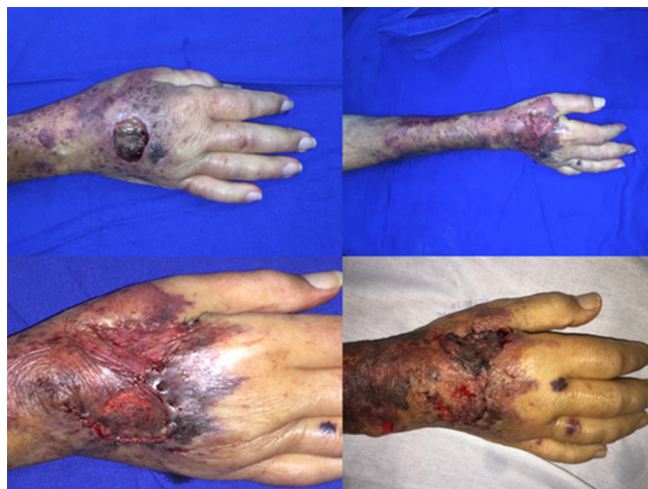

Figura 5. Rhomboid local flap (Limberg) on the back of right hand. In the upper left corner, initial ulcerated lesion, treated with debridement and vacuum dressing, allowing the local flap to be carried out, with good wound coverage.

DISCUSSION

The incidence of drug extravasations in the literature is underestimated, as most are not reported^{7,8}. Most of these events occur at night, going unnoticed, and the risk is increased when inexperienced individuals are manipulating intravenous accesses, especially when cytotoxic drugs are used⁸. Possibly, the number of events

occurred in our Hospital is greater than the observed, considering that only one of the cases did not require surgical debridement for the removal of necrotic tissue. Thus, probably the evaluation of the Plastic Surgery was requested only for the most serious cases.

The sites most frequently involved in cases of drug extravasation are the back of the hand and foot, ankle, antecubital fossa, near joints or joint spaces, areas with little subcutaneous tissue to protect underlying structures^{8,9}.

In the presented series, the main agent responsible for the lesions due to extravasation was noradrenaline, and in two of the three cases, it was being administered in a peripheral vein. The main risk factors for necrosis due to extravasation of vasopressor drugs are the presence of vascular diseases, hypotension, diabetic neuropathy, Raynaud's disease, coagulopathy, advanced age and altered mental status¹⁰. In addition, another important risk factor is administration to small, peripheral or slow-circulation veins, such as the antecubital fossa and the saphenous vein. The rate of cutaneous necrosis resulting from peripheral administration of noradrenaline amounts to 46-60%.

The rapid recognition of the adverse event is essential for the initial measures to be taken. Early diagnosis is critical to reduce the extent of the lesion and the first symptoms are pain, erythema and local edema, followed by pallor, flicten and cutaneous dyschromia. The presence of pain is the most important symptom to alert the team about the occurrence of extravasation, and its duration, referred by the patients, indicates the severity of the event^{8,11}.

After recognition of the lesion by extravasation, the infusion of the drug should be immediately interrupted, and its aspiration, attempted through the existing access. There are a range of acceptable options, such as immobilization

and continuous observation, topical and injectable antidotes when available, subcutaneous irrigation techniques, and early surgical debridement and fasciotomy, when there are signs of compartment syndrome¹².

Surgical intervention of extravasation lesions may be immediate or late. The best timing and type of surgical intervention required in extravasation lesions remains controversial in view of the variety of agents causing the lesions and the characteristics of the patients in the studies^{3,13,14}. Although some authors advocate early surgical intervention within 24 hours after the event to avoid ulceration, necrosis and secondary infection, most recommend a conservative initial management^{14,15}. However, surgical treatment may be necessary early and its indication can be classified into three situations: emergency (neurovascular involvement or suspicion of compartment syndrome); urgency (persistent pain, total plane necrosis and cutaneous sepsis focus) and elective (ulceration, nonadherence to treatment with dressings, delayed treatment of the underlying disease and delayed healing)^{3,16}.

We agree that, initially, all cases of extravasation identified should be treated through frequent observation and conservative methods. Such measures include elevation of the affected limb, emollient, anti-inflammatory and analgesic agents, cold dressings (or heated if caused by catecholamines or vinca-derived alkaloids), surgery being reserved to the situations previously mentioned, and whenever there is delimitation of the necrotic tissue, a period that varies between 24 hours and 14 days⁷. Thus, we based our definitive surgical management on two main conditions: the presence of necrosis and the patient's clinical and nutritional conditions (Figure 6). In general, we prefer to perform definitive surgical treatment in patients with hemoglobin levels above 10g/dl and albumin above 3.0g/dl.

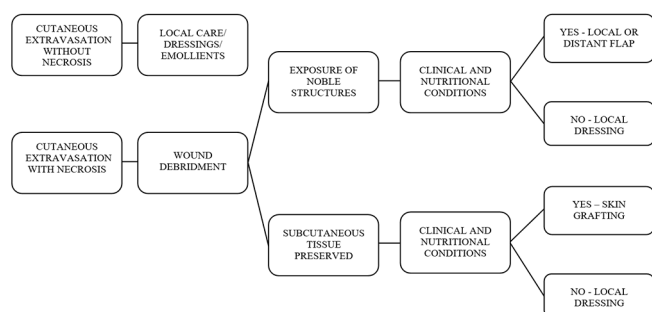


Figura 6. Flowchart of conduct after injury by drug extravasation, based on the presence or absence of necrosis and on the patient's clinical conditions.

Firat *et al.*⁷ studied 22 cases of drug extravasation in a two-year period, with involvement of the upper limb in most cases (68%), more specifically the back of the hand. The majority of the cases required surgical resolution and were resolved with skin grafts (36.4%) and flaps (27.3%). The closure of the wound by second intention occurred in five cases, and conservative treatment, in three cases. The author believes that surgical management should be reserved for cases of cutaneous necrosis in which there is indication of a surgical procedure, not intervening early in extravasation cases.

In general, surgical procedures are required in about one-third of initially conservatively managed extravasation lesions¹⁷. Surgical debridement should be radical and remove all non-viable tissue, keeping only the non-affected and well-perfused tissue observed by active bleeding in the wound bed after surgical cleaning⁸. Often, multiple debridements are required in the weeks following the occurrence of extravasation to remove necrosis and infectious foci. In such cases, debridement sequences are necessary until a suitable bed is obtained for definitive closure of the wound through skin grafting or flaps, increasing the length of hospital stay and treatment costs^{15,18}. In our surgical cases with a definitive closure proposal, we used negative pressure therapy, which has the capacity to reduce wound size, remove fluid and bacteria, decrease the local inflammatory process

and stimulate granulation tissue, collaborating with the improvement of the wound bed^{19,20}.

Immediate or late reconstructive surgery can be performed with similar results²¹. Once indicated, the surgical procedure should be performed as soon as possible to reduce morbidity and not to delay treatment for the patient's primary condition. Cedidi *et al.*²² compared early and late surgical treatment of extravasation lesions and found that all 18 patients who were referred late (on average 22 days after the event) required debridement and temporary and definitive wound coverage by means of grafts and flaps. This author concludes that early referral to a plastic surgeon is necessary to reduce the need for complex surgical procedures, risk of infection, treatment time and consequently costs.

Murphy *et al.*² evaluated 43 cases of drug extravasation lesions over 18 months in an Australian pediatric hospital and referred immediately after the event identification to the Plastic Surgery team. They observed the need for subcutaneous tissue irrigation in five patients (11%) and only three (7%) developed cutaneous necrosis. These lesions were debrided and treated satisfactorily by dressing with silver in their composition, without the need for reconstructive surgeries, but with increased morbidity and prolonged hospitalization. This finding corroborates the expectant behavior regarding the lesions treated conservatively in the three cases presented here in pediatric patients.

The use of well-established initial care protocols after the occurrence of extravasation and the use of measures such as skin infiltration with saline solution may contribute to the reduction of the number of cases that evolve with tissue necrosis²³. D'Andrea *et al.*²⁴ evaluated drug extravasation in a period of 12 years, finding 240 cases. Of these,

only 11 evolved with necrosis and ulceration, requiring definitive coverage. All lesions were on the back of the hands and were treated by grafting in one case, local flap in four cases, radial flap in other four cases, and serratus myocutaneous microsurgical flap in two. Another option for patients sustaining wounds with exposure of noble

structures after surgical debridement is the use of dermal substitutes, when available.

It was observed that the definitive treatment skin flaps was adequate for the cases of wounds by extravasation of drugs in the subcutaneous tissue when there is exposure of deep structures in patients with favorable clinical conditions.

R E S U M O

Objetivo: relatar a experiência da Divisão de Cirurgia Plástica do Hospital das Clínicas da Faculdade de Medicina da Universidade de São Paulo no tratamento de lesões cutâneas por extravasamento acidental de drogas. **Métodos:** foram incluídos os pacientes com lesões por extravasamento de drogas num período de 18 meses. Os seguintes parâmetros foram avaliados retrospectivamente: idade, diagnósticos durante internação e comorbidades, níveis séricos de albumina e hemoglobina, local de internação, droga envolvida, segmento anatômico acometido, conduta terapêutica e óbito durante internação. **Resultados:** foram acompanhados 14 pacientes. A principal droga envolvida foi a noradrenalina (21%). Todos os pacientes foram submetidos a desbridamento da necrose tecidual. Três pacientes foram submetidos a retalhos após preparo do leito com terapia por pressão negativa, com bons resultados. Sete pacientes não tiveram tratamento definitivo de suas lesões por falta de condições clínicas. **Conclusão:** o tratamento definitivo por meio de retalhos se mostrou adequado para os casos de feridas por extravasamento de drogas em tecido subcutâneo, quando há exposição de estruturas nobres, em pacientes com condições clínicas favoráveis.

Descritores: Doença iatrogênica. Extravasamento de Materiais Terapêuticos e Diagnósticos. Isquemia. Necrose. Retalhos Cirúrgicos. Cirurgia Plástica.

REFERENCES

1. Reynolds PM, MacLaren R, Mueller SW, Fish DN, Kiser TH. Management of extravasation injuries: a focused evaluation of noncytotoxic medications. *Pharmacotherapy*. 2014;34(6):617-32.
2. Murphy AD, Gilmour RF, Coombs CJ. Extravasation injury in a paediatric population. *ANZ J Surg*. 2017 Jul 6. doi: 10.1111/ans.
3. Goutos I, Cogswell LK, Giele H. Extravasation injuries: a review. *J Hand Surg Eur Vol*. 2014;39(8):808-18.
4. Tong R. Preventing extravasation injuries in neonates. *Paediatr Nurs*. 2007;19(8):22-5.
5. Bhananker SM, Liao DW, Kooner PK, Posner KL, Caplan RA, Domino KB. Liability related to peripheral venous and arterial catheterization: a closed claims analysis. *Anesth Analg*. 2009;109(1):124-9.
6. Le A, Patel S. Extravasation of noncytotoxic drugs: a review of the literature. *Ann Pharmacother*. 2014;48(7):870-86.
7. Firat C, Erbatur S, Aytakin AH. Management of extravasation injuries: a retrospective study. *J Plast Surg Hand Surg*. 2013;47(1):60-5.
8. Al-Benna S, O'Boyle C, Holley J. Extravasation injuries in adults. *ISRN Dermatol*. 2013;2013:856541.
9. Garden AL, Laussen PC. An unending supply of 'unusual' complications from central venous catheters. *Paediatr Anaesth*. 2004;14(11):905-9.
10. Chen JL, O'Shea M. Extravasation injury associated with low-dose dopamine. *Ann Pharmacother*. 1998;32(5):545-8.
11. Heckler FR. Current thoughts on extravasation injuries. *Clin Plast Surg*. 1989;16(3):557-63.
12. Hannon MG, Lee SK. Extravasation injuries. *J Hand Surg Am*. 2011;36(12):2060-5.
13. Wickham R, Engelking C, Sauerland C, Corbi D. Vesicant extravasation part II: Evidence-based management and continuing controversies. *Oncol Nurs Forum*. 2006;33(6):1143-50.

14. Boulanger J, Ducharme A, Dufour A, Fortier S, Almanric K; Comité de l'évolution de la pratique des soins pharmaceutiques (CEPSP); Comité de l'évolution des pratiques en oncologie (CEPO). Management of the extravasation of anti-neoplastic agents. *Support Care Cancer*. 2015;23(5):1459-71.
15. Schulmeister L. Extravasation management: clinical update. *Semin Oncol Nurs*. 2011;27(1):82-90.
16. Fallscheer P, Kammer E, Roeren T, Meuli-Simmen C. Injury to the upper extremity caused by extravasation of contrast medium: a true emergency. *Scand J Plast Reconstr Surg Hand Surg*. 2007;41(1):26-32.
17. Kassner E. Evaluation and treatment of chemotherapy extravasation injuries. *J Pediatr Oncol Nurs*. 2000;17(3):135-48.
18. Ener RA, Meglathery SB, Styler M. Extravasation of systemic hemato-oncological therapies. *Ann Oncol*. 2004;15(6):858-62.
19. Anghel EL, Kim PJ. Negative-pressure wound therapy: a comprehensive review of the evidence. *Plast Reconstr Surg*. 2016;138(3 Suppl):129S-37S.
20. Milcheski DA, Ferreira MC, Nakamoto HA, Pereira DD, Batista BN, Tuma P Jr. Subatmospheric pressure therapy in the treatment of traumatic soft tissue injuries. *Rev Col Bras Cir*. 2013;40(5):392-6.
21. Shenaq SM, Abbase EH, Friedman JD. Soft-tissue reconstruction following extravasation of chemotherapeutic agents. *Surg Oncol Clin N Am*. 1996;5(4):825-45.
22. Cedidi C, Hierner R, Berger A. Plastic surgical management in tissue extravasation of cytotoxic agents in the upper extremity. *Eur J Med Res*. 2001;6(7):309-14.
23. Napoli P, Corradino B, Badalamenti G, Tripoli M, Vieni S, Furfaro MF, et al. Surgical treatment of extravasation injuries. *J Surg Oncol*. 2005;91(4):264-8.
24. D'Andrea F, Onesti MG, Nicoletti GF, Grella E, Renzi LF, Spalvieri C, et al. Surgical treatment of ulcers caused by extravasation of cytotoxic drugs. *Scand J Plast Reconstr Surg Hand Surg*. 2004;38(5):288-92.

Received in: 05/15/2018

Accepted for publication: 05/29/2018

Conflict of interest: none.

Source of funding: none.

Mailing address:

Dimas André Milcheski

E-mail: dimas.milcheski@hc.fm.usp.br

drdimasandre@gmail.com

