

Facial paralysis and vestibular syndrome in feedlot cattle in Argentina¹

Ernesto Odriozola^{2*}, Santiago Diab³, Pablo Khalloub³, Adriana Bengolea³, Luciana Lázaro³, Darío Caffarena³, Luis Pérez⁴, Germán Cantón² and Carlos Campero²

ABSTRACT.- Odriozola E., Diab S., Khalloub P., Bengolea A., Lázaro L., Caffarena D., Pérez L., Cantón G. & Campero C. 2009. **Facial paralysis and vestibular syndrome in feedlot cattle in Argentina.** *Pesquisa Veterinária Brasileira* 29(11):894-898. INTA EEA Balcarce, CC 276, (7620) Balcarce, Argentina. E-mail: eodriozola@balcarce.inta.gov.ar

This paper reports 6 outbreaks of neurological disease associated with paralysis of the facial and vestibulocochlear nerves caused by intracranial space occupying lesions in feedlot cattle. The clinical signs observed were characterized by head tilt, uni or bilateral drooping and paralysis of the ears, eyelid ptosis, keratoconjunctivitis, and different degrees of ataxia. Morbidity and mortality rates ranged from 1.1 to 50% and 0 to 1%, respectively. Gross lesions observed included yellow, thickened leptomeninges, and marked enlargement of the roots of cranial nerves VII (facial) and VIII (vestibulocochlear). Histopathologically, there was severe, chronic, granulomatous meningitis and, in one case, chronic, granulomatous neuritis of the VII and VIII cranial nerves. Attempts to identify bacterial, viral, or parasitic agents were unsuccessful. Based on the morphologic lesions, the clinical condition was diagnosed as facial paralysis and vestibular syndrome associated with space occupying lesions in the meninges and the cranial nerves VII and VIII. Feedlot is a practice of growing diffusion in our country and this is a first report of outbreaks of facial paralysis and vestibular disease associated with space occupying lesions in Argentina.

INDEX TERMS: Vestibular syndrome, bovine, feedlot, neuropathology.

RESUMO.- [Paralisia facial e síndrome vestibular de bovinos em confinamento.] Descrevem-se 6 surtos de uma doença neurológica com paralisia dos nervos facial e vestibulo-coclear causada por lesões intracraniais que ocupam espaço em bovinos em confinamento. Os sinais clínicos foram desvio da cabeça, queda e paralisia das orelhas, ptose palpebral, ceratoconjuntivite e diferentes graus de ataxia. As taxas de morbidade e mortalidade foram de 1.1%-50% e de 0-1%, respectivamente. As lesões macroscópicas incluíram engrossamento das meninges, que se apresentavam amareladas, e marcado engrossamento das raízes dos nervos cranianos VII (facial) e VIII (vestíbulo-

coclear). Histologicamente observaram-se meningite crônica granulomatosa e, em um caso, neurite granulomatosa crônica do VII e VIII pares cranianos. Cultivos para bactérias ou vírus resultaram negativos. De acordo com as lesões observadas o quadro clínico foi diagnosticado como paralisia facial e síndrome vestibular associadas a lesões que ocupam espaço nas meninges e nervos cranianos VII e VIII. O confinamento é uma prática em expansão na Argentina e este é o primeiro relato, neste país, de surtos de paralisia facial e síndrome vestibular associados com lesões que ocupam espaço.

TERMOS DE INDEXAÇÃO: Síndrome vestibular, bovinos, confinamento, neuropatologia.

¹ Received on April 14, 2009.

Accepted for publication on June 24, 2009.

² INTA EEA Balcarce, CC 276, (7620) Balcarce, Argentina. *Corresponding author: eodriozola@balcarce.inta.gov.ar

³ Residencia Interna en Salud Animal, INTA EEA Balcarce.

⁴ Laboratorio Santa Rosa, Av. Uruguay 1058, (6300) Santa Rosa, Argentina.

INTRODUCTION

Numerous causes of facial paralysis and vestibular disease have been described in domestic animals. In dogs and cats, traumatism (surgical and nonsurgical), neoplasias, and otitis media/interna are mentioned as the most

common causes of facial paralysis and vestibular disease (Kern & Erb 1987). Traumatism and otitis media in horses (Firth 1977), and a granulomatous encephalitis of possible viral etiology in goats (Cork et al. 1974) may cause clinical signs of facial paralysis and vestibular disease.

In cattle, meningoencephalitis caused by *Listeria monocytogenes* (Campero et al. 2002), intoxication by *Propolis juliflora* (Tabosa et al. 2006) and *P. caldenia* (Odriozola, unpublished data), otitis media, and neoplasias such as meningiomas and acoustic neuromas, may also cause vestibular signs and facial paralysis (Maenhout et al. 1984, George 1996, Walz et al. 1997, Radostits et al. 1999a, Tokarnia et al. 2000, Maeda et al. 2003, Duarte & Hamdan 2004, Lamm et al. 2004). Other authors reported sporadic cases of facial paralysis associated with space occupying lesions of the cranial nerves in calves similar to those described in this study (Maenhout et al. 1984, Van der Lugt, 1994).

This study describes the clinical and pathological findings observed in six outbreaks of neurologic disease associated with space occupying lesions of the meninges and VII and VIII cranial nerves in feedlot cattle in two Argentinean provinces.

MATERIALS AND METHODS

The six outbreaks (A, B, C, D, E, F) of neurological disease occurred in five different feedlot commercial facilities in the Argentinean provinces of Buenos Aires and La Pampa. The age of the affected cattle ranged between 3 months and 5 years, but a great majority (>90% of affected animals) was between 3 and 18 months, and the breeds included Hereford, Aberdeen Angus, Shorthorn and various crossbreeds (Table 1). The animals were fed rations containing variable amounts of corn kernels, soya beans, sunflower expeller and minerals and vitamins supplements.

A limited clinical examination of affected cattle was made and necropsies were performed on 7 animals from outbreaks B, C, D, E and F (necropsies 1-7, respectively). Samples of the central nervous system (CNS) were obtained and stored refrigerated or frozen for bacteriological culture and viral isolation, respectively. Various visceral organs, brain, meninges and cranial nerves were fixed in 10% buffered formalin for histopathology. Virus isolation on cell cultures and immunofluorescence techniques for bovine viral diarrhoea virus (BVDV) and bovine herpesvirus (BHV) were performed on CNS tissues. Aerobic and microaerophilic cultures were performed in McConkey and agar blood Columbia mediums for bacterial isolation from ocular swabs of 2 affected live steers (outbreak C) and CNS from all necropsied animals. A complete blood cell count (CBC) and serum concentrations of calcium, phosphorus

and magnesium were determined from blood and serum samples collected from 4 animals with clinical signs on outbreak F.

Histologic sections from all fixed tissues were stained with routine H&E, and Gridley's stain for fungi, Ziehl-Neelsen stain for acid fast bacteria, and Gram and Giemsa for bacteria were performed on selected sections. Immunohistochemistry (IHC) technique with the avidin-biotin kit to identify *Mycoplasma* sp. (Prairie Diagnostic Service, Western College of Veterinary Medicine, Saskatoon, Canada) was performed on sections from the meninges and VII and VIII cranial nerve roots and from soft tissues found at the entrance of the internal acoustic meatus on two animals (necropsies 1 and 3).

RESULTS

Including the 6 outbreaks in cattle, 458 out of 5140 animals were affected. Morbidity was variable among the outbreaks, ranging from 1.12% to 50% and mortality rates were very low, ranging from 0 to 1%. Only three animals from outbreak A and 5 from outbreak E spontaneously died several days after the onset of the clinical signs. The majority of the affected cattle had a slow, but complete recovery, whereas others still showing some neurological sequelae, such as ear drooping and slight head tilt after two months. All animals showed typical signs of facial paralysis and vestibular disease, characterized by head tilt, uni or bilateral drooping and paralysis of the ears, eyelid ptosis (Fig.1), different degree of ataxia, kerato-conjunctivitis, and excessive lacrimation. Otitis externa was not observed in any of the 6 outbreaks. Only animals from outbreak E had a history of evident signs of respiratory disease 1 to 2



Fig.1. Facial paralysis signs registered in an affected steer (outbreak F).

Table 1. Characteristics, category and place of the outbreaks of facial paralysis and vestibular disease in Argentina

Outbreak	Category	Total cattle	Affectedcattle	Month and year	County, Province
A	Steer	600	100	Jan.2002	Loventué, La Pampa
B	Steer / heifer	380	37	Oct./Nov.2003	La Maruja, La Pampa
C	Steer	2600	50	Oct./Nov.2003	Loventué, La Pampa
D	Steer	260	12	Nov.2003	Daireaux, Buenos Aires
E	Heifer / cow	500	250	Jul./Aug.2005	Toay, La Pampa
F	Steer	800	9	Oct.2008	Pehuajó, Buenos Aires

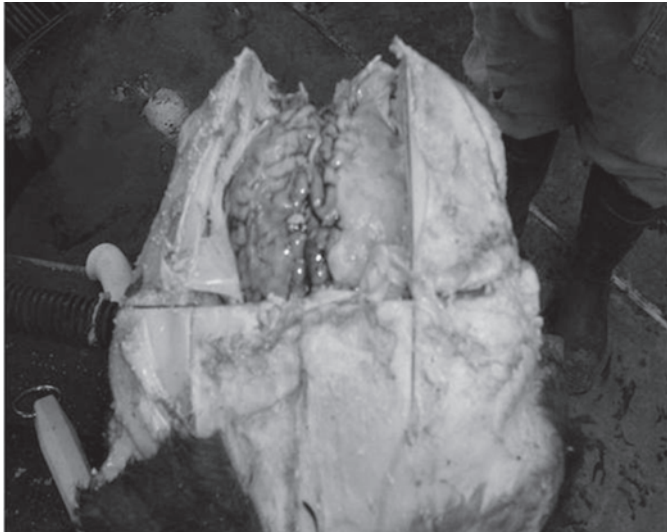


Fig.2. Yellowish and thickened meninges on the lateroventral wall of the cranial cavity of the left side of affected calf in outbreak B.

weeks before the onset of the neurologic signs, with minimal mortality. According to the attending veterinarian, the respiratory signs varied in severity from mild to severe and were characterized by respiratory distress, variable depression, reddening and ulceration of the muzzle, coughing and serous nasal secretion. Necropsy #1 was performed on a steer (outbreak B) that was euthanized several days after the onset of the typical signs of facial paralysis and vestibular syndrome. Grossly, the irregularly and markedly thickened (up to 4mm in diameter) leptomeninges were tan to yellow and had a gelatinous consistency (Fig.2). A focal area, approximately 5cm long and 2-3cm wide, located on the surface of the left sphenoid bone (floor of the skull) was covered by a hard, rough, tan-yellowish substance. Bilaterally, the roots of cranial nerves VII and VIII were markedly enlarged (approximately twice the normal size) and a firm, rounded, white-tan mass, approximately 7mm x 5mm was present near the internal acoustic meatus. The steer from necropsy #3 (outbreak D), one heifer and a cow (necropsies #4 and #5 of outbreak E) had similar lesions in the leptomeninges as the steer in necropsy #1, which were characterized by diffuse, marked thickening, gelatinous consistency and tan-yellow discoloration of the leptomeninges.

Necropsies #2, #6 and #7 (outbreaks C, E and F, respectively) were performed on 2 steers and a cow that were euthanized after a few days of the onset of the clinical signs of head tilt and ear drooping, and no gross lesions were observed within the CNS.

Histologically, the CNS from the animals in necropsies #1, #3, #4 and #5 showed marked expansion of the leptomeninges by abundant loose connective tissue and a granulomatous reaction composed of macrophages, fewer lymphocytes and multinucleated giant cells (foreign body-type) with neovascularization (Fig.3). Occasionally, the meninges had small foci of necrosis infiltrated by

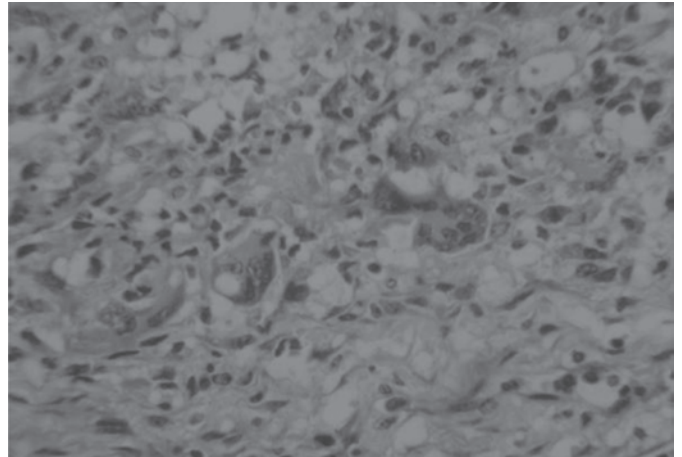


Fig.3. Granulomatous reaction in meninges of affected calf in outbreak D. HE, 100x.

degenerate and viable neutrophils and fewer lymphocytes and macrophages. A segment of the cranial nerves VII and VIII collected from within the petrous bone had microscopic nodules with abundant fibroblasts and giant cells. No histologic lesions were observed in the cerebral cortex, brainstem, cerebellum, lung, heart, liver, kidney, spleen, and gastrointestinal tract. Animals from necropsies #2, #6 and #7 showed no significant microscopic findings.

No viral or bacterial pathogens were isolated from the ocular swabs or CNS tissues and Gridley's, Ziehl-Neelsen, GRAM and Giemsa special stains of sections of the meninges and cranial nerves did not show intralosomal microorganisms. No *Mycoplasma* spp. were detected by IHC of the meninges and cranial nerves VII and VIII. The CBC in all 4 animals from the outbreak F was unremarkable and the serum samples had mild hypocalcemia and normal magnesium and phosphorus serum concentrations.

Bovine Herpesvirus-4 (BHV-4) was isolated from CNS tissue collected from the animal of necropsy #7 (outbreak F).

DISCUSSION

The neurologic signs of facial paralysis and vestibular disease observed in these five outbreaks can be partially explained by the bilateral, space occupying lesions found along the VII (facial) and VIII (vestibulocochlear) cranial nerves in one of the steers necropsied. The severe and also space occupying granulomatous meningitis, found in two of the animals necropsied, may have contributed to the presentation of the neurologic signs. The intracranial space occupying lesions cause compression of the cranial nerves, causing axonal degeneration and loss, which interferes greatly with the normal axonal transport. Attempts to identify an infectious etiologic agent were unsuccessful, although the histologic lesions are suggestive of a chronic, possibly bacterial infection. We speculate that the chronic stage of the lesions in the CNS submitted for viral isolation and bacterial cultures may have hampered the isolation of a specific agent. The isolation of BHV-4 from the CNS of an animal that had neurologic signs but no gross or histo-

logic lesions is likely an incidental finding, with no clinical significance in this case. This virus has been secondarily associated with cases of infertility, abortion and mastitis (Donofrio et al. 2005, Deim et al. 2007).

Listeria monocytogenes can produce facial paralysis and vestibular signs but the epidemiology, the very low mortality, and the absence of the characteristic microabscesses in histological sections of the brainstem rule this agent out. (Radostits et al. 1999b, Campero et al. 2002, Campero 2008). *Prosopis caldenia* was not present on the premises where outbreaks A, C, D, E and F occurred, therefore *Prosopis* sp. poisoning was not a possibility. Tumors that cause dysfunction of the cranial nerves are rare, usually individual and sporadic, and do not manifest as a herd problem (Maenhout et al. 1984).

Otitis externa was not observed in any of the animals examined. Nevertheless, the middle ear was not examined and therefore the presence of otitis media cannot be ruled out. Otitis media is common in calves, generally with an acute presentation, especially during drought seasons (Jensen et al. 1983, Maeda et al. 2003). This is also a frequent pathology found in feedlot cattle and commonly associated with affections of the upper respiratory tract that progress via the Eustachian tube (Williams 1982, Van der Lugt & Jordaan 1994, Walz et al. 1997, Maeda et al. 2003, Francoz et al. 2004). In previous studies, *Pasteurella multocida* prevailed in samples obtained from acute cases, and *Corynebacterium pseudotuberculosis* from chronic cases of otitis media (Jensen et al. 1983). Other bacterial agents that have been implicated with otitis media include *Histophilus somni*, *Streptococcus* spp., *Arcanobacterium pyogenes*, *Actinomyces* spp. and *Mycoplasma bovis* (Walz et al. 1997, Maeda et al. 2003, Duarte & Hamdan 2004, Foster et al. 2009, Francoz et al. 2004). None of these bacteria were found on the bacterial cultures performed from CNS samples and no intralésional bacterial or fungal microorganisms were observed histologically with special stains performed on meninges and cranial nerves. More recently, *Mycoplasma* sp. have been identified in dairy calves with otitis media and vestibular signs, on dairy farms with a high incidence of mastitis and respiratory disease (Maeda et al. 2003, Francoz et al. 2004, Lamm et al. 2004, Foster et al. 2009). In this study, IHC for *Mycoplasma* spp. was negative from samples of the lesions observed within the CNS. In 5 of the 6 outbreaks reported in this study, there is no history of obvious prior respiratory problems nor did the animals show respiratory distress at the time of the clinical observation on the premises. Nevertheless, sub-clinical upper respiratory tract infection or respiratory disease that may have gone undetected cannot be completely ruled out in those 5 outbreaks (A, B, C, D, and F).

One study found a strong correlation between pneumonic and middle ear lesions among slaughtered animals (Jensen et al. 1982) and other authors suggest that the pathogenesis of space occupying lesions affecting the intracranial segments of the cranial nerves involves an initial infection of the upper respiratory tract, which then

spreads through the Eustachian tube into the middle ear and finally reaches the CNS via the VII-VIII cranial nerves (Van Der Lugt & Jordaan 1994). We agree with the pathogenesis proposed by these authors, but in the absence of conclusive evidence, a definitive pathogenesis is yet to be established.

There were common epidemiologic factors in all six outbreaks, including production system, long lasting conditions of drought, diet type, and age of the affected animals which, individually or in combination, may have predisposed the appearance of the disease. According to the clinicopathological similarities in all the outbreaks, we strongly believe that they share the same causal agent/s and pathogenesis.

CONCLUSIONS

The 6 outbreaks of facial paralysis and vestibular syndrome are partially explained by the space occupying lesions found along the intracranial segment of the cranial nerves VII-VIII and leptomeninges.

The etiology of the condition remains undetermined, but a bacterial cause is suspected. Bovine practitioners and cattle producers should consider epidemiologic factors (such as production type, age of the animals, morbidity, and mortality) and clinical signs to suspect the presence of this disease. The support of a veterinary diagnostic laboratory to reach a definitive diagnosis, try to determine the etiology of the disease and better characterize its pathogenesis is mandatory.

REFERENCES

- Cork L.C., Hadlow W.J. & Goreham J. 1974. Pathology of viral leukoencephalomyelitis of goats. *Acta Neuropathol.* 29:281-292.
- Campero C.M., Odeón A.C., Cipolla A.L., Moore D.P., Poso M.A. & Odriozola E. 2002. Demonstration of *Listeria monocytogenes* by immunohistochemistry in formalin-fixed brain tissues from natural cases of ovine and bovine encephalitis. *J. Vet. Med. B* 49:379-383.
- Campero C.M. 2008. *Listeria monocytogenes* en bovinos y ovinos y su rol como zoonosis, p.257-266. In: Cacchione R.A., Durlach R. & Martino P. (Eds), *Temas de Zoonosis. IV. Asociación Argentina de Zoonosis*, Buenos Aires.
- Deim Z., Szeredi L. & Egyed L. 2007. Detection of bovine herpesvirus 4 DNA in aborted bovine fetuses. *Can. J. Vet. Res.* 71:226-229.
- Donofrio G., Cavirani S., Van Santen V. & Flammini C.F. 2005. Potential secondary pathogenic role for bovine herpesvirus 4. *J. Clin. Microbiol.* 43:3421-3426.
- Duarte E.R. & Hamdan J.S. 2004. Otitis in cattle: An aetiological review. *J. Vet. Med. B* 51:1-7.
- Firth E.C. 1977. Vestibular disease and its relationship to facial paralysis in the horse: A clinical study of 7 cases. *Aust. Vet. J.* 53:560-565.
- Foster A.P., Naylor R.D., Howie N.M., Nicholas R.A.J. & Ayling R.D. 2009. *Mycoplasma bovis* and otitis in dairy calves in the United Kingdom. *Vet. J.* 179:455-457.
- Francoz D., Fecteau G., Desrochers A. & Fortin M. 2004. Otitis media in dairy calves: A retrospective study of 15 cases (1987 to 2002). *Can. Vet. J.* 45:661-666.
- George L.W. 1996. Diseases of the nervous system, p.1001-1175, In:

- Smith B.P. (Ed.), Large Animal Internal Medicine. Mosby-Year Book, St Louis, Missouri. 1825p.
- Jensen R., Maki L.R., Lauerman L.H., Raths W.R., Swift B.L., Flack D.E., Hoff R.L., Hancock H.A., Tucker J.O., Horton D.P. & Weibel J.L. 1983. Cause and pathogenesis of middle ear infection in young feedlot cattle. J. Am. Vet. Med. Assoc. 182:967-972.
- Jensen R., Pierson R.E., Weibel J.L., Tucker J.O. & Swift B.L. 1982. Middle ear infection in feedlot lambs. J. Am. Vet. Med. Assoc. 181:805-807.
- Kern T.J. & Erb H.N. 1987. Facial neuropathy in dogs and cats: 95 cases (1975-1985). J. Am. Vet. Med. Assoc. 191:1604-1609.
- Lamm C.G., Munson L., Thurmond M.C., Barr B.C. & George L.W. 2004. *Mycoplasma* otitis in California calves. J. Vet. Diag. Invest. 16:397-402.
- Maeda T., Shibahara T., Kimura K., Wada Y., Sato K., Imada Y., Ishikawa Y. & Kadota K. 2003. *Mycoplasma bovis*-associated suppurative otitis media and pneumonia in bull calves. J. Comp. Pathol. 129:100-110.
- Maenhout D., Ducatelle R., Coussement W., Nuytten J. & Thoonen H. 1984. Space occupying lesions of cranial nerves in calves with facial paralysis. Vet. Rec. 115:407-410.
- Radostits O.M., Gay C.G., Blood D.C. & Hinchcliff K.W. 1999a. Enfermedades del sistema nervioso, p.589-645. In: Ibid. (Eds), Medicina Veterinaria. Vol. 1. Novena Edición. Nueva Editorial Interamericana-McGraw-Hill, España. 1206p.
- Radostits O.M., Gay C.G., Blood D.C. & Hinchcliff K.W. 1999b. Enfermedades causadas por bacterias (I), p. 831-886. In: Ibid. (Eds), Medicina Veterinaria. Vol.1. Novena Edición. Nueva Editorial Interamericana - McGraw-Hill, España. 1206p.
- Tabosa I.M., Riet-Correa F., Barros S.S., Summers B.A., Simões S.V.D., Medeiros R.M.T. & Nobre V.M.T. 2006. Neurohistologic and ultrastructural lesions in cattle experimentally intoxicated with the plant *Prosopis juliflora*. Vet. Pathol. 43:695-701.
- Tokarnia C.H., Döbereiner J. & Peixoto P.V 2000. Plantas que causam perturbações nervosas, p.134-137. In: Ibid. (Eds), Plantas Tóxicas do Brasil. Editorial Helianthus, Rio de Janeiro. 310p.
- Van der Lugt J.J. & Jordaan P. 1994. Facial paralysis associated with the space occupying lesions of cranial nerves in calves. Vet. Rec. 134:579-580.
- Walz P.H., Mullaney T.P., Render J.A., Walker R.D., Mosser T. & Baker J.C. 1997. Otitis media in preweaned Holstein dairy calves in Michigan due to *Mycoplasma bovis*. J. Vet. Diag. Invest. 9:250-254.
- Williams E.I. 1982. An update on selected bovine neurological problems in the United States of America. Proc. 12th World Congress on Diseases of Cattle, The Netherlands, 2:903-907.