

Digital dermatitis of the accessory digits of dairy cows¹

Celso A. Rodrigues^{2*}, Maria C.R. Luvizotto², Ana Liz G. Alves³, Piero H.M. Teodoro³ and Elisa A. Gregório⁴

ABSTRACT.- Rodrigues C.A., Luvizoto M.C.R., Alves A.L.G., Teodoro P.H.M. & Gregório E.A. 2010. **Digital dermatitis of the accessory digits of dairy cows.** *Pesquisa Veterinária Brasileira* 30(3):246-248. Departamento de Clínica, Cirurgia e Reprodução Animal, Curso de Medicina Veterinária, Universidade Estadual Paulista, Campus de Araçatuba, Rua Clovis Pestana 793, Araçatuba, SP 16050-680, Brazil. E-mail: celrodri@fmva.unesp.br

This report characterizes the digital dermatitis (DD) lesions in the accessory digits of dairy cows and presents data on the applied therapy. Fifteen Holstein cattle with DD affecting the accessory digits of the hindlimbs from four dairy farms with previous history of DD were evaluated. Lesions were excised, the wounds were sutured, and a topical application of oxytetracycline powder covered by bandaging was associated with a single parenteral administration of long acting oxytetracycline IM (20mg/kg). Tissue samples were obtained for histopathology and transmission electronic microscopy (TEM). Lesions from all the animals were recuperated 15 days after surgical procedure. Overall, most DD lesions were papillomatous epidermal projections or wartlike verrucous lesions. Histopathologically, samples revealed hyperplasia of epidermis with hyperkeratosis, several mitoses in the stratum basale and elongated rete ridges in the superficial and middle dermis. TEM revealed long, thin spirochete-like bacteria. Morphologic features of lesions and its response to therapy were comparable to those described for DD.

INDEX TERMS: Dairy cattle, accessory digit, dewclaws, digital dermatitis, papillomatosis, spirochetes.

RESUMO.- [Dermatite digital nos dígitos acessórios de vacas leiteiras.] Esse estudo caracteriza lesões de dermatite digital (DD) nos dígitos acessórios de vacas leiteiras, além de apresentar a terapia aplicada. Foram utilizados 15 bovinos leiteiros da raça Holandês com DD nos dígitos acessórios dos membros pélvicos. Os animais eram provenientes de quatro fazendas leiteiras com histórico prévio de dermatite digital (DD). Todos os quinze animais foram tratados da mesma forma: após excisão das lesões e sutura das feridas cutâneas, aplicou-se oxitetraciclina pó topicamente sob bandagem e oxitetraciclina (20mg/kg) de longa ação, via intramuscular. Obtiveram-se amostras de

tecidos para histopatologia, inclusive por microscopia eletrônica de transmissão (MET). Observou-se cicatrização em todos os animais após 15 dias do procedimento cirúrgico. A maioria das lesões macroscópicas foram projeções papilomatosas ou em forma de verrugas. Os achados histopatológicos de todas as amostras revelaram hiperplasia da epiderme com hiperqueratose, inúmeras mitoses no estrato basal, com invasões alongadas em forma de rede na derme superficial e intermediária. A MET evidenciou organismos com formas longas, afiladas e espiraladas, presumivelmente espiroquetas. Tanto as características morfológicas, quanto a resposta à terapia das lesões foram comparáveis às descritas para DD.

TERMOS DE INDEXAÇÃO: Vaca leiteira, dermatite digital, dígitos acessórios, papilomatose, espiroquetas.

INTRODUCTION

Digital dermatitis (DD) is an apparently contagious, painful, circumscribed dermatitis of the feet of cattle. Early lesions are typically red, flat and ulcerative whereas older lesions are raised proliferative with wartlike papillary projections.

¹ Received on July 13, 2009.

Accepted for publication on November 16, 2009.

² Departamento de Clínica, Cirurgia e Reprodução Animal, Curso de Medicina Veterinária, Universidade Estadual Paulista (Unesp), Campus de Araçatuba, Rua Clovis Pestana 793, Jardim Dona Amelia, Aracatuba, SP 16050-680, Brazil. *Autor para correspondência: celrodri@fmva.unesp.br

³ Faculdade de Medicina Veterinária e Zootecnia, Unesp, Campus de Botucatu, Distrito de Rubião Junior, Botucatu, SP 18618-000, Brazil.

⁴ Instituto de Ciências Biológicas, Unesp, Campus de Botucatu, SP.

DD lesions usually occur on the hind feet at or above the plantar interdigital ridge adjacent to the bulbs of the heels (Blowey & Sharp 1988, Döpfer et al. 1997, Read & Walker 1998, Berry 2001), but DD lesions have not been reported to occur above the level of the dewclaws (Berry 2001). DD has been referred to as papillomatous digital dermatitis (PDD), verrucous dermatitis, hairy footwarts and by other names (Read & Walker 1998). While spirochetes *Treponema* sp. are the predominant organisms in DD lesions (Walker et al. 1995, Döpfer et al. 1997, Cruz et al. 2005), polymicrobial communities and a number of management and environmental factors have been associated with a multifactorial etiology for DD (Döpfer et al. 1997, Rodriguez-Lainz et al. 1996, 1999, Edwards et al. 2003, Cruz et al. 2001, 2005). Most DD affected cows may respond favorably to therapy (washing of the lesions preceding topical applications of antibiotics and/or disinfectants preparations followed by bandaging). Topical spray preparations, parenteral antibiotics, and surgical excision, among other methods have all been described as effective methods (Blowey & Sharp 1988, Read & Walker 1998). However, some degree of recurrence of the DD lesions has also been frequently reported. The condition has been reported as a major cause of lameness in numerous countries (Blowey & Sharp 1988, Read & Walker 1998, Argaez-Rodriguez et al. 1997, Rodriguez-Lainz et al. 1999, Berry 2001). In Brazil, preliminary studies already indicated the occurrence of DD since the mid-1990s (Borges et al. 1992, Molina et al. 1999); however, DD lesions were later studied by Cruz et al. (2001, 2005). This communication describes DD lesions affecting an unusual site: the accessory digits of dairy cows, as well as present results on the treatment of the condition.

MATERIALS AND METHODS

Animals used in this study were from four dairy farms with previous history of DD occurrence. Data were collected and animals were treated during farm visits by authors. This study was performed in compliance with institutional guidelines for research on animals. Circular incisions through the skin edges of the lesions were performed and the accessory digits were amputated. The wounds were sutured following topical application of oxytetracycline powder and bandaging. Finally, each animal received a single injection of oxytetracycline IM (20mg/kg) long acting. Tissue samples from all lesions excised were formalin fixed, paraffin embedded, and routinely processed for histology. Ultrastructural analysis was performed on sections from all lesions sampled. The sections were fixed in buffered phosphate (pH 7.3) at 2.5% glutaraldehyde solution for three hours and post fixed 1% osmic acid for two hours. The sections were dehydrated in graded series of ethanol and embedded in Araldite M. Ultrathin sections were cut on a ultramicrotome⁵, stained with uranyl acetate saturated solution and Reynold's lead acetate and examined with a transmission electron microscope.

RESULTS

Fifteen Holsteins, male and female, with different ages and affected with DD on the accessories digits were used in



Fig.1. Severe papillomatous proliferative digital dermatitis in the accessory digit of a dairy cow.

this study. In fourteen animals, lesions were restricted to one affected. Animals were observed for healing 15 days after surgical procedures. Most of DD lesions had papillomatous appearance or were of wartlike verrucous form (Fig.1). The histopathological findings were constant in samples from all animals and included hyperplasia of epidermis with hyperkeratosis, several mitoses in the stratum basale and elongated rete ridges in the superficial and middle dermis. Superficial epidermal necrosis was observed with diffuse infiltrate of polymorphonuclear and mononuclear cells. These findings were also observed in the dermis. The TEM found long, thin spirochete-like organisms with a coat of fibrils in association with the cytoplasmic membrane (Fig.2A-B). During the follow-up period of one year, no recurrence of the proliferative lesions was observed.

DISCUSSION

Gross, microscopic, and ultrastructural findings observed in those DD lesions affecting the accessory digits of dairy cattle were comparable to those described for DD or PDD (Blowey & Sharp 1988, Grund et al. 1995, Read & Walker 1998). Although the lesions studied here were of unknown age, their predominant features of severely proliferative

⁵ LKB Instruments Ltd, Addington Road 232, South Croydon, Surrey CR2 8YDI, London, UK.

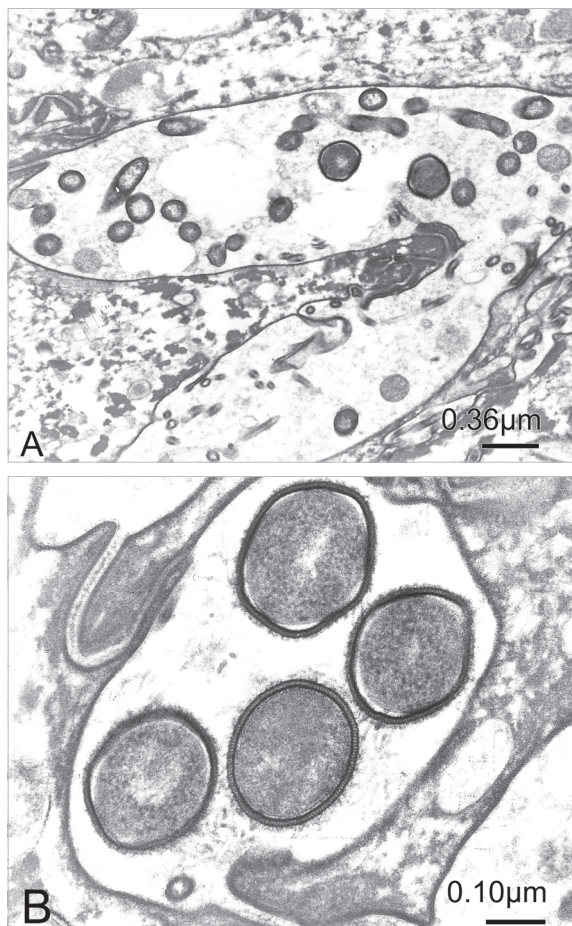


Fig.2. (A) Transmission electron micrograph of the lesion in the accessory digit of a cow showing transversal sections of spirochete-like organisms, amidst epidermal keratinocytes. (B) A coat of fibrils can be observed in association with the cytoplasmic membrane of organisms presumed to be spirochetes.

changes may be associated with advanced processes (Thompson 1984). While a number of topical preparations/approaches have been described to treat DD lesions (Blowey & Sharp 1988, Read & Walker 1998), without excision such proliferative lesions would probably not cure totally with topical antibiotic/disinfectants preparations. Surgical excision associated with topical and parenteral administration of oxytetracycline was highly effective to treat the DD lesions in accessory digits. Similar results have already been reported (Read & Walker 1998). Additional advantages of the method applied in those cases included the reconstitution of anatomical aspect and limited labor and costs, since treatment was completed at one visit to the farm. DD lesions of cattle have been described at varying degrees of severity, varying stages

of development, and different sites of location in the bovine digit (Read & Walker 1998, Cruz et al. 2001). However, although DD lesions have also been referred to affect the accessory digits or dewclaws of cows, this report adds information on DD lesions of such location.

Acknowledgments.- To the technicians from Electron Microscopy Center, Institute of Biological Science of Botucatu. This study was supported by Fundunesp Grant 00432/02-DFP.

REFERENCES

- Argaez-Rodriguez F.J., Hird D.W., Hernandez De Anda J., Read D.H. & Rodriguez-Lainz A. 1997. Papillomatous digital dermatitis on a commercial dairy farm in Mexicali, Mexico: Incidence and effect on reproduction and milk production. *Prev. Vet. Med.* 32:275-286.
- Berry L.S. 2001. Disease of the digital soft tissues. *Vet. Clin. North. Am., Food Anim. Pract.* 17:129-142.
- Blowey R.W. & Sharp M.W. 1988. Digital dermatitis in dairy cattle. *Vet. Rec.* 122:505-508.
- Borges J.R.J., Pitombo C.A., Santiago S.S., Ribeiro P.N. & Ronconi M.A. 1992. Incidência de afecções podais em bovinos leiteiros submetidos a diferentes sistemas de manejo. *Arq. Esc. Med. Vet. UFBA* 15:34-42.
- Cruz C.E., Driemeier D., Cerva C. & Corbellini L.G. 2001. Bovine digital dermatitis in southern Brazil. *Vet. Rec.* 148:576-577.
- Cruz C.E., Pescador C.A., Nakajima Y. & Driemeier D. 2005. Immunopathological investigations on bovine digital epidermitis. *Vet. Rec.* 157:834-840.
- Döpfer D., Koopmans A., Meijer F.A., Szaká L.L.I., Schukken Y.H., Klee W., Bosma R.B., Cornelisse J.L., Van Asten A.J. & Ter Huurne A.A. 1997. Histological and bacteriological evaluation of digital dermatitis in cattle, with especial reference to spirochaetes and *Campylobacter faecalis*. *Vet. Rec.* 140:620-623.
- Edwards A.M., Dymock D. & Jenkinson H.F. 2003. From tooth to hoof: treponemes in tissue-destructive diseases. *J. Appl. Microbiol.* 94:767-780.
- Grund S., Nattermann H. & Horsch F. 1995. Zum elektronenmikroskopischen Spirochäten-Nachweis bei der Dermatitis digitalis des Rindes. *J. Vet. Med. B* 42:533-542.
- Molina L.R., Carvalho A.U., Facury Filho E.J., Ferreira P.M. & Ferreira V.C.P. 1999. Prevalência das afecções podais em vacas lactantes na bacia leiteira de Belo Horizonte. *Arq. Bras. Med. Vet. Zootec.* 51:149-152.
- Read D.H. & Walker R.L. 1998. Papillomatous digital dermatitis (footwarts) in California dairy cattle: Clinical and gross pathologic findings. *J. Vet. Diagn. Invest.* 10:67-76.
- Rodriguez-Lainz A., Hird D.W., Carpenter T.E. & Read D.H. 1996. Case-control study of papillomatous digital dermatitis in southern California dairy farms. *Prev. Vet. Med.* 28:117-131.
- Rodriguez-Lainz A., Melendez-Retamal P., Hird D.W., Read D.H. & Walter R.L. 1999. Farm- and host-level risk factors for papillomatous digital dermatitis in Chilean dairy cattle. *Prev. Vet. Med.* 42:87-97.
- Thompson R.G. 1984. *General Veterinary Pathology*. 2nd ed. W.B. Saunders, Philadelphia, p163-280.
- Walker R.L., Read D.H., Loretz K.J. & Nordhausen R.W. 1995. Spirochetes isolated from dairy cattle with papillomatous digital dermatitis and interdigital dermatitis. *Vet. Microbiol.* 47:343-355.