

## Retrospective study on clinical management of indolent ulcers in Boxer dogs<sup>1</sup>

Ana Paula Hvenegaard<sup>2\*</sup>, Joaquim E. Vieira<sup>3</sup>, Daniela C. Leandro<sup>2</sup>, Ana Carolina Góes<sup>2</sup>,  
Angélica M.V. Safatle<sup>2</sup> and Paulo S.M. Barros<sup>2</sup>

**ABSTRACT.** Hvenegaard A.P., Vieira J.E., Leandro D.C., Góes A.C., Safatle A.M.V. & Barros P.S.M. 2011. **Retrospective study on clinical management of indolent ulcers in Boxer dogs.** *Pesquisa Veterinária Brasileira* 31(10):910-915. Departamento de Cirurgia, Faculdade de Medicina Veterinária e Zootecnia, Universidade de São Paulo, Av. Prof. Dr. Orlando Marques de Paiva 87, São Paulo, SP 05508-270, Brazil. E-mail: [ana6113@hotmail.com](mailto:ana6113@hotmail.com)

Indolent ulcers are superficial corneal ulcers secondary to several changes on the corneal surface. They are frequently observed in middle-aged Boxer dogs, cause pain of acute onset and requires appropriate treatment. Aiming to evaluate the efficacy of clinical managements on the rate of healing of indolent ulcers, a retrospective study was conducted (1997-2008). Results demonstrated that proteinase inhibitors were the most often prescribed medication, and its administration did not interfere on the healing rate, as well as observed in dogs that received 1% atropine, antibiotics and anti-inflammatory drugs. Healing was delayed in dogs administered orally with vitamin C, but the healing process was faster on those dogs that went through corneal debridement/cauterization. In conclusion, to know the various types of treatments seems to be fundamental for the rapid resolution of the disease. It is suggested that debridement/cauterization, administration of proteinase inhibitor eye drops, prophylactic topical antibiotics and oral vitamin C, should be considered as an effective clinical management for indolent ulcers in Boxer dogs.

**INDEX TERMS:** Indolent ulcers, Boxer dogs, treatment, proteinase inhibitors, vitamin C, debridement/cauterization, dogs.

**RESUMO.- [Estudo retrospectivo do tratamento clínico da úlcera indolente em cães da raça Boxer.]** Úlceras indolentes são úlceras corneais superficiais e espontâneas, que apresentam curso prolongado e que tendem a recidivar. Comumente observadas em cães de meia idade da raça Boxer, provoca dor de início agudo e necessita de tratamento específico, já que este, quando não realizado corretamente, pode prolongar o curso da lesão por semanas a meses. Com o objetivo de avaliar a eficácia dos tratamentos clínicos quanto à rapidez na resolução do quadro, realizou-se estudo retrospectivo (1997 a 2008). Observou-se que os inibidores das proteinases foram as medicações mais

frequentemente prescritas e que sua administração não interferiu no tempo de cicatrização corneal, o que também foi observado nos casos em que se administrou antibióticos e anti-inflamatórios tópicos e sistêmicos e/ou atropina 1%. A administração de vitamina C retardou, de maneira estatisticamente significativa, o tempo de cicatrização. Por outro lado, a realização do debridamento/cauterização corneal acelerou, significativamente, o processo. Conhecer os diversos tipos de tratamentos parece ser fundamental no sucesso e rapidez da resolução da doença. Os autores sugerem que a realização do debridamento/cauterização corneal, administração de inibidores das proteinases e antibióticos tópicos, associados à vitamina C por via oral, seja considerado um tratamento clínico efetivo na rápida resolução da doença.

**TERMOS DE INDEXAÇÃO:** Úlcera indolente, Boxer, tratamento, inibidores das proteinases, vitamina C, debridamento, cães.

### INTRODUCTION

Indolent ulcers are spontaneous superficial corneal ulcers, commonly observed in middle-aged Boxer dogs that cau-

<sup>1</sup> Received on March 3, 2011.

Accepted for publication on August 27, 2011.

<sup>2</sup> Departamento de Cirurgia, Faculdade de Medicina Veterinária e Zootecnia (FMVZ), Universidade de São Paulo (USP), Av. Prof. Dr. Orlando Marques de Paiva 87, Bloco 8 superior, Cidade Universitária, São Paulo, SP 05508 270, Brazil. \*Corresponding author: [ana6113@hotmail.com](mailto:ana6113@hotmail.com)

<sup>3</sup> Faculdade de Medicina (FM), USP, Av. Dr. Arnaldo 455, Cerqueira César, São Paulo, SP 01246903.

ses pain of acute onset, presents prolonged course and a tendency to relapse (Gelatt & Samuelson 1982, Kirschner 1990, Morgan & Abrams 1994, Stanley et al. 1998, Campbell & Murphy 1999, Bentley et al. 2001, Murphy et al. 2001, Gelatt 2003, Ledbetter et al. 2003b, Bentley 2005, Slatter 2005). The pathogenesis of the condition includes several changes on the ocular surface, which induce its appearance and prolongs the healing period (Gelatt & Samuelson 1982, Kirschner et al. 1989, Kirschner 1990, Bentley et al. 2001, Brooks et al. 2002, Ollivier et al. 2002, Slatter 2005). Main recommended treatments are punctate and grid keratotomies and superficial keratectomy. Despite of its excellent results, those procedures are invasive and may require general anesthesia. Clinical management of the indolent ulcer, including epithelial debridement/cauterization and the administration of topic and/or systemic drugs, may also be capable to treat the cornea (Stanley et al. 1998, Bentley et al. 2001, Ledbetter et al. 2003a, Ledbetter et al. 2003b, Bentley, 2005).

Combinations of antibiotics are commonly prescribed for the treatment of indolent ulcers in dogs (Slatter 2005), although, some of those may be toxic to the corneal epithelium, such as bacitracin, gentamicin and neomycin sulfate (Petroustos et al. 1983), ofloxacin (Moreira et al. 1997, Marino et al. 2005) and ciprofloxacin (Moreira et al. 1997, Jensen et al. 2005, Marino et al. 2005). Despite of the toxicity of tobramycin at the reepithelization process, this medication induces fewer morphological alterations on corneal cells when compared to fluoroquinolones (Nelson et al. 1990, Hendrix et al. 2001).

The prescription of anti-inflammatory drugs, although rather common is controversial, since previous studies observed that some of those may prejudice epithelial regeneration, such as glycosaminoglycan polysulfate, suprofen, hydrocortisone and dexamethasone (Hendrix et al. 2001, Slatter 2005), and some don't, such as sodium diclofenac (Loya et al. 1994), ketorolac tromethamine and nepafenac (Donnenfeld et al. 2007, Durrie et al. 2007). Atropine eye drops is often prescribed in order to relieve the spasm of the ciliary muscle (pain), due to anterior uveitis secondary to the ulcer. Its performance may last 24 hours or more, however, this drug is contraindicated in breeds that are susceptible to glaucoma, animals diagnosed with lens luxation or presenting keratoconjunctivitis sicca (Hollingsworth et al. 1992, Slatter 2005).

Administration of proteinase inhibitors (collagenase and metalloproteinase) is referred by many authors as an important part of the treatment, but is seldom prescribed by veterinarians. This drug is capable to promote stability and give support to the corneal tissue on its restructuration (Berman 1975, Burns et al. 1989, Brooks et al. 2002), reduce proteolytic activity of ocular surface (Ollivier et al. 2002) and even accelerate the process of reepithelialization (Aldavood et al. 2003). Acetylcysteine, ethylenediaminetetraacetic acid (EDTA) and blood serum ( $\alpha$ -2 macroglobulin), are some of the available proteinase inhibitors on veterinary ophthalmology practice (Aldavood et al. 2003). Orally vitamin C (ascorbic acid), may also be recommended for the treatment of indolent ulcers by its capacity to sti-

mulate and regulate the synthesis of collagen, fibroblasts and components of the extracellular matrix in the cornea (Saika et al. 1992, Gross 2000, Stojanovic et al. 2003, Guo et al. 2007).

The removal of the non adherent corneal epithelium is known as debridement/cauterization (Stanley et al. 1998, Ledbetter et al. 2003a, Slatter 2005). It can be performed with sterile dry swabs (debridment) (Stanley et al. 1998), or utilizing swabs impregnated with different chemical agents (debridement/cauterization), such as trichloroacetic acid, phenol liquid, tincture of iodine or diluted povidone iodine (Gelatt 2003, Slatter 2005).

Aiming to assess the effectiveness of the clinical management performed by the Ophthalmology Service of the HOVET-FMVZ-USP, on the rate of healing indolent ulcers in Boxer dogs, a retrospective study of cases treated from 1997 to 2008 was conducted.

## MATERIALS AND METHODS

Medical records of Boxer dogs examined from 1997 to 2008 at the Ophthalmology Service of the Veterinary Hospital (HOVET-FMVZ-USP) were reviewed. Animals diagnosed with indolent ulcer after the ophthalmological examination, including fluorescein dye<sup>4</sup>, applanation tonometry<sup>5</sup> and slit lamp biomicroscopy<sup>6</sup> were separated for the study (Fig.1). Defined exclusion criteria included that: animals could not present indolent ulcers secondary to eyelid abnormalities, keratoconjunctivitis sicca or any other ophthalmopathy that could justify its development; could not present concurrent systemic diseases requiring any medication; dogs should have been only submitted to clinical management, including eye drops, systemic medications and corneal debridement/cauterization. Records should be complete and correctly filled, from the diagnosis till the day of corneal cicatrization.

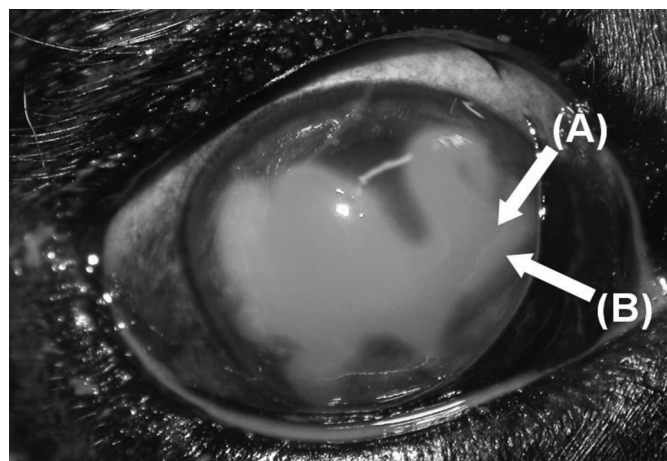


Fig.1. Indolent ulcer in the right eye of a 7-year-old Boxer dog, after fluorescein dye instillation. Observe the edge of the lesion at (A) and the fluorescein stain under degenerated and unattached epithelium.

<sup>4</sup> Colírio de fluoresceína 1%, Ophthalmos Indústria Farmacêutica, Rua Nhandirobas 471, São Paulo, SP, Brazil.

<sup>5</sup> Tono-pen XL®, Mentor Ophthalmics, 280 Bridge Street Dedham, MA, USA.

<sup>6</sup> SL-15®, Kowa Optimed Inc., 20001 South Vermont Ave, Torrance, CA, USA.

To evaluate studied parameters, authors first identified all kinds of treatments recommended by veterinarians of the Ophthalmology Service of the HOVET-FMVZ-USP during studied period. After that, each ulcer was correlated with its day of cicatrization and treatment. To facilitate the analysis, medications were organized in groups, such as: every ulcer treated with proteinaase inhibitors formed group (A); the ones that received vitamin C orally, group (B); corneal debridement/cauterization with povidone iodine, group (C); the group of animals that received antibiotics, administered either topically as systemically, group (D); ulcers in which topical 1% atropine was administered, group (E) and, finally, topical or systemic anti-inflammatories, steroidal and nonsteroidal, formed group (F). Despite of most dogs had been treated by one or more groups, authors decided to evaluate treatments separately, comparing cases that received, with the ones that did not receive the evaluated group of treatment.

### Statistical analysis

The effectiveness of the different groups at the quickness on the resolution of the wound were evaluated comparing, by statistical analysis (SPSS 15.0 for Windows<sup>7</sup>), the taken time to cicatrize ulcers utilizing the group of treatment, with the taken time to cicatrize ulcers that did not utilize the same group of treatment (Mann-Whitney, utilizing Kolmogorov-Smirnov = K-S

to justify results). The capacity of those different groups on healing ulcers in less than 30 days, in other words, the capacity to accelerate the cicatrization process was evaluated by the Exact Fisher test. Statistical values for "p", calculated by Kruskal-Wallis, which resulted in  $p < 0.05$ , were considered statistically significant.

## RESULTS

Boxer dogs examined at the Ophthalmology Service, HOVET-FMVZ-USP, from 1997-2008 totaled 324, of which 189 (58.33%) were diagnosed with indolent ulcer. However, 47 dogs met the exclusion criteria; thus, 142 cases in 120 records (dogs) were studied, being 67 (55.83%) females and 53 males (44.17%), with ages from 1-12 years old (mean 7.71). Some of the studied animals also presented systemic diseases concomitant to the lesion, such as mastocytoma (n=12), some degree of heart disease (n=7) or arthritis (n=2). As refereed dogs were not under any type of treatment, were also included in this study.

Clinical history showed that most dogs (n=126, 88.73%) had been examined by other veterinarians and were having topical and/or systemic drugs unsuccessfully. Blepharospasm (n=99, 69.72%), red eyes (conjunctival hyperemia and/or congestion) (n=98, 69.01%) and ocular discharge (n=92, 64.79%), were the most referred ocular alterations at the first consultation. Besides that, some owners reported apathy (n=2) and disorexia (n=1); others, tried to attempt the diagnostic, suggesting that their animals were presenting glaucoma (n=3), cataracts (n=2) or conjunctivitis (n=1). Trauma was reported in 10 cases as the cause of the wound. Ophthalmological examination at first consultation revealed that most ulcers were unilateral (n=130), however, 6 animals presented the disease in both eyes, simultaneously. Recurrence was observed after some time at

the contralateral eye (n=10) or at the previous affected eye (n=4). Indolent ulcers were more frequently observed at the right (n=77, 54.23%) than the left eye (n=65, 45.77%), usually located at the center of the cornea (n=57, 40.14%), presenting discontinuation of the epithelium (n=49, 34.51%), discontinuation of the epithelium with neovascularization (n=34, 23.94%) or discontinuation of the epithelium and granuloma (n=17, 11.97%).

Regarding treatment, incidence of recommended groups (Fig.2), frequency of administration and their respective mean time of healing are described in the following topics:

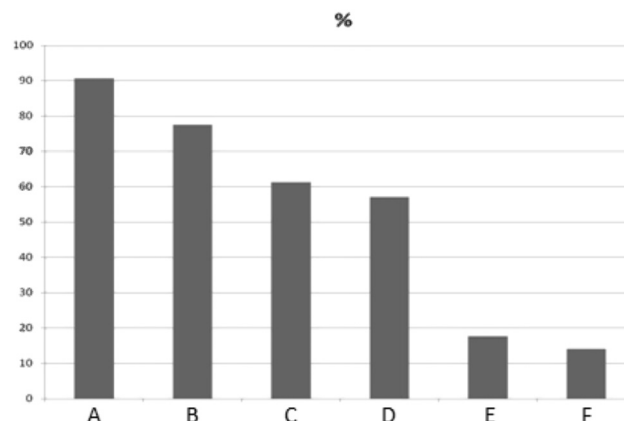


Fig.2. Graphical representation of the different groups of recommended treatment, according to the percentage of ulcers. (A) Proteinase inhibitors; (B) Vitamin C; (C) Corneal debridement/cauterization; (D) Topical or systemical antibiotics; (E) 1% atropine and (F) Topical or systemical, steroidal or nonsteroidal anti-inflammatories.

- Proteinase inhibitors, administered four times daily, were one of the most frequently prescribed medications (n=129 cases, 90.68%), with an average healing time of about 30 days (7-132 days). Acetylcysteine 10% was prescribed for 121 cases, 5% acetylcysteine and 0.35% EDTA for 4 cases each. Statistically, its administration did not interfere at corneal healing rate (Table 1).

Table 1. Distribution of recommended groups of treatments according to the corneal healing time

Group of treatment <sup>a</sup>	Used		Not used		p
	Ulcers (cases)	Healing time Mean $\pm$ SD (days)	Ulcers (cases)	Healing time Mean $\pm$ SD (days)	
(A)	129	30,95 $\pm$ 19,56	13	30,38 $\pm$ 21,63	0,648
(B)	110	32,69 $\pm$ 20,81	32	24,75 $\pm$ 13,71	<b>0,023</b>
(C)	87	26,64 $\pm$ 15,52	55	37,64 $\pm$ 23,5	<b>p&lt;0,0001</b>
(D)	81	31,99 $\pm$ 21,96	61	29,46 $\pm$ 16,23	0,593
(E)	25	39,24 $\pm$ 33,43	117	29,12 $\pm$ 14,88	0,672
(F)	20	41,55 $\pm$ 35,17	122	29,15 $\pm$ 15,34	0,420

<sup>a</sup> (A) = Proteinase inhibitors; (B) = Vitamin C; (C) = Corneal debridement/cauterization; (D) = Topical or systemical antibiotics; (E) = atropine 1%; (F) = Topical or systemical, steroidal or nonsteroidal anti-inflammatory drugs. SD = Standard Deviation.

<sup>7</sup> SPSS 15.0 for Windows, SPSS Incorporation, 1989-2006, IBM Company Headquarters, 233 S. Wacker Drive, 11th floor, Chicago, IL, USA.

- Orally vitamin C (ascorbic acid, 500 milligrams), was prescribed twice daily and was the second most routinely prescribed medication by HOVET-USP veterinarians (n=110, 77.46%). Statistically significant results demonstrated that this medication prolonged the cicatrization period when compared to dogs whose vitamin was not administered (about 32 days, 7-132 days).
- Corneal debridement/cauterization was the third most accomplished clinical treatment. The procedure was realized after topical anesthesia<sup>8</sup> in 87 cases (61.28%), utilizing a tweezer of smoothed edges and a small piece of cotton<sup>9</sup> impregnated with povidone iodine<sup>10</sup>, diluted at 0.2% in distilled water<sup>11</sup> (Fig.3), repeated after 20 days in 5 cases, and again after 20 days (40 days) in one case. It was able to heal 100% of the wounds which were debrided/seared, did not induce granuloma formation and presented statistically significant shorter period of healing (average 26 days, 7 to 132 days), suggesting that this treatment may, probably, accelerate corneal wound healing in less than 30 days (p<0.05) (Table 2).

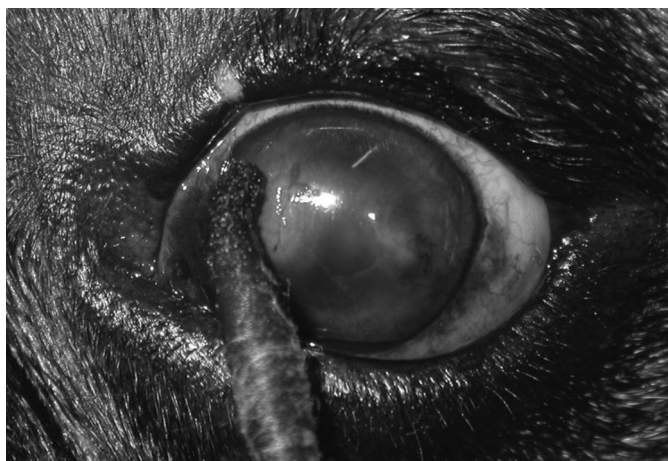

Fig.3. Corneal debridement/cauterization, performed at the left eye of a 8-year-old Boxer dog after topical anesthesia, utilizing a tweezer of smoothed edges and cotton tip, impregnated with povidone iodine, diluted at 0.2% in distilled water.

- Antibiotic therapy, administered four times daily as eye drops or in recommended doses for dogs when systemically administered, was the fourth group of drugs prescribed at the HOVET (n=81, 57,04%). It was prescribed tobramycin 0.3% eye drops for 60 (42%) of the 142 studied cases, ofloxacin for 12 cases, ciprofloxacin for 6 cases, gatifloxacin for 1 case and chloramphenicol ointment for one case. Veterinary eye drops containing chondroitin sulfate summed 8 of the 60 cases which were prescribed tobramycin, and 3 of the 6 cases which were prescribed

**Table 2. Distribution of groups of recommended treatments and corneal healing time within 30 days**

Group of treatment <sup>a</sup>	Within 30 days		More than 30 days		p
	Used	Not used	Used	Not used	
(A)	81	9	48	4	0,768
(B)	67	23	43	9	0,302
(C)	61	29	26	26	<b>0,049</b>
(D)	48	42	33	19	0,292
(E)	14	76	11	41	0,493
(F)	10	80	10	42	0,214

<sup>a</sup> (A) = Proteinase inhibitors; (B) = Vitamin C; (C) = Corneal debridement/cauterization; (D) = Topical or systemical antibiotics; (E) = 1% atropine 1%; (F) = Topical or systemical, steroidal or nonsteroidal anti-inflammatory drugs.

ciprofloxacin. Enrofloxacin was orally prescribed for one case. Statistical analysis of this group was not performed according to each type of antibiotic, but by the evaluation of its management. Overall, antibiotics did not affect the healing rate (mean of 32 days, 5-132 days).

- 1% atropine eye drops was prescribed 1-3 times daily, for up to the first 20 days, for 25 cases (17%). It was observed that, despite of the prolonged healing time (mean of 39 days, 7-132 days), these data was not statistically significant.
- Topical and systemic anti-inflammatories, also administered four times daily as eye drops or in recommended doses for dogs when systemically administered, were occasionally prescribed (n=20, 14,08%). Nonsteroidal anti-inflammatory eye drops was the most frequently recommended medication. Sodium diclofenac eye drops was prescribed for 11 cases and ketorolac tromethamine for 3. Systemically, meloxicam was prescribed to one case and flunixin meglumine to another case. Prescribed steroidal anti-inflammatories included fluocinolone and dexamethasone. According to statistics, despite of these drugs had present the highest average healing time (41 days, 5-132 days), these data was not statistically significant. It was also observed that one dog, utilizing meloxicam and another, topical diclofenac, led the wounds to corneal melting

## DISCUSSION

Indolent ulcers were often observed in middle-aged Boxer dogs at the Ophthalmology Service practice of the HOVET-FMVZ-USP, what was also frequently observed by many authors in several previous studies (Gelatt & Samuelson 1982, Kirschner et al. 1989, Morgan & Abrams 1994, Stanley et al. 1998, Bentley et al. 2001, Murphy et al. 2001, Gelatt 2003, Ledbetter et al. 2003b, Bentley 2005, Slatter 2005). Most studied dogs presented the ocular alteration for some time before first consultation (Gelatt & Samuelson 1982, Kirschner et al. 1989, Stanley et al. 1998, Murphy et al. 2001, Ledbetter et al. 2003b, Bentley 2005) and had tried different treatments unsuccessfully. Authors believe that some of the dogs may had presented intermittent recurrence of the disease or must had been under inadequate treatments. The prescription of appropriate medication is

<sup>8</sup> Anestalcon®, Cloridrato de Proximetacaína 0,5%, Alcon Labs do Brasil Ltda, Av. Nossa Senhora Assunção 736, VI, Butantã, São Paulo, SP, Brazil.

<sup>9</sup> Cremer S/A Produtos Textéis Cirurgicos, Rua Comendador Jose de Mattos 83, VI, Clarice, São Paulo, SP, Brazil.

<sup>10</sup> Povidine Anti-Séptico Tópico. Vic Pharma Indústria e Comércio Ltda, Rua Geraldo Rosa 62, Taquaritinga, SP, Brazil.

<sup>11</sup> Água destilada. Darrow, Rua Marquês de Olinda 69, Rio de Janeiro, RJ 22251-040, Brazil.

crucial for its healing (Kirschner 1990, Campbell & Murphy 1999, Bentley 2005) and its recurrence is not uncommon (Gelatt & Samuelson 1982, Kirschner et al. 1989, Gelatt 2003), which may occur in approximately 50% of the dogs (Gelatt & Samuelson 1982). Only 14 (9.86%) ulcers, of the 142 studied cases recurred at the same or in the contralateral eye. Furthermore, only 6 animals presented the ulcer in both eyes simultaneously, which was also occasionally observed by other authors in previous studies (Gelatt & Samuelson 1982, Kirschner et al. 1989). As reported by several authors, blepharospasm, red eyes and ocular discharge were also the most reported ocular alterations during first consultation (Gelatt & Samuelson 1982, Kirschner et al. 1989, Morgan & Abrams 1994, Stanley et al. 1998, Bentley et al. 2001, Murphy et al. 2001, Gelatt 2003, Bentley 2005, Slatter 2005).

Some authors suggests trauma, occurred weeks or even months before the appearance of the ulcer, to be one of the causes of the disease (Kirschner et al. 1989), which was also reported by 10 owners in our study. However, most studies show that indolent ulcer occurs spontaneously, being this one of its main diagnostic features (Gelatt 2003, Bentley 2005, Slatter 2005). Corroborating with previous studies, it was observed that most ulcers were unilateral, transparent, presenting only the discontinuation of the epithelium or neovascularization, located at the center of the cornea and that, besides the slightly difference between the occurrence at right and left eyes, it was hardly statistically significant (Gelatt & Samuelson 1982, Kirschner et al. 1989, Kirschner 1990, Bentley et al. 2001, Hendrix et al. 2001, Murphy et al. 2001, Gelatt 2003, Ledbetter et al. 2003a, Ledbetter et al. 2003b, Slatter 2005). In spite of some authors refer that granuloma may be frequently observed in Boxer dogs (Gelatt & Samuelson 1982, Bentley 2005, Slatter 2005), granuloma and corneal edema were only occasionally diagnosed.

Different types of medications were prescribed by other veterinarians before the first consultation, some of those were kept, but others interrupted for being considered inappropriate for its treatment (Gelatt & Samuelson 1982, Kirschner 1990, Campbell & Murphy 1999, Gelatt 2003, Bentley 2005, Slatter 2005). Despite of previous studies had referred that proteinase inhibitors may be capable to accelerate the process of reepithelialization (Aldavood et al. 2003), it was observed that it doesn't interfere at the corneal healing rate (Petroutsos et al. 1982, Aldavood et al. 2003). Nevertheless, authors suggest its administration in every case of indolent ulcer aiming to reduce the proteolytic activity of the ocular surface (Ollivier et al. 2002) and to give support to corneal tissue on its restructuration (Berman 1975, Brooks et al. 2002, Burns et al. 1989). Orally vitamin C (ascorbic acid) prolonged the cicatrization period when compared to studied dogs whose vitamin was not administered. Authors didn't find any previous studies referring the healing rate when vitamin C is administered, but recommend its administration aiming to stimulate and regulate the synthesis of collagen, fibroblasts and components of the extracellular matrix in the cornea (Saika et al.

1992, Gross 2000, Stojanovic et al. 2003, Guo et al. 2007) and restore levels during corneal injury (Bilgihan et al. 2001).

Although several studies has refereed debridement/cauterization to be less efficient than keratotomies or keratectomies (Gelatt & Samuelson 1982, Kirschner et al. 1989, Kirschner 1990, Stanley et al. 1998, Bentley et al. 2001, Gelatt 2003, Slatter 2005), authors decided to study only this procedure because of the facility and safety on its realization. This procedure appears to be fundamental to corneal healing, since it was capable to heal 100% of the wounds, most of them in less than 30 days. Removal of corneal epithelium beyond the margins of the ulcers and repetition of the technique were frequently observed in this study and often referred by many authors (Kirschner et al. 1989, Stanley et al. 1998, Gelatt 2003).

According to the literature, indolent ulcers present no contamination (Bentley et al. 2001, Hendrix et al. 2001), as so, antibiotics should only be prescribed prophylactically (Bentley 2005). Overall, antibiotics did not affected the healing rate in studied cases, being therefore recommended by authors to be administered 4 times daily, for the first 10 days, especially in cases that underwent corneal debridement/cauterization, what could increase corneal vulnerability to infection by the loss of its basement membrane (Kirschner 1990). Topical and systemic anti-inflammatories were occasionally prescribed. Despite of this type of medication be able to promote the return of corneal transparency in cases of opaque and vascularized wounds, it may also increase the risk of corneal infection (Slatter 2005). Authors agree that it should only be administered after ulcer healing, since 2 cases of corneal melting were observed in our study. To know the various types of treatments appears to be fundamental to the rapid resolution of the disease; therefore, based on presented results, authors suggest that debridement/cauterization, administration of proteinase inhibitors eye drops, prophylactic topical antibiotics and orally vitamin C, should be considered an effective clinical management for indolent ulcers in Boxer dogs.

**Acknowledgement.**- To CAPES (Coordenação de Aperfeiçoamento de Pessoal de Nível Superior) and to the staff of the HOVET-FMVZ-USP, in retrieving studied medical records.

## REFERENCES

- Aldavood S.J., Behyar R., Sarchahi A.A., Rad M.A., Noroozian I., Ghamsari S.M. & Sadeghi-Hashjin G. 2003. Effect of Acetylcysteine on Experimental Corneal Wounds in Dogs. *Ophthal. Res.* 35:319-323.
- Bentley E. 2005. Spontaneous chronic corneal epithelial defects in dogs: A review. *J. Am. Anim. Hosp. Assoc.* 41:158-165.
- Bentley E., Abrams G.A., Covitz D., Cook C.S., Fischer C.A., Hacker D., Stuhr C.M., Reid T.W. & Murphy C.J. 2001. Morphology and immunohistochemistry of spontaneous chronic corneal epithelial defects (SCCED) in Dogs. *Invest. Ophthalmol. Vis. Sci.* 42(10):2262-2269.
- Berman N. 1975. Collagenase inhibitors: rational for their use in treating corneal ulceration. *Int. Ophthalmol. Clin.* 15(4):49-66.
- Bilgihan A., Bilgihan K., Toklu Y., Konuk O., Yis O. & Hasanreisoglu B. 2001. Ascorbic acid levels in human tears after photorefractive keratectomy, transepithelial photorefractive keratectomy, and laser in situ keratomileusis. *J. Cataract. Refract. Surg.* 27(4):585-588.

- Brooks D.E., Ollivier F.J., Schultz G.S., Andrew S.E., Gelatt K.N., Lassaline M.E. & Kallberg M.E. 2002. Duration of in vitro inhibitory activity of equine serum against equine tear film matrix metalloproteinase. American College of Veterinary Ophthalmologists (Abstract 23). *Vet. Ophthalmol.* 5:283-301.
- Burns F.R., Stack M.S., Gray R.D. & Parerson C.A. 1989. Inhibition of Purified Collogenase from Alkali-Burned Rabbit Corneas. *Invest. Ophthalmol. Vis. Sci.* 30(7):1569-1575.
- Campbell S. & Murphy C. 1999. Clinical characterization of spontaneous, chronic, non-septic corneal epithelial defects in dogs. *Invest. Ophthalmol. Vis. Sci.* 40(4):337.
- Donnenfeld E.D., Holland E.J., Durrie D.S. & Raizman M.B. 2007. Double-masked study of the effects of nepafenac 0.1% and ketorolac 0.4% on corneal epithelial wound healing and pain after photorefractive keratectomy. *Adv. Ther.* 24(4):852-862.
- Durrie D.S., Kennard M.G. & Boghossian A.J. 2007. Effects of nonsteroidal ophthalmic drops on epithelial healing and pain in patients undergoing bilateral photorefractive keratectomy (PRK). *Adv. Ther.* 24(6):1278-1285.
- Gelatt K.N. 2003. *Manual de Oftalmologia Veterinária*. 3ª ed. Manole, Barueri. 594p.
- Gelatt K.N. & Samuelson D.A. 1982. Recurrent corneal erosions and epithelial dystrophy in the boxer dog. *J. Am. Anim. Hosp. Assoc.* 18:453-460.
- Gross R.L. 2000. The effect of ascorbate on wound healing. *Int. Ophthalmol. Clin.* 40(4):51-57.
- Guo X., Hutcheon A.E.K., Melotti S.A., Zieske J.D., Trinkaus-Randall V. & Ruberti J.W. 2007. morphologic characterization of organized extracellular matrix deposition by ascorbic acid-stimulated human corneal fibroblasts. *Invest Ophthalmol. Vis. Sci.* 48:4050-4060.
- Hendrix D.V., Ward D.A. & Barnhill M.A. 2001. Effects of antibiotics on morphologic characteristics and migration of canine corneal epithelial cells in tissue culture. *Am. J. Vet. Res.* 62:1664-1669.
- Hendrix D.V., Ward D.A. & Barnhill M.A. 2002. Effects of anti-inflammatory drugs and preservatives on morphologic characteristics and migration of canine corneal epithelial cells in tissue culture. *Vet. Ophthalmol.* 5(2):127-135.
- Hollingsworth S.R., Canton D.D., Buyukmihci N.C. & Farver T.B. 1992. Effect of topically administered atropine on tear production in dogs. *J. Am. Vet. Med. Assoc.* 200(10):1481-1484.
- Jensen H., Zerouala C., Carrier M. & Short B. 2005. comparison of ophthalmic gatifloxacin 0.3% and ciprofloxacin 0.3% in healing of corneal ulcers associated with *Pseudomonas aeruginosa*-induced ulcerative keratitis in rabbits. *J. Ocul. Pharmacol. Ther.* 21(1):36-42.
- Kirschner S.E. 1990. Persistent corneal ulcers. What to do when ulcers won't heal. *Vet. Clin. North Am., Small Anim. Pract.* 20(3):627-643.
- Kirschner S.E., Niyo Y. & Betts D.M. 1989. Idiopathic persistent corneal erosions: clinical and pathological findings in 18 dogs. *J. Am. Anim. Hosp. Assoc.* 25:84-90.
- Ledbetter E.C., Munger R.J. & Ring R.D. 2003a. Efficacy of a topical antibiotic-chondroitin sulfate solution in the therapy of recurrent corneal erosions: A preliminary report. American College of Veterinary Ophthalmologists (Abstract 29). *Vet. Ophthalmol.* 6:343-350.
- Ledbetter E.C., Munger R.J. & Ring R.D. 2003b. Efficacy of topical antibiotic-chondroitin sulfate solutions in the therapy of canine recurrent corneal erosions. American College of Veterinary Ophthalmologists (Abstract 21). *Vet. Ophthalmol.* 6:351-366.
- Loya N., Bassage S., Vyas S., del Cerro M., Park S.B. & Aquavella J.V. 1994. Topical diclofenac following excimer laser: Effect on corneal sensitivity and wound healing in rabbits. *J. Refract. Surg.* 10(4):423-427.
- Marino C., Paladino G.M., Scuderi A.C., Trombetta F., Mugridge K. & Enea V. 2005. *In vivo* toxicity of netilmicin and ofloxacin on intact and mechanically damaged eyes of rabbit. *Cornea* 24(6):710-716.
- Moreira L.B., Lee R.F., Oliveira C., Labree L. & McDonnell P.J. 1997. Effect of topical fluoroquinolones on corneal re-epithelialization after excimer laser keratectomy. *J. Cataract. Refract. Surg.* 23(6):845-848.
- Morgan R.V. & Abrams K.L. 1994. A comparison of six different therapies for persistent corneal erosions in dogs and cats. *Vet Comp of Ophthalmol.* 4:38-43.
- Murphy C.J., Marfurt C.F., McDermott A., Bentley E., Abrams G.A., Reid T.W. & Campbell S. 2001. Spontaneous chronic corneal epithelial defects in dogs: Clinical features, innervation, and effect of topical SP, with or without IGF-12. *Invest. Ophthalmol. Vis. Sci.* 42:2252-2261.
- Nelson J.D., Silverman V., Lima P.H. & Beckman G. 1990. Corneal epithelial wound healing: a tissue culture assay on the effect of antibiotics. *Cur. Eye Res.* 9(3):277-285.
- Ollivier F.J., Brooks D.E., Kallberg M.E., Komaromy A.M., Lassaline M.E., Cutler T.J., Sapp H.L. & Schultz G.S. 2002. *In vitro* effect of EDTA, doxycycline, n acetylcysteine, ilomostat, and a1-proteinase inhibitor on matrix metalloproteinase activity in the tear film of horses with ulcerative keratitis. American College of Veterinary Ophthalmologists (Abstract 24). *Vet. Ophthalmol.* 5:283-301.
- Petroutsos G., Guimaraes R., Giraud J.P., Renard G. & Pouliquen Y. 1982. Effect of acetylcysteine (Mucomyst) on epithelial wound healing. *Ophthalmic Res.* 14(4):241-248.
- Petroutsos G., Guimaraes R., Giraud J. & Pouliquen Y. 1983. Antibiotics and corneal epithelial wound healing. *Arch. Ophthalmol.* 101:1775-1778.
- Saika S., Uenoyama K., Hiroi K. & Ooshima A. 1992. L-ascorbic acid 2-phosphate enhances the production of type I and type III collagen peptides in cultured rabbit keratocytes. *Ophthalmic Res.* 24(2):68-72.
- Slatter D. 2005. *Fundamentos de Oftalmologia Veterinária*. 3ª ed. Roca, São Paulo. 685p.
- Stanley R.G., Hardman C. & Johnson B.W. 1998. Results of grid keratotomy, superficial keratectomy and debridement for the management of persistent corneal erosions in 92 dogs. *Vet. Ophthalmol.* 1:233-238.
- Stojanovic A., Ringvold A. & Nitter T. 2003. Ascorbate prophylaxis for corneal haze after photorefractive keratectomy. *J. Refract. Surg.* 19(3):338-343.