

## Sawfly larval poisoning in cattle: Report on new outbreaks and brief review of the literature<sup>1</sup>

Bianca Tessele<sup>2</sup>, Juliana Sperotto Brum<sup>2</sup>, Ana Lucia Schild<sup>3</sup>, Mauro P. Soares<sup>3</sup>  
and Claudio S.L. Barros<sup>4\*</sup>

**ABSTRACT.**- Tessele B., Brum J.S., Schild A.L., Soares M.P. & Barros C.S.L. 2012. **Sawfly larval poisoning in cattle: Report on new outbreaks and brief review of the literature.** *Pesquisa Veterinária Brasileira* 32(11):1095-1102. Departamento de Patologia, Universidade Federal de Santa Maria, Camobi, Santa Maria, RS 97105-900, Brazil. E-mail: [claudioslbarros@uol.com.br](mailto:claudioslbarros@uol.com.br)

Sawfly larval poisoning (SLP) is an acute hepatotoxicosis documented in livestock in Australia, Denmark and in countries of South America. It is caused by the ingestion of the larval stage of insects of the suborder Symphyta, order Hymenoptera, commonly known as "sawfly". Three species of sawfly are reportedly involved in the toxicosis. The insect involved in Australian SLP is *Lophyrotoma interrupta* (Pergidae), in Denmark the cause of SLP is the ingestion of the larvae *Arge pullata* (Argidae), and in South American countries documented outbreaks of SLP were caused by the ingestion of yet another sawfly, *Perreyia flavipes* (Pergidae). In all geographical areas where it occurred, SLP causes important livestock losses. In cattle, as well as in other affected species, the disease has a short clinical course and in many outbreaks affected cattle can be found dead. When observed, clinical signs include apathy, recumbence, tremors, paddling movements and death in 24-48 hours. Neurological signs such aggressiveness attributable to hepatic encephalopathy are also observed. In cases with a more protracted course icterus and photodermatitis may develop. Gross findings included ascites, petechiae and ecchymosis over serosal surfaces of thoracic and abdominal cavities, and an enlarged liver that displays accentuation of the lobular pattern and edema of the gall bladder wall. Sawfly larval body fragments and heads are consistently found in the fore stomachs and occasionally abomasum of affected cattle. Main microscopic lesions are restricted to the liver and consist of centrolobular (periacinar) to massive hepatocellular necrosis. In most lobules necrotic areas extended up to the portal triads where only a few viable hepatocytes remain. Mild to moderate lymphocyte necrosis is seen in lymphatic tissues. Cases occur in the winter months when the larval stages of the sawfly are developing. D-amino acid-containing peptides have been found to be the toxic principle in each sawfly involved in SLP. The octapeptide lophyrotomin is the major toxin in the larvae of Australian and Danish sawflies and is present in small amounts in the larvae of South American sawfly. The heptadecapeptide pergidin is the main toxin in the South American sawfly while small amounts of pergidin have been found in the other two species of toxic sawfly. During the winter of 2011 (July-August) four outbreaks of SLP were diagnosed in the State of Rio Grande do Sul, Brazil. The findings in those outbreaks are reported here and a brief review of the literature regarding SLP around the world is provided.

INDEX TERMS: Sawfly larval poisoning, hepatotoxicosis, *Perreyia flavipes*, *Lophyrotoma interrupta*, *Arge pullata*, cattle diseases, liver diseases.

<sup>1</sup> Received on July 11, 2012.

Accepted for publication on August 2, 2012.

<sup>2</sup> Post-Graduate Program in Veterinary Medicine, Major in Veterinary Pathology, Centro de Ciências Rurais (CCR), Universidade Federal de Santa Maria (UFSM), Avenida Roraima 1000, Cidade Universitária, Camobi, Santa Maria, RS 97105-900, Brazil.

<sup>3</sup> Laboratório Regional de Diagnóstico, Faculdade de Veterinária, Universidade Federal de Pelotas, Campus Universitário s/n, Pelotas, RS 96010-900, Brazil.

<sup>4</sup> Laboratório de Patologia Veterinária, Departamento de Patologia, Centro de Ciências da Saúde, UFSM, Santa Maria, RS. Pesquisador 1A do CNPq. \*Corresponding author: [claudioslbarros@uol.com.br](mailto:claudioslbarros@uol.com.br)

**RESUMO.- [Intoxicação por larvas de mosca serra: relato de novos surtos e breve revisão da literatura.]** A intoxicação por larvas de mosca serra (ILMS) é uma hepatotoxicose aguda documentada em animais de fazenda na Austrália, Dinamarca e em países da América do Sul. É causada pela ingestão de larvas de insetos da subordem Symphyta, ordem Hymenoptera, conhecidos popularmente como mosca serra. Três espécies de moscas serra são relatadas como envolvidas na intoxicação. O inseto envolvido na ILMS australiana é *Lophyrotoma interrupta* (Pergidae); na Dinamarca a causa da ILMS é a ingestão de larvas de *Arge pullata* (Argidae) e nos países de América do Sul a ingestão de larvas de ainda outra espécie de mosca serra, *Perreyia flavipes* (Pergidae), é a causa de ILMS. Em todas essas áreas geográficas, a ILMS causa importantes perdas na pecuária. Em bovinos, como nas outras espécies afetadas, a doença tem um curso clínico breve e em muitos surtos os bovinos afetados podem ser encontrados mortos. Quando observados, os sinais clínicos incluem apatia, decúbito, tremores, movimentos de pedalagem e morte em 24-48 horas. Sinais neurológicos como agressividade, atribuídos à encefalopatia hepática, são também observados. Em casos com curso clínico mais protraído, pode ocorrer icterícia e fotodermatite. Achados de necropsia incluem ascite, petéquias e equimoses em superfícies serosas das cavidades torácica e abdominal e um fígado aumentado de volume e com acentuação do padrão lobular, e edema da parede da vesícula biliar. Em todas as necropsias de bovinos afetados, fragmentos do corpo e cabeças de larvas são encontrados nos pré-estômagos e, ocasionalmente, no abomaso. As principais lesões microscópicas são restritas ao fígado e consistem de necrose hepatocelular centrolobular (periacinar) a massiva. Na maioria dos lóbulos as áreas de necrose estendem-se até as triades portais onde apenas algumas lâminas de hepatócitos viáveis permanecem. Leve a moderada necrose de linfócitos é observada nos tecidos linfáticos. Os surtos de ILMS ocorrem nos meses de inverno quando os estágios larvais estão em desenvolvimento. Peptídeos que contêm D-aminoácidos constituem os princípios tóxicos de cada uma das moscas serra envolvidas na ILMS. O octapeptídeo lofirotomina é a principal toxina nas larvas das moscas serra australianas e dinamarquesas e também ocorre em pequenas quantidades nas larvas da mosca serra sul-americana. O heptadecapeptídeo pergidina é a principal toxina das larvas da mosca serra sul-americana, enquanto que pequenas quantidades de pergidina foram encontradas nas outras duas espécies tóxicas de mosca serra. Durante o inverno de 2011 (Julho-Agosto) quatro surtos de ILMS foram diagnosticados no Estado do Rio Grande do Sul, Brasil. Os achados desses surtos são relatados aqui e é feita uma breve revisão da literatura sobre ILMS ao redor do mundo.

**TERMOS DE INDEXAÇÃO:** Intoxicação por larvas de mosca serra, hepatotoxicose, *Perreyia flavipes*, *Lophyrotoma interrupta*, *Arge pullata*, doenças de bovinos, doenças hepáticas.

## INTRODUCTION

Sawfly larval poisoning (SLP) is the commonly used appellation to describe a form of livestock poisoning cau-

sed by ingestion of the toxin containing larval stages of some species of insects of suborder Symphyta, order Hymenoptera. These insects are commonly known as "sawfly" because the female specimens bear a saw-toothed appendage on the abdomen with which they cut clefts in the leaves of trees for oviposition (Oelrichs 1982, McKenzie et al. 1985b). SLP has been described in cattle (Callow 1955, Oelrichs 1982, McKenzie et al. 1985a,b, Dutra et al. 1997, Soares et al. 2008, Raymundo et al. 2009), sheep (Thamsborg et al. 1987, Dutra et al. 1997, Raymundo et al. 2008) and pigs (Jonck et al. 2010) and in a dog (Brummerstedt et al. 1987). Species of sawfly are reportedly associated with livestock poisoning in Australia, Denmark and South America. In South America the disease was reported from Uruguay and Brazil (Dutra 1997, Soares 1997, Raymundo 2008).

In Southern Brazil, although not generally recognized, SLP is an important cause of death in cattle in winter months. Most practicing veterinarians in our region find difficult believing that cattle could get poisoned by just eating fly larvae. Recently four outbreaks of SLP caused by the ingestion of the sawfly *Perreyia flavipes* were diagnosed in cattle from Rio Grande do Sul, Brazil, by two veterinary diagnostic laboratories operating in this State. The purpose of this paper is to aggregate data collect from these newly recognized outbreaks into literature while elaborating a brief review of the information available on SLP in the world literature in order to supply practicing veterinarians with pertinent resource on this subject.

## LITERATURE REVIEW

Sawfly larval poisoning (SLP) is an acute hepatotoxicity of cattle caused by the ingestion of larval stage of insects of the suborder Symphyta, order Hymenoptera, commonly known as "sawfly". SLP has been described in cattle (Tryon 1921, Roberts 1932, Callow 1955, Dutra et al. 1997, McKenzie et al. 1985a,b, Soares et al. 2008, Raymundo et al. 2009), sheep (Dutra et al. 1997, Raymundo et al. 2008, Thamsborg et al. 1987), and pigs (Jonck et al. 2010) and there is one isolated report o SLP in a dog (Brummerstedt et al. 1987). It is a remarkable disease since the toxin is present in the larvae of the insects.

In Australia SLP is caused by the ingestion of the larvae of the sawfly *Lophyrotoma interrupta* (Pergidae, Hymenoptera), formerly referred also as *Pterigophorus analis*, *Pterigophorus interruptaa* and *Platysectra interrupta* (Roberts 1932, McKenzie et al. 1985a,b). The poisoning of cattle eating *L. interrupta* (commonly referred to as the Australian sawfly larva) has been studied for over 70 years, since it was first described in the Maranoa district of southern Queensland in 1911 (Tryon 1921, Roberts 1932, Callow 1955, McKenzie et al. 1985a,b) where it is reportedly responsible for annual losses amounting to 1 million Australian dollars in 1981 values (McKenzie et al. 1985b). During 1972-1981 in Australia, 37 farms experienced 5,254 deaths during July to September and 1,800 deaths in cattle occurring in just one year were attributed to the intoxication (Dadswell et al. 1985). Cattle were introduced

in this area between 1862 and 1866 and the first suspected cases appeared in 1887 but the definite occurrence was only established in 1911 (Tryon 1921). Outbreaks in Australia are confined to districts where there are large forests of the silver leaf ironbark tree (*Eucalyptus melanophloia*), the main host for *L. interrupta* (Callow 1955, Oelrichs et al. 1977, Oelrichs 1982, McKenzie et al. 1985a,b); most deaths occur between July and October (Dadswell et al. 1985) although some may occur after the dried-out remains of dead larvae are moistened by rain during summer (Dadswell et al. 1985).

In Denmark SLP was reported in sheep caused by the ingestion of the larvae of the sawfly *Arge pullata* (Argidae), commonly referred as Danish sawfly larva, which feed on the leaves of birch trees (*Betula pendula*). This outbreak of SLP have been reported from the Danish Island of Sjælland where 50 sheep from a flock of 250 died 3 days after they were moved to the area infested by *A. pullata* larvae (Thamsborg et al. 1987). At this occasion the disease was reproduced experimentally in goats that were orally fed larvae from this outbreak (Thamsborg et al. 1987).

The sawfly *Perreyia flavipes* Konow, 1899 (Pergidae: Perreyiinae) also referred as *Lophyroides flavipes* and *Brachytoma flavipes* have been reported from Uruguay and Brazil as affecting cattle (Dutra et al. 1997, Soares et al. 2008, Raymundo et al. 2009), sheep (Dutra et al. 1997, Raymundo et al. 2008), and pigs (Jonck et al. 2010). The disease was reproduced in cattle, sheep (Dutra et al. 1997) and pigs (Soares 1997, Soares et al. 2001) and rabbits (Raymundo 2008). *P. flavipes* is commonly referred to as South American sawfly larva. Reports on SLP, possibly *P. flavipes*, in pigs from southern Brazil are known at least since the 1940's (Costa Lima 1941, Camargo 1956). Although the causal-effect between these larvae and the disease was not experimentally established at that time, the anecdotal reports of SLP in pigs are so common in southern Brazil that in this region of the country the larvae acquired the popular sobriquet of "mata-porco" (Portuguese for "pig killer") and the notion that mata-porco represents a deadly poison for livestock is entrenched even in the folk songs of the region (Medeiros 2011) The reproduction of the disease by *P. lepida* was achieved in pigs (Soares et al. 1997), but it was later found that the larvae classified as *P. lepida* in that experiment was probably *P. flavipes* (Dutra 1997, Dutra et al. 1997, Soares et al. 2001)

The economical importance of sawfly (*P. flavipes*) larval poisoning in South America can be evaluated if one considers that within a three-year period (1993-1995) at least 40 outbreaks of this intoxication occurred in Uruguay and that during just one year (1995) cattle losses exceeded 1,000 heads (Dutra et al. 1997). Mortality rates vary and are reported as 1.6%, 7.0% and 1.38% from one study (Dutra et al. 1997) and 0.8%, 6.2% and 33% from another (Soares et al. 2008)

D-amino acid-containing peptides have been found to the toxic principle in each sawfly involved in farm animal poisonings (Kannan et al. 1988, Oelrichs et al. 1999, 2001). The octapeptide lophyrotomin is the major toxin in the larvae of Australian and Danish sawflies and is present

in small amounts in the larvae of South American sawfly. The heptadecapeptide pergidin is the main toxin in the South American sawfly while small amounts of pergidin have been found in the other two species of toxic sawfly (Oelrichs et al. 1999). Val<sup>4</sup>- co-occurs varying quantities within pergidin in these extracts (Oelrichs et al. 1999).

One interesting environmental phenomenon related to sawfly occurred in Florida. The broad-leave paper bark tree (*Melaneuca quinquenervia*) was introduced from Australia into Florida, USA, early in 1900's, and has since then proliferated to such an extent as to be found in all 10 counties of Southern Florida in an area over 200,000 ha where it causes considerable environmental and economic damage. Therefore the sawfly *Lophyrotoma zonalis* was introduced, again from Australia, as a possible biological control agent for the tree due to its ability to defoliate *M. quinquenervia*. However this may turn out to be a dangerous practice since, although no cases of spontaneous poisonings in animals attributable to the ingestion of *L. zonalis* larvae have been detected either from Florida or Australia, the toxins lophyrotomin and a mixture of pergidin and val<sup>4</sup>- pergidin were demonstrated in *L. zonalis* larvae (Oelrichs et al. 1999), making the larvae a possible threat to livestock. Furthermore, the toxic substances in *L. zonalis* larvae proved toxic to mice (Oelrichs et al. 2001).

The biological cycle of *P. flavipes* was studied in laboratory (Soares et al. 2001). It was determined that it develops along the whole year. Larvae appear in pasture from march on, when they are bright black and small 1 mm in length thus being not promptly observed. From March to August (autumn and winter in the south hemisphere) they measure 17-22 mm in length and are promptly detected. Under normal conditions full growth is reached in the late winter and early spring. They are ingested by cattle during this period. The reason why cattle eat the sawfly larvae is unknown. In the case of *L. interrupta* it has been suggested that this behavior reflects some form of nutritional deficiency (Roberts 1932) however this remains unproven. Alternatively it has been suggested that some property of the sawfly may be involved in causing the animals to seek out and eat the larvae (Oelrichs 1982, Oelrichs et al. 1999). The nature of such attraction has not been determined but it is reported (Oelrichs 1982) that after eating the larval stage of *L. interrupta* cattle develop a considerable liking for it and voraciously consume both the dead and living larvae; actually cattle have been seen to run in mobs from tree to tree in attempt obtain more of the larvae, the ingestion of which in a short time will cause their death (Oelrichs 1982). Larvae of *P. flavipes* feed on decomposing plant material, dry leaves and dried cattle manure. Larvae go through a series of changes until they pupate, when the insect penetrates 3-10cm into the ground and form a bright black, leathery-like, 1x0.5cm ovoid cocoon. Within the cocoon the larvae becomes white and remains in this stage from August to January when they emerge as adult. The adult insects are bright black and have a short life span: Only 18-36 hours for females and 24-48 hours for males, time sufficient to start a new cycle. Females are 8-10 mm and males are 7.5-10 mm in length (Soares et al. 2001).

SLP is an acute condition in all affected species. Most affected cattle have weakness, muscular tremors, apathy, stupor and death within 2-5 days of the onset of clinical signs (Dadswell et al. 1985, Dutra et al. 1997, McKenzie et al. 1985a, Raymundo et al. 2009). Some animals become very agitated and aggressive (Dutra et al. 1997) and those cattle surviving for longer periods may show icterus and hepatogenous photodermatitis (Callow 1955, Dutra et al. 1997). Some less affected cattle may recover (Roberts 1932, Callow 1955, Dutra et al. 1997).

Necropsy findings include accentuation of the lobular pattern of the liver, edema of the gall bladder and serosal hemorrhages. Fragments of larvae (*P. flavipes*) can be found in the rumen and omasum. The main histological lesion consists of centrilobular to massive liver necrosis and necrosis of lymphoid tissue (Dutra et al. 1997, Soares et al. 2008, Raymundo et al. 2009).

## MATERIALS AND METHODS

The outbreaks were observed on site by visits to the farms where poisoning occurred, done by the staff from the Veterinary Pathology Laboratory of the *Universidade Federal de Santa Maria* and from the Regional Laboratory Diagnostic of the *Universidade Federal de Pelotas*, both in the State of Rio Grande do Sul. In the farms information were gathered from the owner or from the practicing veterinarian. Four necropsies were performed on site and routine histopathology was carried out in several organs including liver and lymphatic system. Fresh larvae collected from the pasture where deaths occurred in Outbreak 1 were ground and orally fed to a healthy 18-month-old calf in one single dose of 20 g/kg/body weight.

## RESULTS

### Spontaneous disease

Outbreaks occurred in farms of the State of Rio Grande do Sul, Brazil, in the municipalities of Santana do Livramento (latitude 30°53'27" S, longitude 55°31'58" W) and Piratini (latitude 31°26'53" S longitude 53°06'15" W).

**Outbreak 1** occurred in a farm in Santana do Livramento where there were 200 yearlings calves (approx. 18 month-olds) of both sexes. During winter (July-August) 16 of those yearlings died within one month-period. Most affected cattle died in two different occasions during this one-month period. Affected cattle had weakness, muscular tremors, apathy and death within 1-5 days of the onset of clinical signs. Some animals became very agitated and aggressive and those surviving for longer periods had icterus and occasionally photodermatitis. Very large numbers of 2-2.5m in length, black insect larvae (Fig.1) were found at the pasture. The larvae formed closely packed masses on the ground and were observed crawling over the grass forming an orderly column of 10-15m long. Large numbers of these larvae were collected from this farm and subsequently identified as *Perreyia flavipes* Konow, 1899 (Hymenoptera: Pergidae). One out of the 16 dead calves was necropsied. This calf died within 24 hours after the onset of clinical signs. Gross findings were consistent with an outbreak caused by an hepatotoxin and included ascites, petechiae and suffusion over the serosal surfaces of thoracic

and abdominal cavities; the liver was somewhat enlarged (round edges) and mottled with had a accentuation of the lobular pattern; this was best seen at the cut surface as 1-2mm in diameter bright red depressed irregular areas surrounded by lighter (beige or tan) areas (Fig.2). The red areas would later be identified on histological examination as consisting of centrilobular necrosis. There was edema of the gall bladder wall. Subendocardial and suppicardial petechiae and ecchymosis were also observed. Sawfly (*P. flavipes*) larval body fragments and heads were found in the rumen. The main microscopic lesion was restricted to the liver and consisted of centrilobular to massive hepatocellular necrosis. In most lobules necrotic areas extended up to the portal triads where only a few viable hepatocytes



Fig.1. A group of black *Perreyia flavipes* larvae crawling over the grass.

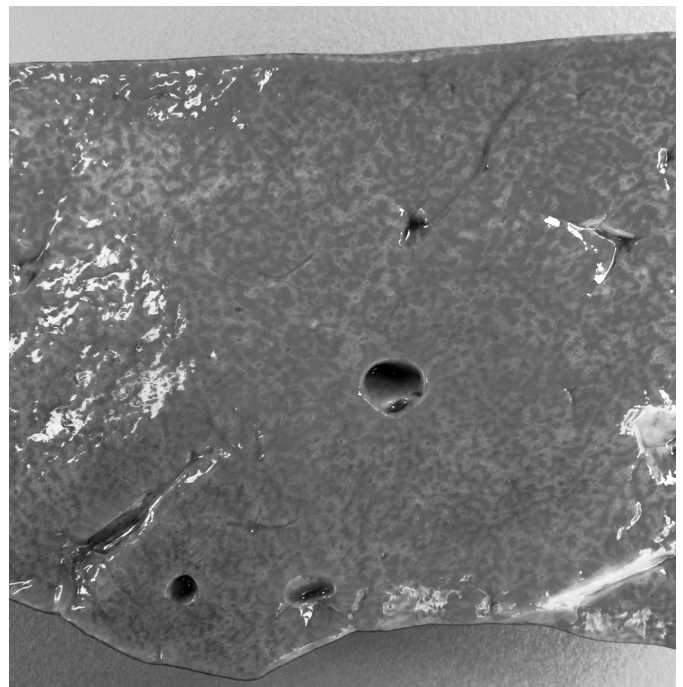


Fig.2. Cross section of the liver from one of the calves poisoned by the ingestion of sawfly *Perreyia flavipes* in Outbreak 1. The cut surface is mottled by bright red depressed irregular areas surrounded by lighter rim.

remained (Fig.3). The lesion appeared diffusely and no preference for any hepatic lobe could be noticed. Hemorrhage occurred in centrolobular areas. Mild to moderate lymphocyte necrosis was seen in the splenic white pulp.

**Outbreak 2** occurred in a farm in Piratini where there were 76 heifers. From 22 to 26 of July five of these heifers died. No clinical signs could be observed. Necropsy findings observed in two necropsied heifers included moderate ascites, accentuation of the lobular pattern of the liver; subendocardial and supericardial petechiae and ecchymosis. Larvae and larval fragments of *P. flavipes* were found in the rumen. Histologically, there was centrolobular (periacinar) to massive necrosis.

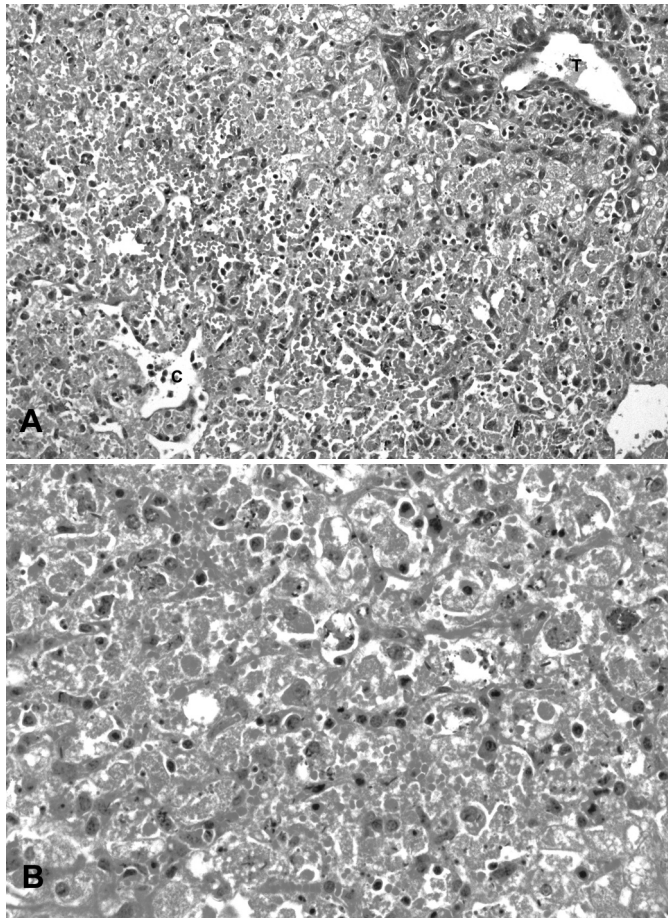


Fig.3. Histology of the hepatic lesions in one of the affected calves in Outbreak 1. (A). There is massive necrosis which extends from the central veins (C) to the portal triads (T). Hemorrhage is marked. HE, obj.20x. (B). Higher magnification of the lesion in A showing several cells in different stages of necrosis HE, obj.40x.

**Outbreak 3.** The owner of a farm in Piratini, reported that during approximately a week in July, 24 zebu cross cattle died. These were part of a small herd of a total 62 zebu cross cattle all of them with about 3 years old. No necropsies were performed in cattle from this outbreak because cattle had died few days before the staff of the diagnostic laboratory was called upon. However the epidemiological characteristics of this outbreak were similar to those of Outbreak 2, with acute deaths and abundant clusters of *P. flavipes* larvae observed in the pasture where cattle have died.

**Outbreak 4** occurred in a farm in Piratini, where there were 65 mixed-breed cattle of varying ages at risk. From the end of July to August the 20<sup>th</sup>, 30 out of these 65 cattle died. Clinical signs in the affected cattle included photodermatitis, aggressiveness, paddling movements with the limbs and in most cases death 24 hours after the onset of clinical signs. The necropsy was performed by a practicing veterinarian who submitted liver and brain for histopathological examination. Histologically, there was centrolobular (periacinar) to massive necrosis of the liver and spongy degeneration of the subcortical telencephalic white matter of. The owner reported to have eliminated 30 colonies of sawfly larvae, after which the deaths ceased. Epidemiological data in these four outbreaks are summarized in Table 1.

#### Experimental disease

The calf which received 20g/kg/body weight of fresh ground larvae *P. flavipes* developed clinical signs within 3 days of the administration of the larvae and died after a short period (approx. 24 hours) of the onset of clinical disease. Clinical signs presented by this calf were similar to those observed in the natural outbreaks. Additionally mild icterus was also observed. The seric activity of liver enzymes was increased as measured before administration of the larvae and just prior the death of the experimental calf. Results of the two evaluated samples are within parenthesis (first value is from the pre-experimental sample and the second value is from the blood sampled just prior the death of the calf): Aspartate aminotransferase (73-804 U/L); gamma-glutamyl transferase (10-89 U/L); and alkaline phosphatase (54-404 U/L). The levels of total bilirubin were also elevated (3.46mg/dL) and direct bilirubin elevation (2.98mg/dL) accounted for this increase. Necropsy and histopathological findings on this experimental calf were similar to the ones observed in the spontaneous outbreak.

#### DISCUSSION

The diagnosis in our cases was based primarily in the clinical signs and pathological findings and in some epi-

**Table 1. Data on four outbreaks of sawfly larval (*Perreyia flavipes*) poisoning in cattle in the State of Rio Grande do Sul in 2011.**

Outbreak #	Local	Time of the year	Duration of outbreak	Cattle at risk	Number of affected cattle	Morbidity (%)	Mortality (%)
1	Santana do Livramento	July-August	1 month	200	16	0.80	100
2	Piratini	July	4 days	76	4	5,26	100
3	Piratini	July	1 week	62	24	38,70	100
4	Piratini	July-August	ND*	65	30	46,15	100

\*ND = not determined.

miological aspects. These aspects of the outbreak reported here are remarkably similar to SLP reported in cattle from Australia caused by *Lophyrotoma interrupta* (Roberts 1932, Callow 1955, McKenzie et al. 1985a,b), in sheep from Denmark caused by *Arge Pullata* (Thamsborg et al. 1987), and in cattle and sheep from Uruguay (Dutra et al. 1997) and cattle (Soares et al. 2008, Raymundo et al. 2009), sheep (Raymundo et al. 2008) and pigs (Jonck et al. 2010) from Brazil caused by *Perreyia flavipes*. Further evidences are the finding of fragments of sawfly larvae in the fore stomachs of necropsied calves and the reproduction of the disease by feeding ground *P. flavipes* larvae collected from the site where the spontaneous outbreak occurred and feeding them to a susceptible calf.

The acute centrolobular necrosis as seen associated to SLP is not specific of this condition and occur in association with several other hepatotoxins, mainly phytotoxins, in farm animals (Rissi et al. 2007). Hepatocytes in the center of the lobule (zone 3) are more vulnerable to a toxic insult as compared with peripheral (zone 1) located hepatocytes because centrolobular hepatocytes have more abundant enzymes which act transforming liposoluble compounds in toxic substances and because centrolobular hepatocytes have lower levels of oxygen and glutathion peroxidase. Hepatocytes in the periphery of the lobule (zone 1) are more vulnerable to toxins of direct action, due to the proximity of these periportal hepatocytes to the blood flow that arrives by the portal vein and hepatic artery branches at the portal triads (Stalker & Hayes 2007). When the toxic principles of sawfly were administered to mice, those treated with lophyrotomin developed periportal (zone 1) necrosis while mice treated with pergidin developed centrolobular (zone 3) necrosis (Oelrichs et al. 2001). This may of course influence the hepatic zonal necrosis distribution in SLP caused by different species of sawfly. Regarding the zonal distribution of hepatic necrosis it is interestingly to note that experimentally, a reduction in the sawfly-induced liver pathology was associated to the concurrent *Fasciola hepatica* infection was observed in lambs. A possible explanation for this phenomenon is an inhibitory action of *F. hepatica* on the microsomal oxidative enzymes responsible by the biotransformation of the active principles within the larvae in toxic metabolites (Olaechea et al. 1991).

Reportedly in cattle affected by SLP necrosis of hepatocytes was most severe in the right lobe (Dutra et al. 1997); the right lobe was described grossly as being swollen and deep reddish purple with a cut surface with prominent, bulging islands of pale tissue and the left lobe being pale and the cut surface finely mottled red and yellow giving a nutmeg appearance. Histologically necrosis of hepatocytes was much more severe in the right lobe (Dutra et al. 1997). A similar difference in distribution of lesions is also reported in the intoxications by *Vernonia mollissima* and *V. rubricaulis* in cattle (Tokarnia et al. 2012) in which the border of the left hepatic lobe of affected cattle is grossly and homogeneously yellow (no marked lobular pattern). However, microscopically there is centrolobular necrosis of these homogenous yellow areas but congestion and hemorrhage are lacking. This may be due to uneven distribution of

blood through the hepatic lobes and consequently uneven distribution of the toxic principle.

The neurologic clinical signs presented by cattle of this report affected by SLP are typical of hepatic encephalopathy. Cattle poisoned by the larvae *Lophyrotoma interrupta* (McKenzie et al. 1985a) and sheep fed *Arge pullata* (Thamsborg et al. 1987) also show signs of hepatic encephalopathy, and the fatally poisoned calves presented increased plasma ammonia sufficient to account for the clinical signs (McKenzie et al. 1985a). Hepatic encephalopathy is common in ruminants and horses with hepatic failure (Cullen 2007). Undetermined as yet are the specific metabolites that cause the neurologic dysfunction in hepatic encephalopathy, but increased concentrations of plasma ammonia derived from amines absorbed from the gastrointestinal tract may be responsible (Cullen 2007). Normally, amines are absorbed from the intestines into the portal blood and metabolized by the liver. The toxic products may not be fully eliminated by the severely damaged liver. However, abnormal ammonia concentrations are not the only possible cause of hepatic encephalopathy. An imbalance between inhibitory and excitatory amino acid neurotransmitters,  $\gamma$ -aminobutyric acid, and L-glutamate, respectively, and increased brain concentrations of endogenous benzodiazepines are other possible explanations (Cullen 2007). Alternatively a low blood sugar can account for the neurological signs and a fall in glucose was noticed in and the fatally poisoned calves by *L. interrupta* (McKenzie et al. 1985a,b).

Widespread hemorrhages are prominent in some field cases of SLP, but they were not invariably present and their severity varied. Lengthened thrombin, activated thromboplastin times and reduced fibrinogen concentration have been reported in calves experimentally poisoned with the larvae of *L. interrupta* (McKenzie et al. 1985a). Hemorrhagic diathesis occurs terminally in animals with severe liver necrosis (Cullen 2007). In these cases bleeding tendencies associated to hepatic failure may be due to impaired synthesis of clotting factors, reduced clearance of the products of the clotting process, and metabolic abnormalities affecting platelet function that affect normal clotting, individually or in combination. In acute liver failure as is the case of liver failure in SLP) diminished synthesis of clotting factors with a short half-life, such as factors V, VII, IX, and X, impairs the ability of blood to coagulate. Diminished clearance of fibrin degradation products activated coagulation factors, and plasminogen factors by the damaged liver also perturbs clotting. Metabolic disturbances resulting from liver failure can affect platelet function and lead to synthesis of abnormal fibrinogen, a condition termed dysfibrinogenemia (Cullen 2007).

Due to the short course of the disease, jaundice and photosensitization are not common findings, although both are seen in some more protracted field cases. An increased concentration of serum bilirubin has been seen in experimental sawfly larval poisoning of cattle and sheep (McKenzie et al. 1985a, Thamsborg et al. 1987).

Tubular and degeneration of the renal epithelium tubular as described in cattle (Callow 1955, Soares et al. 2008), sheep (Raymundo et al. 2008), and pigs (Soares et

al. 2001) were not observed in our cases. In calves experimentally poisoned by the sawfly *L. interrupta* (McKenzie et al. 1985a) there was also little effect on the kidney function.

In the differential diagnosis other toxins and diseases of the central nervous system in cattle should be considered. SLP causes clinical disease and lesions in cattle that closely resemble those evoked by the ingestion of poisonous plants causing acute toxic liver disease (Barros et al. 2011, Tokarnia et al. 2012). *Microcystis aeruginosa*, the blue-green algae growing as a bloom on lakes and ponds,

produces microcystin, a well-documented cause of similar lesions in cattle. This type of poisoning is still unreported in cattle in Brazil. The geographic distribution of the poisonous plants should help determine which plant is involved. Table 2 summarizes the important hepatotoxicoses in farm animals in Brazil.

Primary diseases of the CNS (rabies, necrotizing meningoencephalitis by bovine herpesvirus 5 and cerebral babesiosis by *Babesia bovis*) and secondary diseases of the CNS (hepatic encephalopathy) should also be included in the list of differential diagnoses (Rissi et al. 2007). The

**Table 2. Acute hepatotoxicoses in farm animals in Brazil\***

Hepatotoxin	Affected species	Toxic principle	Main lesion	Comments
<b>Plants</b>				
<i>Xanthium</i> spp.	Cattle, sheep, pigs	Carboxyatractyloside	Periacinar to massive necrosis	Poisoning in swine is associated with hypoglycemia and ascites
<i>Cestrum parqui</i>	Cattle	Carboxyatractyloside	Periacinar necrosis	
<i>Cestrum corymbosum</i> var. <i>hirsutum</i>	Cattle	Not determined	Periacinar necrosis	Serosal hemorrhages, edema of the gall bladder wall. In natural conditions only causes acute poisoning.
<i>Cestrum intermedium</i>	Cattle	Not determined	Periacinar necrosis	Serosal hemorrhages, edema of the gall bladder wall. In natural conditions only causes acute poisoning.
<i>Sesaea brasiliensis</i>	Cattle	Not determined	Periacinar necrosis	Serosal hemorrhages, edema of the gall bladder wall. In natural conditions only causes acute. Experimentally small repeatedly administered doses can cause hepatic cirrhosis.
<i>Dodonea viscosa</i>	Cattle	Not determined	Periacinar necrosis	Serosal hemorrhages, edema of the gall bladder wall. In natural conditions only causes acute poisoning.
<i>Myoporum laetum</i>	Sheep	Furanosquiterpenoids (ngaione)	Usually periacinar necrosis but variable zonal necrosis can occur.	Other species can be affected but the in Brazil was only recognized in sheep.
<i>Cestrum intermedium</i>	Cattle	Not determined	Periacinar necrosis	Serosal hemorrhages, edema of the gall bladder wall. In natural conditions only causes acute poisoning.
<i>Cestrum laevigatum</i>	Cattle	Saponins, cestrumide	Periacinar necrosis	Serosal hemorrhages, edema of the gall bladder wall. In natural conditions only causes acute poisoning. Experimentally small repeatedly administered doses can cause hepatic cirrhosis
<i>Dodonea viscosa</i>	Cattle	Not determined	Periacinar necrosis	Serosal hemorrhages, edema of the gall bladder wall. In natural conditions only causes acute poisoning.
<i>Trema micrantha</i>	Goats and sheep	Not determined	Periacinar necrosis	Serosal hemorrhages, edema of the gall bladder wall. In natural conditions only causes acute poisoning. Yellow discoloration of the left hepatic lobe
<i>Vernonia molissima</i>	Cattle and sheep	Not determined	Periacinar necrosis	There is also degeneration of renal tubular epithelium. Yellow discoloration of the left hepatic lobe
<i>Vernonia rubricaulis</i>	Cattle	Not determined	Necrose centrolobular	Outbreaks occur in the dry season
<b>Bacteria</b>				
<i>Microcystis aeruginosa</i>	Cattle, sheep, horses, goats	Microcystins and others	Periacinar to massive necrosis	Multiple toxins present. Can also cause death by neuromuscular disturbances. This poisoning was not documented in farm animals in Brazil but there are evidences that it occurs
<b>Insect larvae</b>				
<i>Perreyia flavipeds</i> (sawfly)	Cattle, sheep and pigs	Pergidin and lophytomin	Periacinar to massive necrosis	Serosal hemorrhages, edema of the gall bladder wall.
<b>Mycotoxins</b>				
Aflatoxin	Pigs, cattle	Bisfuranocoumarin compounds	Centrolobular necrosis (lipidosis)	Hemorrhages. Other species can be affected but the listed two are so more often in the country. Cattle are affected as young and develop a chronic form with fibrosis, megalocytosis and bile duct hyperplasia

\*Source: Barros et al. 2011.

al. 2001) were not observed in our cases. In calves experimentally poisoned by the sawfly *L. interrupta* (McKenzie et al. 1985a) there was also little effect on the kidney function.

In the differential diagnosis other toxins and diseases of the central nervous system in cattle should be considered. SLP causes clinical disease and lesions in cattle that closely resemble those evoked by the ingestion of poisonous plants causing acute toxic liver disease (Barros et al. 2011, Tokarnia et al. 2012). *Microcystis aeruginosa*, the blue-green algae growing as a bloom on lakes and ponds, produces microcystin, a well-documented cause of similar lesions in cattle. This type of poisoning is still unreported in cattle in Brazil. The geographic distribution of the poisonous plants should help determine which plant is involved. Table 2 summarizes the important hepatotoxicoses in farm animals in Brazil.

Primary diseases of the CNS (rabies, necrotizing meningoencephalitis by bovine herpesvirus 5 and cerebral babesiosis by *Babesia bovis*) and secondary diseases of the CNS (hepatic encephalopathy) should also be included in the list of differential diagnoses (Rissi et al. 2007). The centrolobular congestion of the liver (congestive heart failure) imparts a gross nutmeg aspect to the liver. Nutmeg liver is morphologically similar to, although pathogenetically quite distinct from, the marked lobular pattern induced by acute hepatotoxins and should be differentiated from it.

## REFERENCES

- Barros C.S.L. 2011. Fígado, vias biliares e pâncreas exócrino, p.183-290. In: Santos R.L. & Alessi A.C. (Eds), Patologia Veterinária. Roca, São Paulo.
- Brummerstedt E., Kristensen E., Nielsen A. & Bille-Hansen A. 1987. Death of a puppy after eating sawfly larvae: Case report. Dansk- Veterinaertids. 70:758-760.
- Callow L.L. 1955. Sawfly poisoning in cattle. Qld J. Agric. Sci. 81:155-161.
- Camargo O.R. 1956. As larvas "mata-porco" no Rio Grande do Sul. Bolm Diretoria Prod. Anim. 1:18-25.
- Costa Lima A. 1941. Bichos "mata porcos". Chácaras e Quintais 63:43.
- Cullen J.M. 2007. Liver, biliary system, and exocrine pancreas: Hepatic failure, p.414. In: McGavin M.D. & Zachary J.F. (Eds) Pathologic Basis of Veterinary Disease. 5<sup>th</sup> ed. Mosby Elsevier, St Louis.
- Dadswell L.P., Abbott W.D. & McKenzie R.A. 1985. The occurrence, cost and control of sawfly larval (*Lophyrotoma interrupta*) poisoning of cattle in Queensland 1972/81. Aust. Vet. J. 62:94-97.
- Dutra F. 1997. Intoxicação por larvas de *Perreyia flavipes* em bovinos e ovinos: caracterização da doença e biologia do inseto. Tese de Mestrado, Faculdade de Veterinária, Universidade Federal de Pelotas, Rio Grande do Sul, 38p.
- Dutra F., Riet-Correa F., Mendez M.C. & Paiva N. 1997. Poisoning of cattle and sheep in Uruguay by sawfly (*Perreyia flavipes*) larvae. Vet. Human Toxicol. 39:281-286.
- Jonck F., Casagrande R.A., Froehlich D.L., Ribeiro Jr D.P. & Gava A. 2010. Intoxicação espontânea por larvas de *Perreyia flavipes* (Pergidae) em suínos no Estado de Santa Catarina. Pesq. Vet. Bras. 30:1017-1020.
- Kannan R., Oelrichs P.B., Thamsborg S.T. & Williams D.H. 1988. Identification of the octapeptide lophyrotomin in the European birch sawfly (*Arge pullata*). Toxicon 26:224-226.
- McKenzie R.A., Dunster P.J., Twist J.O., Dimmock C.K., Oelrichs P.B., Rogers R.J. & Reichmann C.K. 1985a. The toxicity of sawfly larvae (*Lophyrotoma interrupta*) to cattle. Qld. Dept. Prim. Ind. Bull. QB85001, p.1-45.
- McKenzie R.A., Rogers R.J. & Oelrichs P.B. 1985b. Sawfly larvae poisoning of cattle in Queensland, p.524-532. In: Seawright A.A., Hegarty M.P., James L.F. & Keeler R.F. (Eds), Proceedings of the Australia-USA Poisonous Plants Symposium, Queensland Poisonous Plant Committee, Brisbane, Australia.
- Medeiros E. 2011. Bicho da chuva. <<http://www.youtube.com/watch?v=Ty2QN6AI2U0>>  
<<http://www.youtube.com/watch?v=Ty2QN6AI2U0>> Acessado em 10 jul. 2012.
- Oelrichs P.B., MacLeod J.K., Seawright A.A., Moore M.R., Ng J.C., Dutra F., Riet-Correa F., Méndez M.C. & Thamsborg S.M. 1999. Unique toxic peptides isolated from sawfly larvae in three continents. Toxicon 37:537-544.
- Oelrichs P.B., McLeod J.K., Seawright A.A. & Grace P.B. 2001. Isolation and identification of toxic peptides from *Lophyrotoma zonalis* (Pergidae) sawfly larvae. Toxicon 39:1933-1936.
- Oelrichs P.B., Valley J.V., McLeod J.K., Cable J., Kiely D. & Summers R.E. 1977. Lophyrotomin, a new toxic octapeptide from the larvae of the sawfly, *Lophyrotoma interrupta*. Lloydia 40:209-214.
- Oelrichs P.B. 1982. Sawfly poisoning in cattle. Qld Agric. J. 108:110-112.
- Olaechea F.V., Thamsborg S.M., Christensen N.Ø., Nansen P. & Robles A. 1991. Interference with sawfly (*Arge pullata*) poisoning in *Fasciola hepatica*-infected lambs. J. Comp. Pathol. 104:419-431.
- Raymundo D.L. 2008. Intoxicação espontânea por larvas de *Perreyia flavipes* (Pergidae) em ovinos e bovinos e intoxicação experimental em ovinos e coelhos. Dissertação de Mestrado, Programa de Pós-Graduação em Ciências Veterinárias, Faculdade de Veterinária, Universidade Federal do Rio Grande do Sul, Porto Alegre. 68p.
- Raymundo D.L., Bezerra Jr P.S., Bandarra P.M., Santos A.S., Sonne L., Pavarini S.P., Correa A.M.R., Dias M.M. & Driemeier D. 2009. Intoxicação espontânea pelas larvas de *Perreyia flavipes* em bovinos no Estado de Santa Catarina, Brasil. Ciência Rural 39:163-166.
- Raymundo D.L., Bezerra Junior P.S., Bandarra P.M., Pedroso P.M.O., Oliveira E.C., Pescador C.A. & Driemeier D. 2008. Spontaneous poisoning by larvae of *Perreyia flavipes* (Pergidae) in sheep. Pesq. Vet. Bras. 28:169-173.
- Rissi D.R., Driemeier D., Silva M.C., Barros R.R. & Barros C.S.L. 2007. Poisonous plants producing acute hepatic disease in Brazilian cattle, p.72-76. In: Panter K.E., Wierenga T.L. & Pfister J.A. (Eds), Poisonous Plants: Global research and solutions. CAB International, Wallingford, UK.
- Roberts F.H.S. 1932. The cattle-poisoning sawfly (*Pterygophorus analis* Costa). Qld Agric. J. 37:41-52.
- Soares M.P. 1997. Intoxicação por larvas de *Perreyia lepida* em suínos. Tese de Mestrado, Faculdade de Veterinária, Universidade Federal de Pelotas. Pelotas, RS. 32p.
- Soares M.P., Quevedo O.S. & Schild A.L. 2008. Intoxicação por larvas de *Perreyia flavipes* em bovinos na Região Sul do Rio Grande do Sul. Pesq. Vet. Bras. 28:169-173.
- Soares M.P., Riet-Correa F., Smith D.R., Pereira Soares M., Mendez M.C. & Brandolt A.L. 2001. Experimental intoxication by larvae of *Perreyia flavipes* Konow, 1899 (Hymenoptera: Pergidae) in pigs and some aspects on its biology. Toxicon 39:669-678.
- Stalker M.J. & Hayes M.A. 2007. Liver and biliary system: Toxic hepatic disease, p.372-378. In: Maxie M.G. (Ed.), Jubb, Kennedy, and Palmer's Pathology of Domestic Animals. Vol.2. 5<sup>th</sup> ed. Saunders Elsevier, Philadelphia.
- Thamsborg S.M., Jørgensen R.J. & Brummerstedt E. 1987. Sawfly poisoning in sheep and goats. Vet. Rec. 121:253-255.
- Tokarnia C.H., Brito M.F., Barbosa J.D., Peixoto P.V. & Döbereiner J. 2012. Pantas/micotoxinas que afetam o fígado, p.147-204. In: Ibid. (Eds), Plantas Tóxicas do Brasil para Animais de Produção. 2<sup>a</sup> ed. Editora Helianthus, Rio de Janeiro.
- Tryon H. 1921. Special cattle fatality in the Maranoa District and its reflection to the larvae of *Pterygophorus analis* Costa. Qld Agric. J. 16:208-216.