

Laminar lesions in horses with systemic oxidative stress, committed by experimentally induced or naturally occurring gastrointestinal disorders¹

Luciane M. Laskoski^{2*}, Rosangela Locatelli-Dittrich², Renato S. Sousa³, Juliana S. Brum², Thierry G. Cristo⁴, Fabiano Montiani-Ferreira², Olair C. Beltrame³ and Carlos A.A. Valadão⁵

ABSTRACT- Laskoski L.M., Locatelli Dittrich R., Sousa R.S., Brum J.S., Cristo T.G., Montiani-Ferreira F., Beltrame O.C. & Valadão C.A.A. 2016. **Laminar lesions in horses with systemic oxidative stress, committed by experimentally induced or naturally occurring gastrointestinal disorders.** *Pesquisa Veterinária Brasileira* 36(8):694-700. Pós-Graduação em Ciências Veterinárias, Universidade Federal do Paraná, Campus de Curitiba, Rua dos Funcionários 1540, Curitiba, PR 80035-050, Brazil. E-mail: luci.laskoski@gmail.com

Laminitis in horses can be associated with lesions in multiple organs secondary to sepsis. Twenty-one horses suffering from gastrointestinal disorders were used in the experiment; 7 horses with experimentally induced endotoxemia and intestinal ischaemia, and 14 horses suffering from naturally occurring colic syndrome. Tissue samples of lungs, liver, heart, brain, cerebellum and hoof laminar tissue were collected for histopathological and oxidative stress evaluation using nitrotyrosine and superoxide dismutase (SOD2) immunostaining. The horses were divided into two groups: the non-oxidative lesions group (NOLG), with 7 horses showing weak immunostaining in lungs, liver and kidney, and the oxidative lesions group (OLG), with 14 horses showing immunostaining indicating systemic oxidative stress in multiple organs. The horses from OLG showed increase of laminar lesions and SOD2 immunostaining in multiple organs when compared to the horses from the NOLG. No differences were found in regard to laminar immunostaining by nitrotyrosine and SOD2 between experimental groups. It was concluded that systemic oxidative stress can be associated with the development of laminar lesions, and that the laminar tissue does not respond to oxidative stress with increase of SOD as occurs in other organs.

INDEX TERMS: Laminitis, nitrotyrosine, peroxyxynitrite, superoxide dismutase, sepsis, horses.

RESUMO.- [Lesões laminares em cavalos com estresse oxidativo sistêmico, acometidos por doenças gastrintestinais experimentalmente induzidas ou de ocorrência natural.] A laminite em equinos pode estar associada

à lesão em múltiplos órgãos secundária a sepsis. Foram utilizados 21 cavalos com afecções gastrintestinais, sendo sete com endotoxemia e isquemia intestinal induzidos experimentalmente, e 14 cavalos com síndrome cólica de origem natural. Amostras teciduais de pulmão, rim, fígado, coração, cérebro e cerebelo e de tecido laminar do casco foram coletadas para avaliação de lesão histopatológica e estresse oxidativo, pela imunomarcagem de nitrorosina e superóxido dismutase (SOD2). Os animais foram divididos em dois grupos: grupo sem lesão oxidativa (NOLG), com sete cavalos com fraca imunomarcagem em pulmão, fígado e rim, e grupo lesão oxidativa (OLG), contendo 14 cavalos com imunomarcagem indicando estresse oxidativo em múltiplos órgãos. Os cavalos do grupo OLG apresentaram aumento de lesões laminares e imunomarcagem para SOD2 em múltiplos órgãos, quando comparados ao NOLG. Não

¹ Received on January 29, 2016.

Accepted for publication on April 26, 2016.

² Pós-Graduação em Ciências Veterinárias, Universidade Federal do Paraná (UFPR), Campus de Curitiba, Rua dos Funcionários 1540, Curitiba, PR 80035-050, Brazil. *Corresponding author: luci.laskoski@gmail.com

³ Departamento de Medicina Veterinária, UFPR, Campus de Curitiba, Rua dos Funcionários 1540, 80035-050, Curitiba, PR 80035-050, Brazil.

⁴ Pós-Graduação em Ciência Animal, Centro de Ciências Agroveterinárias (CAV), Universidade do Estado de Santa Catarina (UDESC), Av. Luiz de Camões 2090, Lages, SC 88520-000, Brazil.

⁵ Pós-Graduação em Cirurgia Veterinária, Universidade Estadual Paulista "Júlio de Mesquita Filho" (Unesp), Campus de Jaboticabal, Via de Acesso Professor Paulo Donato Castellane s/n, Jaboticabal, SP 14884-900, Brazil.

houve diferença sobre a imunomarcção laminar para nitrotirosina e SOD2 entre os grupos experimentais. Conclui-se que o estresse oxidativo sistêmico está associado ao desenvolvimento de lesões laminares, e que o tecido laminar não responde ao estresse oxidativo com aumento de SOD como ocorre nos outros órgãos.

TERMOS DE INDEXAÇÃO: Laminite, nitrotirosina, peroxinitrito, superóxido dismutase, seps, equinos.

INTRODUCTION

Laminitis is a severe podal disorder which affects horses and occurs commonly secondary to other inflammatory diseases with systemic implication, such as the colic syndrome (Parsons et al. 2007), or in horses showing endocrinopathic changes, such as pituitary pars intermedia dysfunction (PPID) (Johnson et al. 2002). Horses suffering from colic syndrome and PPID can show laminar lesions even without clinical signs of laminitis (Laskoski et al. 2009, Laskoski et al. 2015).

Laminitis shares many characteristics with the dysfunction in multiple organs that occurs in sepsis or systemic inflammatory response syndrome (SIRS) in humans (Belknap et al. 2009), such as the presence of systemic clinical signs compatible with SIRS (Tadros et al. 2012), increase of systemic inflammatory mediators, leukocyte infiltration (Faleiros et al. 2011) and expression of pro-inflammatory cytokines in hoof laminar tissue (Fontaine et al. 2001, Riggs et al. 2007).

Oxidative stress plays an important role in the development of multiple organ failure and sepsis (Galley 2010), by reaction of free radicals with proteins, lipids and DNA (Berg et al. 2004), and it is associated with the pathogenesis of laminar lesions (Loftus et al. 2006, Yin et al. 2009, de Laat et al. 2012). Peroxynitrite is an oxidant arising from the reaction of nitric oxide and superoxide anions (Carerras et al. 1994), and its main function is to destroy invading microorganisms by binding to proteins, but consequently causing cell injury (Ischiropoulos & Al-Mehdi 1995, Szabó et al. 2012, Weidinger & Kozlov 2015). Nitrotyrosine is identified as a marker for peroxynitrite (Ischiropoulos & Al-Mehdi 1995).

Non-pathological conditions can trigger oxidative stress associated to immune response of the organism, as it occurs physiologically in the liver that is exposed to toxins from the intestines pumped to the liver through the portal vein (Nolan & Camara 1985, Cogger et al. 2004). Therefore, immunostaining for nitrotyrosine can be observed in tissues without lesion, such as the liver (Ottesen et al. 2001), kidney (Kong et al. 2012, Xu et al. 2015) and lungs (Haddad et al. 1994) of healthy humans or animals. The organs such as heart and nervous system do not show the presence of nitrotyrosine in healthy animals (Tanaka et al. 1997, Bodega et al. 2006, Szabó et al. 2012). There are tissue antioxidants that control the gravity of lesions caused by oxidants, such as superoxide dismutase enzyme (SOD), and an imbalance between them affect the neutralization capacity of these substances, resulting in oxidative injury (Beckman et al. 1994, Macdonald et al. 2003). Loftus et al. (2006) sho-

wed that SOD is not present in the hoof laminar tissue of healthy horses. The increase of this substance occurs after, probably in an attempt to reduce the deleterious effects of oxidizing species released (Gimenez-Garzo et al. 2015). Nitrotyrosine and SOD levels increased after sepsis induction in rats, but the antioxidant effect is insufficient to protect the lungs against severe sepsis (Constantino et al. 2014)

The aim of this study was to evaluate the severity of laminar lesions in horses with systemic oxidative stress, affected by naturally occurring or experimentally induced gastrointestinal disorders.

MATERIALS AND METHODS

Animals. Samples of hoof laminar tissue from the four limbs were collected from 21 male and female horses, from different breeds, weighing between 250-560 kg, aged 8 to 15 years. From these horses, 7 were submitted to experimental intestinal ischaemia and lipopolysaccharide (LPS) administration, and 14 horses died or were submitted to euthanasia after complications caused by naturally occurring gastrointestinal disorders.

Experimental design. Intestinal ischaemia and endotoxemia induction: Seven horses⁶ were submitted to food and water fasting. The dose of 50ng/kg *Escherichia coli* 055:B5 (Sigma) was diluted in 0.9% saline solution and infused intravenously over a period of 30 minutes. One hour and a half after endotoxemia induction, the horses were sedated with acepromazine chlorhydrate and detomidine chlorhydrate, IV. The left paracostal fossa was prepared and local anesthesia was administered in an inverted L pattern, using 2% lidocaine hydrochloride. Then, the small intestine was exposed with the horse in standing position. A Penrose drain (number 3) was inserted forming a loop through the bowel 30 cm from the ileocecal valve, blocking mesenteric irrigation for three hours. After this period, ischaemia was undone by withdrawing the Penrose drain, and the previously obstructed segment was repositioned and subjected to reperfusion for 7 hours and 30 minutes. Then, the animal was euthanized using an overdose of anesthetics.

Natural Gastrointestinal Disorders: 14 horses were treated at Veterinary Hospitals of Higher Education Institutions for colic syndrome. The causes of gastrointestinal disorders were grain overload (n=2), enterolithiasis (n=2), intestinal impaction (n=4) and colon displacement/twisted bowel (n=6), which caused death or led to the indication of euthanasia due to intestinal ischaemia and necrosis. The experiment was approved by the Animal Welfare and Ethics Committee of the Federal University of Parana (protocol number 038/2012).

Tissue samples and histopathology. Samples tissues of the lungs, heart, kidney, liver, brain and cerebellum were collected from all horses. Hoof laminar tissue were collected from four limbs, after cross-sectioning the hoof wall, and was collected with a scalpel blade and forceps, containing the interface between dermic and epidermal laminae (Pollitt 1996). Samples were fixed in 10% buffered formalin for 48 hours, and routinely processed and stained with hematoxylin and eosin (HE) and periodic acid-Schiff (PAS) for histologic evaluation in the hoof laminar tissue.

Light microscopy was performed by three observers, following the method described by Pollitt (1996) with adaptation,

⁶ Samples obtained of study "Clinical and laboratory aspects of methylene blue used in the experimental obstruction of the jejunum in horses exposed to lipopolysaccharide", approved by Animal Welfare and Ethics Committee of the São Paulo State University (Unesp), Campus of Jaboticabal, SP (protocol no. 12471/07).

Table 1. Medians and inter-quartile range for the laminar lesions grades and scores of SOD2 immunostaining in the organs and in hoof laminar tissue, and nitrotyrosine laminar immunostaining, in the NOLG and OLG experimental groups (p<0.05)

	Laminar lesions grades	SOD2 immunostaining scores in the organs	Nitrotyrosine laminar immunostaining score	SOD2 laminar immunostaining score
NOLG	0 (0-0) a	1 (1-1) a	0 (0-0) a	0 (0-0) a
OLG	1 (0-1) b	2 (1-2) b	0 (0-1) a	0 (0-1) a

and the severity of laminar lesions were graded as 0, 1, 2 and 3 (Laskoski et al. 2015).

Immunohistochemistry for nitrotyrosine and SOD2. Nitrotyrosine and SOD2 in hoof laminar tissue and organs were investigated using immunohistochemistry. Paraffin-embedded tissue sections (5 µm) placed on positively charged slides were deparaffinized and antigen retrieval was performed in sodium citrate using a slow cooker for 30 minutes (92-95°C/197-203°F). A commercial kit was used to block proteins (DPB-125, Spring Bioscience, Pleasanton, CA, EUA), and endogenous peroxidase (DHP-125, Spring Bioscience, Pleasanton, CA - EUA). Mouse anti-nitrotyrosine (AB 61392, ABCAM, San Francisco, USA) antibody was diluted 1:6000, and rabbit anti-SOD2 (AB 13534, ABCAM, San Francisco, USA) antibody was diluted 1:4000. Both antibodies were incubated for 60 minutes at room temperature, following incubation with universal immunoperoxidase polymer (Nichi-414152-F, Nichirei Bioscience Inc, Tokyo, Japan) for 30 minutes. The DAB reaction was performed for four minutes and counterstained with Harris hematoxylin for 30 seconds, dehydrated with ethanol, cleared with xylene and mount with a resinous medium. Slides were evaluated by three independent observers.

Evaluation of nitrotyrosine and SOD2 staining in organs was graded according to the immunostaining intensity, and in the hoof laminar tissue was made using scores as described for Laskoski et al. (2016).

Experimental groups. The horses were divided in two experimental groups, according to the immunostaining intensity for nitrotyrosine in the organs:

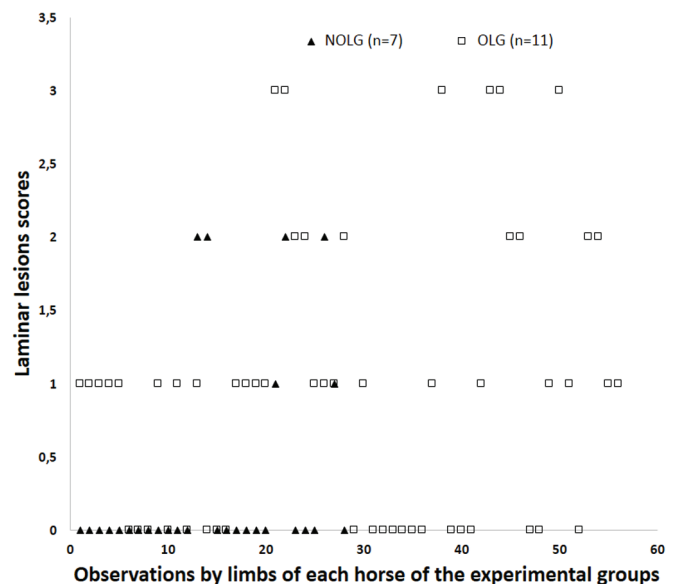
- 2.5.1 Non Oxidative Lesion Group (NOLG): seven horses with immunostaining of weak intensity in liver, kidney and lung, considered as expected in healthy animals, by the characteristics of the organs (contact with organisms and/or toxins).
- 2.5.2 Oxidative Lesion Group (OLG): fourteen horses with immunostaining of moderate to strong intensity in liver, kidney and lung, and presence in heart and nervous system (brain and cerebellum).

Statistical analysis. The medians found for the grades of laminar lesions, immunostaining intensity score for nitrotyrosine in the hoof laminar tissue and immunostaining score for SOD2 in the hoof laminar tissue and in the organs were compared in both experimental groups using the Mann Whitney test (p<0.05).

RESULTS

Experimental groups

Two horses suffering from experimentally induced intestinal ischemia and endotoxemia were included in the NOLG, and the five remaining horses were included in the OLG. Previous statistical results (Mann Whitney test) showed no difference between any of the variables analyzed when comparing horses suffering from experimentally induced or naturally occurring gastrointestinal disorders, and thus, the data of all horses could be used.



intense immunostaining was observed in the bronchial and alveolar epithelium and macrophages of lungs, in cortical and medullary zones of the kidney and in hepatocytes and also nitrotyrosine residues in the sinusoids and blood vessels of the liver. In this group immunostaining was also observed in cardiomyocytes and endothelium heart vessels; neuron body, intravascular leukocytes in the brain and in Purkinje neurons of the cerebellum (Fig.2). Nitrotyrosine immunostaining in these organs was used only to define the experimental groups.

Nitrotyrosine immunostaining in laminar tissue was observed in dermal laminae, in cytoplasm and in the nucleus of endothelial cells and leukocytes, and also as nitrotyrosine residues into blood vessels or in tissue. Immunostaining for nitrotyrosine in the hoof laminar tissue showed from completely absent staining to strong intensity, with score 3. Ten horses showed no immunostaining for nitrotyrosine in any limb, four of the GSLO and six of the GLO. Nine had a score 1, three of the GSLO and six of the GLO. A horse showed a score of 2 on a limb, and a horse showed score 3 in all four limbs, both of GLO. There was no difference between the laminar medians scores observed in the experimental groups (Table 1). The score median observed in the NOLG was 0, and the score median observed in the OLG was 0.

Immunostaining for SOD 2

Was observed in all organs, with tissue stains in regions similar to the nitrotyrosine, but more widespread in the cell cytoplasm. The most important immunostaining was observed in the bronchial and bronchiolar area in lungs; in the hepatocytes and sinusoids in the liver; in kidney, in the tubular area; in the heart, in the sarcoplasm of cardiomyocytes; Purkinje neurons in the cerebellum and brain neurons (Fig.3). The immunostaining were considered of moderate intensity (score 1), with more concentrated stained areas and of strong intensity (score 2), when the staining was disseminated in the tissue evaluated. The OLG showed increased median of SOD2 immunostaining when compared to NOLG (table 1), with score median of 2. The score median observed in the NOLG was 1.

The SOD2 immunostaining in the laminar tissue occurred in cell cytoplasm, and it was considered specific and positive in epidermal laminae. No immunostaining for SOD2 was observed in the hoof laminar tissue of 12 horses, four of them from the NOLG, and eight from the OLG. Seven horses had a score 1, two of the GSLO and five of the GLO. Two horses showed a score 2, one from each experimental group. No horse of this study had a score 3 of SOD2 immunostaining. There was no difference in the intensity of laminar immunostaining for SOD2 between the medians obtained in the two experimental groups (table 1). The score median observed in these groups was 0,

DISCUSSION

It was considered that the organs assessed were under intense oxidative stress in the horses from the OLG, confirmed by nitrotyrosine immunostaining. Oxidative stress has been implicated in the development of tissue injury in

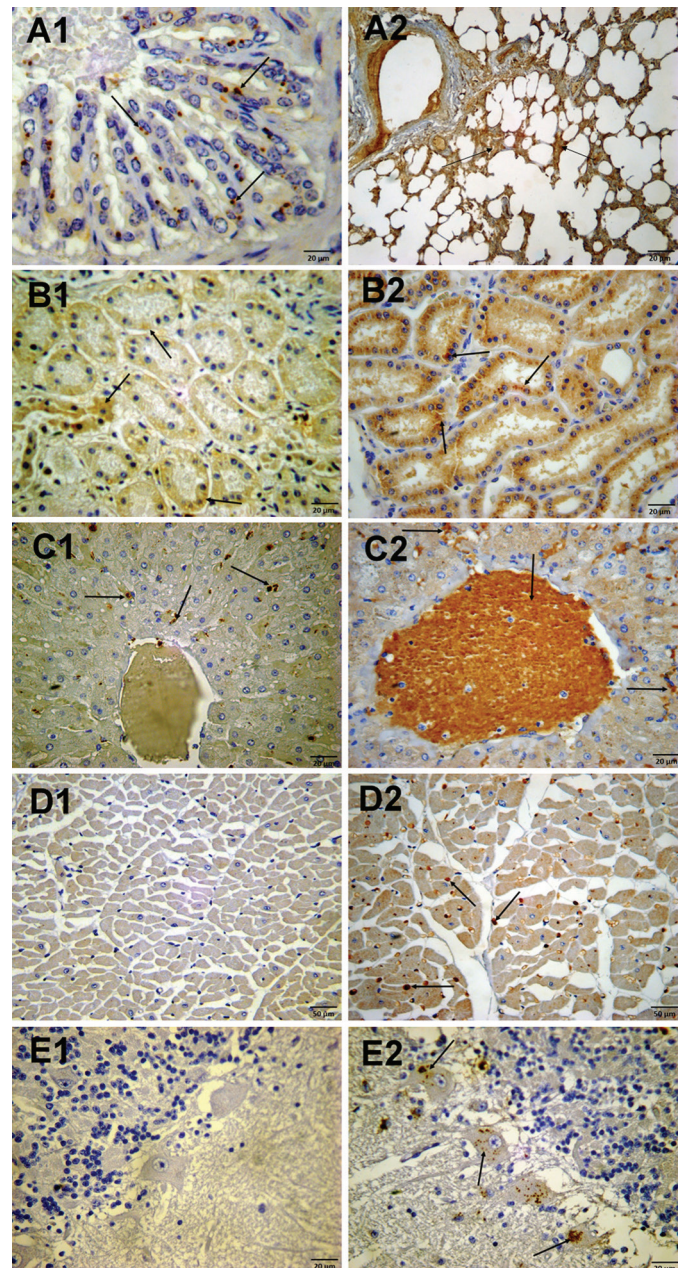


Fig.2. Immunohistochemistry photomicrography. Anti-nitrotyrosine antibody, counterstained with Harris hematoxylin, in tissues of the horses suffering from gastrointestinal disorders. **Lung (A1)** Immunostaining of weak intensity in the cytoplasm of bronchial epithelial cells (arrows, NOLG). **(A2)** Strong positivity in the interalveolar septum (arrows, OLG). **Kidney (B1)** Immunostaining of weak intensity in the cytoplasm of the renal tubular epithelium (arrows, NOLG). **(B2)** Strong positivity in cytoplasm of the renal tubular epithelium (arrows, OLG). **Liver (C1)** Immunostaining of weak intensity in the cytoplasm of hepatocytes (arrows, NOLG). **(C2)** Immunostaining of strong intensity in the sinusoid. In centrolobular vein, there is immunostaining of nitrotyrosine residues and inflammatory cells (arrows, OLG). **Heart (D1)** Absence of immunostaining in cardiomyocytes (NOLG). **(D2)** There is positive immunostaining in the cardiomyocytes (arrows, OLG). **Cerebellum (E1)** Absence of immunostaining between the granular layer, Purkinje neurons and molecular layer of the cerebellum (NOLG). **E2.** Positive immunostaining in the Purkinje neurons and in the neuropils (arrows, OLG).

several diseases, such as kidney injury as a result of experimental sepsis (Pathak et al. 2012), organ failure caused by hemorrhagic shock in kidney, lungs, liver and intestine (Mo-

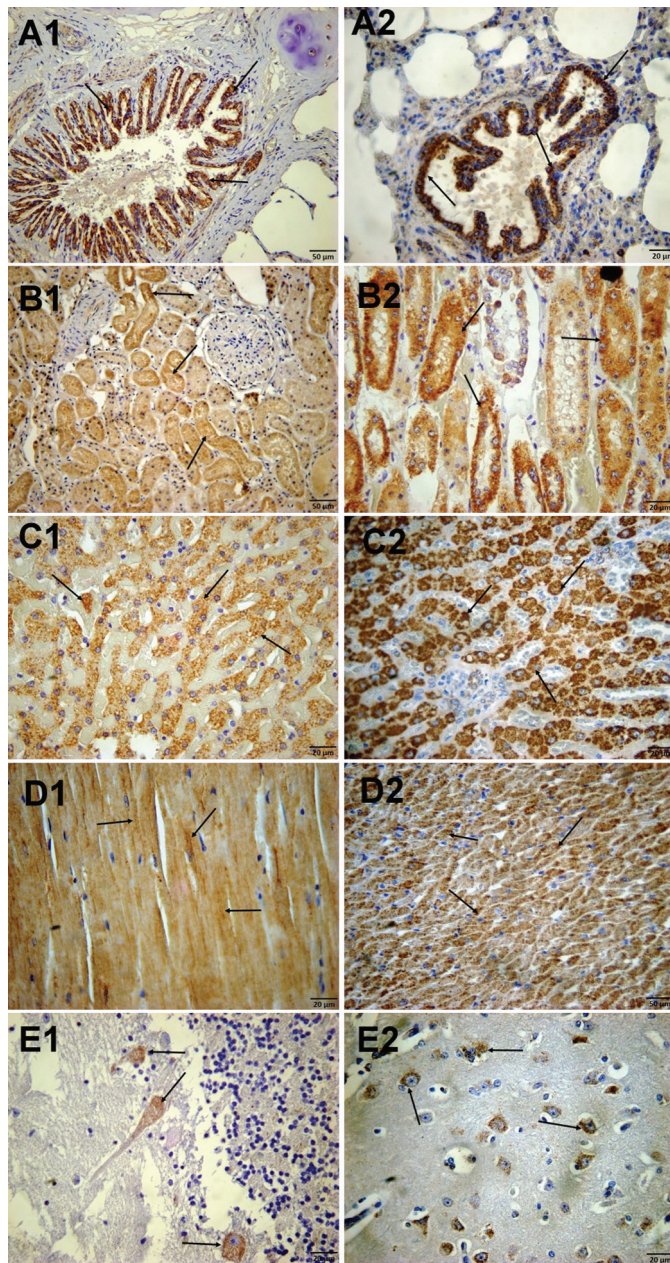


Fig.3. Immunohistochemistry photomicrography using anti-SOD2 antibody, counterstained with Harris hematoxylin, in tissues from horses suffering from gastrointestinal disorders. **Lung (A1)** Strong immunostaining in bronchial epithelium (arrows, NOLG). **(A2)** Strong immunostaining in bronchiolar epithelium (arrows, OLG). **Kidney (B1)** Immunostaining of moderate intensity in the renal tubular epithelium (arrows, NOLG). **(B2)** Immunostaining of strong intensity in the renal tubular epithelium (arrows, OLG). **Liver (C1)** Immunostaining of moderate intensity in sinusoids (arrows, NOLG). **C2.** Immunostaining of strong intensity in sinusoids (arrows, OLG). **Heart (D1)** Immunostaining of moderate intensity in sarcoplasm (arrows, OLG). **(D2)** Immunostaining of strong intensity in sarcoplasm (arrows, OLG). **Cerebellum (E1)** Immunostaining of the moderate intensity in neurons of Purkinje (arrows, OLG). **(E2)** Brain. Immunostaining of moderate intensity in the brain axons (arrows, OLG).

ta-Filipe 1990), and acetaminophen hepatotoxicity (Knight et al. 2002). Peroxynitrite, a powerful oxidant agent, can be associated to oxidative lesion by the nitrotyrosine immunostaining in tissues, as observed by Constantino et al. (2014) in the lungs of rats submitted to experimental sepsis. Peroxynitrite is formed by the reaction between nitric oxide and superoxide anions (Beckman et al. 1994) and promotes endothelial dysfunction, vascular hyporeactivity, primary myocardial disease (Szabó 1996) and inactivation of mitochondrial electron transport, damaging cellular respiration (Radi et al. 1994). The immunostaining of weak intensity observed in the lungs, liver and kidneys of the horses from the NOLG were considered as control because mild oxidative stress occurs in these organs in healthy animals (Haddad et al. 1994, Ottesen et al. 2001, Xu et al. 2015), and only strong staining are associated with lesions and inflammatory diseases in lungs (Haddad et al. 1994), in hepatic parenchyma (Ottesen et al. 2001), in tubular epithelial cells in medulla and in the cortex zone in experimental endotoxemia in rats (Xu et al. 2015). However, in the heart and nervous system, no immunostaining for nitrotyrosine is observed in healthy animals (Bodega et al. 2006, Szabó et al. 2012).

In this study, horses suffering from induced or naturally occurring gastrointestinal disorders were used as induction model of lamellar lesions. The study of laminitis, using clinical cases of horses affected by natural gastrointestinal disorders was also carried out by Steelman et al. (2014), even if there are relevant variations between the causes of the diseases and clinical evolution of the patients. Horses with colic syndrome can develop sepsis (Parsons et al. 2007, Wylie et al. 2012) that can result in oxidative damage in organs distant from the intestinal damage, causing multiple organ failure (Fink 2002, Galley 2010, Alkharfy et al. 2015). Epstein et al. (2011) determined that around 30% of horses undergoing treatment of colic may develop SIRS, with symptoms including tachycardia, tachypnea, leukocytosis or leukopenia. Endotoxemia has been associated with laminitis in horses, especially in colic syndrome; however, the administration of endotoxin does not induce laminitis in healthy horses (Tadros & Frank 2012). The most important studies of sepsis are carried out using cecal ligation and puncture in laboratory animals for more comprehensive verification of SIRS, since systemic inflammatory response can be caused by a complex process, such as damage in organs (Zeng et al. 2015).

The results observed in the OLG showed that the horses affected by oxidative stress, with strong immunostaining for nitrotyrosine in liver, kidney lungs, nervous tissue and heart, had more serious lamellar lesions. So, it is suggested that the development of laminitis is associated with the systemic oxidative status. Belknap et al. (2009) suggested that laminitis is similar to organ dysfunction that occurs in human sepsis, which corroborates the results of our study, demonstrating that lamellar lesions are more severe in horses affected by systemic oxidative stress, which can cause multiple organ failure. Similar result was showed by Tadros et al. (2012) and Stewart et al. (2009), who observed

that only the horses that developed clinical laminitis after the administration of oligofructose or black walnut extract (BWE), showed inflammatory response in organs such as the liver and lungs.

Burns et al. (2011) did not observed increase of immunostaining for laminar nitrotyrosine in horses affected by experimentally induced laminitis by carbohydrate overload or BWE. In this study, intense nitrotyrosine immunostaining were observed in some horses; however, no difference was found between the experimental groups, which demonstrates that peroxynitrite may not be the major triggering oxidant agent.

SOD is an antioxidant that converts the superoxide anions, preventing the formation of peroxynitrite. However, the isolated increase of tissue SOD is not sufficient to prevent oxidative damage, because other antioxidants are necessary to degrade the products of this reaction, such as hydrogen peroxide (H₂O₂), a powerful oxidant that is degraded by catalase (Halliwell & Gutteridge 1995). Sepsis causes an uneven increase in the relation of SOD and catalase, which exacerbates oxidative stress (Visner et al. 1990, Andrades et al. 2005, Andrades et al. 2011). In this study, all horses showed immunostaining for SOD2 in organs, and horses from the OLG showed increased immunostaining for SOD2, which corroborates the findings of increase of this antioxidant in systemic inflammatory response, especially if caused by sepsis (Constantino et al. 2014, Gimenez-Garzo et al. 2015). SOD2 present in hoof laminar tissue of horses in this study was observed in different intensities variables between animals, and no difference was observed among experimental groups. SOD is only observed in the hoof laminar tissue during the development period of laminitis (Noschka et al. 2009), and different from that occurs in others organs such as liver, lung and skin, laminar SOD is not found in healthy horses.

It is believed that the hoof laminar tissue is more susceptible to the lesions when compared to others organs in multiple organ failure, due to increased expression of inflammatory mediators, lower antioxidant capacity and physical stress caused by the traction exerted by the locomotion structure, which does not occur in any other organ (Belknap et al. 2009, Stewart et al. 2009, Yin et al. 2009). The laminar tissue of the hoof, when compared to others organs, lies in deep hypoxic environment and, in the development period of laminitis, hypoxia worsens, which may explain why this tissue is more susceptible to lesion caused by the inflammatory damage in sepsis (Pawlak et al. 2013). In this study, it was observed that horses affected by systemic oxidative stress showed more severe laminar lesions. Others substances apart from peroxynitrite may be involved in the development of laminitis that occurs together with the multiple organ failure, but that shows laminar repercussions more severe due to the inherent characteristics of this tissue. Another point to be considered is that, although there are strong oxidative stress, only two horses showed lesions in organs, in the others no showed lesions. Thus, maybe these tissues would not have their function committed if the animal survived, different from what was observed for the hoof laminar tissue, wherein at least four

horses affected by laminar lesion grade 3 would probably present clinical signs of laminitis.

CONCLUSIONS

The systemic oxidative stress contributes to the development of more serious laminar injuries in horses with gastrointestinal disorders.

Laminar tissue does not increase the expression of superoxide dismutase, as the other organs, arouse by systemic oxidative stress.

Acknowledgements.- Supported by FAPESP (Scholarship nº 2006/05271-9 and research granted nº 2007/01604-6).

REFERENCES

- Alkharfy K.M., Ahmad A., Raish M. & Vanhoutte P.M. 2015. Thymoquinone modulates nitric oxide production and improves organ dysfunction of sepsis. *Life Sci.* 143:131-138.
- Andrades M., Ritter C., Moreira J.C. & Dal-Pizzol F. 2005. Oxidative parameters differences during non-lethal and lethal sepsis development. *J. Surg. Res.* 125(1):68-72.
- Andrades M., Ritter C., Streck E.L., Moreira C.F. & Dal-Pizzol F. 2011. Antioxidant treatment reverses organ failure in rat model of sepsis: role of antioxidant enzymes imbalance, neutrophil infiltration, and oxidative stress. *J. Surg. Res.* 167:307-313.
- Beckman J.S., Chen J., Ischiropoulos H. & Crow J.E. 1994. Oxidative chemistry of peroxynitrite. *Methods Enzymol.* 233:229-240.
- Belknap J.K., Moore J.N. & Crouser E.C. 2009. Sepsis from human organ failure to laminar failure. *Vet. Immunol. Immunopathol.* 129(3/4):155-157.
- Berg K., Wiseth R., Bjerve K., Brurok H., Gunnes S., Skarra S., Jynge P. & Basu S. 2004. Oxidative stress and myocardial damage during elective percutaneous coronary interventions and coronary angiography: a comparison of blood-borne isoprostane and troponin release. *Free Rad. Res.* 38(5):517-525.
- Bodega S.G., Arilla E., Felipe V. & Fernández B. 2006. The expression of nNOS, iNOS and nitrotyrosine is increased in the rat cerebral cortex in experimental hepatic encephalopathy. *Neuropathol. Appl. Neurobiol.* 32(6):594-604.
- Burns T.A., Westerman T., Nuovo G.J., Watts M.R., Pettigrew A., Yin C. & Belknap J.K. 2011. Role of oxidative tissue injury in the pathophysiology of experimentally induced equine laminitis: comparison of 2 models. *J. Vet. Intern. Med.* 25(3):540-548.
- Carreras M.C., Pargament G.A., Catz S.D., Poderoso J.J. & Boveris A. 1994. Kinetics of nitric oxide and hydrogen peroxide production and formation of peroxynitrite during the respiratory burst of human neutrophils. *FEBS Lett.* 341(1):65-68.
- Cogger V.C., Muller M., Fraser R., McLean A.J., Khan J. & Couteur D.L. 2004. The effects of oxidative stress on the liver sieve. *J. Hepatol.* 41(3):370-376.
- Constantino L., Gonçalves R.C., Giombelli V.R., Tomasi C.D., Vuolo F., Kist L.W., Oliveira G.M., Pasquali M.A., Bogo M.R., Mauad T., Horn A. Jr, Melo K.V., Fernandes C., Moreira J.C., Ritter C. & Dal-Pizzol F. 2014. Regulation of lung oxidative damage by endogenous superoxide dismutase in sepsis. *Int. Care Med. Exp.* 1:2-17.
- de Laat M.A., Kyaw-Tanner M.T., Sillence M.N., McGowan C.M. & Pollitt C.C. 2012. Advanced glycation end products in horses with insulin-induced laminitis. *Vet. Immunol. Immunopathol.* 145(1-2):395-401.
- Epstein K.L., Brainard B.M., Gomez-Ibanez S.E., Lopes M.A., Barton M.H. & Moore J.N. 2011. Thrombelastography in horses with acute gastrointestinal disease. *J. Vet. Intern. Med.* 25(2):307-14.
- Faleiros R.R., Johnson P.J., Nuovo G.J., Messer N.T., Black S.J. & Belknap J.K. 2011. Lamellar leukocyte accumulation in horses with carbohydrate overload-induced laminitis. *J. Vet. Intern. Med.* 25(1):107-115.

- Fink M.P. 2002. Reactive oxygen species as mediators of organ dysfunction caused by sepsis, acute respiratory distress syndrome, or hemorrhagic shock: potential benefits of resuscitation with Ringer's ethyl pyruvate solution. *Curr. Opin. Clin. Nutr. Metab. Care* 5(2):167-174.
- Fontaine G.L., Belknap J.K., Allen D., Moore J.N. & Kroll D.L. 2001. Expression of interleukin-1beta in the digital laminae of horses in the prodromal stage of experimentally induced laminitis. *Am. J. Vet. Res.* 62(5):714-720.
- Galley H.F. 2010. Bench-to-bedside review: targeting antioxidants to mitochondria in sepsis. *Crit. Care* 14(4):230.
- Gimenez-Garzo C., Urios A., Agust A., Gonzalez-Lopez O., Escudero-Garcia D., Escudero-Sanchis A., Serra M.A., Giner-Duran R., Montoliu C. & Felipo V. 2015. Is Cognitive Impairment in Cirrhotic Patients Due to Increased Peroxynitrite and Oxidative Stress? *Antioxid. Redox Signal.* 22(10):871-877.
- Haddad I.Y., Hu G.P.P., Galliani C., Beckman J.S. & Matalon S. 1994. Quantitation of Nitrotyrosine Levels in Lung Sections of Patients and Animals with Acute Lung Injury. *J. Clin. Invest.* 94(6):2407-2413.
- Halliwell B. & Gutteridge J.M. 1995. The definition and measurement of antioxidants in biological systems. *Free Rad. Bio. Med.* 18(1):125-126.
- Ischiropoulos H. & Al-Mehdi A.B. 1995. Peroxynitrite-mediated oxidative protein modifications. *FEBS Lett.* 364(3):279-282.
- Johnson P.J. 2002. The equine metabolic syndrome peripheral Cushing's syndrome. *Vet. Clin. North Am. Equine Pract.* 18(2):271-293.
- Knight T.R., Ho Y.S., Farhood A. & Jaeschke H. 2002. Peroxynitrite is a critical mediator of acetaminophen hepatotoxicity in murine livers: protection by glutathione. *J. Pharmacol. Exp. Ther.* 303(2):468-475.
- Kong X., Zhang Y., Wu H., Li F., Zhang D. & Su Q. 2012. Combination therapy with losartan and pioglitazone additively reduces renal oxidative and nitrate stress induced by chronic high fat, sucrose, and sodium intake. *Oxidative Medicine and Cellular Longevity* 2012: Article ID 856085, 9p. <<http://dx.doi.org/10.1155/2012/856085>>
- Laskoski L.M., Valadão C.A.A., Vasconcelos R.O., Pereira R.N., Uribe Dias A.D.P. & Alessi A.C. 2009. Morphologic alterations of the hoof lamellar tissue, and clinic and laboratorial analyses of horses with lethal colic syndrome. *Pesq. Vet. Bras.* 29(9):731-735.
- Laskoski L.M., Locatelli-Dittrich R., Valadão C.A.A., Deconto I., Gonçalves K.A., Montiani-Ferreira F., Brum J.S., de Brito H.F. & de Sousa R.S. 2015. Systemic leukopenia, evaluation of lamellar leukocyte infiltration and lamellar lesions in horses with naturally occurring colic syndrome. *Res. Vet. Sci.* 101:15-21.
- Laskoski L.M., Dittrich R.L., Valadão C.A., Brum J.S., Brandão Y., Brito H.F. & Sousa R.S. 2016. Oxidative stress in hoof lamellar tissue of horses with lethal gastrointestinal diseases. *Vet. Immun. Immun.* 171:66-72.
- Loftus J.P., Belknap J.K., Stankiewicz K.M. & Black S.J. 2006. Lamellar xanthine oxidase, superoxide dismutase and catalase activities in the prodromal stage of black-walnut induced equine laminitis. *Eq. Vet. J.* 39(1):48-53.
- MacDonald J.H.F., Galley H.F. & Webster N.R. 2003. Oxidative stress and gene expression in sepsis. *Br. J. Anaesth.* 90(2):221-232.
- Mota-Filipe H., McDonald M.C., Cuzzocrea S. & Thiemermann C.A. 1990. Membrane-permeable radical scavenger reduces the organ injury in hemorrhagic shock. *Shock* 12(4):255-261.
- Nolan J.P. & Camara D.S. 1985. The importance of intestinal endotoxins in liver disease. *Prog. Clin. Biol. Res.* 189:347-367.
- Noschka E., Vandenplas M.L., Hurley D.J. & Moore J.N. 2009. Temporal aspects of lamellar gene expression during the developmental stages of equine laminitis. *Vet. Immunol. Immunopathol.* 129(3/4):242-253.
- Ottesen L.H., Harry D., Frost M., Davies S., Khan K., Halliwell B. & Moore K. 2001. Increased formation of S-nitrothiols and nitrotyrosine in cirrhotic rats during endotoxemia. *Free Rad. Biol. Med.* 31(6):790-798.
- Parsons C.S., Orsini J.A., Krafty R., Capewell L. & Boston R. 2007. Risk factors for development of acute laminitis in horses during hospitalization: 73 cases (1997-2004). *J. Am. Vet. Med. Assoc.* 230(6):885-889.
- Pathak E., MacMillan-Crow L.A. & Mayeux P.R. 2012. Role of mitochondrial oxidants in an in vitro model of sepsis-induced renal injury. *J. Pharmacol. Exp. Ther.* 340(1):192-201.
- Pawlak E.A., Geor R.J., Watts M.R., Black S.J., Johnson P.J. & Belknap J.K. 2013. Regulation of hypoxia-inducible factor-1a and related genes in equine digital lamellae and in cultured keratinocytes. *Equine Vet. J.* 46(2):203-209.
- Pollitt C.C. 1996. Basement membrane pathology: a feature of acute equine laminitis. *Equine Vet. J.* 28(1):38-46.
- Radi R., Rodriguez M., Castro L. & Telleri R. 1994. Inhibition of mitochondrial electron transport by peroxynitrite. *Arch. Biochem. Biophys.* 308(1):89-95.
- Riggs L.M., Franck T., Moore J.N., Krunkosky T.M., Hurley D.J., Peroni J.F., de la Rebiere G. & Sertejn D.A. 2007. Neutrophil myeloperoxidase measurements in plasma, lamellar tissue, and skin of horses given black walnut extract. *Am. J. Vet. Res.* 68(1):81-86.
- Stelman S.M., Johnson P., Jackson A., Schulze J. & Chowdhary P.B. 2014. Serum metabolomics identifies citrulline as a predictor of adverse outcomes in an equine model of gut-derived sepsis. *Physiol. Genomics* 46(10):339-347.
- Szabó C. 1996. The pathophysiological role of peroxynitrite in shock, inflammation, and ischemia-reperfusion injury. *Shock* 6(2):79-88.
- Szabó G., Loganathan S., Merkely B., Groves J.T., Karck M., Szabó C. & Radovits T. 2012. Catalytic peroxynitrite decomposition improves reperfusion injury after heart transplantation. *J. Thor. Cardiovasc. Surg.* 143(6):1443-1449.
- Stewart A.J., Pettigrew A., Cochran A.M. & Belknap J.K. 2009. Indices of inflammation in the lung and liver in the early stages of the black walnut extract model of equine laminitis. *Vet. Immunol. Immunopathol.* 129(3/4):254-260.
- Tadros E.M. & Frank N. 2012. Effects of continuous or intermittent lipopolysaccharide administration for 48 hours on the systemic inflammatory response in horses. *Am. J. Vet. Res.* 73(9):1394-1402.
- Tadros E.M., Frank N., Newkirk K.M., Donnell R.L. & Horohov D.W. 2012. Effects of a "two-hit" model of organ damage on the systemic inflammatory response and development of laminitis in horses. *Vet. Immunol. Immunopathol.* 150(1/2):90-100.
- Tanaka K., Shirai T., Nagata E., Dembo T. & Fukuuchi Y. 1997. Immunohistochemical detection of nitrotyrosine in postischemic cerebral cortex in gerbil. *Neurosci. Lett.* 235(1/2):85-88.
- Visner G.A., Dougall W.C., Wilson J.M., Burr I.A. & Nick H.S. 1990. Regulation of manganese superoxide dismutase by lipopolysaccharide, interleukin-1, and tumor necrosis factor. Role in the acute inflammatory response. *J. Biol. Chem.* 265(5):2856-2864.
- Xu S., Chen Y., Tan Z., Xie D., Zhang C., Xia M., Wang H., Zhao H., Xu D. & Yu D. 2015. Vitamin D3 pretreatment alleviates renal oxidative stress in lipopolysaccharide-induced acute kidney injury. *J. Steroid Biochem. Mol. Biol.* 152:133-141.
- Weidinger A. & Kozlov A.V. 2015. Biological activities of reactive oxygen and nitrogen species: oxidative stress versus signal transduction. *Biomolecules* 5(2):472-484.
- Wylie C.E., Collins S.N., Verheyen K.L. & Newton J.R. 2012. Risk factors for equine laminitis: a systematic review with quality appraisal of published evidence. *Vet. J.* 193(1):58-66.
- Yin C., Pettigrew A., Loftus J.P., Black S.J. & Belknap J.K. 2009. Tissue concentrations of 4-HNE in the black walnut extract model of laminitis: Indication of oxidant stress in affected laminae. *Vet. Immunol. Immunopathol.* 129(3/4):211-215.
- Zeng M., He W., Li L., Li B., Luo L., Huang X., Guan K. & Chen W. 2015. Ghrelin attenuates sepsis-associated acute lung injury oxidative stress in rats. *Inflammation* 38(2):683-690.