

Efficacy of virginiamycin for the control of periodontal disease in calves¹

Thamiris N.M. Ramos² , Ana Carolina Borsanelli³, Júlia R. Saraiva², Juliana Vaccari², Christiane M. Schweitzer⁴, Elerson Gaetti-Jardim Jr⁵ and Iveraldo S. Dutra^{6*}

ABSTRACT.- Ramos T.N.M., Borsanelli A.C., Saraiva J.R., Vaccari J., Schweitzer C.M., Gaetti-Jardim Jr. E. & Dutra I.S. 2019. **Efficacy of virginiamycin for the control of periodontal disease in calves.** *Pesquisa Veterinária Brasileira* 39(2):112-122. Departamento de Apoio, Produção e Saúde Animal, Faculdade de Medicina Veterinária de Araçatuba, Universidade Estadual Paulista, Rua Clóvis Pestana 793, Cx. Postal 533, Jardim Dona Amélia, Araçatuba, SP 16050-680, Brazil. E-mail: iveraldo.dutra@unesp.br

Periodontal diseases are multifactorial infectious processes caused by complexes of microorganisms, with damage to health, production, and animal welfare. The aim of the present study was to evaluate the efficacy of virginiamycin in the prevention and control of two early forms of periodontal disease: gingivitis and necrotizing gingivitis. Ten weaned calves, aged four to six months, were permanently kept in a single lot under the same rotational grazing regime in a newly reformed area of *Panicum maximum*. Five of the calves were orally administered 340mg of virginiamycin (Virginiamycin Group) daily for a period of 18 weeks, while the remaining five calves (Control Group) remained under the same food management but did not receive virginiamycin. During this period, animals underwent 18 weekly evaluations regarding periodontal health, with monitoring and recording of clinical parameters of the eight deciduous incisor teeth on the labial and lingual faces. At approximately two-week intervals, nine collections of subgingival sulcus material from five sites of the four right incisor teeth of each animal were performed and subjected to microbiological evaluation using polymerase chain reaction with primers of 25 microorganisms considered potentially pathogenic. After 1440 periodontal clinical evaluations of incisor teeth of the 10 calves, a total of 395 episodes of gingivitis were recorded, of which 267 occurred in the Control Group and 128 in the Virginiamycin Group. Similarly, 89 episodes of necrotizing gingivitis were recorded; 58 in the Control Group and 31 in the Virginiamycin Group. Comparison of between-group means found significant differences for teeth with gingivitis and necrotizing gingivitis (t test; $p < 0.05$). The total number of teeth with gingivitis ($p < 0.01$) and necrotizing gingivitis ($p < 0.01$) in Control Group was significantly higher than that of gingivitis ($p < 0.01$) and necrotizing gingivitis ($p < 0.05$) in the Virginiamycin Group. There was a positive correlation between total occurrence of gingivitis and necrotizing gingivitis in the Virginiamycin Group by Pearson's test. Virginiamycin had a protective effect on treated animals compared with the Control Group (OR = 0.36; CI (95%) = 0.27-0.43). In the Control Group, *Actinomyces israelii* (4.74%), domain *Archaea* (1.58%), *Eikenella corrodens* (1.05%), *Fusobacterium nucleatum* (27.37%), class *Mollicutes* (5.26%); *Porphyromonas endodontalis* (5.26%); *Porphyromonas gulae* (0.53%),

¹ Received on August 29, 2018.

Accepted for publication on October on 11, 2018.

² Postgraduate Program in Veterinary Medicine, Faculdade de Ciências Agrárias e Veterinárias, Universidade Estadual Paulista (Unesp), Via de Acesso Professor Paulo Donato Castellane s/n, Jaboticabal, SP 14884-900, Brazil. E-mail: thami.naiasha@gmail.com

³ Postdoctoral in Veterinary Medicine, Departamento de Apoio, Produção e Saúde Animal, Faculdade de Medicina Veterinária de Araçatuba, Universidade Estadual Paulista (Unesp), Campus de Araçatuba, Rua Clóvis Pestana 793, Jardim Dona Amélia, Araçatuba, SP 16050-680. E-mail: carol_borsanelli@yahoo.com.br

⁴ Departamento de Matemática, Faculdade de Engenharia de Ilha Solteira, Universidade Estadual Paulista (Unesp), Alameda Rio de Janeiro 266, Ilha Solteira, SP 15385-000, Brazil. E-mail: chris@mat.feis.unesp.br

⁵ Departamento de Patologia e Propedêutica Clínica, Faculdade de Odontologia de Araçatuba, Universidade Estadual Paulista (Unesp), Rua José Bonifácio 1193, Araçatuba, SP 16015-050. E-mail: gaettijardim@gmail.com

⁶ Departamento de Apoio, Produção e Saúde Animal, Faculdade de Medicina Veterinária de Araçatuba, Universidade Estadual Paulista (Unesp), Campus de Araçatuba, Rua Clóvis Pestana 793, Jardim Dona Amélia, Araçatuba, SP 16050-680. *Corresponding author: iveraldo.dutra@unesp.br

Prevotella buccae (6.32%), *Prevotella loescheii* (3.68%), *Prevotella nigrescens* (8.42%), *Prevotella oralis* (1.58%), *Tannerella forsythia* (0.53%), and *Treponema denticola* (4.21%) were detected at healthy sites, and gingivitis or necrotizing gingivitis samples. In the Virginiamycin Group, *A. israeli* (3.41%), domain *Archaea* (0.98%), *F. nucleatum* (9.27%), class *Mollicutes* (4.39%), *P. endodontalis* (4.39%), *P. gulae* (0.49%), *P. buccae* (8.29%), *P. loescheii* (6.83%), *P. nigrescens* (15.61%), *P. oralis* (1.46%), *Selenomonas sputigena* (0.49%), *T. forsythia* (0.49%), and *T. denticola* (2.44%) were detected. In conclusion, virginiamycin administered at a dosage of 340mg/animal/day significantly reduced the occurrence of gingivitis and necrotizing gingivitis in cattle maintained on reformed pastures, and was revealed to have action against periodontal bacterial microbiota considered to be potentially pathogenic.

INDEX TERMS: Virginiamycin, control, periodontal disease, gingivitis, necrotizing gingivitis, ruminants, cattle, microbiology, clinics.

RESUMO.- [Eficácia da virginiamicina no controle de doença periodontal em bezerros.]

As doenças periodontais são processos infecciosos multifatoriais causados por complexos de micro-organismos, que provocam danos à saúde, produção e ao bem-estar animal. O objetivo do presente estudo foi o de avaliar a eficácia da virginiamicina na prevenção e controle de duas formas de doença periodontal; a gengivite e a gengivite necrosante. Assim, dez bezerros desmamados, com idade entre 4 e 6 meses, foram mantidos permanentemente em lote único e sob o mesmo regime de pastejo rotacionado em área reformada de *Panicum maximum*. Cinco bezerros receberam via oral 340mg de virginiamicina (Grupo Virginiamicina) diariamente, por um período de dezoito semanas, enquanto o Grupo Controle permaneceu sob o mesmo manejo alimentar, mas sem receber a virginiamicina. No período, os animais passaram por 18 avaliações semanais quanto à saúde periodontal, com monitoramento e registro dos parâmetros clínicos dos oito dentes incisivos decíduos, nas suas faces labial e lingual. Em intervalos aproximadamente quinzenais foram realizadas nove coletas de material do sulco subgengival de cinco sítios de quatro dentes incisivos direitos de cada animal para avaliação microbiológica, com o emprego da reação em cadeia da polimerase e com iniciadores de 25 micro-organismos considerados potencialmente patogênicos. Ao final das 1440 avaliações clínicas periodontais dos dentes incisivos dos dez bezerros, pôde-se registrar um total de 395 episódios de dentes com gengivite, nos quais 267 foram registrados no Grupo Controle e 128 no Grupo Virginiamicina. De forma semelhante, do total de 89 registros de gengivite necrosante, 58 foram no Grupo Controle e 31 no Grupo Virginiamicina. Na comparação entre médias dos grupos as diferenças encontradas para dentes com gengivite e gengivite necrosante foram significativas pelo teste t ($p < 0,05$). Assim, o total de dentes com gengivite ($p < 0,01$) e gengivite necrosante ($p < 0,01$) no Grupo Controle, foi significativamente superior ao de gengivite ($p < 0,01$) e gengivite necrosante ($p < 0,05$) do Grupo Virginiamicina. Houve correlação positiva entre o total de ocorrência de gengivite e gengivite necrosante no Grupo Virginiamicina pelo teste de Pearson. A virginiamicina possuiu um efeito protetor nos animais tratados em comparação com o controle (OR = 0,36; IC (95%) = 0,27-0,43). Na avaliação microbiológica do Grupo Controle foram detectados nas amostras de sítios sadios, com gengivite ou com gengivite necrosante *Actinomyces israeli* (4,74%), domínio *Archaea* (1,58%), *Eikenella corrodens* (1,05%), *Fusobacterium nucleatum* (27,37%), classe *Mollicutes* (5,26%), *Porphyromonas endodontalis* (5,26%), *Porphyromonas gulae* (0,53%), *Prevotella buccae* (6,32%), *Prevotella loescheii* (3,68%),

Prevotella nigrescens (8,42%), *Prevotella oralis* (1,58%), *Tannerella forsythia* (0,53%) e *Treponema denticola* (4,21%). Enquanto no Grupo Virginiamicina foram detectados: *A. israeli* (3,41%), domínio *Archaea* (0,98%), *F. nucleatum* (9,27%), classe *Mollicutes* (4,39%), *P. endodontalis* (4,39%), *P. gulae* (0,49%), *P. buccae* (8,29%), *P. loescheii* (6,83%), *P. nigrescens* (15,61%), *P. oralis* (1,46%), *Selenomonas sputigena* (0,49%), *T. forsythia* (0,49%) e *T. denticola* (2,44%). Em conclusão, a virginiamicina administrada na dosagem de 340mg/animal/dia reduziu significativamente a ocorrência da gengivite e gengivite necrosante em bovinos mantidos em pastos reformados e revelou ter ação frente à microbiota bacteriana periodontal considerada potencialmente patogênica.

TERMOS DE INDEXAÇÃO: Virginiamicina, controle, doença periodontal, gengivite, gengivite necrosante, ruminantes, bovinos, microbiologia, clínica.

INTRODUCTION

Periodontal diseases are a group of diseases that affect the tissues associated with protection and support of teeth. Among the reversible forms of periodontal disease are gingivitis and necrotizing gingivitis, which are caused predominantly by aggression of gingival biofilm (Konradsson et al. 2007, Kistler et al. 2013).

Untreated gingivitis can progress to periodontitis, with consequent compromise of periodontal ligaments and alveolar bone, culminating in tooth loss (Page 1986, Lyon 2005, Kinane & Bartold 2007, Herrera et al. 2014). This way, the health of the periodontium depends on the balance between bacterial composition of dental biofilm and its interaction with the host immune system (Hajishengallis 2015).

In cattle, gingivitis has been reported in calves aged 5 to 60 days old, characterized as a physiological manifestation resulting from eruption of teeth (Döbereiner et al. 1974). Additionally, necrotizing gingivitis has been described in cattle with leukocyte adhesion deficiency (Nagahata et al. 1993). However, in this animal species, little is known about gum diseases, most likely due to the difficulties in evaluating the oral cavity of the animals and by the fact that these diseases do not present evident clinical changes as seen in periodontitis. However, in humans and adolescents, these diseases have been well described (Kiran et al. 2011, Marshall et al. 2014).

In cases of gingivitis, the gingival border is noted to be intensely red and edematous, and bleeding, either spontaneous or with probing, may be observed and in more severe

cases, the gingiva may have ulcerations (Diehl & Rosychuk 1993, Lyon 2005, Riggio et al. 2011, Newman et al. 2012, Antiabong et al. 2013, Kutasi et al. 2016). In cases of necrotizing gingivitis, spontaneous bleeding or bleeding after probing as well as the presence of a layer of yellowish-white or grayish-white fibrin on the necrotic gingival border may be observed (Klokkevold 2012, Rodríguez-Pulido et al. 2016).

Periodontal diseases occur by the modification of the microbiota and constituents of the oral cavity; in humans, several modifying factors have been associated with the occurrence of gingivitis and necrotizing gingivitis, including hormonal changes and immunodeficiencies (Stamm 1986, Rowland 1999, Dufty et al. 2016). However, in cattle, modifying factors associated with the occurrence of periodontal diseases are unknown and the suspicions are related to soil management and diet (Dutra et al. 1993, Döbereiner et al. 2000).

In a recent study, oral microbiomes of healthy cattle and those with periodontitis revealed 72.1% dissimilarity; however, the diversity of bacteria found in healthy and diseased sites was similar, with a predominance of the genera *Prevotella*, *Fusobacterium*, and *Porphyromonas* in periodontal lesions (Borsanelli et al. 2018). Thereby, it can be evidenced that bovine oral microbiota is rich and diversified, composed of 395 genera or higher taxa and that microorganisms considered as potential periodontal pathogens are associated with the occurrence of periodontitis in these animals. These include several species of *Porphyromonas*, *Prevotella*, and *Treponema*, as well as *Fusobacterium nucleatum*, *Fusobacterium necrophorum*, and *Actinomyces naeslundii* (Dutra et al. 2000, Borsanelli et al. 2015a, 2015b, Borsanelli 2017).

In previous studies, virginiamycin has been shown to be efficient for recovery of calves with periodontitis (Tims et al. 1992), as well as periodontitis prevention (Dutra et al. 1993). In this context, the present study aimed to evaluate the efficacy of virginiamycin for the control of gingivitis and necrotizing gingivitis in cattle, in view of the need to develop strategies for the control of periodontal diseases in production animals and characteristics of the antibiotic.

MATERIALS AND METHODS

Animals. Ten male Jersey or Jersey cross calves, weaned and healthy, aged four to six months, were used. They were weighed and randomized into two groups of five animals each. The animals remained under rotational grazing and even single-plot zootechnical management in 24 paddocks (approximately 3 hectares) that had previously been reformed in order to simulate the potential representative situation for the occurrence of periodontal disease in cattle. Mixed pastures of Massai grasses (*Panicum maximum* cv. Massai) and Mombasa (*Panicum maximum* cv. Mombasa) were reformed following conventional farming practices such as soil analysis, liming, and fertilization. Water and mineral salt were supplied *ad libitum* over the total period of approximately 24 weeks of experimentation, including adaptation of the animals to the diet. Five animals (Virginiamycin Group) received daily, oral (*pour dressing*) administration of virginiamycin (340mg/day/animal) for 18 consecutive weeks while the other five (Control Group) did not receive the antibiotic.

General and periodontal clinical evaluation. At the beginning of the experiment, the animals had good body condition scores for their age and were apparently healthy. In the initial oral cavity clinical examination, they had deciduous dentition, with dental units (tooth and periodontium) normal. Weekly periodontal clinical evaluation of

the incisor teeth was performed for 18 consecutive weeks, starting after four weeks of diet adaptation and management and coinciding with virginiamycin administration. For the examination, the calves were physically restrained in the trunk, and periodontal status was evaluated with the aid of a mouth opener and flashlight and recorded in individual odontograms. Although the visible clinical condition of the dental arch of the animals was examined, only the lingual and labial faces of the incisor teeth were evaluated in the present study, avoiding any means of chemical containment that could interfere in the objective of the research. The criteria for periodontal clinical examination were based on those used by Loe (1967). Gingivitis was characterized by presence of edema in the gingival border, appearance, color, spontaneous bleeding or bleeding associated with probing. For cases of necrotizing gingivitis, we sought to visualize the presence of ulcerations in the gingival margin, with or without the presence of a white-grayish/yellowish-white pseudomembrane and manipulation pain.

Collection of material for microbiological examinations.

Samples were collected every two weeks throughout the study. After removal of food residues, drying of saliva, and removal of supragingival biofilm with sterile gauze, biofilm was collected from the gingival sulcus of four incisors, of the following teeth: 401 on the labial and lingual face, 402, 403, and 404. Materials from curettage (Gracey curette) or paper cone were packed into cryotubes with ultrapure water and stored at -80°C until DNA extraction.

Extraction of microbial DNA. Each sample for bacterial DNA detection in sterile ultrapure water was extracted by boiling. First, the sample was homogenized for 20 seconds; 500µl aliquots were then removed and stored in Eppendorf tubes. The samples were then boiled for 15 minutes, centrifuged at 10.36×g for 5 minutes and aliquots of 400µl. The samples were then stored at -80°C until the amplification reaction of the DNA was carried out by the polymerase chain reaction (PCR).

Detection of microorganisms by conventional PCR. Specific primers and amplification conditions were employed for the main microbial groups associated with oral biofilm gingivitis and necrotizing gingivitis in cattle and in other animal species: *Actinomyces israelii*, *Actinomyces naeslundii*, *Archaea* domain, *Eikenella corrodens*, *Campylobacter* spp., *Fusobacterium nucleatum*, *Fusobacterium necrophorum*, class *Mollicutes*, *Parvimonas micra*, *Porphyromonas asaccharolytica*, *Porphyromonas endodontalis*, *Porphyromonas gingivalis*, *Porphyromonas gulae*, *Prevotella buccae*, *Prevotella loescheii*, *Prevotella intermedia*, *Prevotella melaninogenica*, *Prevotella nigrescens*, *Prevotella oralis*, *Selenomonas sputigena*, *Tannerella forsythia*, *Treponema amylovorum*, *Treponema denticola*, *Treponema maltophilum*, and *Treponema pectinovorum* (Ashimoto et al. 1996, Tran et al. 1997, Willis et al. 1999, Fouad et al. 2002, Mayanagi et al. 2004, Hardham et al. 2005, Yoshida et al. 2005, Stevenson et al. 2007, Aroutcheva et al. 2008, Gaetti-Jardim Junior et al. 2012, Nadkarni et al. 2012, Xia & Baumgartner 2003, Cogulu et al. 2008, Lopes Neto 2007). The specificity of these primers is demonstrated in the above-mentioned literature and can be evaluated through the National Center for Biotechnology Information databases (NCBI).

Amplifications of target DNA by PCR were performed in 25µl volumes containing 1X PCR / Mg + 2 buffer (Boehring Mannheim, Indianapolis, IN, USA), 0.2µl of each dNTP (Pharmacia Biotech, Piscataway, NJ, USA), 0.5U Taq DNA polymerase (Invitrogen do Brasil, São Paulo/SP, Brazil), 0.4µl of each primer pair (Invitrogen), and 10ng template. The amplifications were performed in a thermocycler (Perkin Elmer, GeneAmp PCR System 9700, Norwalk/CT, USA) programmed at 94°C (5 minutes), 30 to 40 cycles at 94°C (30 to 60 seconds,

according to the primers used), specific annealing temperature for each primer pair, 72°C (30 to 60 seconds), followed by a 5 minute period at 72°C for the final extension of the amplified DNA strands. The PCR amplification products were subjected to agarose gel electrophoresis in 1% TBE buffer (1M Tris, 0.9M boric acid, 0.01M EDTA, pH 8.4), stained with ethidium bromide (0.5mg/ml) and photographed in ultraviolet light transilluminator (UV Light Transilluminator; Eastman Kodak Co., NY, USA).

DNA samples of reference strains were used for control of detection procedures, as well as clinical samples positive for the target microorganisms (Gaetti-Jardim Junior et al. 2012). Ultrapure water was used as a negative control.

Statistical analysis. The means of the cases with gingivitis and necrotizing gingivitis were compared between the Virginiamycin Group and the Control Group using Student's t test and Pearson's test, with a significance level of $p < 0.05$. For the statistics regarding the detection of microorganisms, a comparison was made between the dichotomous variables, in which the presence of microorganisms between the Virginiamycin and Control Groups was compared; the correlation between the microorganisms, and their relation to sites with periodontal or healthy lesions, was evaluated using the chi-Square test of maximum-likelihood, with a significance level of $p < 0.05$. Odds ratios (OR) and confidence intervals (CI) for the OR were calculated to verify whether the use of virginiamycin would be a protective factor against gingivitis and necrotizing gingivitis.

Research ethics commission. The experiment was approved by the Ethics Committee on Animal Use (CEUA) of the Faculty of Agrarian and Veterinary Sciences - Unesp, Campus Jaboticabal/SP (Process FCAV/Unesp No. 15.207/16).

RESULTS

At the end of 18 weeks, the animals that did not receive virginiamycin had unsatisfactory body condition scores. Furthermore, at different moments of the study, the control animals presented symptoms of diarrhea and nasal secretion, and showed an apparent increase in susceptibility to intercurrent diseases such as endoparasitoses. In contrast, among the five animals in the Virginiamycin Group, only one had episodes of diarrhea. The mean weight of calves receiving virginiamycin (188.2kg) was significantly higher ($p = 0.02$) than that observed in the Control Group (123.5kg).

Periodontal evaluation of incisor teeth of the calves in the Control and Virginiamycin Groups kept in a single lot, under rotational grazing in a newly reformed area and even feeding management, revealed episodes of gingivitis and same necrotizing gingivitis, initial forms for progression of periodontitis in the animals of the two experimental groups.

During the study period, according to the weekly clinical examination of the eight deciduous teeth (labial and lingual faces), 395 episodes of teeth (dental unit) with gingivitis were recorded in the 1440 evaluations performed. Of these episodes, 267 occurred in Control Group calves and 128 in the Virginiamycin Group (Fig.1). In the same evaluation, of a total of 89 records of teeth with necrotizing gingivitis, 58 occurred in the Control Group and 31 in the Virginiamycin Group (Fig.2). The clinical manifestations of gingivitis included changes in the color of the gingival mucosa, ranging from moderate to severe red, edema, and bleeding (spontaneous or with probing). In necrotizing gingivitis, the marginal gingival epithelium presented necrotic ulcerations or epithelial areas covered

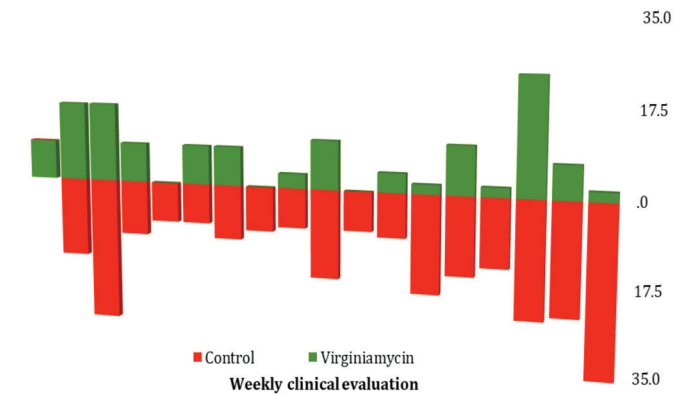


Fig.1. Number of deciduous teeth with gingivitis in calves in the Virginiamycin Group (n=5) and Control Group (n=5) after 18 evaluations in 4 and a half months, totaling 1440 evaluations and 395 episodes of gingivitis. The Virginiamycin Group had 128 episodes of gingivitis, while the Control Group presented 267 episodes. This difference was statistically significant ($p < 0.01$).

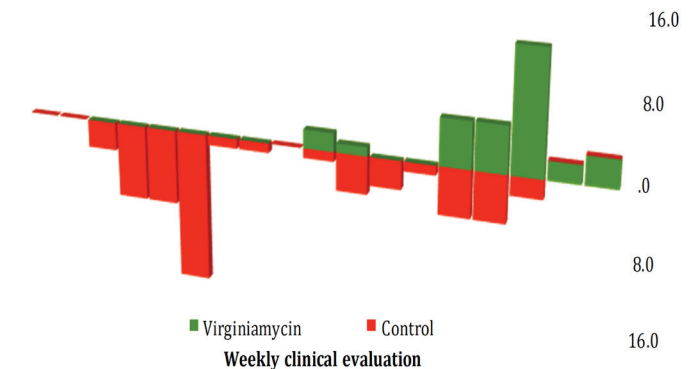


Fig.2. Number of deciduous incisor teeth with necrotizing gingivitis in calves in the Virginiamycin Group (n=5) and Control Group (n=5) after 18 clinical evaluations in 4 and a half months, totaling 1440 evaluations and 89 episodes of necrotizing gingivitis. The Virginiamycin Group had 31 episodes while the Control Group had 58 episodes. This difference was statistically significant ($P < 0.05$).

with a white-gray/yellowish-white membranous layer, and bleeding (spontaneous or with probing) (Fig.3 and Fig.4).

In the comparison of the means of the experimental groups, the differences found for teeth (dental unit) with gingivitis and necrotizing gingivitis were significant according to the t test ($p < 0.05$). Thus, the total number of teeth with gingivitis ($p < 0.01$) and necrotizing gingivitis ($p < 0.01$) in the Control Group was significantly higher than the total number of gingivitis ($p < 0.01$) and necrotizing gingivitis ($p < 0.05$) in the Virginiamycin Group. There was a positive correlation between the total occurrence of gingivitis and necrotizing gingivitis in the Virginiamycin Group according to Pearson's test. Virginiamycin was considered a protective factor against the development of gingivitis and necrotizing gingivitis (OR = 0.36; CI (95%) = 0.27-0.43).

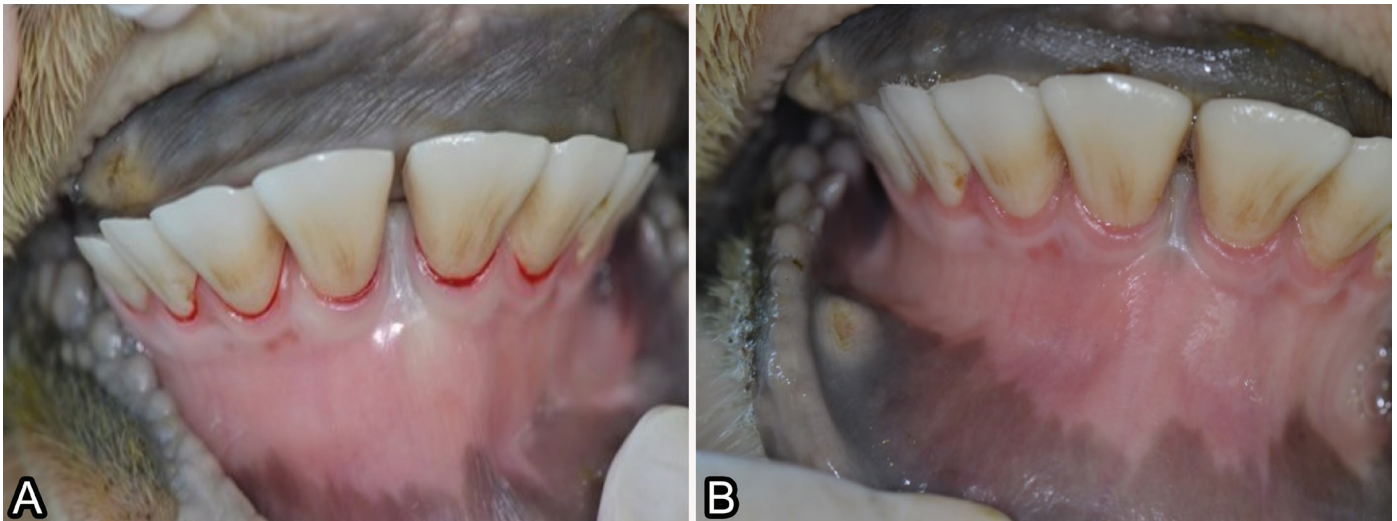


Fig.3. (A,B) Incisor teeth of calves with gingivitis, showing edema in the gingival margin of the first, second and third incisors, alteration of coloration in the second and third incisors, as well as (A) bleeding in first, second and third incisors after probing.

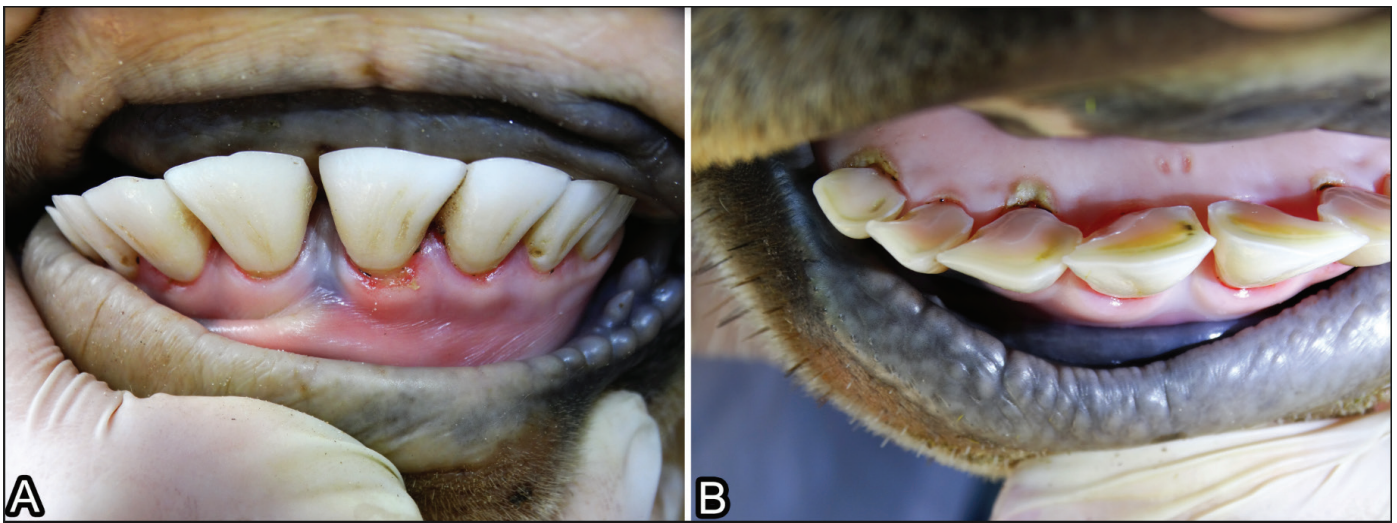

Fig.4. (A) Gingival edge ulceration on tooth 301 compatible with clinical signs of necrotizing gingivitis. (B) Deciduous incisor teeth of calves presenting necrotizing gingivitis on tooth 402 and 404 right on the lingual surface.

In the microbiological evaluation, 395 samples were evaluated by PCR (Table 1) to detect the presence of 25 microorganisms considered indicators and with pathogenic potential. The sites with the lowest number of microorganisms detected were those associated with necrotizing gingivitis (Table 2 and 3). The amount of microorganism samples at the different sites collected differed among the animals and between the groups (Fig.5). In addition, there was a difference in the types of microorganisms detected between the sample collections.

Fusobacterium nucleatum, class *Mollicutes*, *Porphyromonas endodontalis*, *Prevotella loescheii*, *Prevotella nigrescens*, *Prevotella oralis*, and *Treponema denticola* were detected in five or more collections, whereas *Actinomyces israelii*, *Archaea* domain, *Eikenella corrodens*, *Porphyromonas gulae*, *Tannerella forsythia*, and *Selenomonas sputigena* were rarer. *Prevotella buccae* was detected in all collections. *Actinomyces*

naeslundii, *Campylobacter* spp., *Fusobacterium necrophorum*, *Parvimonas micra*, *Porphyromonas assacharolytica*, *P. gingivalis*, *Prevotella intermedia*, *P. melaninogenica*, *Treponema amylovorum*, *T. maltophilum*, and *T. pectinovorum* were not identified in either of the two groups. *S. sputigena* was negative in the Control Group animals and *E. corrodens* was negative in the Virginiamycin Group.

In the analysis of the variables using the chi-square test of maximum-likelihood, there was a significant difference in the frequency of detected microorganisms ($p < 0.05$). The presence of *Fusobacterium nucleatum* ($p < 0.01$) was more significant in Control Group, while *Prevotella nigrescens* ($p < 0.04$) and other bacteria of the genus *Prevotella* ($p < 0.02$) was more frequent in the Virginiamycin Group. *Prevotella loescheii* showed association with *Prevotella buccae* ($p < 0.01$) and *P. nigrescens* ($p < 0.01$); *P. buccae* was associated with *P. nigrescens* ($p < 0.01$) and

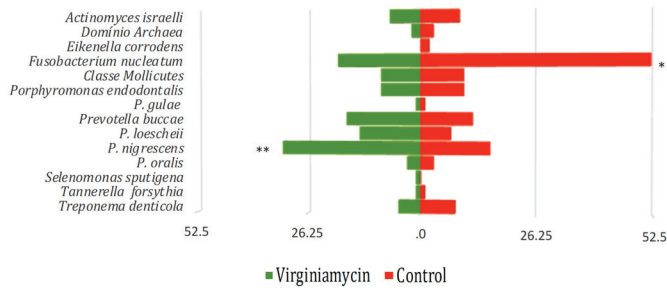


Fig.5. Number of microorganisms detected in the 395 samples collected from four deciduous teeth of each animal from the Virginiamycin Group (n=5) and Control Group (n=5). * P<0.01, ** P<0.05.

Table 1. Microorganisms detected by polymerase chain reaction (PCR) in the samples of 395 subgingival sulcus sites of 10 calves of groups Control (n=190) and Virginiamycin (n=205)

Microorganism	Control group	Virginiamycin group	P
	N(%)	N(%)	
<i>Actinomyces israelii</i>	9 (4.7)	7 (3.4)	
Archaea domain	3 (1.6)	2 (1.0)	
<i>Eikenella corrodens</i>	2 (1.1)	0 (0.0)	
<i>Fusobacterium nucleatum</i>	52 (27.4)	19 (9.3)	<0.01*
Mollicutes class	10 (5.3)	9 (4.4)	
<i>Porphyromonas endodontalis</i>	10 (5.3)	9 (4.4)	
<i>P. gulae</i>	1 (0.5)	1 (0.5)	
<i>Prevotella buccae</i>	12 (6.3)	17 (8.3)	
<i>P. loescheii</i>	7 (3.7)	14 (6.8)	
<i>P. nigrescens</i>	16 (8.4)	32 (15.6)	<0.05*
<i>P. oralis</i>	3 (1.6)	3 (1.5)	
<i>Selenomonas sputigena</i>	0 (0.0)	1 (0.5)	
<i>Tannerella forsythia</i>	1 (0.5)	1 (0.5)	
<i>Treponema denticola</i>	8 (4.2)	5 (2.4)	

*Significant values of P by the Chi-square test of M-L.

Table 2. Microorganisms identified by PCR in four incisor healthy teeth (n=119) with gingivitis (n=63) or necrotizing gingivitis (n=8) of five calves in the Control Group

Microorganism	Healthy	Gingivitis	Necrotizing gingivitis
	N(%)	N(%)	N(%)
<i>Actinomyces israelii</i>	6 (5.0)	3 (4.8)	0 (0.0)
Archaea domain	3 (2.5)	0 (0.0)	0 (0.0)
<i>Eikenella corrodens</i>	1 (1.0)	1 (1.6)	0 (0.0)
<i>Fusobacterium nucleatum</i>	31 (26.1)	19 (30.2)	2 (25.0)
Mollicutes class	6 (5.0)	4 (6.4)	0 (0.0)
<i>Porphyromonas endodontalis</i>	9 (7.6)	1 (1.6)	0 (0.0)
<i>P. gulae</i>	1 (1.0)	0 (0.0)	0 (0.0)
<i>Prevotella buccae</i>	8 (6.7)	3 (4.8)	1 (12.5)
<i>P. loescheii</i>	4 (3.4)	1 (1.6)	2 (25.0)
<i>P. nigrescens</i>	13 (11.0)	1 (1.6)	2 (25.0)
<i>P. oralis</i>	1 (1.0)	2 (3.2)	0 (0.0)
<i>Tannerella forsythia</i>	0 (0.0)	1 (1.6)	0 (0.0)
<i>Treponema denticola</i>	4 (3.4)	4 (6.4)	0 (0.0)

Table 3. Microorganisms identified by PCR in samples of four healthy incisor teeth (n=156), with gingivitis (n=42) or necrotizing gingivitis (n=7) of five calves of the Virginiamycin Group

Microorganisms	Healthy	Gingivitis	Necrotizing gingivitis
	N(%)	N(%)	N(%)
<i>Actinomyces israelii</i>	5 (3.2)	2 (4.8)	0 (0.0)
Archaea domain	1 (0.6)	0 (0.0)	1 (14.3)
<i>Fusobacterium nucleatum</i>	14 (8.9)	5 (12.0)	0 (0.0)
Mollicutes class	4 (2.6)	4 (9.5)	1 (14.3)
<i>Porphyromonas endodontalis</i>	6 (3.8)	3 (7.1)	0 (0.0)
<i>P. gulae</i>	0 (0.0)	1 (2.4)	0 (0.0)
<i>Prevotella buccae</i>	15 (9.6)	2 (4.8)	0 (0.0)
<i>P. loescheii</i>	13 (8.3)	1 (2.4)	0 (0.0)
<i>P. nigrescens</i>	25 (16.03)	7 (16.7)	0 (0.0)
<i>P. oralis</i>	3 (1.9)	0 (0.0)	0 (0.0)
<i>Selenomonas sputigena</i>	1 (0.6)	0 (0.0)	0 (0.0)
<i>Tannerella forsythia</i>	1 (0.6)	0 (0.0)	0 (0.0)
<i>Treponema denticola</i>	5 (3.2)	0 (0.0)	0 (0.0)

Archaea domain (p<0.04). Likewise, there was an association between the frequency of *P. nigrescens* and *Actinomyces israelii* (p<0.04), *E. corrodens* (p<0.01), and Mollicutes class (p<0.03); while *A. israelii* also showed association with Mollicutes class (p<0.04). Concerning the association of microorganisms with clinical signs, only *Prevotella oralis* had a level of significance with gingivitis (p<0.02).

DISCUSSION

The occurrence of gingivitis and necrotizing gingivitis in cattle kept on reformed pastures is an original description in the literature about this important complex of diseases of ruminant's oral cavity. In fact, although gingivitis and necrotizing gingivitis are precursors of necrotizing periodontitis and periodontitis, their description in farm animals is rare. In general, existing studies deal with the final event (periodontitis) that is possible to be evaluated by extensive periodontal lesions such as gingival recession, clinical loss of insertion level, and damage to animal health and welfare (Döbereiner et al. 2000, 2004, Borsanelli 2017). In this context, the present longitudinal study and clinical monitoring of deciduous teeth of calves has enabled an unprecedented documentation of a natural occurrence, in successive episodes followed by remission, of two precursor forms of periodontitis. No less important, results of virginiamycin use in periodontal disease control in a longitudinal study with clinical monitoring of the gingival condition of the incisor teeth for four consecutive months and the presence of microorganisms indicative of potentially pathogenic microbiota are also unprecedented.

Progression of gingivitis in periodontitis is associated with individual, environmental, and etiological factors (Lang et al. 2009). It is known that pasture reform, through liming and fertilization, can favor the occurrence of bovine periodontitis in previously endemic areas (Dutra et al. 2000). However, it is unknown whether this frequent association is valid for all periodontal diseases; it should be added that

retrospective analysis makes it impossible to retrieve this information in areas that have been open for at least 50 years, as was the case in the present study. According to the initial purposes of the study, the retention of calves under the same diet, in a reformed pasture and in a single management batch, made it possible to simulate an epidemiological condition associated with naturally occurring periodontitis and in a supposedly uniform challenge in which the probable environmental trigger would be present. Although the occurrence of periodontitis was not clinically observed in the 1440 evaluations performed over the 18-week period, the finding of 395 episodes of gingivitis and 89 episodes of necrotizing gingivitis is unprecedented and of great significance in studies of periodontal diseases. During this period of observation, the episodes of either disease were not constant or progressive, as they are acute inflammatory diseases that are characterized by discontinuous outbreaks and are mostly transient in the affected individuals (Page 1986).

Under the present experimental conditions, it could be noted the succession of episodes and remission of gingivitis and necrotizing gingivitis in incisor teeth, loss of body condition in animals that did not receive virginiamycin and the untreated animals had a higher frequency of diarrhea and other diseases. In this context, it is possible to associate the general clinical condition of untreated animals with the frequency of the occurrence of gingival diseases. This is corroborated with the OR, which indicated that treatment with virginiamycin was associated with a favorable reduction in the occurrence of gingivitis and necrotizing gingivitis.

Virginiamycin is a streptogramin marketed as a growth promoter at a dose of 340mg/head/day, according to Brazilian legislation (Brasil 2003). The product acts on ruminal bacteria sensitive to this class, allowing a better rumen feeding (Araújo et al. 2016). In the present study, the use of virginiamycin at this same dosage for one of the groups probably contributed to improvement of the periodontal condition, favoring prehension, chewing, rumination, and improvement in animal performance in addition to promoting weight gain.

According to Holmstrup & Westergaard (2008), individuals with successive episodes of gingivitis are more susceptible to the development of necrotizing gingivitis; this is a very common clinical condition in children and causes severe pain in the oral cavity. Necrotizing gingivitis is associated with individuals with immunodeficiency (Williams et al. 1990), and in Holstein cows with a genetic defect in leukocyte adhesion activity (Nagahata et al. 1993). In the present study, it was observed that the animals with several episodes of gingivitis presented episodes of necrotizing gingivitis later (Fig.1 and Fig.2), consistent with the aforementioned information. As this was not the main objective of the study, it is not possible to associate necrotizing gingivitis with any changes in immunological factors of the two groups of animals.

The presence of altered color, edema, and bleeding, both spontaneously and with gingival sulcus examination, observed in animals with gingivitis in both groups, parallels observations of gingivitis in small animals (Gorrel et al. 2008). Sheep with necrotizing gingivitis present necrotic ulcerations covered by a pseudomembrane (Salisbury et al. 1953), similar to what was observed in the present study.

It is worth noting that the succession of episodes of these two forms of periodontal disease precursors in cattle is paralleled throughout the literature with respect to this group of diseases in humans and other animals (Kinane & Bartold 2007, Marshall et al. 2014). In an objective and conclusive manner, it is possible to attribute a lower frequency of episodes of these two periodontal diseases in calves treated with virginiamycin. The difference between the two experimental groups was significant, with significant benefit to the group that ingested 340mg of virginiamycin daily for the study period. Tims et al. (1992) previously reported the effect of the antibiotic on the recovery of animals with the aggressive form of periodontitis even when they continued under the same epidemiological condition that triggered the outbreak of the disease.

As multifactorial infectious diseases, periodontal diseases are non-linear processes, external to the organism but associated with the bacterial biofilm adhered to the tooth and planktonic microbiota (Socransky & Haffajee 2005, Borsanelli et al. 2018). In this approach, the action of virginiamycin probably has been in the promotion of bacterial homeostasis favorable to the maintenance of periodontal health or in the prevention of dysbiosis, which causes the onset of periodontal diseases.

In periodontal diseases, gingival biofilm plays an essential role in its etiology (Löe 1994). In the calves included in the present study, there was practically no biofilm accumulation or dental calculus visible in the incisors.

A widely evidenced concept in the literature is that each tooth can have its own microbial complex, which, when analyzed, show differences in their constitution among teeth, such as supragingival and in the constitution and formation of the subgingival biofilm (Haffajee et al. 2009, Teles et al. 2012). The importance of conducting research at different collection sites, in other words, in each subgingival groove of the labial incisor teeth, was evident when analyzing the frequency and presence of these microorganisms (Table 1-3). In the comparisons between the collections and in the collections by animals, it was observed that a microorganism detected at one site would not necessarily be detected elsewhere, indicating that each one may have a specific biofilm at the time of collection.

In cattle with periodontitis, the disease does not occur without the presence of certain microorganisms that are considered normal constituents of the oral microbiota (Dutra & Döbereiner 2001, Borsanelli et al. 2018). Thus, in animals with gingivitis and necrotizing gingivitis, *A. israeli*, *E. corrodens*, *F. nucleatum*, *P. buccae*, *P. loescheii*, *P. nigrescens*, *P. oralis*, *P. endodontalis*, *T. forsythia*, and *T. denticola* were detected, which were also previously identified in healthy or in periodontal pockets in cattle (Borsanelli 2017). It is interesting to note that the role of bacteria in periodontal infections must meet Socransky's postulate, since they are not conventional exogenous infectious diseases, but diseases of an endogenous nature, associated with the microbial biofilm, so that the interaction between the different taxa is important for the development of these diseases (Socransky & Haffajee 2010). In this sense, a statistical correlation of co-occurrence was observed between the different members of the genus *Prevotella*, which are part of the so-called "orange complex", associated with the first manifestations of inflammatory

periodontal diseases, in both gingivitis and necrotizing gingivitis (Socransky et al. 1998, Larsen & Fiehn 2017).

Porphyromonas spp., *Tannerella* spp., *Campylobacter* spp., *Eikenella* spp., *Parvimonas* spp., *Treponema* spp., and *Selenomonas* spp. were detected in monkeys with gingivitis, but in greater quantity in monkeys with periodontitis and periodontal abscesses (Gaetti-Jardim Junior et al. 2012). Thus, the use of amplification of the target DNA by conventional PCR in the present study made it possible to detect several microorganisms considered potentially pathogenic. However, it is a qualitative test, which requires caution in interpreting the results, especially in the face of endogenous disease or dysbiosis. On the other hand, Gram-positive bacteria, and some Gram-negative bacteria such as *F. nucleatum* and spirochetes, detected in sites with gingivitis and necrotizing gingivitis, can be associated as agents involved in the progression of these diseases in cattle. This is similar to observations in humans with these diseases (Harvey 2017).

In the present study, there was a trend in the frequency of occurrence of microorganisms detected in necrotizing gingivitis. In the Control Group, *F. nucleatum*, *P. buccae*, *P. loeschei*, and *P. nigrescens* were detected, while in the Virginiamycin Group, the *Archaea* domain and *Mollicutes* classes were observed. In the samples of animals with necrotizing gingivitis, no spirochetes of the genus *Treponema* were detected, which diverges from studies in humans, in which this genus has a recognized role (Herrera et al. 2014). *T. denticola* was identified in samples from healthy or gingivitis sites, similar to that observed in the oral microbiota of healthy adult bovines (Borsanelli 2017).

In ruminants and other animals it is known that *Porphyromonas* spp. is present in the periodontal pockets of animals with periodontitis (Senhorinho et al. 2011, Borsanelli et al. 2015b, Agostinho 2017, Campello 2017). Based on the results of the present study, it can be stated that besides being related to periodontitis, *P. endodontalis* and *P. gulae* are present in samples from healthy calves and calves with gingivitis.

Mollicutes class and *Archaea* domain, in humans and animals, are present in healthy patients with gingivitis, necrotizing gingivitis, or periodontitis (Yamabe et al. 2008, Faveri et al. 2011, Griffen et al. 2012, Chen et al. 2015, Harris et al. 2015). In cattle with periodontitis, *Mollicutes* class is more often associated with the disease (Borsanelli et al. 2018). In the calves in the present study, class *Mollicutes* was detected in sites with gingivitis and necrotizing gingivitis, and it can be noted that this microorganism was present in the different phases of periodontal diseases. *Archaea* domain to date has not been reported in this species; this is the first study to detect *Archaea* domain in healthy sites of both groups and in calves with necrotizing gingivitis that ingested virginiamycin. This difference indicates that the promoter leads to dysbiosis, favoring the growth of these microorganisms.

Prevotella nigrescens is associated with the development of necrotizing gingivitis and periodontitis in humans (Loesche et al. 1985, Stingu et al. 2013) and was also identified in healthy sites and periodontal pockets of bovines (Borsanelli et al. 2015a). In the present study, the frequency of *P. nigrescens* was significant, being detected in greater number in treated animals. This genus has evidence of resistance to this class of streptogramin, which would explain the higher number of positive samples in the group that took the antibiotic (Chung et al. 2002). Another factor that makes the detection of the genus *Prevotella* important in this work

is due to the greater number of samples detected at the same time as the increase of cases of necrotizing gingivitis in the Virginiamycin Group, suggesting that in the treated animals this bacterium possibly has some function in evolution of necrotizing gingivitis.

Among the microorganisms associated with gingivitis, *F. nucleatum* presents great importance, since it is one of the organisms responsible for the inflammatory process, the beginning of the development of periodontitis, and the recruitment of other periodontopathogens. Although *F. nucleatum* is commonly found in microbiological studies of periodontal diseases, it is also detected in healthy periodontal sites, as well as in sites with gingivitis and periodontitis in humans and animals (Kolenbrander 2000, Kolenbrander et al. 2002, Senhorinho et al. 2011, Signat et al. 2011, Harris et al. 2015). Species of *Fusobacterium* genus are susceptible to the action of virginiamycin (Araújo et al. 2016), which is related to the results of this present study, in which the highest number of positive samples were in the Control Group (Fig.3 and Fig.4). Consistent with these events, more episodes of gingivitis and necrotizing gingivitis were observed in the Control Group animals.

Antibiotic treatment causes changes in the structure of the microbial community (Antiabong et al. 2013), which reflects the condition between health and disease. In the calves, it was possible to visualize the difference caused by the treatment between the groups and the presence of certain microorganisms in the analyzed sites. This is consistent with observations of the bacterial composition of humans with periodontitis treated with amoxicillin and metronidazole, in which individuals with a good response to treatment had reduced periodontopathogens such as *P. endodontalis*, *Prevotella* spp., and *Fusobacterium* spp. (Colombo et al. 2012).

In a previous study, Tims et al. (1992) reported the benefit of virginiamycin in the recovery of cattle kept in an endemic area. In the present study, the results show the benefit of the use of the antibiotic in the control of periodontal diseases, which are considered complex, polymicrobial, and dependent on relationships among the bacterial, host, and environment communities. Employed in growth promoter dose in this study, virginiamycin was effective in controlling two precursor forms of periodontitis, gingivitis and necrotizing gingivitis, and it can be considered a form of protection against the development of periodontal disease. In this context, it represents an excellent alternative to the control of periodontal diseases in bovines, especially as it does not leave residues in the meat and does not pose any risks to public health (Menzies-Gow & Young 2011, Bessegatto et al. 2017).

CONCLUSION

Virginiamycin administered at a dosage of 340mg/animal/day reduced significantly the occurrence and was effective in control and prevention of periodontal diseases (gingivitis and necrotizing gingivitis) in calves kept in reformed pastures and with a potentially periodontal pathogenic bacterial microbiota.

Acknowledgments.- To CNPq for grant awarded and to Phibro Animal Health Corporation for project funding. We also acknowledge Robson Vaneri, Department of Pathology and Clinical Propedeutics, Faculty of Dentistry, Unesp-Araçatuba and Adão Ângelo Custódio, Department of Support, Production and Animal Health, Faculty of Veterinary Medicine, Unesp-Araçatuba, for technical services.

Conflict of interest statement.- The authors declare no conflict of interest.

REFERENCES

- Agostinho S.D. 2017. Periodontite e desgaste dentário em ovinos. Doctor of Science in Veterinary Medicine, Faculdade de Ciências Agrárias e Veterinárias, Universidade Estadual Paulista, Jaboticabal, SP. 78p.
- Antiabong J.F., Boardman W., Moore R.B., Brown M.H. & Ball A.S. 2013. The oral microbial community of gingivitis and lumpy jaw in captive macropods. *Res. Vet. Sci.* 95(3):996-1005. <<http://dx.doi.org/10.1016/j.rvsc.2013.08.010>> <PMid:24012349>
- Araújo D.B., Barbosa L.F.S.P., Borges C.A.A., Coulter R., Boselli E., Grandini D.V., Gorocica M.A. & Gosselè F. 2016. Use of virginiamycin in cattle feeding, p.189-2012. In: Millen D.D., Arrigoni M.B. & Pacheco R.D.L. (Eds), *Ruminology*. Springer International Publishing, Switzerland. <http://dx.doi.org/10.1007/978-3-319-30533-2_7>
- Aroucheva A., Ling Z. & Faro S. 2008. *Prevotella bivia* as a source of lipopolysaccharide in the vagina. *Anaerobe* 14(5):256-260. <<http://dx.doi.org/10.1016/j.anaerobe.2008.08.002>> <PMid:18849004>
- Ashimoto A., Chen C., Bakker I. & Slots J. 1996. Polymerase chain reaction detection of 8 putative periodontal pathogens in subgingival plaque of gingivitis and advanced periodontitis lesions. *Oral Microbiol. Immunol.* 11(4):266-273. <<http://dx.doi.org/10.1111/j.1399-302X.1996.tb00180.x>> <PMid:9002880>
- Bessegato J.A., Paulino L.R., Lisboa J.A.N., Alfieri A.A., Montemor C.H., Medeiros L.P., Kobayashi R.K.T., Weese J.S. & Costa M.C. 2017. Changes in the fecal microbiota of beef cattle caused by change in management and the use of virginiamycin as a growth promoter. *Res. Vet. Sci.* 114:355-362. <<http://dx.doi.org/10.1016/j.rvsc.2017.06.011>> <PMid:28675873>
- Borsanelli A.C. 2017. Genotipagem de bactérias anaeróbias associadas às lesões da periodontite bovina. Faculdade de Ciências Agrárias e Veterinárias, Universidade Estadual Paulista, Jaboticabal, SP. 116p.
- Borsanelli A.C., Gaetti-Jardim Junior E., Döbereiner J. & Dutra I.S. 2015a. *Treponema denticola* in microflora of bovine periodontitis. *Pesq. Vet. Bras.* 35(3):237-240. <<http://dx.doi.org/10.1590/S0100-736X2015000300005>>
- Borsanelli A.C., Gaetti-Jardim Junior E., Schweitzer C.M., Döbereiner J. & Dutra I.S. 2015b. Presence of *Porphyromonas* and *Prevotella* species in the oral microflora of cattle with periodontitis. *Pesq. Vet. Bras.* 35(10):829-834. <<http://dx.doi.org/10.1590/S0100-736X2015001000002>>
- Borsanelli A.C., Lappin D.F., Viora L., Bennett D., Dutra I.S., Brandt B.W. & Riggio M.P. 2018. Microbiomes associated with bovine periodontitis and oral health. *Vet. Microbiol.* 218:1-6. <<http://dx.doi.org/10.1016/j.vetmic.2018.03.016>> <PMid:29685214>
- Brasil 2003. Relatório Técnico, nº 808. Ministério da Agricultura, Pecuária e Abastecimento, Brasília. Available at <http://www.agricultura.gov.br/assuntos/insumos-agropecuarios/insumos-pecuarios/arquivos-de-insumos-pecuarios/RelatorioTecnicoFinal05_05_04.doc>. Accessed on May 31, 2018.
- Campello P.L. 2017. Periodontite e desgaste dentário em cabras leiteiras. Doctor of Science in Veterinary Medicine, Faculdade de Ciências Agrárias e Veterinárias, Universidade Estadual Paulista, Jaboticabal, SP. 111p.
- Chen H., Liu Y., Zhang M., Wang G., Zhengnan Q.I., Bridgewater L., Zhao L., Tang Z. & Pang X. 2015. A filifactor alocis-centered co-occurrence group associates with periodontitis across different oral habitats. *Sci. Rep.* 5(9053):1-9.
- Chung W.O., Gabany J., Persson G.R. & Roberts M.C. 2002. Distribution of erm(F) and tet(Q) genes in 4 oral bacterial species and genotypic variation between resistant and susceptible isolates. *J. Clin. Periodontol.* 29(2):152-158. <<http://dx.doi.org/10.1034/j.1600-051x.2002.290210.x>> <PMid:11895543>
- Cogulu D., Uzel A., Oncag O., Eronat C. & Izmir B. 2008. PCR-based identification of selected pathogens associated with endodontic infections in deciduous and permanent teeth. *Oral Surg. Oral Med. Oral Pathol. Oral Radiol.* 106(3):443-449. <<http://dx.doi.org/10.1016/j.tripleo.2008.03.004>> <PMid:18547832>
- Colombo A.P., Bennet S., Cotton S.L., Goodson J.M., Kent R., Haffajee A.D., Socransky S.S., Hasturk H., Van Dyke T.E., Dewhirst F.E. & Paster B.J. 2012. Impact of periodontal therapy on the subgingival microbiota of severe periodontitis: comparison between good responders and individuals with refractory periodontitis using the human oral microbe identification microarray. *J. Periodontol.* 83(10):1279-1287. <<http://dx.doi.org/10.1902/jop.2012.110566>> <PMid:22324467>
- Diehl K. & Rosychuk R.A.W. 1993. Feline gingivitis: stomatitis-pharyngitis. *Vet. Clin. N. Am., Small Anim. Pract.* 23(1):139-153. <[http://dx.doi.org/10.1016/S0195-5616\(93\)50009-8](http://dx.doi.org/10.1016/S0195-5616(93)50009-8)> <PMid:8421885>
- Döbereiner J., Dutra I.S. & Rosa I.V. 2004. A etiologia da "cara inchada", uma periodontite epizootica dos bovinos. *Pesq. Vet. Bras.* 24(1):50-56.
- Döbereiner J., Dutra I.S., Rosa I.V. & Blobel H. 2000. Cara inchada of cattle, an infectious, apparently soil antibiotics-dependant periodontitis in Brazil. *Pesq. Vet. Bras.* 20(2):47-64. <<http://dx.doi.org/10.1590/S0100-736X2000000200001>>
- Döbereiner J., Inada T. & Tokarnia C.H. 1974. "Cara inchada", doença periodontária em bovinos. *Pesq. Agropec. Bras.* 9:63-85.
- Duffy J., Gkraniyas N., Petrie A., McCormick R., Elmer T. & Donos N. 2016. Prevalence and treatment of necrotizing ulcerative gingivitis (NUG) in the British Armed Forces: a case-control study. *Clin. Oral Investig.* 21(6):1935-1944. <<http://dx.doi.org/10.1007/s00784-016-1979-9>>
- Dutra I.S. & Döbereiner J. 2001. Cara inchada dos bovinos, p.397-401. In: Riet-Correa F., Schild A.L., Lemos R.A.A. & Borges J.R.J. (Eds), *Doenças de Ruminantes e Equídeos*, vol.1. 2ª ed. Varela, São Paulo.
- Dutra I.S., Botteon R.C.M. & Döbereiner J. 2000. Modificação da microbiota associada às lesões periodontárias da "cara inchada" em bezerros transferidos para área indene. *Pesq. Vet. Bras.* 20(2):71-74. <<http://dx.doi.org/10.1590/S0100-736X2000000200003>>
- Dutra I.S., Matsumoto T. & Döbereiner J. 1993. Surtos de periodontite em bezerros ("cara inchada") associados ao manejo do solo. *Pesq. Vet. Bras.* 13(1/2):1-4.
- Faveri M., Gonçalves L.F., Feres M., Figueiredo L.C., Gouveia L.A., Shibli J.A. & Mayer M.P. 2011. Prevalence and microbiological diversity of *Archaea* in peri-implantitis subjects by 16S ribosomal RNA clonal analysis. *J. Periodont. Res.* 46(3):338-344. <<http://dx.doi.org/10.1111/j.1600-0765.2011.01347.x>> <PMid:21338359>
- Fouad A.F., Barry J., Caimano M., Clawson M., Zhu Q., Carver R., Hazlett K. & Radolf J.D. 2002. PCR-based identification of bacteria associated with endodontic infections. *J. Clin. Microbiol.* 40(9):3223-3231. <<http://dx.doi.org/10.1128/JCM.40.9.3223-3231.2002>> <PMid:12202557>
- Gaetti-Jardim Junior E., Monti L.M., Nicolas Ciesielski F.I., Gaetti-Jardim E.C., Okamoto A.C., Schweitzer C.M. & Avila-Campos M.J. 2012. Subgingival microbiota from *Cebus paella* (capuchin monkey) with different periodontal conditions. *Anaerobe* 18(3):263-269. <<http://dx.doi.org/10.1016/j.anaerobe.2012.02.002>> <PMid:22710412>
- Correl C., Andersson S. & Verhaert L. 2008. Oral examination and recording, p.57-66 In: *Ibid.* (Eds), *Veterinary Dentistry for the General Practitioner*. Elsevier, Toronto.
- Griffen A.L., Beall C.J., Campbell J.H., Firestone N.D., Kumar P.S., Yang Z.K., Podar M. & Leys E.J. 2012. Distinct and complex bacterial profiles in human periodontitis and health revealed by 16S pyrosequencing. *ISME J.* 6(6):1176-1185. <<http://dx.doi.org/10.1038/ismej.2011.191>> <PMid:22170420>
- Haffajee A.D., Teles R.P., Patel M.R., Song X., Yaskell T. & Socransky S.S. 2009. Factors affecting human supragingival biofilm composition. II. Tooth position. *J. Periodont. Res.* 44(4):520-528. <<http://dx.doi.org/10.1111/j.1600-0765.2008.01155.x>> <PMid:18973539>
- Hajshengallis G. 2015. Periodontitis: from microbial immune subversion to systemic inflammation. *Nat. Rev. Immunol.* 15(1):30-44. <<http://dx.doi.org/10.1038/nri3785>> <PMid:25534621>

- Hardham J., Dreier K., Wong J., Sfintescu C. & Evans R.T. 2005. Pigmented anaerobic bacteria associated with canine periodontitis. *Vet. Microbiol.* 106(1/2):119-128. <<http://dx.doi.org/10.1016/j.vetmic.2004.12.018>> <PMid:15737481>
- Harris S., Croft J., O'Flynn C., Deusch O., Colyer A., Allsopp J., Milella L. & Davis I.J. 2015. A pyrosequencing investigation of differences in the feline subgingival microbiota in health, gingivitis e mild periodontitis. *Plos One* 10(11):e0136986. <<http://dx.doi.org/10.1371/journal.pone.0136986>> <PMid:26605793>
- Harvey J.D. 2017. Periodontal microbiology. *Dent. Clin. N. Am.* 61(2):253-269. <<http://dx.doi.org/10.1016/j.cden.2016.11.005>> <PMid:28317565>
- Herrera D., Alonso B., Arriba L., Cruz I.S., Serrano C. & Sanz M. 2014. Acute periodontal lesions. *Periodontol.* 2000 65(1):149-177. <<http://dx.doi.org/10.1111/prd.12022>> <PMid:24738591>
- Holmstrup P. & Westergaard J. 2008. Necrotizing periodontal disease, p.468-474. In: Lindhe J., Lang N.P. & Karring T. (Eds), *Clinical Periodontology and Implant Dentistry*. 5th ed. Blackwell Publishing.
- Kinane D.F. & Bartold P.M. 2007. Clinical relevance of the host responses of periodontitis. *Periodontol.* 2000 43(1):278-293. <<http://dx.doi.org/10.1111/j.1600-0757.2006.00169.x>> <PMid:17214845>
- Kiran K., Swati T., Kamala B.K. & Jaiswal D. 2011. Prevalence of systemic and local disturbances in infants during primary teeth eruption: a clinical study. *Eur. J. Paediatr. Dent.* 12(4):249-252. <PMid:22185250>
- Kistler J.O., Booth V., Bradshaw D.J. & Wade W.G. 2013. Bacterial community development in experimental gingivitis. *PloS One* 8(8):e71227. <<http://dx.doi.org/10.1371/journal.pone.0071227>> <PMid:23967169>
- Klokkevold P.R. 2012. Necrotizing ulcerative periodontitis. p.165-168 In: Newman M.G., Takei H.H., Klokkevold P.R. & Carranza F.A. (Eds), *Carranza's Clinical Periodontology*. 11th ed. Elsevier, Missouri. <<http://dx.doi.org/10.1016/B978-1-4377-0416-7.00017-2>>.
- Kolenbrander P.E. 2000. Oral microbial communities: biofilms, interactions, and genetic systems. *Ann. Rev. Microbiol.* 54(1):413-437. <<http://dx.doi.org/10.1146/annurev.micro.54.1.413>> <PMid:11018133>
- Kolenbrander P.E., Andersen R.N., Blehert D.S., Eglund P.G., Foster J.S. & Palmer Junior R.J. 2002. Communication among oral bacteria. *Microbiol. Mol. Biol. Revs* 66(3):486-505. <<http://dx.doi.org/10.1128/MMBR.66.3.486-505.2002>> <PMid:12209001>
- Konradsson K., Claesson R. & Van Dijken J.W.V. 2007. Dental biofilm, gingivitis and interleukin-1 adjacent to approximal sites of a bonded ceramic. *J. Clin. Periodontol.* 34(12):1062-1067. <<http://dx.doi.org/10.1111/j.1600-051X.2007.01146.x>> <PMid:17941884>
- Kutasi O., Andrasofszky E., Szenci O., Bersenyi A., Siller I. & Abonyi T. 2016. Foxtail grass (*Setaria viridis*), induced ulcerative stomatitis-gingivitis resembling viral vesicular stomatitis in horses. *Livest. Sci.* 215:41-45. <<http://dx.doi.org/10.1016/j.livsci.2017.03.012>>
- Lang N.P., Schätzle M.A. & Löe H. 2009. Gingivitis as a risk factor in periodontal disease. *J. Clin. Periodontol.* 36(Suppl.10):3-8. <<http://dx.doi.org/10.1111/j.1600-051X.2009.01415.x>> <PMid:19432625>
- Larsen T. & Fiehn N.E. 2017. Dental biofilm infections, an update. *Acta Pathol. Microb. Immunol. Scand.* 125(4):376-384. <<http://dx.doi.org/10.1111/apm.12688>> <PMid:28407420>
- Löe H. 1967. The gingival index, the plaque index and the retention index systems. *J. Periodontol.* 38(6):610-616. <<http://dx.doi.org/10.1902/jop.1967.38.6.610>> <PMid:5237684>
- Löe H. 1994. Periodontal disease as we approach the year 2000. *J. Periodontol.* 65(5):464-467. <<http://dx.doi.org/10.1902/jop.1994.65.5s.464>>
- Loesche W.J., Syed S.A., Schmidt E. & Morrison E.C. 1985. Bacterial profiles of subgingival plaques in periodontitis. *J. Periodontol.* 56(8):447-456. <<http://dx.doi.org/10.1902/jop.1985.56.8.447>> <PMid:3869648>
- Lopes Neto R. 2007. Estudo da frequência de micoplasma no trato urogenital, orofarínge e conjuntiva de macaco (*CEBUS*). Master's Thesis in Microbiology, Universidade de São Paulo, São Paulo. 82p.
- Lyon K.F. 2005. Gingivostomatitis. *Vet. Clin. N. Am., Small Anim. Pract.* 35(4):891-911. <<http://dx.doi.org/10.1016/j.cvsm.2005.02.001>>
- Marshall M.D., Wallis C.V., Milella L., Colyer A., Tweedie A.D. & Harris S. 2014. A longitudinal assessment of periodontal disease in 52 miniature schnauzers. *Vet. Res.* 10:166. <PMid:25179569>
- Mayanagi G., Sato T., Shimauchi H. & Takahashi N. 2004. Detection frequency of periodontitis-associated bacteria by polymerase chain reaction in subgingival and supragingival plaque of periodontitis and healthy subjects. *Oral Microbiol. Immunol.* 19(6):379-385. <<http://dx.doi.org/10.1111/j.1399-302x.2004.00172.x>> <PMid:15491463>
- Menzies-Gow N.J. & Young N.J. 2011. Antibiotic resistance in faecal bacteria isolated from horses receiving virginiamycin for the prevention of pasture-associated laminitis. *Vet. Microbiol.* 152(3/4):424-428. <<http://dx.doi.org/10.1016/j.vetmic.2011.05.026>> <PMid:21676560>
- Nadkarni M.A., Browne G.V., Chhour K.L., Byun R., Nguyen K.A., Chapple C.C., Jacques N.A. & Hunter N. 2012. Pattern of distribution of *Prevotella* species/phylogenotypes associated with healthy gingiva and periodontal disease. *Eur. J. Clin. Microbiol. Infect. Dis.* 31(11):2989-2999. <<http://dx.doi.org/10.1007/s10096-012-1651-5>> <PMid:22684253>
- Nagahata H., Nochi H., Tamoto K., Taniyama H., Noda H., Morita M., Kanamaki M. & Kociba G.J. 1993. Bovine leukocyte adhesion deficiency in holstein cattle. *Can. J. Vet. Res.* 57(4):255-261. <PMid:7903594>
- Newman M.G., Takei H.H. & Klokkevold P.R. 2012. Características clínicas da gengivite, p.77-84. In: Newman M.G., Takei H.H., Klokkevold P.R. & Carranza F.A. (Eds), *Carranza, Periodontia Clínica*. 11ª ed. Elsevier, Rio de Janeiro.
- Page R.C. 1986. Gingivitis. *J. Clin. Periodontol.* 13(5):345-359. <<http://dx.doi.org/10.1111/j.1600-051X.1986.tb01471.x>> <PMid:3522644>
- Riggio M.P., Lennon A., Taylor D.J. & Bennett D. 2011. Molecular identification of bacteria associated with canine periodontal disease. *Vet. Microbiol.* 150(3/4):394-400. <<http://dx.doi.org/10.1016/j.vetmic.2011.03.001>> <PMid:21489726>
- Rodríguez-Pulido J., Quiroga-Zúñiga N. & Martínez-Sandoval G. 2016. Clinical diagnosis and treatment of necrotizing ulcerative gingivitis in the orthodontic patient, a case report. *J. Oral Res.* 5(3):119-123. <<http://dx.doi.org/10.17126/joralres.2016.026>>
- Rowland R.W. 1999. Necrotizing ulcerative gingivitis. *Ann. Periodontol.* 4(1):65-73, discussion 78. <<http://dx.doi.org/10.1902/annals.1999.4.1.65>> <PMid:10863376>
- Salisbury R.M., Armstrong M.C. & Gray K.G. 1953. Ulcero-membranous gingivitis in the sheep. *N.Z. Vet. J.* 1(3):51-52. <<http://dx.doi.org/10.1080/00480169.1953.33104>>
- Senhorinho G.N., Nakano V., Liu C., Song Y., Finegold S.M. & Avila-Campos M.J. 2011. Detection of *Porphyromonas gulae* from subgingival biofilms of dogs with and without periodontitis. *Anaerobe* 17(5):257-258. <<http://dx.doi.org/10.1016/j.anaerobe.2011.06.002>> <PMid:21723404>
- Signat B., Roques C., Poulet P. & Duffaut D. 2011. Role of *Fusobacterium nucleatum* periodontal health and disease. *Curr. Issues Intest. Microbiol.* 13(2):25-36. <PMid:21220789>
- Socransky S.S. & Haffajee A.D. 2005. Periodontal microbial ecology. *Periodontol.* 2000 38(1):135-187. <<http://dx.doi.org/10.1111/j.1600-0757.2005.00107.x>> <PMid:15853940>
- Socransky S.S. & Haffajee A.D. 2010. Infecções periodontais, p.197-254. In: Lindhe J., Lang N.P. & Karring T. (Eds), *Tratado de Periodontia Clínica e Implantologia Oral*. 5ª ed. Guanabara Koogan, Rio de Janeiro. 1340p.
- Socransky S.S., Haffajee A.D., Cugini M.A., Smith C. & Kent Junior R.L. 1998. Microbial complexes in subgingival plaque. *J. Clin. Periodontol.* 25(2):134-144. <<http://dx.doi.org/10.1111/j.1600-051X.1998.tb02419.x>> <PMid:9495612>

- Stamm J.W. 1986. Epidemiology of gingivitis. *J. Clin. Periodontol.* 13(5):360-366. <<http://dx.doi.org/10.1111/j.1600-051X.1986.tb01473.x>> <PMid:3522645>
- Stevenson G.C., Riano P.C., Moretti A.J., Nichols C.M., Engelmeier R.L. & Flaitz C.M. 2007. Short term success of osseointegrated dental implants in HIV positive individuals: a prospective study. *J. Contemp. Dent. Pract.* 8(1):1-10. <PMid:17211499>
- Stingu C.S., Schaumann R., Jentsch H., Eschrich K., Brosteanu O. & Rodloff A.C. 2013. Association of periodontitis with increased colonization by *Prevotella nigrescens*. *J. Investig. Clin. Dent.* 4(1):20-25. <<http://dx.doi.org/10.1111/j.2041-1626.2012.00129.x>> <PMid:22767485>
- Teles F.R., Teles R.P., Uzel N.G., Song X.Q., Torresyap G., Socransky S.S. & Haffajee A.D. 2012. Early microbial succession in redeveloping dental biofilms in periodontal health and disease. *J. Periodont. Res.* 47(1):95-104. <<http://dx.doi.org/10.1111/j.1600-0765.2011.01409.x>> <PMid:21895662>
- Tims F.M., Dutra I.S., Matsumoto T. & Döbereiner J. 1992. Eficiência da virginamicina na recuperação de bezerros com a doença peridentária "cara inchada". *Pesq. Vet. Bras.* 12:77-80.
- Tran T., Flynn M.J., Chen C. & Slots J. 1997. Absence of *Porphyromonas asaccharolytica*, *Bacteroides fragilis* and *Chlamydia pneumoniae* in human subgingival plaque. *Oral Microbiol. Immunol.* 12(6):377-378. <<http://dx.doi.org/10.1111/j.1399-302X.1997.tb00742.x>> <PMid:9573814>
- Williams C.A., Winkler J.R., Grassi M. & Murray P.A. 1990. HIV-associated periodontitis complicated by necrotizing stomatitis. *Oral Surg. Oral Med. Oral Pathol. Oral Radiol.* 69(3):351-355. <[http://dx.doi.org/10.1016/0030-4220\(90\)90298-7](http://dx.doi.org/10.1016/0030-4220(90)90298-7)> <PMid:2314860>
- Willis S.G., Smith K.S., Dunn V.L., Gapter L.A., Riviere K.H. & Riviere G.R. 1999. Identification of seven *Treponema* species in health- and disease-associated dental plaque by Nested PCR. *J. Clin. Microbiol.* 37(3):867-869. <PMid:9986879>
- Xia T. & Baumgartner C. 2003. Occurrence of *Actinomyces* in infections of endodontic origin. *J. Endodontics* 29(9):549-552. <<http://dx.doi.org/10.1097/00004770-200309000-00001>>
- Yamabe K., Maeda H., Kokeguchi S., Tanimoto I., Sonoi N., Asakawa S. & Takashiba S. 2008. Distribution of *Archaea* in Japanese patients with periodontitis and humoral immune response to the components. *FEMS Microbiol. Lett.* 287(1):69-75. <<http://dx.doi.org/10.1111/j.1574-6968.2008.01304.x>> <PMid:18707623>
- Yoshida A., Tachibana A.M., Ansai T. & Takehara T. 2005. Multiplex polymerase chain reaction assay for simultaneous detection of black-pigmented *Prevotella* species in oral specimens. *Oral Microbiol. Immunol.* 20(1):43-46. <<http://dx.doi.org/10.1111/j.1399-302X.2004.00179.x>> <PMid:15612945>