

## Experimental reproduction of congenital anomalies in the progeny of cows fed apple pomace during pregnancy<sup>1</sup>

Nathalia S. Wicpolt<sup>2</sup>, Raissa M. Morais<sup>2</sup>, Francieli Adriane Molossi<sup>2</sup> ,  
Daiane Ogliari<sup>2</sup>, Joana Mezzalira<sup>3</sup>, Osmar D. Prestes<sup>4</sup>, Renato Zanella<sup>4</sup> and Aldo Gava<sup>2\*</sup> 

**ABSTRACT.**- Wicpolt N.S., Morais R.M., Molossi F.A., Ogliari D., Mezzalira J., Prestes O.D., Zanella R. & Gava A. 2019. **Experimental reproduction of congenital anomalies in the progeny of cows fed apple pomace during pregnancy.** *Pesquisa Veterinária Brasileira* 39(6):371-375. Laboratório de Patologia Animal, Departamento de Medicina Veterinária, Centro de Ciências Agroveterinárias, Universidade do Estado de Santa Catarina, Av. Luiz de Camões 2090, Lages, SC 88520-000, Brazil. E-mail: [aldo.gava@udesc.br](mailto:aldo.gava@udesc.br)

This study aimed to describe and discuss the results of an experiment carried out in two stages with pregnant cows fed 25kg/apple pomace/day. The first stage involved 16 pregnant Holstein Friesian cows divided into four groups: Group 0 - Control (5 cows); Group I - 1 month-gestation (4 cows); Group II - 3 month-gestation (4 cows); Group III - 6 month-gestation (3 cows) and was performed from September to December 2015. The second stage comprised 12 pregnant Holstein Friesian cows divided into three groups: Group 0 - Control (6 cows), Group I - 1 month-gestation (3 cows), and Group II - 3 month-gestation (3 cows) and was conducted from April 2016 to February 2017. All study animals received apple pomace at a dose of 25kg/day. As for the first experiment stage, a cow in Group III bred a calf with complete absence of the coccygeal vertebrae and tail, slight bending of the hind limbs, scoliosis in the thoracic spine, and limited mobility. At 30 days, it presented with diarrhea and underdevelopment, and was euthanized for necropsy. At gross examination, malformations were observed in the thoracic spine, coxofemoral joint, and genitourinary tract. Regarding the second experiment stage, a cow in Group I gave birth to a calf with curved pelvic and thoracic limbs with thick joints and flattening hooves. Microscopic examination of the femur showed disorganized, irregular hypertrophic zone and scarce growth zone, in addition to primary spongy zone with short, slightly mineralized trabeculae. Samples of the apple pomace used in this study were frozen and sent for laboratory evaluation of pesticide residues, which showed a positive result for the fungicide carbendazim.

**INDEX TERMS:** Experimental reproduction, congenital anomalies, progeny, cows, apple pomace, pregnancy, calf, cattle, pathology.

<sup>1</sup> Received on November 28, 2018.

Accepted for publication on February 12, 2019.

<sup>2</sup> Laboratório de Patologia Animal, Departamento de Medicina Veterinária, Centro de Ciências Agroveterinárias (CAV), Universidade do Estado de Santa Catarina (UDESC), Av. Luiz de Camões 2090, Bairro Conta Dinheiro, Lages, SC 88520-000, Brazil. \*Corresponding author: [aldo.gava@udesc.br](mailto:aldo.gava@udesc.br)

<sup>3</sup> Laboratório de Reprodução Animal, Departamento de Medicina Veterinária, Centro de Ciências Agroveterinárias (CAV), Universidade do Estado de Santa Catarina (UDESC), Av. Luiz de Camões 2090, Bairro Conta Dinheiro, Lages, SC 88520-000.

<sup>4</sup> Laboratório de Análises de Resíduos de Pesticidas, Departamento de Química, Universidade Federal de Santa Maria (UFSM), Avenida Roraima 1000, Campus Universitário, Santa Maria, RS 97105-900.

**RESUMO.- [Reprodução experimental de anomalias congênitas na progênie de vacas alimentadas com bagaço de maçã durante a gestação.]** O presente trabalho tem por finalidade descrever e discutir os resultados do experimento realizado em vacas prenhes que foram alimentadas com 25kg/dia de bagaço de maçã. Experimentos foram conduzidos em duas etapas, a primeira no ano de 2015, de setembro a dezembro onde foram utilizadas 16 vacas prenhes da raça holandês. Estas foram divididas em quatro grupos: Grupo 0, Controle (5 vacas); Grupo I, 1 mês gestação (4 vacas); Grupo II, 3 meses

gestação (4 vacas); Grupo III, 6 meses gestação (3 vacas). A segunda etapa foi realizada em abril de 2016 a fevereiro de 2017. Foram utilizadas 12 vacas prenhes da raça holandês, divididas em três grupos: Grupo 0, Controle (6 vacas); Grupo I, 1 mês gestação (3 vacas); Grupo II, 3 meses gestação (3 vacas). Todas as vacas receberam bagaço de maçã na dose de 25kg/dia/vaca. Para o primeiro experimento, uma vaca do Grupo III pariu uma bezerra, com ausência completa das vértebras coccígeas e cauda, encurvamento leve dos membros posteriores, escoliose na coluna torácica e dificuldade de locomoção. Decorridos 30 dias do nascimento, manifestou diarreia e pouco desenvolvimento, sendo eutanasiada para necropsia. Na macroscopia, havia malformações na coluna torácica, articulação coxofemoral e no aparelho urogenital. Em relação ao segundo experimento uma vaca do Grupo I pariu uma bezerra com membros pélvicos e torácicos, curvos e com articulações consideravelmente grossas e “achinelamento” de cascos. Na microscopia do fêmur foi observado na placa epifisária, zona hipertrófica desorganizada, irregular e zona de crescimento escassa. Na zona esponjosa primária observou-se trabéculas curtas e pouco mineralizadas. Amostras do bagaço de maçã utilizado na experimentação foram congeladas e enviadas para avaliação de resíduos agrotóxicos, onde foi encontrado resultado positivo para o fungicida carbendazim.

**TERMOS DE INDEXAÇÃO:** Reprodução experimental, anomalias congênitas, progênie, vacas, bagaço de maçã, gestação, bezerra, bovinos, patologia.

## INTRODUCTION

Apple is a crop of great economic importance in the South Region of Brazil, which is responsible for 98% of the national production of this fruit. Pomace is the main by-product of this fruit, corresponding to 25% of its weight. Apple pomace is composed of 18% dry matter (DM), 6.5% crude protein (CP), 42% neutral detergent fiber (NDF), 3.2% ethereal extract (EE), 4.2% mineral matter (MM), and 62.4% total digestible nutrient (TDN). It is characterized by presenting low DM and CP contents; however, it shows medium NDF content and can be an alternative energy source in the feeding of ruminants (Ribeiro Filho et al. 2012). This by-product is often used to feed bovines and has been shown to cause osseous malformation in calves born of cows that ingested it during pregnancy (Wicpolt 2018, Wicpolt & Gava 2019).

According to Rumsey et al. (1977), these malformations may be associated with pesticides frequently used in apple culture, which may remain as residue in the bagasse. In the states of Santa Catarina and Rio Grande do Sul, a variety of agrochemicals are used for pest control in apple crops. According to the National Agency of Sanitary Surveillance (Anvisa 2017), over 60 different types of pesticides are used for this purpose, including carbamates and organophosphates. Exposure to these pesticides may harm the development of newborn calves (Grecco et al. 2009, Oliveira-Filho et al. 2010). Another product frequently used in apple trees is abamectin, which can cause neurological changes and death in cattle if applied at doses higher than the recommended (Seixas et al. 2006).

This study aimed to confirm the presence of osseous malformation in calves born of cows fed apple pomace during pregnancy and identify pesticides and other chemicals present in this by-product that could be the cause of these malformations.

## MATERIALS AND METHODS

This study was carried out in two stages: the first stage involved 16 pregnant Holstein Friesian cows divided into four groups: Group 0 - Control (5 cows); Group I - 1 month-gestation (4 cows); Group II - 3 month-gestation (4 cows); Group III - 6 month-gestation (3 cows) and was performed from September to December 2015. The second stage comprised 12 pregnant Holstein Friesian cows divided into three groups: Group 0 - Control (6 cows), Group I - 1 month-gestation (3 cows), and Group II - 3 month-gestation (3 cows) and was conducted from April 2016 to February 2017. In both experiment stages, for each group, except for the Control groups, the pregnant cows were offered apple pomace from the *Planalto Catarinense* region (silage) at the dose of 25kg/animal/day. All study animals also grazed on *Trifolium repens* (white clover) and *Pennisetum clandestinum* (kikuyu grass) pasture. In the first stage, animals were offered apple pomace for three months, whereas in the second stage, cows in Group I received apple pomace for eight months and cows in Group II received it for six months (Table 1). Both experiment stages used cows after gestation was confirmed by rectal palpation and ultrasound (US) examination. Two calves were born with malformation: one in each of the experiment stages. At necropsy, tissue samples were collected from the heart, lung, liver, kidney, omasum, abomasum, intestine, spleen, lymph node, skeletal muscle, bone and central nervous system for histological examination. Samples were fixed in 10% formalin, dehydrated in alcohol, clarified with xylene, and embedded in 10% paraffin. 3µm-thick sections of the material were stained using the hematoxylin-eosin (HE) technique (Prophet et al. 1992) and examined under optical light microscopy. Samples of the apple pomace used in the experiment were sent to the Laboratory of Pesticide Residue Analysis (LARP) of the “Universidade Federal de Santa Maria” (UFSM) for residue identification of the pesticides most commonly used in apple crops. Residue analysis was conducted using the modified QuEChERS method; quantification was performed by liquid chromatography coupled with serial mass spectrometry (LC-MS/MS) as described by Kemmerich et al. (2018). Seventy-seven chemical substances were analyzed. The experiments were performed at the Dairy Cattle Sector of the Agronomic Sciences Center located in the municipality of Lages, Santa Catarina state, Brazil

**Table 1. Experimental design with apple pomace offered to pregnant cows at the dose of 25kg/animal/day**

Year	Group	Bovine (n)	Gestation time (months)	Ingestion time (months)
2015	0 (control)	5	1 to 6	-
	I	4	1	3
	II	4	3	3
	III	3	6	3
2016-2017	0 (control)	6	1 to 6	-
	I	3	1	8
	II	3	3	6

## RESULTS

Of the 16 cows in experiment stage 1, one in Group III gave birth to a calf with malformations characterized by complete absence of the coccygeal vertebrae, curved posterior limbs (Fig.1), and scoliosis in the thoracic spine. Thirty days after birth, it presented with diarrhea, developmental delay and limited mobility, and was euthanized. Necropsy revealed lateral deviation of the thoracic spine (Fig.2) and thickened chondral articulations.

The urogenital tract showed deviation of the right ureter, which had a blind ending and extended from the kidney to the cervix; the left uterine horn and ovary were inside the bladder neck (Fig.3). In experiment stage 2, eight cows gave birth to normal calves, and one cow in Group I bred a calf with curved posterior limbs, moderate thickening of the articulations, and flattened hooves, which impaired mobility and balance (Fig.4).



Fig.1. Experimental reproduction (Experiment stage 1). Calf with curved posterior limbs, thickened articulations, and absence of the coccygeal vertebrae.

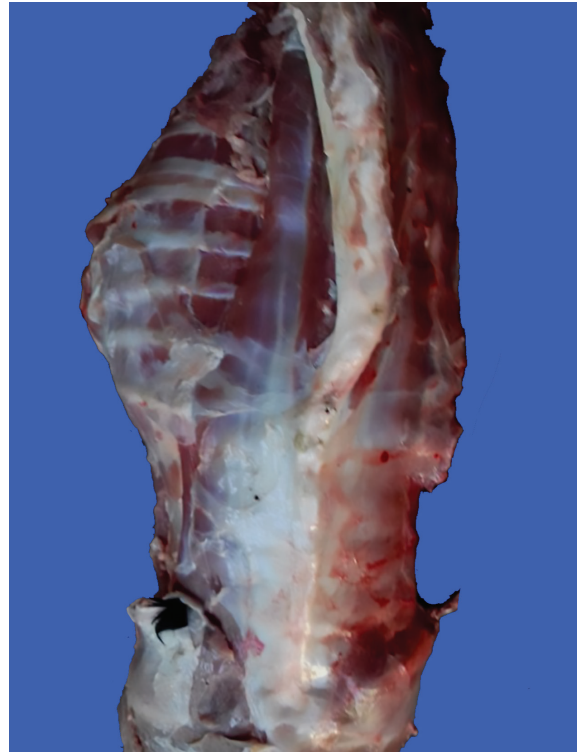


Fig.2. Experimental reproduction (Experiment stage 1). Scoliosis in the thoracic spine of a calf.

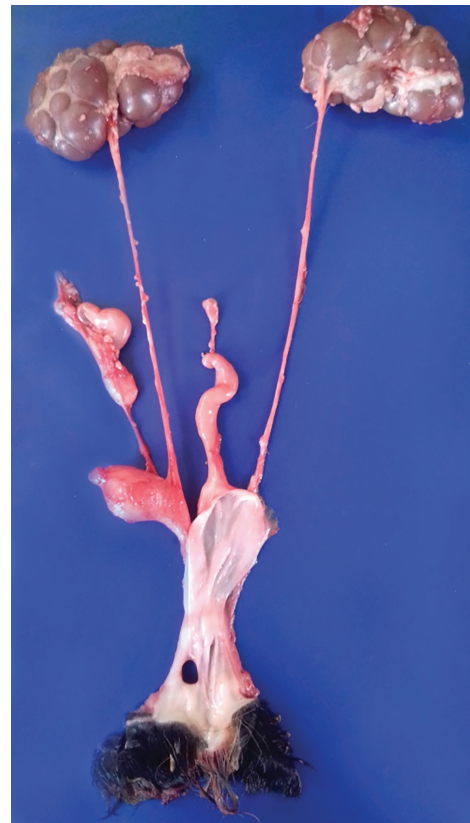

Fig.3. Experimental reproduction (Experiment stage 1). Urogenital tract of a calf showing deviation of the right ureter with blind ending and extending from the kidney to the cervix; the left uterine horn and ovary were inside the bladder neck.

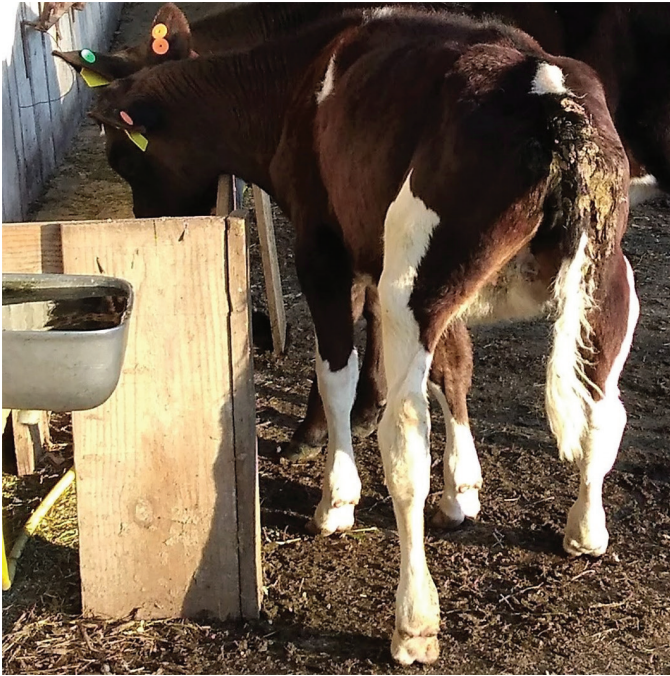

Fig.4. Experimental reproduction (Experiment stage 2). Calf with angular deformity of the pelvic limbs and moderate thickening of the joints.

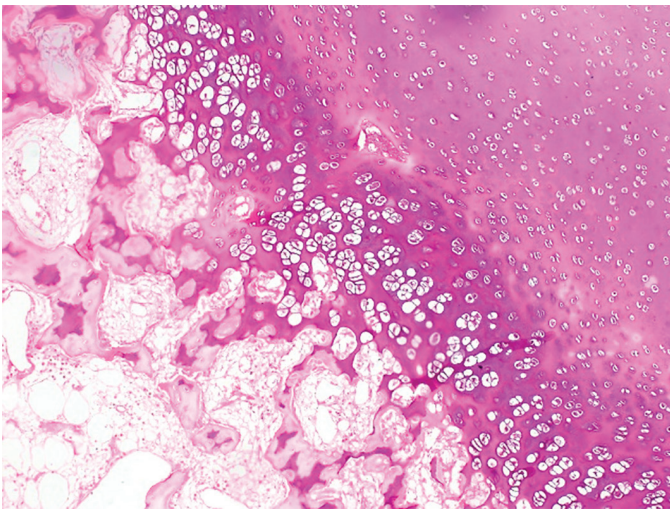


Fig.5. Femur (Experiment stage 1). Disorganized, irregular hypertrophic zone, scarce growth zone, and primary spongy zone with short, slightly mineralized trabeculae. HE, obj.10x.

Microscopically, the femur epiphysis showed disorganized, irregular hypertrophic zone and scarce growth zone. Short, slightly mineralized trabeculae were observed in the primary spongy zone (Fig.5). Analysis of chemicals present in the apple pomace was positive only for the fungicide carbendazim, belonging to the benzimidazole chemical group, at a concentration of  $0.006\text{mg/kg}^{-1}$ .

## DISCUSSION

Experimentally, ingestion of apple pomace by 17 pregnant cows at the dose of  $25\text{kg/animal/day}$  for 3 and 8 months, respectively, resulted in malformation in two calves, characterized mainly

by curved limbs, especially the posterior quarters. One of the calves showed lateral deviation of the thoracic spine, absence of coccygeal vertebrae, and malformation of the urogenital tract. Bending of the limbs was similar, but less severe than that observed in calves born of cows with natural intoxication with apple pomace (Wicpolt 2018, Wicpolt & Gava 2019). It is worth noting that in cases of natural intoxication, the apple pomace was of unknown origin and from different regions of the states of Santa Catarina and Rio Grande do Sul. The apple pomace used in this study was from an apple juice extraction plant and, according to information obtained later, the criteria for use of pesticides were very strict.

Assessment of malformation in calves associated with ingestion of apple pomace by the pregnant cows should consider the amount ingested. According to Wicpolt (2018), in cases of natural poisoning, the osseous malformations were observed in properties where the cows ingested amounts greater than  $20\text{ kg/animal/day}$  for a period longer than three months.

Malformation due to ingestion of apple pomace by pregnant cows should be assessed by differential diagnosis of the malformations caused by plants. In the Northeast Region of Brazil, ingestion of "jurema preta" (*Mimosa tenuiflora*) and "catingueira" (*Poincianella pyramidalis*) leads to craniofacial osseous anomalies, ocular malformation, and arthrogryposis (Pimentel et al. 2007, Medeiros et al. 2008, Souza et al. 2018, Dantas et al. 2010, Santos et al. 2012). Intoxication with *Lupinus angustifolius*, *Veratrum californicum*, *Nicotiana glauca* (Kellerman et al. 1990), and *Conium maculatum* (Tokarnia et al. 1985) experimentally affect not only bovines, but also ovine, swine and goats, which in addition to malformations, also present signs of salivation, staggering gait, tremors, convulsions, and dyspnea. Of these plants, *Conium maculatum* (poison hemlock) is the only one growing in the South Region; however, this plant was not found in any of the properties where the disease occurred.

Malformations in cattle are also caused by the Bovine Viral Diarrhea (BVD) (Flores & Schuch 2007, Quincozes et al. 2007) and the Bluetongue (Riet-Correa 2007, Antoniassi et al. 2010) viruses. The aforementioned authors have reported that these pathogens are highly infectious and also affect ovine, goats, and free-living ruminants. In addition to causing erosive lesions and ulcers in the mucosa, affected animals also show respiratory symptoms such as fever, mucopurulent or bloody nasal discharge, embryonic death, and abortion. These clinical signs were not observed in the cows and calves in which the spontaneous disease occurred, or in the cows used in the experiment. Many factors can be involved in malformation in calves born of cows fed apple pomace. The present study was performed based on the hypothesis of association with pesticides present in the bagasse as residues, namely, organophosphates, carbamates (Oliveira-Filho et al. 2010), pyrethroids (Fenster et al. 2006, Wolansky & Harrill 2008), and abamectin (Seixas et al. 2006). Analysis of the apple pomace used in this study detected only residues of carbendazim. According to specifications from Anvisa (2017) and the U.S. Environmental Protection Agency (EPA 2017), carbendazim is a fungicide of toxicological class III, showing medium toxicity. Animal experiments performed by Silva et al. (2014), confirmed the mutagenic and/or carcinogenic potential of carbendazim. According to them, the compound can cause chromosomal anomalies, with change in the number of chromosomes in the cells, leading to DNA damage (mutagenic effects) and affecting embryonic or fetal development (teratogenic/embryotoxicity effects). Janardhan et al. (1984), verified that doses of 4 to  $80\text{mg/kg/day}$  of carbendazim, administered between 6 and 15 days of gestation, increased the incidence of fetal reabsorption. Embryonic death, growth

delay, and development of anomalies were also observed by Cummings et al. (1992) with the use of carbendazim in pregnant mice, which was also responsible for causing malformation in fetus with hydrocephalus, deformation of skull and limbs, fusion of vertebrae, ribs and sternum, and anophthalmia (Alvarez 1987).

## CONCLUSIONS

Experimentally, apple pomace provided to pregnant cows at the dose of 25kg/animal/day for a period longer than three months cause malformation in calves characterized by osseous deformities, curved hind quarters, thickened joints, absence of coccygeal vertebrae, and malformation of the urogenital tract.

Fungicide carbendazim remains in apple pomace in its residual form, and can be responsible for the malformations observed in the calves of this study.

**Conflict of interest statement.** - The authors declare that there are no conflicts of interest.

## REFERENCES

- Alvarez L. 1987. Teratogenicity study of INE-965 (carbendazim) in rats: unpublished report No MR- 7976-001 HLR 281-87. Human Health Risk Assessment of Carbendazim. Australian Pesticides and Veterinary Medicines Authority, Office of Chemical Safety and Environmental Health, Office of Health Protection, Department of Health and Ageing, Canberra, p. 63-66. Available at <<https://apvma.gov.au/sites/default/files/publication/14531-carbendazim-prf-vol2.pdf>> Accessed on Nov. 9, 2017.
- Antoniassi N.A.B., Pavarini S.P., Ribeiro L.A.O., Silva M.S., Flores E.F. & Driemeier D. 2010. Caracterização patológica e imunohistoquímica da infecção pelo vírus da diarreia viral bovina. *Pesq. Vet. Bras.* 30(12):1010-1016. <<http://dx.doi.org/10.1590/S0100-736X2010001200002>>
- Anvisa 2017. Programa de Análise de Resíduos de Agrotóxicos em alimentos (PARA). Available at <[http://portal.anvisa.gov.br/documents/111215/0/Relat%C3%B3rio+PARA+2013-2015\\_VERS%C3%83FINAL.pdf/494cd7c5-5408-4e6a-b0e5-5098cbf759f8](http://portal.anvisa.gov.br/documents/111215/0/Relat%C3%B3rio+PARA+2013-2015_VERS%C3%83FINAL.pdf/494cd7c5-5408-4e6a-b0e5-5098cbf759f8)> Accessed on Nov. 9, 2017.
- Cummings A.M., Ebron-McCoy M.T., Rogers J.M., Barbee B.D. & Harris S.T. 1992. Developmental effects of methyl benzimidazolecarbamate following exposure during early pregnancy. *Fundam. Appl. Toxicol.* 18(2):288-293. <[http://dx.doi.org/10.1016/0272-0590\(92\)90057-0](http://dx.doi.org/10.1016/0272-0590(92)90057-0)> <PMid:1601229>
- Dantas A.F.M., Riet-Correa F., Medeiros R.M.T., Galiza G.J.N., Pimentel L.A., Anjos B.L. & Mota R.A. 2010. Malformações congênitas em ruminantes no semiárido do Nordeste Brasileiro. *Pesq. Vet. Bras.* 30(10):807-815. <<http://dx.doi.org/10.1590/S0100-736X2010001000002>>
- EPA 2017. United States Environmental Protection Agency. Available at <[http://www.epa.gov/pesticides/facsheets/chemicals/carbendazim\\_ra.pdf](http://www.epa.gov/pesticides/facsheets/chemicals/carbendazim_ra.pdf)> Accessed on Nov. 9, 2017.
- Fenster L., Eskenazi B., Anderson M., Bradman A., Harley K., Hernandez H., Hubbard A. & Barr D.B. 2006. Association of in utero organochlorine pesticide exposure and fetal growth and length of gestation in an agricultural population. *Environ. Health Perspect.* 114(4):597-602. <<http://dx.doi.org/10.1289/ehp.8423>> <PMid:16581552>
- Flores E.F. & Schuch L.F.D. 2007. Diarreia viral bovina, p.81-93. In: Riet-Correa F., Schild A.L., Lemos R.A.A. & Borges J.R.J. (Eds), *Doenças de Ruminantes e Equídeos*. Vol.1. 3ª ed. Varela, São Paulo.
- Grecco F.B., Schild A.L., Soares M.P., Raffi M.B., Sallis E.S.V. & Damé M.C. 2009. Intoxicação por organofosforados em búfalos (*Bubalus bubalis*) no Rio Grande do Sul. *Pesq. Vet. Bras.* 29(3):211-214. <<http://dx.doi.org/10.1590/S0100-736X2009000300004>>
- Janardhan A., Sattur P.B. & Sisodia P. 1984. Teratology of methyl benzimidazole carbamate in rats and rabbits. *Bull. Environ. Contam. Toxicol.* 33(3):257-263. <<http://dx.doi.org/10.1007/BF01625540>> <PMid:6478073>
- Kellerman T.S., Coetzer J.A.W. & Naudé T.W. 1990. Neurological disorders without notable pathological lesions, p.47-82. In: *Ibid.* (Eds), *Plant Poisonings and Mycotoxicoses of Livestock in Southern Africa*. 2nd ed. Oxford, Cape Town.
- Kemmerich M., Bernardi G., Prestes O., Adaime M.B. & Zanella R. 2018. Comprehensive method validation for the determination of 170 pesticide Residues in pear employing modified QuEChERS Without clean-up and ultra-high performance liquid chromatography coupled to tandem mass spectrometry. *Food Anal. Method.* 11(2):556-577. <<http://dx.doi.org/10.1007/s12161-017-1026-8>>
- Medeiros R.M.T., Figueiredo A.P.M., Benício T.M.A., Dantas F.P.M. & Riet-Correa F. 2008. Teratogenicity of *Mimosa tenuiflora* seeds to pregnant rats. *Toxicol. 51(2):316-319*. <<http://dx.doi.org/10.1016/j.toxicol.2007.06.012>> <PMid:18078971>
- Oliveira-Filho J.C., Carmo P.M.S., Pierezan F., Tochetto C., Lucena R.B., Rissi D.R. & Barros C.S.L. 2010. Intoxicação por organofosforado em bovinos no Rio Grande do Sul. *Pesq. Vet. Bras.* 30(10):803-806. <<http://dx.doi.org/10.1590/S0100-736X2010001000001>>
- Pimentel L.A., Correa F.R., Gardner D., Panter K.E., Dantas A.F., Medeiros R.M., Mota R.A. & Araújo J.A. 2007. *Mimosa tenuiflora* as a cause of malformations in ruminants in the Northeastern Brazilian semiarid rangelands. *Vet. Pathol.* 44(6):928-931. <<http://dx.doi.org/10.1354/vp.44-6-928>> <PMid:18039908>
- Prophet E.B., Mills B., Arrington J.B. & Sobin L.H. 1992. Laboratory methods in histotechnology. American Registry of Pathology, Armed Forces Institute of Pathology, Washington, DC. 274p.
- Quincozes C.G., Fischer G., Hubner S.O., Vargas G.D., Vidor T. & Brod C.S. 2007. Prevalência e fatores associados a infecção pelo vírus da Diarreia Viral Bovina na Região Sul do Rio Grande do Sul. *Semina, Ciênc. Agrárias* 28(2):269-276. <<http://dx.doi.org/10.5433/1679-0359.2007v28n2p269>>
- Ribeiro Filho H.M.N., Oliveira Junior L.C.S. & Dias K.M. 2012. Avaliação nutricional do bagaço de maçã como suplementação energética para bovinos. *Ciência Rural* 42(9):1627-1633. <<http://dx.doi.org/10.1590/S0103-84782012005000065>>
- Riet-Correa F. 2007. Língua azul, p.169-173. In: Riet-Correa F., Schild A.L., Lemos R.A.A. & Borges J.R.J. (Eds), *Doenças de Ruminantes e Equídeos*. Vol.1. 3ª ed. Varela, São Paulo.
- Rumsey T.S., Bovard K.P., Fontenot J.P., Oltjen R.R. & Priode B.M. 1977. Supplementation of apple pomace with nonprotein nitrogen for gestating beef cows. IV. Pesticide accumulation. *J. Anim. Sci.* 46(3):543-550. <http://dx.doi.org/10.2527/jas1977.453543x>. PMid:578509.
- Santos J.R.S., Dantas A.F.M. & Riet-Correa F. 2012. Malformações, abortos e mortalidade embrionária em ovinos causada pela ingestão de *Mimosa tenuiflora* (Leguminosae). *Pesq. Vet. Bras.* 32(11):1103-1106. <<http://dx.doi.org/10.1590/S0100-736X2012001100005>>
- Seixas J.N., Peixoto P.V., Armien A.G., Jabour F.F. & Brito M.F. 2006. Aspectos clínicos e patogênicos da intoxicação por abamectina em bezerros. *Pesq. Vet. Bras.* 26(3):161-166. <<http://dx.doi.org/10.1590/S0100-736X2006000300006>>
- Silva R.C., Barros K.A. & Pavão A.C. 2014. Carcinogenicidade do carbendazim e seus metabólitos. *Química Nova* 37(8):1329-1334.
- Souza M.F., Bezerra I.T.F., Barbosa F.M.S., Rocha V.C., Sousa M.S., Oliveira Neto T.S., Lacerda-Lucena P.B. & Lucena R.B. 2018. Abortos, malformações congênitas e falhas reprodutivas espontâneas em caprinos causados pela intoxicação pelas folhas da catingueira, *Poincianella pyramidalis* (sin. *Caesalpinia pyramidalis*). *Pesq. Vet. Bras.* 38(6):1051-1057. <http://dx.doi.org/10.1590/1678-5150-pvb-5243>.
- Tokarnia C.H., Dobereiner J. & Peixoto P.V. 1985. Intoxicação experimental por *Conium maculatum* (Umbelíferae) em bovinos e ovinos. *Pesq. Vet. Bras.* 5(1):15-25.
- Wicpolt N.S. 2018. Artrogripose e condrodysplasia em bezerros nascidos de vacas alimentadas com bagaço de maçã. Doctoral Dissertation in Animal Science, Centro de Ciências Agroveterinárias, Universidade do Estado de Santa Catarina, Florianópolis. 49p.
- Wicpolt N.S. & Gava A. 2019. Osseous malformation in calves and its relationship with ingestion of apple pomace in pregnant cows. *Pesq. Vet. Bras.* 39(5):304-307. <<http://dx.doi.org/10.1590/1678-5150-pvb-6086>>
- Wolansky M.J. & Harrill J.A. 2008. Neurobehavioral toxicology of pyrethroid insecticides in adult animals: a critical review. *Revta Neurotoxicol. Teratol.* 30(2):55-78. <<http://dx.doi.org/10.1016/j.ntt.2007.10.005>> <PMid:18206347>