

Delleman syndrome in a Brazilian boy

M.L. Guion-Almeida and N.M. Kokitsu-Nakata

ABSTRACT

We report on a Brazilian boy, born to normal and nonconsanguineous parents and presenting facial asymmetry, hypotonia, cerebral anomalies, bilateral anophthalmia, supraorbital cysts, skin tags, cleft lip and palate, micrognathia, glossoptosis, cryptorchidism, and genital hypoplasia.

INTRODUCTION

The syndrome of orbital and intracranial cysts, cerebral anomalies, skin tags, focal dermal aplasia/hypoplasia was delineated by Delleman and Oorthuys in 1981. Further cases have since been published (Ferguson *et al.*, 1984; Wilson *et al.*, 1985; Al-Gazali *et al.*, 1988; Giorgi *et al.*, 1989; Lauras *et al.*, 1990; Bleeker-Wagemakers *et al.*, 1990; Brodsky *et al.*, 1990; Hoo *et al.*, 1991; De Cock and Merizian, 1992). Unilateral anophthalmia was observed in a boy reported by Lauras *et al.* (1990) and Brodsky *et al.* (1990). Here we describe a patient with bilateral anophthalmia and typical signs of the Delleman syndrome.

CLINICAL REPORT

RBLM (Figure 1A-C), the propositus, was born at term in 1993 after a normal pregnancy. He is the first child of a normal 34-year old G1P1 mother and her unrelated and normal 29-year old husband. Delivery was through cesarean section. Half-sibs through maternal and paternal line, and close relatives, were normal. Birth weight was 3,000 g (10th-25th centile) and length was 49 cm (10th-25th centile). Cleft lip and palate, eye and ear anomalies were noted at birth.

Examination at one month showed a weight of 2,660 g (< 3rd centile), length of 50.5 cm (3rd centile), an occipitofrontal circumference (OFC) of 36.5 cm (50th centile). He had: postnatal growth failure, hypotonia, structural asymmetry of the face, bilateral anophthalmia, hypoplastic nasal septum and nostrils, right cleft lip and palate, micrognathia, glossoptosis, multiple facial skin tags and cysts, hypoplastic scrotum and penis, and bilateral cryptorchidism (Figure 2).

Due to respiratory difficulties, tracheostomy was performed at age 2 months. Voiding cystourethrogram was normal. Roentgenograms showed facial asymmetry, hypoplastic left orbit and nasal structures, and abnormally developed zygoma. Spine and ribs were normal. CT scan showed secondary anophthalmia with bilateral remnants of the eye globe and optic nerve, brain asymmetry, and cystic lesion in the left cerebellar hemisphere (Figure 3A, B). G-banded chromosomes in peripheral lymphocytes were normal. Follow-up of our patient showed that the boy, at age two years, had mild psychomotor developmental delay, and was beginning to walk and speak. He appeared alert and responsive to his environment. No seizure had been observed.

DISCUSSION

The Delleman syndrome is a recurrent-pattern syndrome and at least 18 isolated patients have been reported (Hoo *et al.*, 1991). Clinical heterogeneity is evident, and the wide phenotypic spectrum with mild or incomplete forms could be responsible for

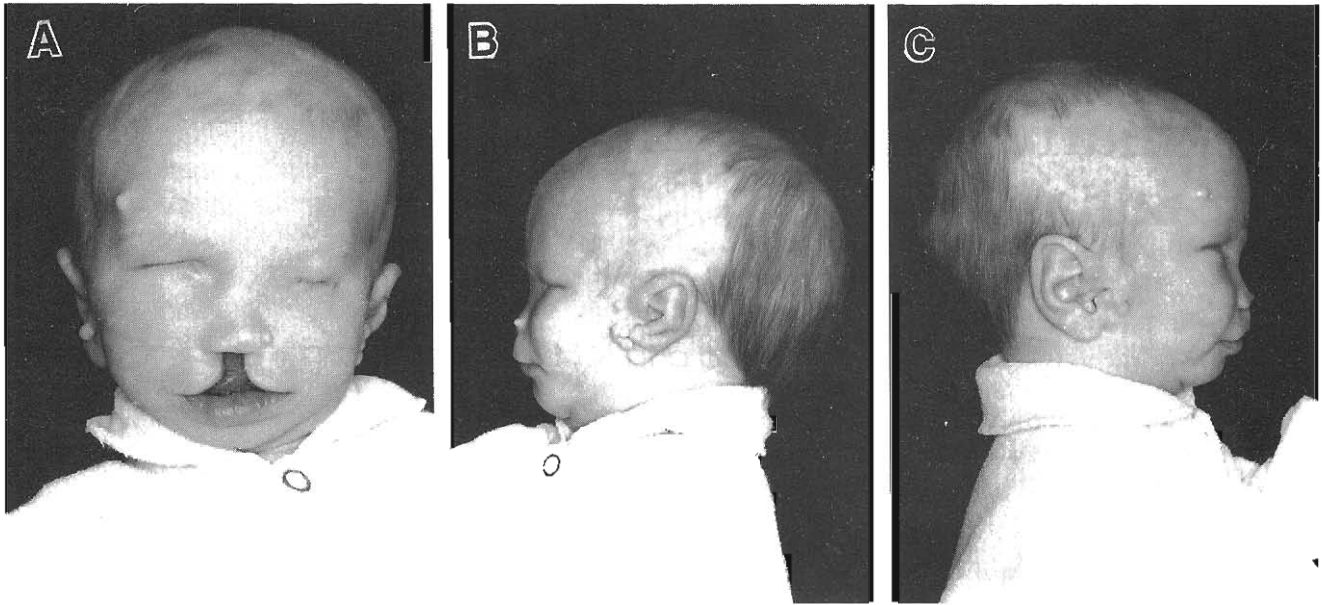


Figure 1A-C - Clinical aspects of the patient.

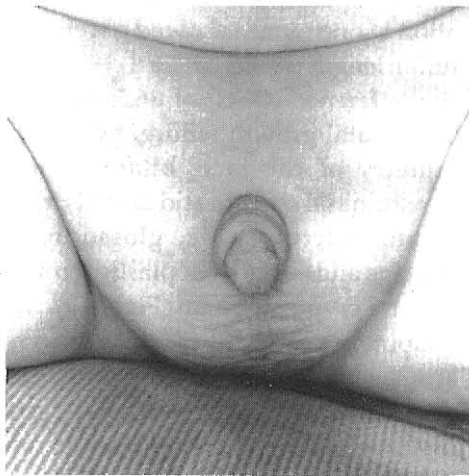


Figure 2 - Hypoplastic scrotum and penis of the patient.

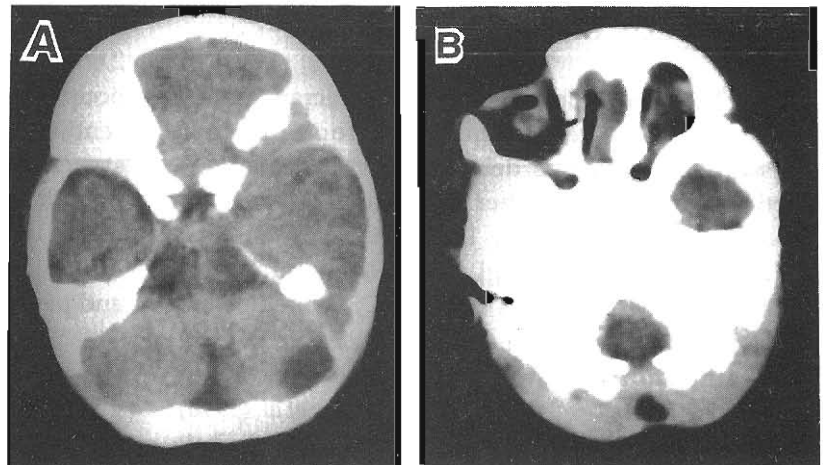


Figure 3A,B - CT scan of the patient.

unreported cases (Gorlin *et al.*, 1990). Hoo *et al.* (1991) observed that this disorder usually affects only one side of the body and that the ratio of unilateral left involvement to unilateral right involvement is about 2:1. Our patient presented bilateral anophthalmia. Cysts and skin appendages were found on both sides. Intracranial cysts and hypoplastic orbit and nasal structures were observed on the left side.

The etiology of the Delleman syndrome remains unknown. All published reports on this condition refer to sporadic cases (both sexes are affected), without any evidence of a known environmental or chromosomal etiological factor. In 1987, Happle postulated that several sporadic syndromes characterized by a mosaic distribution of

skin defects are due to the action of a lethal gene surviving by mosaicism. The presence of the mutation in the zygote would lead to death of the embryo at an early stage of development. Cells bearing the mutation can survive only in a mosaic state. The clinical criteria suggesting a lethal gene surviving by mosaicism is observed in Delleman syndrome. On the other hand, the condition could be the result of an autosomal dominant gene, with variable expression. Consanguinity of phenotypically normal parents was noted twice (Lauras *et al.*, 1990 and De Cock and Merizian, 1992), therefore, autosomal recessive inheritance may be considered.

RESUMO

Os autores descrevem um menino, filho de pais normais e não consangüíneos, apresentando assimetria facial, anomalias cerebrais, anoftalmia bilateral, cistos supraorbitais e intracraniais, apêndices cutâneos, fissura lábio-palatina, micrognatia, glossoptose, criptorquidia, hipoplasia genital e retardo neuromotor. Estudo cromossômico: 46,XY.

REFERENCES

- Al-Gazali, L.I., Donnai, D., Berry, S.A., Say, B. and Mueller, R.F.** (1988). The oculocerebrocutaneous (Delleman) syndrome. *J. Med. Genet.* 25: 773-778.
- Bleeker-Wagemakers, L.M., Hamel, B.C.J., Hennekam, R.C.M., Beemer, F.A. and Oorthuys, H.W.E.** (1990). Oculocerebrocutaneous syndrome. *J. Med. Genet.* 27: 69-70.
- Brodsky, M.C., Harper, R.A., Keppen, L.D. and Glasier, C.M.** (1990). Letter to the Editor: Anophthalmia in Delleman syndrome. *Am. J. Med. Genet.* 37: 157-158.
- De Cock, R. and Merizian, A.** (1992). Delleman syndrome: a case report and review. *Br. J. Ophthalmol.* 76: 115-116.
- Delleman, J.W. and Oorthuys, J.W.E.** (1981). Orbital cyst in addition to congenital cerebral and focal dermal malformations: A new entity? *Clin. Genet.* 19: 191-198.
- Ferguson, J.W., Hutchison, H.T. and Rouse, B.M.** (1984). Ocular, cerebral and cutaneous malformations: confirmation of an association. *Clin. Genet.* 25: 464-469.
- Giorgi, P.L., Gabrielli, O., Catassi, C. and Coppa, G.V.** (1989). Oculo-cerebro-cutaneous syndrome: description of a new case. *Eur. J. Pediatr.* 148: 325-326.
- Gorlin, R.J., Cohen Jr., M.M. and Levin, L.S.** (1990). *Oxford Monographs in Medical Genetics no. 19. Syndromes of the Head and Neck.* 3rd edn. Oxford Monograph Press, New York, pp. 511-512.
- Happle, R.** (1987). Lethal genes surviving by mosaicism: A possible explanation for sporadic birth defects involving the skin. *J. Amer. Acad. Derm.* 16: 899-906.
- Hoo, J.J., Kapp-Simon, K., Rollnick, B. and Chao, M.** (1991). Oculocerebrocutaneous (Delleman) syndrome: A pleiotropic disorder affecting ectodermal tissues with unilateral predominance. *Am. J. Med. Genet.* 40: 290-293.
- Lauras, B., Damon, G., Allard, D., Claudy, A. and Chavier, Y.** (1990). Syndrome oculo-cérébrocutané ou syndrome de Delleman et Oorthuys. *Pédiatrie* 45: 193-196.
- Wilson, R.D., Traverse, L., Hall, J.G., Flodmark, C.O. and Rootman, J.** (1985). Oculocerebrocutaneous syndrome. *Am. J. Ophthalmol.* 99: 142-148.

(Received January 8, 1996)