

Low-dose doxycycline prevents inflammatory bone resorption in rats

M.M. Bezerra¹,
G.A.C. Brito²,
R.A. Ribeiro¹ and
F.A.C. Rocha³

Departamentos de ¹Fisiologia e Farmacologia, ²Morfologia and
³Medicina Clínica, Faculdade de Medicina,
Universidade Federal do Ceará, Fortaleza, CE, Brasil

Abstract

Matrix metalloproteinases (MMP) are considered to be key initiators of collagen degradation, thus contributing to bone resorption in inflammatory diseases. We determined whether subantimicrobial doses of doxycycline (DX) ($\leq 10 \text{ mg kg}^{-1} \text{ day}^{-1}$), a known MMP inhibitor, could inhibit bone resorption in an experimental periodontitis model. Thirty male Wistar rats (180-200 g) were subjected to placement of a nylon thread ligature around the maxillary molars and sacrificed after 7 days. Alveolar bone loss (ABL) was measured macroscopically in one hemiarcade and the contralateral hemiarcade was processed for histopathologic analysis. Groups of six animals each were treated with DX (2.5, 5 or 10 $\text{mg kg}^{-1} \text{ day}^{-1}$, *sc*, 7 days) and compared to nontreated (NT) rats. NT rats displayed significant ABL, severe mononuclear cell influx and increase in osteoclast numbers, which were significantly reduced by 5 or 10 $\text{mg kg}^{-1} \text{ day}^{-1}$ DX. These data show that DX inhibits inflammatory bone resorption in a manner that is independent of its antimicrobial properties.

Key words

- Tetracyclines
- Doxycycline
- Metalloproteinases
- Periodontitis
- Osteoporosis
- Bone resorption
- Inflammation

Correspondence

F.A.C. Rocha
Departamento de Fisiologia e
Farmacologia
Faculdade de Medicina, UFC
Rua Cel. Nunes de Melo, 1127
60430-270 Fortaleza, CE
Brasil
Fax: + 55-85-288-8333
E-mail: arocha@ufc.br
Research supported by CAPES and
FUNCAP.

Received October 4, 2001
Accepted March 19, 2002

Progressive loss of matrix constituents leading to bone resorption is an essential step in the pathogenesis of inflammatory bone disease, such as rheumatoid arthritis and periodontitis (1). Accumulating evidence suggests that activation of proteolytic enzymes, including the matrix metalloproteinase (MMP) family, is responsible for collagen destruction during inflammatory diseases. Apparently, an imbalance between activation of MMP and down-regulation of their endogenous inhibitors leads to pathologic breakdown of the extracellular matrix (2-4).

Tetracyclines (TTC) have long been used as adjuncts in the treatment of periodontal diseases (5,6). Although initially attributed to its antimicrobial properties (1), the clinical efficacy of TTC in periodontitis has been recently suggested to be due to their intrinsic

anti-inflammatory activity (7), since low doses of (subantimicrobial) doxycycline (DX) decrease attachment loss and excessive collagenase activity in the crevicular fluid of periodontitis patients (8,9). Inhibition of the MMP activity would then be responsible for the protective effect of TTC in periodontitis.

Despite the protective effects of TTC in periodontitis, there are no studies reporting that these compounds effectively inhibit bone resorption. In the present study, we determined whether DX, the most potent TTC with anticollagenase activity commercially available, could prevent alveolar bone resorption in an experimental periodontitis model in rats.

Thirty male Wistar rats weighing 180 to 200 g obtained from our own animal facilities were housed in temperature-controlled

rooms and received water and food *ad libitum*. There were 5 groups of 6 animals each consisting of 3 groups treated with DX (Pfizer®, Guarulhos, SP, Brazil) (2.5, 5 or 10 mg/kg) subcutaneously 1 h before the surgical procedure and daily until sacrifice on the 7th day; a control group (naive), which did not receive any manipulation, and a non-treated group of rats subjected to periodontitis that received no pharmacological treatment. Surgical procedures and animal treatments were conducted in accordance with the Guide for the Care and Use of Laboratory Animals (DHEW Publication, Bethesda, MD, USA).

We used an experimental periodontitis model with minor modifications, as described elsewhere (10,11). Briefly, rats were anesthetized with chloral hydrate (400 mg/kg, *ip*) and subjected to surgical placement of a nylon (3-0) thread ligature around the cervix of the maxillary second molars on both sides. The ligature was knotted on the buccal side, so that it remained subgingivally on the palatal side and supragingivally on the buccal side. Animals were sacrificed after 7 days of periodontitis by cervical dislocation under anesthesia and had their maxillae excised. The left maxillary jaws were used to determine the degree of bone loss (macroscopic analysis) and the right jaws were used for histological analysis.

The left jaws were stained with aqueous methylene blue (1%) in order to delineate the cemento-enamel junction. A stereoscope loupe (4X magnification) was used to measure the distance between the cemento-enamel junction and the alveolar bone, as described in Ref. 12. Recordings were made along the long axis of both the buccal and palatal surfaces of all molar teeth. The sum of all recordings for each tooth surface was used as a measure of total alveolar bone loss.

The right jaws were prepared for hematoxylin-eosin staining. Sections of 6 μm corresponding to the area between the first and second molars, where the ligature was placed, were analyzed. Histological analysis consid-

ered a 0-3 score grade based on the following parameters: cell influx, osteoclast numbers and alveolar process and cementum integrity.

Data are reported as means \pm SEM or medians, as appropriate. Univariate ANOVA followed by the Tukey test to compare means and the Mann-Whitney test to compare medians were used for statistical analysis. $P < 0.05$ was considered to be significant.

Surgical placement of a ligature around the cervix of the maxillary second molars of the rats induced significant ($P < 0.05$) alveolar bone loss that started 4 days after periodontitis induction, reaching a maximum at 7 days (data not shown). Histopathological analysis of the region between the first and second molars revealed progressive mononuclear cell infiltration and increase in the number of osteoclasts, together with severe cementum and alveolar bone resorption. In preliminary experiments, these changes peaked at 7 days of periodontitis (11). Therefore, for the analysis of drug treatments, alveolar bone loss on the buccal side was measured at 7 days.

Figure 1 shows that animals subjected to 7 days of periodontitis and treated with DX (2.5, 5 or 10 mg kg^{-1} day^{-1}) exhibited a dose-dependent inhibition of alveolar bone loss that was significantly different from untreated rats ($P < 0.05$).

The reduction in bone loss was accompanied by a decrease in the mononuclear cell influx and osteoclast numbers, coupled with preservation of the cementum and the alveolar process (Table 1). The histopathology measurements for the 5 or 10 mg kg^{-1} day^{-1} DX groups were significantly different ($P < 0.05$) from those for the 2.5 mg kg^{-1} day^{-1} DX and the nontreated group (Table 1).

In this study, DX, a semi-synthetic TTC, dose-dependently inhibited alveolar bone resorption. TTC, besides having antimicrobial properties, are also able to inhibit the activity of interstitial collagenases (MMP) present in a variety of cells such as neutrophils and macrophages (5,6). The demonstration that TTC

treatment reduced gingival collagenase activity by 70% in germ-free rats (13) led to the suggestion that TTC could inhibit extracellular collagenase by a mechanism not related to its antimicrobial effect.

DX, the most potent and cost-effective TTC commercially available, has been shown to reduce collagenase production by osteoblasts and osteoclasts and also to delay osteoclast recruitment following dental surgery (14). In the present study, low-dose (subantimicrobial) DX prevented alveolar bone resorption both at the macroscopic and microscopic levels. In accordance with these data, it was shown that systemic DX prevented both root resorption and bone loss in rats after periodontal surgery (6). In an infectious periodontitis model, DX (5 mg kg⁻¹ 7 day⁻¹) reduced gingival MMP activity although it did not alter the microbiotic flora of the oral cavity (15). Locally applied DX was shown to have a beneficial effect on osteogenesis in dogs subjected to mechanically induced bone lesions (16). Also, systemic DX had bone-sparing effects after periradicular surgery in dogs (17). Additionally, chemically modified DX (CMT-8), that does not display antimicrobial properties, reduced MMP expression in ovariectomized rats (18) and the same CMT-8, combined with disodium clodronate (an aminobisphosphonate that inhibits bone resorption), reduced alveolar bone loss in endotoxin-induced periodontal disease in rats (19).

The present data add to these previous studies confirming that low-dose DX has bone sparing effects in an inflammatory model of bone resorption, that are not related to its antimicrobial activity, thus avoiding the risk of emergence of resistant bacteria and minimizing gastrointestinal side effects usually associated with long-term DX administration. Additionally, we provide, for the first time, direct evidence that DX effectively inhibits inflammatory bone resorption that was not related to infectious agents. The reduction in osteoclast numbers observed in

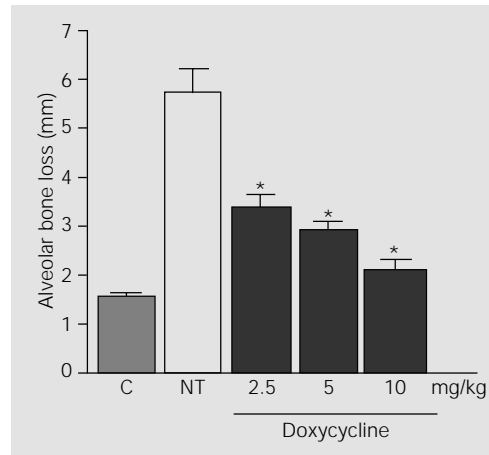


Figure 1. Effect of doxycycline (DX) treatment on alveolar bone loss (ABL) in periodontitis. Rats were subjected to the placement of a nylon thread (3-0) ligature around the cervix of the maxillary second molars. Rats were treated with DX (2.5, 5 or 10 mg/kg, sc) 1 h before periodontitis induction and daily until sacrifice after 7 days. ABL was measured (mm) under microscopy (4X original) as the distance between the cemento-enamel junction and the alveolar bone. "C" indicates naive animals. Data are reported as means \pm SEM for six animals in each group. * $P < 0.05$ compared to nontreated (NT) rats (ANOVA).

Table 1. Effect of doxycycline (2.5, 5 or 10 mg kg⁻¹ day⁻¹) on histological changes in rats subjected to periodontitis.

	Groups				
	Naive	NT	Doxycycline		
			2.5	5	10
Score	0 (0-0)	3 (2-3)	1.5 (1-3)	0 (0-1)*	0 (0-2)*

Rats were subjected to the placement of a nylon thread (3-0) ligature around the cervix of the maxillary second molars to induce periodontitis. Groups were treated with doxycycline (DX, 2.5, 5 or 10 mg/kg, sc) 1 h before periodontitis induction and daily until sacrifice after 7 days. Sections of 6 μ m corresponding to the area where ligature was placed were analyzed. Histological analysis considered a 0-3 grade score based on the following parameters: cell influx, osteoclast numbers, alveolar process and cementum integrity. Naive indicates rats which did not receive any manipulation and nontreated group (NT) indicates rats subjected to periodontitis that received no pharmacological treatment. Data are reported as medians with range within parentheses. * $P < 0.05$ compared to 2.5 DX and NT groups (Mann-Whitney).

DX-treated rats may be due to a direct DX activity on these cells, e.g., by promoting osteoclast apoptosis, as reported recently (20). The low cost and easy access to DX in clinical practice justify additional studies on the efficacy of DX as an adjunct therapy in noninfectious bone resorbing diseases.

Acknowledgments

The authors would like to thank José Ivan Rodrigues de Souza, Federal University of Ceará, for technical assistance.

References

1. Vernillo AT, Ramamurthy NS, Golub LM & Rifkin BR (1994). The antimicrobial properties of tetracycline for the treatment of periodontal disease. *Current Opinion in Periodontology*, 2: 111-118.
2. Golub LM, Ciancio S, Ramamurthy NS, Leung M & McNamara TF (1990). Low-dose doxycycline therapy: Effect on gingival and crevicular fluid collagenase in humans. *Journal of Periodontal Research*, 25: 321-330.
3. Ashley RA (1999). Clinical trials of a matrix metalloproteinase inhibitor in human periodontal disease. SDD clinical research team. *Annals of the New York Academy of Sciences*, 30: 335-346.
4. Page R (1991). The role of inflammatory mediators in the pathogenesis of periodontal disease. *Journal of Periodontal Research*, 26: 230-242.
5. Grevstad HJ (1993). Doxycycline prevents root resorption and alveolar bone loss in rats after periodontal surgery. *Scandinavian Journal of Dental Research*, 101: 287-291.
6. Ramamurthy NS, Schroeder KL, McNamara TF, Gwinnett AJ, Evans RT, Bosko C & Golub LM (1998). Root-surface caries in rats and humans: inhibition by a non-antimicrobial property of tetracyclines. *Advanced Dentistry Research*, 12: 43-50.
7. Walker C, Thomas J, Nango S, Lennon J, Wetzel J & Powala C (2000). Long-term treatment with subantimicrobial dose doxycycline exerts no antibacterial effect on the subgingival microflora associated with adult periodontitis. *Journal of Periodontology*, 71: 1465-1471.
8. Thomas J, Walker C & Bradshaw M (2000). Long-term use of subantimicrobial dose doxycycline does not lead to changes in antimicrobial susceptibility. *Journal of Periodontology*, 71: 1472-1483.
9. Caton JG, Ciancio SG, Blieden TM, Bradshaw M, Crout RJ, Hefti AF, Massaro JM, Polson AM, Thomas J & Walker C (2000). Treatment with subantimicrobial dose doxycycline improves the efficacy of scaling and root planing in patients with adult periodontitis. *Journal of Periodontology*, 71: 521-532.
10. Sallay K, Sanavi F, Pham P, Behling UH & Nowotny A (1982). Alveolar bone destruction in the immunosuppressed rat. *Journal of Periodontal Research*, 17: 263-274.
11. Bezerra MM, Lima V, Alencar VBM, Brito GAC, Ribeiro RA & Rocha FAC (2000). Selective cyclooxygenase-2 inhibition prevents alveolar bone loss in experimental periodontitis in rats. *Journal of Periodontology*, 71: 1009-1014.
12. Crawford JM, Taubman MA & Smith DJ (1978). The natural history of periodontal bone loss in germfree and gnotobiotic rats infected with periodontopathic microorganisms. *Journal of Periodontal Research*, 13: 316-325.
13. Golub LM, Lee H-M, Lehrer G, Nemiroff A, McNamara TF, Kaplan R & Ramamurthy NS (1983). Minocycline reduces gingival collagenolytic activity during diabetes: preliminary observations and a proposed new mechanism of action. *Journal of Periodontal Research*, 18: 516-526.
14. Grevstad HJ & Boe OE (1995). Effect of doxycycline on surgically induced osteoclast recruitment in the rat. *European Journal of Oral Sciences*, 103: 156-159.
15. Golub LM, Wolff M, Steven R, Lee H-M, Leung M & Payonic GS (1994). Treating periodontal diseases. *Journal of the American Dental Association*, 125: 163-171.
16. Chang CY & Yamad S (2000). Evaluation of the effect of a 25% doxycycline-loaded biodegradable membrane for guided tissue regeneration. *Journal of Periodontology*, 71: 1086-1093.
17. Cummings GR & Torabinejad M (2001). Effect of systemic doxycycline on alveolar bone loss after periradicular surgery. *Journal of Endodontics*, 26: 325-327.
18. Ramamurthy NS, McClain AS, Pirila E, Maisi P, Salo T, Kucine A, Sorsa T, Vishram F & Golub LM (1999). Wound healing in aged normal and ovariectomized rats: effect of chemically modified doxycycline (CMT-8) on MMP expression and collagen synthesis. *Annals of the New York Academy of Sciences*, 30: 720-723.
19. Llanaveras A, Ramamurthy NS, Heikkila P, Tereonen O, Salo T, Rifkin BR, Ryan ME, Golub LM & Sorsa T (2001). A combination of a chemically modified doxycycline and a bisphosphonate synergistically inhibits endotoxin-induced periodontal breakdown in rats. *Journal of Periodontology*, 72: 1069-1077.
20. Bettany JT, Peet NM, Wolowacz RG, Skerry TM & Grabowski PS (2000). Tetracyclines induce apoptosis in osteoclasts. *Bone*, 27: 75-80.