

Decreased left temporal lobe volume of panic patients measured by magnetic resonance imaging

R.R. Uchida¹, C.M. Del-Ben¹,
A.C. Santos², D. Araújo¹,
J.A. Crippa¹, F.S. Guimarães³
and F.G. Graeff¹

Departamentos de ¹Neurologia, Psiquiatria e Psicologia Médica,
²Clínica Médica, and ³Farmacologia, Faculdade de Medicina de Ribeirão Preto,
Universidade de São Paulo, Ribeirão Preto, SP, Brasil

Abstract

Reported neuroimaging studies have shown functional and morphological changes of temporal lobe structures in panic patients, but only one used a volumetric method. The aim of the present study was to determine the volume of temporal lobe structures in patients with panic disorder, measured by magnetic resonance imaging. Eleven panic patients and eleven controls matched for age, sex, handedness, socioeconomic status and years of education participated in the study. The mean volume of the left temporal lobe of panic patients was 9% smaller than that of controls ($t_{21} = 2.37$, $P = 0.028$). In addition, there was a trend (P values between 0.05 and 0.10) to smaller volumes of the right temporal lobe (7%, $t_{21} = 1.99$, $P = 0.06$), right amygdala (8%, $t_{21} = 1.83$, $P = 0.08$), left amygdala (5%, $t_{21} = 1.78$, $P = 0.09$) and left hippocampus (9%, $t_{21} = 1.93$, $P = 0.07$) in panic patients compared to controls. There was a positive correlation between left hippocampal volume and duration of panic disorder ($r = 0.67$, $P = 0.025$), with recent cases showing more reduction than older cases. The present results show that panic patients have a decreased volume of the left temporal lobe and indicate the presence of volumetric abnormalities of temporal lobe structures.

Key words

- Panic disorder
- Temporal lobe
- Magnetic resonance imaging
- Volumetric analysis

Correspondence

F.G. Graeff
Pós-Graduação em Saúde Mental
FMRP, USP
Av. 9 de Julho, 980
14025-000 Ribeirão Preto, SP
Brasil
Fax: +55-16-635-0713
E-mail: fggraeff@keynet.com.br

Research supported by FAPESP
(No. 98/10639-7). F.G. Graeff was
supported by research fellowships
from FAEPA (Ribeirão Preto) and
CNPq (No. 300577/1980-0).
J.A. Crippa is supported by a
CNPq fellowship (No. 200984/01).

Received November 13, 2002
Accepted April 17, 2003

Panic disorder is a psychiatric condition that affects nearly 3% of the general population (1), with a higher risk among first-degree relatives of individuals with panic disorder (2).

Different theoretical models have implicated brain structures localized in the temporal lobes, such as the amygdala and the hippocampus, in the neural circuitry underlying panic disorder (3-5). In agreement, several neuroimaging studies have documented functional or morphological changes in the temporal lobes of panic patients. Briefly, functional studies with positron emission tomog-

raphy and single-photon emission computed tomography have revealed asymmetrical activation of parahippocampal and hippocampal regions (6,7), while qualitative morphological studies using magnetic resonance imaging (MRI) have demonstrated a higher incidence of anatomical abnormalities in the brain of panic patients compared to healthy controls, particularly in the temporal lobes (8-10).

The only quantitative MRI study performed so far reported that panic patients had a smaller temporal lobe volume, bilaterally, than controls, although there was no

significant difference in hippocampal volume between the two groups (11). Nevertheless, a limitation of the cited study was that the head of the hippocampus, the amygdala and the anterior portion of the temporal lobe were not measured.

As a consequence, the aim of the present investigation was to use a volumetric MRI method to compare the volumes of the temporal lobes of panic patients and healthy controls, focusing particularly on the amygdala and the hippocampus.

The Ethics Committee of the Hospital das Clínicas de Ribeirão Preto, Faculdade de Medicina de Ribeirão Preto, Universidade de São Paulo, approved the present study. All subjects signed an informed consent statement.

Eleven patients with a current or past history of panic disorder were selected according to Diagnostic Statistical Manual IV (DSM-IV) criteria (12). All patients were submitted to the Structured Clinical Interview for DSM-IV (SCID-IV) (13), translated into Portuguese and adapted (14).

Patients with comorbid psychiatric disorders were excluded from the study, with the exception of major depression and dysthymia, which are often associated with panic disorder. No subject in either group had a history of head trauma, electroconvulsive shock, major medical illness or substance abuse. The selected patients were paired with 11 healthy subjects matched for sex, age, socioeconomic status, years of education and handedness.

Statistical analysis was performed using the statistical package SPSS for Windows. The parametric Student *t*-test and the non-parametric Mann-Whitney and chi-square tests were used to analyze demographic and clinical data. The *t*-test was also used to analyze the volumetric data.

All subjects were right-handed, as assessed by the Edinburgh Inventory (15). Panic patients were 3 males and 8 females and controls 5 males and 6 females. The age (mean \pm SD) of panic patients was $36.86 \pm$

11.9 years and the age of controls was 34.27 ± 10.2 years. Panic patients had 10.45 ± 4.34 years of education and controls, 9.18 ± 2.92 . The mean socioeconomic status was 2.40 ± 0.80 for the panic disorder group and 2.00 ± 0.77 for the control group, according to the Brazilian socioeconomic classification criteria (16), with a lower figure indicating a higher socioeconomic level. There was no significant difference between groups for any of these parameters.

Among the patients, the first panic attack occurred when they were 28.36 ± 9.54 years old, and the duration of panic disorder was 8.04 ± 6.65 years. Eight of the 11 patients were receiving pharmacological treatment at the time of evaluation: four were taking a selective serotonin reuptake inhibitor, associated with a benzodiazepine in one case; three were taking clomipramine, and the remaining patient, a benzodiazepine alone. Six patients (54%) met the criteria for panic disorder with agoraphobia. Five patients had a history of major depression and one met the criteria for dysthymia.

T₁-weighted images were acquired on the sagittal plane from 0.97-mm thick slices with a 1.5 Tesla magnetic resonance camera (Magnetom Vision, Siemens, Erlangen, Germany), using a three-dimensional fast low angle shot protocol (TE = 4 ms, TR = 9.7 ms, flip angle = 12°, number of excitations = 1, field of view = 25.6 cm, matrix = 256 x 256). The images were reformatted using the multiplanar reformatting protocol for the coronal plane.

For volumetric evaluation, 2-mm thick three-dimensional images perpendicular to the main axis of the hippocampus with no slice gap were reformatted on the coronal plane. The number of slices per subject was 32.09 ± 1.57 (mean \pm SD) for controls and 31.82 ± 1.45 for panic patients.

The anatomical landmarks were defined according to Watson et al. (17). The temporal pole was defined as the portion of the temporal lobe anterior to the plane delimited

by the end of the temporal sulcus and the beginning of the entorhinal sulcus. Rostrally, the temporal lobe was measured up to the last slice in which the lamina quadrigemina was visible. A straight line from the ventral-most point of the circular sulcus of the insula to the dorsal-most point of the entorhinal sulcus defined the dorsomedial border of the temporal lobe. Therefore, the temporal lobe included the amygdala, the hippocampus and the inferior horn of the lateral ventricle. The rostral limit of the amygdala was defined by the end of the lateral sulcus and the beginning of the entorhinal sulcus, the medial limit by the entorhinal cortex, the ventrolateral border by the neighboring white matter and the ventral horn of the lateral ventricle, and the dorsal limit by a straight line from the dorsolateral optical tract to the bottom of the circular sulcus of the insula. The inferior horn of the lateral ventricle was used to separate the posterior amygdala from the head of the hippocampus. The ventral limit of the hippocampus was the angle determined by the medial subiculum and the parahippocampal gyrus. The body of the hippocampus included the subiculum, dentate gyrus and alveus, in addition to the hippocampus proper. Caudally, the hippocampus was measured up to the last slice in which the lamina quadrigemina was visible.

A single rater (R.R.U.), blind to the subject's identity, delineated the structures manually using the Image J software (Scion Corp., Frederick, MD, USA). The volumes were calculated by multiplying the area by the slice thickness. Normalized values were obtained by dividing the absolute value by the supratentorial volume. Supratentorial volume was defined as the volume of parenchymal structures above the tentorium cerebelli in all slices in which the hippocampal formation was measured. The lateral ventricles and the third ventricle were included in the supratentorial volume.

To assess inter-rater reliability of volumetric measures, seven measures obtained

by R.R.U. during training were compared with measures made by a neuroradiologist well trained in volumetric brain analysis (D.A.). The intraclass correlation coefficients were: 0.87 for the temporal poles, 0.65 for the temporal lobes, 0.75 for the amygdala, 0.84 for the hippocampus, and 0.96 for the supratentorial volume.

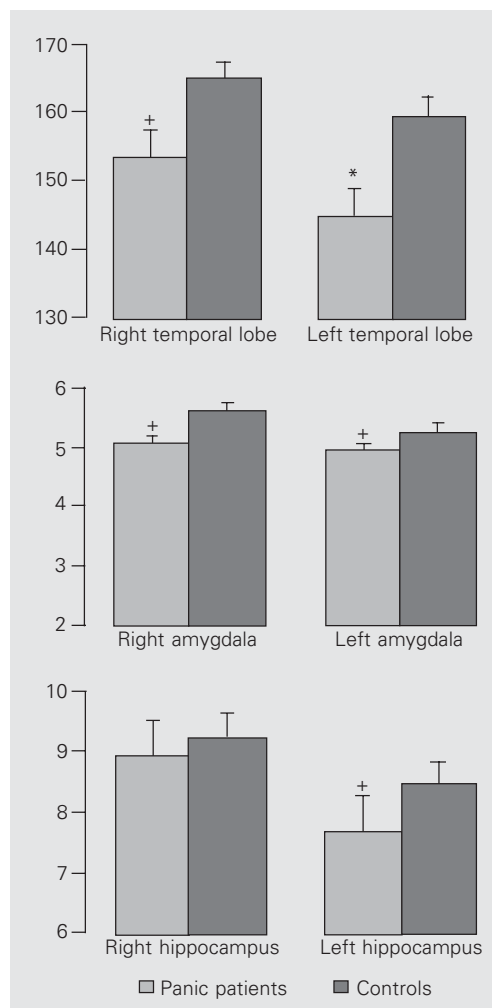
Intra-rater reliability was determined using the intraclass correlation coefficients in seven repeated measures performed by R.R.U., yielding the following results: 0.97 for the right temporal pole, 0.97 for the left temporal pole, 0.91 for the right temporal lobe, 0.97 for the left temporal lobe, 0.97 for the right amygdala, 1.00 for the left amygdala, 1.00 for the right hippocampus, 0.93 for the left hippocampus, and 0.99 for the supratentorial volume.

The main finding of the present study was that the left temporal lobe of panic patients was significantly smaller than that of controls ($t_{21} = 2.37$, $P = 0.028$). The present results also showed a nearly significant trend for smaller volumes of the right temporal lobe ($t_{21} = 1.99$, $P = 0.06$), right amygdala ($t_{21} = 1.83$, $P = 0.082$), left amygdala ($t_{21} = 1.78$, $P = 0.09$) and left hippocampus ($t_{21} = 1.93$, $P = 0.07$) in panic patients compared to controls. These results are illustrated in Figure 1.

In addition, a statistically significant positive correlation was found between left hippocampal volume and duration of panic disorder ($r = 0.67$, $P = 0.025$).

There was no significant difference between groups in the volume of the right temporal pole ($t_{21} = 0.03$, $P = 0.97$), the left temporal pole ($t_{21} = 0.71$, $P = 0.48$) and the right hippocampus ($t_{21} = 1.0$, $P = 0.32$). The smaller volume of the left temporal lobe and the trend to a smaller right temporal lobe found in the present study are consistent with previously reported results using quantitative MRI (11). It is worth remarking that the present measurements were more precise than those of the former study, in which

Figure 1. Volumetric changes in panic patients. Data are reported as ratios: volume of the structure divided by the supratentorial volume and multiplied by 1000. Columns indicate the mean volume and vertical bars the SEM for 11 patients or 11 controls. Comparisons between groups: * $P < 0.05$ (Student t -test); $+0.05 \leq P \leq 0.10$ (Student t -test).



the temporal lobe was measured in only five slices, 3 mm wide, anterior to the superior colliculus.

The present results also suggested a trend to a smaller volume of the right and left amygdala as well as of the left hippocampus in panic patients compared to controls. These findings add to reported qualitative morphological (8-10) and functional neuroimaging studies (6,7), indicating that abnormalities in temporal lobe structures are frequently found in panic disorder patients.

A reduced hippocampal volume has also been reported in major depression (18) and post-traumatic stress disorder (19). This reduction has been attributed to higher plasma levels of cortisol, due to repeated or persistent stress (20). However, this explanation does not seem to apply to the present findings, because there was a positive correlation between hippocampal volume and time course of panic disorder, that is, recent cases showed more hippocampal reduction than older cases. So far, no explanation can be proposed for this puzzling result. In any case, this correlation indicates that the volume reductions shown by the present results are less likely to be due to comorbid current or past depressive disorders.

References

- Kessler RC, McGonagle KA, Zhao S, Nelson CB, Hughes M, Eshleman S, Wittchen HU & Kendler KS (1994). Lifetime and 12-month prevalence of DSM-III-R psychiatric disorders in the United States. Results from the National Comorbidity Survey. *Archives of General Psychiatry*, 51: 8-19.
- Dick CL, Bland RC & Newman SC (1994). Panic disorder. *Acta Psychiatrica Scandinavica*, 89 (Suppl 376): 45-63.
- Deakin JWF & Graeff FG (1991). 5-HT and mechanisms of defense. *Journal of Psychopharmacology*, 5: 305-315.
- Gray JA & MacNaughton N (2000). *The Neuropsychology of Anxiety. An Enquiry into the Functions of the Septo-Hippocampal System*. 2nd edn. Oxford University Press, Oxford, UK.
- Gorman JM, Kent JN, Sullivan G & Coplan JD (2000). Neuroanatomical hypothesis of panic disorder, revised. *American Journal of Psychiatry*, 157: 493-505.
- Reiman EM, Reichle ME, Robins E, Butler FK, Herscovitch P, Fox P & Perlmutter J (1986). The application of positron emission tomography to the study of panic disorder. *American Journal of Psychiatry*, 143: 469-477.
- De Cristofaro MT, Sessarego A, Pupi A, Biondi F & Faravelli C (1993). Brain perfusion abnormalities in drug-naive, lactate-sensitive panic patients: a SPECT study. *Biological Psychiatry*, 33: 505-512.
- Dantendorfer K, Prayer D, Kramer J et al. (1996). High frequency of EEG and MRI brain abnormalities in panic disorder. *Psychiatry Research*, 68: 41-53.
- Ontiveros A, Fontaine R, Breton G, Elie R, Fontaine S & Dery R (1989). Correlation of severity of panic disorder and neuroanatomical changes on magnetic resonance imaging. *Journal of Neuropsychiatry and Clinical Neurosciences*, 1: 404-408.
- Fontaine R, Breton G, Dery R, Fontaine S & Elie R (1990). Temporal lobe abnormalities in panic disorder: an MRI study. *Biological Psychiatry*, 27: 304-310.
- Vythilingam M, Anderson ER, Goddard A, Woods SW, Staib LH, Charney DS & Bremner JD (2000). Temporal lobe volume in panic disorder - a quantitative magnetic resonance imaging study. *Psychiatry*, 63: 469-477.

- chiatry Research*, 99: 75-82.
12. American Psychiatric Association (1994). *Diagnostic and Statistical Manual of Mental Disorders*. 4th edn., revised. APA Press, Washington, DC, USA.
 13. First MB, Spitzer RL, Williams JBW & Gibbon M (1997). *Structured Clinical Interview for DSM-IV (SCID)*. APA Press, Washington, DC, USA.
 14. Del-Ben CM, Vilela JAA, Crippa JA, Hallak JEC, Labate CM & Zuardi AW (2001). Confiabilidade da "Entrevista Clínica Estruturada para o DSM IV - Versão Clínica" traduzida para o português. *Revista Brasileira de Psiquiatria*, 23: 156-159.
 15. Oldfield RC (1971). The assessment and analysis of handedness: The Edinburgh Inventory. *Neuropsychologia*, 9: 97-113.
 16. Associação Brasileira dos Institutos de Pesquisa de Mercado (1997). *Critério de Classificação Sócio-Econômica, Brasil*. ABIPEME, São Paulo, SP, Brazil.
 17. Watson C, Andermann F, Gloor P, James-Gotman M, Peters T, Evans A, Olivier A, Melanson D & Leroux G (1992). Anatomic basis of amygdaloid and hippocampal volume measurement by magnetic resonance imaging. *Neurology*, 42: 1743-1750.
 18. Sheline Y, Sanghavi M, Mintun M & Gado M (1999). Depression duration but not age predicts hippocampal volume loss in medically healthy women with recurrent major depression. *Journal of Neuroscience*, 19: 5034-5043.
 19. Bremner JD, Randall P, Scott TM, Bronen RA, Seibyl JP, Southwick SM, Delaney RA, MacCarthy G, Charney DS & Innis RB (1995). MRI-based measurement of hippocampal volume in patients with combat-related posttraumatic stress disorder. *American Journal of Psychiatry*, 152: 973-981.
 20. Sapolsky (1996). Why stress is bad for your brain. *Science*, 273: 749-750.