

Effect of a selective nonsteroidal anti-inflammatory inhibitor of cyclooxygenase-2 on the small bowel of rats

A.Z.A. Leite¹, A.M. Sipahi¹,
A.O.M.C. Damiao¹,
A.T. Garcez²,
C.A. Buchpiguel²,
F.P. Lopasso¹,
M.L.L. Lordello¹,
C.L.O. Agostinho¹
and A.A. Laudanna¹

¹Laboratório de Investigação Médica (LIM 07), Departamento de Gastroenterologia, and ²Departamento de Radiologia, Hospital das Clínicas, Faculdade de Medicina, Universidade de São Paulo, São Paulo, SP, Brasil

Abstract

The pathogenesis of nonsteroidal anti-inflammatory drug (NSAID) enteropathy is a complex process involving the uncoupling of mitochondrial oxidative phosphorylation and inhibition of cyclooxygenase (COX). Rofecoxib, a selective inhibitor of COX-2, has shown less gastric damage, but the same beneficial effect is not clear in the case of the small bowel. Fifty-seven male Wistar rats (250-350 g) were divided into three groups (N = 19 each) to evaluate the effect of this NSAID on the rat intestine. The groups received 2.5 mg/kg rofecoxib, 7.5 mg/kg indomethacin or water with 5% DMSO (control) given as a single dose by gavage 24 h before the beginning of the experiment. A macroscopic score was used to quantify intestinal lesions and intestinal permeability was measured using [⁵¹Cr]-ethylenediaminetetraacetic acid ([⁵¹Cr]-EDTA). The extent of intestinal lesion, indicated by a macroscopic score, was significantly lower when rofecoxib was administered compared to indomethacin (rofecoxib = 0.0 vs indomethacin = 63.6 ± 25.9; P < 0.05) and did not differ from control. The intestinal permeability to [⁵¹Cr]-EDTA was significantly increased after indomethacin (control = 1.82 ± 0.4 vs indomethacin = 9.12 ± 0.8%; P < 0.0001), but not after rofecoxib, whose effect did not differ significantly from control (control = 1.82 ± 0.4 vs rofecoxib = 2.17 ± 0.4%; ns), but was significantly different from indomethacin (indomethacin = 9.12 ± 0.8 vs rofecoxib = 2.17 ± 0.4%; P < 0.001). In conclusion, the present data show that rofecoxib is safer than indomethacin in rats because it does not induce macroscopic intestinal damage or increased intestinal permeability.

Key words

- Intestinal permeability
- Enteropathy
- Nonsteroidal anti-inflammatory drugs
- Indomethacin
- Rofecoxib
- COX-2 inhibitor

Correspondence

A.Z.A. Leite
Disciplina de Gastroenterologia Clínica
Av. Dr. Enéas de Carvalho Aguiar, 255
ICHC, 9º andar, sala 9159
05403-900, São Paulo, SP
Brasil
Fax: +55-11-3082-7599
E-mail: azaleite@uol.com.br

Publication supported by FAPESP.

Received February 18, 2003

Accepted December 8, 2003

Nonsteroidal anti-inflammatory drugs (NSAID) are widely used due to their analgesic, anti-inflammatory and antipyretic properties. The main concern about these drugs is the frequency and severity of their digestive

side effects involving the entire gastrointestinal tract. Fecal calprotectin is altered in 44% (1) of patients taking NSAID, and scintigrams suggest small intestine inflammation in 42%, but when fecal excretion of [¹¹¹In]-

labelled leukocytes was used as a measure of inflammation up to 67% (2) of patients were found to have enteropathy. Similarly, intestinal lesions were detected by enteroscopy (3) in 66% of patients and in a *post-mortem* study, the prevalence of nonspecific intestinal ulceration was 13.5% (4). The intestinal lesions caused by NSAID can mimic inflammatory bowel disease (5) and may lead to chronic bleeding, protein loss, strictures, diverticulitis, appendicitis, internal fistulas, and relapse of inflammatory bowel disease.

The pathogenesis of NSAID enteropathy is complex and not completely understood. There are two main pathogenic mechanisms. The first involves specific biochemical damage to mitochondria (6-8), with uncoupling of the oxidative phosphorylation reaction, which increases intestinal permeability and calcium release into cytosol, which in turn cause secondary biochemical damage (9,10). The second, and more controversial, mechanism involves the inhibition of cyclooxygenase-1 and/or -2 (COX-1, COX-2) and its products (prostaglandins). However, some studies have shown that COX inhibition is not involved (11,12), while another study claimed that this inhibition is the pivotal event (13).

Early evidence obtained with selective COX-2 inhibitors such as nimesulide (14), celecoxib (15) and rofecoxib (16) suggests that they are indeed associated with significantly improved gastrointestinal tolerability. However, it is not clear whether these agents are less toxic to the small bowel.

Thus, the aim of the present study was to assess the effect of rofecoxib, a selective COX-2 inhibitor, on the small intestine by assessing intestinal permeability and macroscopic damage.

Fifty-seven male Wistar rats (250-350 g) were individually housed in metabolic cages with free access to water and standard laboratory rat chow. The animals were divided into three groups (N = 19 in each group). The groups received water with 5% dimethylsulfoxide (DMSO, control), 7.5 mg/kg indo-

methacin, or 2.5 mg/kg rofecoxib, given as a single dose by gavage 24 h before the beginning of the experiment. The drug was initially dissolved in DMSO and then diluted in water so that the final concentration of DMSO was less than 5% and adjusted to pH 7.4. After drug administration, the rats had free access to standard rat food and water.

Several methods can be used to assess intestinal permeability. The dual sugar method uses a disaccharide and a monosaccharide, which permit the assessment of the paracellular and transcellular pathway without a radioactive probe. The disadvantage of this method is the necessity of more sophisticated equipment, such as a mass spectrophotometer or high performance liquid chromatograph.

In the present study, the [^{51}Cr]-ethylenediaminetetraacetic acid ([^{51}Cr]-EDTA) technique was used to measure the changes of intestinal permeability induced by NSAID (17,18) that basically alter the paracellular pathway. Intestinal permeability was assessed on the basis of urinary [^{51}Cr]-EDTA excretion (10,19) after its oral administration. The rats were given 5 μCi [^{51}Cr]-EDTA in 0.5 ml distilled water by gavage, followed by 5 ml water. The animals were then placed in individual metabolic cages with free access to tap water and food for 5 h for collection of urine. The rats were sacrificed by lethal injection (50 mg) of ketamine (Ketalar[®]), laparotomy was performed and the bladder was emptied by puncture. The total 5-h radioactivity excreted into the urine was determined. Data are reported as fractional excretion of the radioactive marker.

The small intestine was gently removed, the intestinal mucosa was exposed by cutting through the contra-mesenteric side, laid out on a piece of cork, and dried with Evan's blue to improve assessment of the macroscopic score 29 h after drug administration, using a stereotactic microscope at 25-50 magnification. The use of a score system is crucial since with the progression of intestinal

damage the small ulcers coalesce and form large longitudinal ulcerations, so that the simple count of the number of ulcers does not reflect the actual intestinal damage. In order to correct this bias, a macroscopic score was used to quantify intestinal lesions as previously described (19). The score was based on the number of mucosal ulcers and the largest diameter of the ulcers as follows: a) <1 mm; b) ≥ 1 and <3 mm; c) ≥ 3 and <5 mm; d) ≥ 5 and <10 mm; e) ≥ 10 mm, multiplied by a factor of 1, 3, 5, 10 and 20, respectively. The total score was calculated as the sum of the values obtained for each item. Results are reported as means \pm SEM. Statistical differences in macroscopic score and intestinal permeability among groups were assessed by one-way analysis of variance and Bonferroni's multiple comparison test.

As shown in Figure 1, the macroscopic scores were significantly different among the three groups, i.e., controls, indomethacin and rofecoxib ($P < 0.0001$). Rofecoxib did not induce intestinal damage. Using a discriminatory test it was possible to show that the macroscopic score was significantly lower when rofecoxib was administered compared to indomethacin (rofecoxib = 0.0 vs indomethacin = 63.6 ± 25.9 , $P < 0.05$) and did not differ from the control group (rofecoxib = 0 vs control = 0, ns).

The intestinal permeability to [^{51}Cr]-EDTA was significantly different among the three groups ($P < 0.0001$; Figure 2). Intestinal permeability was significantly increased after indomethacin (controls = 1.82 ± 0.4 vs indomethacin = $9.12 \pm 0.8\%$, $P < 0.0001$). When rofecoxib was given, intestinal permeability did not differ significantly from controls (controls = 1.82 ± 0.4 vs rofecoxib = $2.17 \pm 0.4\%$, ns), but was significantly different from indomethacin alone (indomethacin = 9.12 ± 0.8 vs rofecoxib = $2.17 \pm 0.4\%$, $P < 0.001$).

When an NSAID is prescribed the intestinal damage induced by these drugs is rarely considered, although the intestine is involved

in a large number of complications related to this class of drugs. The present study points out the important side effects of NSAID, and demonstrates that it is possible to reduce the risk of intestinal damage by choosing a less toxic NSAID, although this involves a higher cost of treatment.

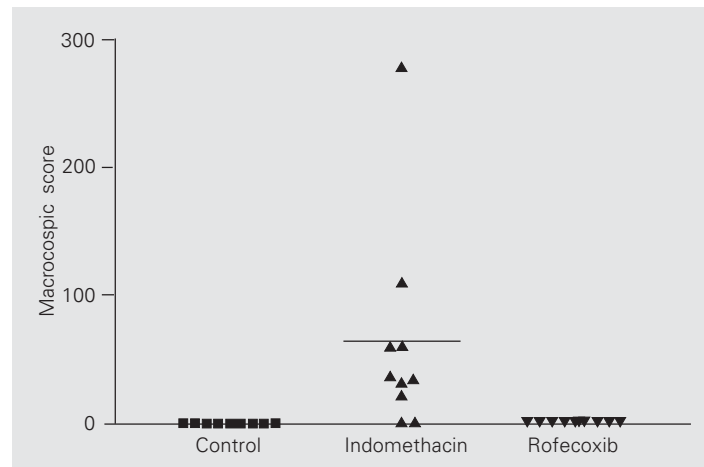


Figure 1. Scatter diagram showing individual and mean intestinal macroscopic scores for control rats (N = 10) and rats treated by gavage with a single dose of 7.5 mg/kg indomethacin (N = 10) and 2.5 mg/kg rofecoxib (N = 10). The horizontal line is the mean. $P < 0.05$ for control vs indomethacin and rofecoxib vs indomethacin. Statistical differences in macroscopic scores among groups were assessed by one-way analysis of variance and Bonferroni's multiple comparison test.

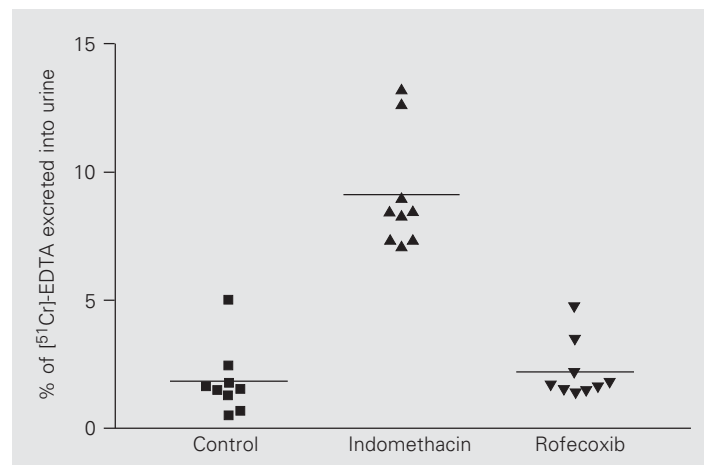


Figure 2. Scatter diagram showing individual mean percent [^{51}Cr]-EDTA excreted into urine for control rats (N = 9) and rats treated by gavage with a single dose of 7.5 mg/kg indomethacin (N = 9) and 2.5 mg/kg rofecoxib (N = 9). The horizontal lines indicate the mean. $P < 0.05$ for control vs indomethacin and rofecoxib vs indomethacin. Statistical differences in intestinal permeability among groups were assessed by one-way analysis of variance and Bonferroni's multiple comparison test.

In agreement with the literature, we showed that indomethacin, a non-selective COX inhibitor, can induce significant damage in the small bowel, as demonstrated by an increase in both the intestinal permeability to ^{51}Cr -EDTA and the macroscopic score. Nevertheless, we also demonstrated that an equivalent dose of a selective COX-2 inhibitor, rofecoxib, did not disrupt the intestinal barrier as determined on the basis of the same parameters, revealing important differences in the intestinal tolerability of these drugs, which is probably related to two fundamental properties of NSAID: the pK

and the inhibition of COX. Rofecoxib is a non-acid NSAID, which does not uncouple the oxidative phosphorylation either *in vitro* or *in vivo* (8,15) and does not reduce prostaglandin levels in the gut, since COX-2 is not constitutively expressed in the normal gut (20), a fact that makes it less toxic to the gastrointestinal tract in general.

We showed here that rofecoxib is safer than indomethacin for the small bowel because it does not induce macroscopic intestinal damage or disrupt intestinal permeability, and therefore should be preferred to indomethacin and other common NSAID.

References

- Tibble JA, Sigthorsson G, Foster R, Scott D, Fagerhol MK, Roseth A & Bjarnason I (1999). High prevalence of NSAID enteropathy as shown by a simple fecal test. *Gut*, 45: 362-366.
- Rooney PJ, Jenkins RT, Smith KM & Coates G (1986). ^{111}In -labelled polymorphonuclear leucocyte scans in rheumatoid arthritis - an important clinical cause of false positive results. *British Journal of Rheumatology*, 25: 167-170.
- Morris AJ, Madhok R, Sturrock RD, Capell HA & MacKenzie JF (1991). Enteroscopic diagnosis of small bowel ulceration in patients receiving non-steroidal anti-inflammatory drugs. *Lancet*, 337: 520 (Abstract).
- Allison MC, Howatson AG, Torrance CJ, Lee FD & Russell RI (1992). Gastrointestinal damage associated with the use of nonsteroidal antiinflammatory drugs. *New England Journal of Medicine*, 327: 749-754.
- Lengeling RW, Mitros FA, Brennan JA & Schulze KS (2003). Ulcerative ileitis encountered at ileo-colonoscopy: Likely role of nonsteroidal agents. *Clinical Gastroenterology and Hepatology*, 1: 160-169.
- Somasundaram S, Hayllar H, Rafi S, Wrigglesworth JM, MacPherson AJ & Bjarnason I (1995). The biochemical basis of non-steroidal anti-inflammatory drug-induced damage to the gastrointestinal tract: a review and a hypothesis. *Scandinavian Journal of Gastroenterology*, 30: 289-299.
- Mingatto FE, Santos AC, Uyemura SA, Jordani MC & Curti C (1996). *In vitro* interaction of nonsteroidal anti-inflammatory drugs on oxidative phosphorylation of rat kidney mitochondria: respiration and ATP synthesis. *Archives of Biochemistry and Biophysics*, 334: 303-308.
- Mahmud T, Rafi SS, Scott DL, Wrigglesworth JM & Bjarnason I (1996). Nonsteroidal antiinflammatory drugs and uncoupling of mitochondrial oxidative phosphorylation. *Arthritis and Rheumatism*, 39: 1998-2003.
- Bjarnason I, Williams P, So A, Zanelli GD, Levi AJ, Gumpel JM, Peters TJ & Ansell B (1984). Intestinal permeability and inflammation in rheumatoid arthritis: effects of non-steroidal anti-inflammatory drugs. *Lancet*, 2: 1171-1174.
- Bjarnason I, Smethurst P, Levi AJ & Peters TJ (1985). Intestinal permeability to ^{51}Cr -EDTA in rats with experimentally induced enteropathy. *Gut*, 26: 579-585.
- Bjarnason I, Williams P, Smethurst P, Peters TJ & Levi AJ (1986). Effect of non-steroidal anti-inflammatory drugs and prostaglandins on the permeability of the human small intestine. *Gut*, 27: 1292-1297.
- Mahmud T, Somasundaram S, Sigthorsson G et al. (1998). Enantiomers of flurbiprofen can distinguish key pathophysiological steps of NSAID enteropathy in the rat. *Gut*, 43: 775-782.
- Tanaka A, Hase S, Miyazawa T & Takeuchi K (2002). Up-regulation of cyclooxygenase-2 by inhibition of cyclooxygenase-1: a key to nonsteroidal anti-inflammatory drug-induced intestinal damage. *Journal of Pharmacology and Experimental Therapeutics*, 300: 754-761.
- Shah AA, Thjodleifsson B, Murray FE et al. (2001). Selective inhibition of COX-2 in humans is associated with less gastrointestinal injury: a comparison of nimesulide and naproxen. *Gut*, 48: 339-346.
- Tibble JA, Sigthorsson G, Foster R & Bjarnason I (2000). Comparison of the intestinal toxicity of celecoxib, a selective COX-2 inhibitor, and indomethacin in the experimental rat. *Scandinavian Journal of Gastroenterology*, 35: 802-807.
- Sigthorsson G, Crane R, Simon T, Hoover M, Quan H, Bolognese J & Bjarnason I (2000). COX-2 inhibition with rofecoxib does not increase intestinal permeability in healthy subjects: a double blind crossover study comparing rofecoxib with placebo and indomethacin. *Gut*, 47: 527-532.
- Ford J, Martin SW & Houston JB (1995). Assessment of intestinal permeability changes induced by nonsteroidal anti-inflammatory drugs in the rat. *Journal of Pharmacological and Toxicological Methods*, 34: 9-16.
- Suenaert P, Bulteel V, Den Hond E, Geypens B, Monsuur F, Luybaerts A, Ghooys Y & Rutgeerts P (2003). *In vivo* influence of nicotine on human basal and NSAID-induced gut barrier function. *Scandinavian Journal of Gastroenterology*, 38: 399-408.
- Leite AZ, Sipahi AM, Damiao AO et al. (2001). Protective effect of metronidazole on uncoupling mitochondrial oxidative phosphorylation induced by NSAID: a new mechanism. *Gut*, 48: 163-167.
- Reuter BK, Asfaha S, Buret A, Sharkey KA & Wallace JL (1996). Exacerbation of inflammation-associated colonic injury in rat through inhibition of cyclooxygenase-2. *Journal of Clinical Investigation*, 98: 2076-2085.