

Early effects of estrogen on the rat ventral prostate

M. García-Flórez¹,
C.A. Oliveira²
and H.F. Carvalho¹

¹Departamento de Biologia Celular, Instituto de Biologia,
Universidade Estadual de Campinas, Campinas, SP, Brasil

²Departamento de Reprodução Animal, Faculdade de Medicina
Veterinária e Zootecnia, Universidade de São Paulo, São Paulo, SP, Brasil

Abstract

Complex interactions between androgen and estrogen (E2) regulate prostatic development and physiology. We analyzed the early effects of a high single dose of E2 (25 mg/kg body weight) and castration (separately or combined) on the adult 90-day-old male Wistar rat ventral prostate. Androgen levels, prostate weight, and the variation in the relative and absolute volume of tissue compartments and apoptotic indices were determined for 7 days. Castration and exogenous E2 markedly reduced ventral prostate weight (about 50% of the control), with a significant reduction in the epithelial compartment and increased stroma. The final volume of the epithelium was identical at day 7 for all treatments (58.5% of the control). However, E2 had an immediate effect, causing a reduction in epithelial volume as early as day 1. An increase in smooth muscle cell volume resulted from the concentration of these cells around the regressing epithelium. The treatments resulted in differential kinetics in epithelial cell apoptosis. Castration led to a peak in apoptosis at day 3, with 5% of the epithelial cells presenting signs of apoptosis, whereas E2 caused an immediate increase (observed on day 1) and a sustained (up to day 7) effect. E2 administration to castrated rats significantly increased the level of apoptosis by day 3, reaching 9% of the epithelial cells. The divergent kinetics between treatments resulted in the same levels of epithelial regression after 7 days (~30% of control). These results show that E2 has an immediate and possibly direct effect on the prostate, and anticipates epithelial cell death before reducing testosterone to levels as low as those of castrated rats. In addition, E2 and androgen deprivation apparently cause epithelial cell death by distinct and independent pathways.

Key words

- Apoptosis
- Estrogen
- Prostate
- Stereology
- Tissue kinetics

Correspondence

H.F. Carvalho
Departamento de Biologia Celular
Instituto de Biologia, UNICAMP
13083-063 Campinas, SP
Brasil
Fax: +55-19-3788-6111
E-mail: hern@unicamp.br

Presented at XII Congresso
Brasileiro de Biologia Celular,
Campinas, SP, Brazil, July 15-18,
2004.

Research supported by FAPESP.
M. García-Flórez was the recipient
of a CNPq fellowship.

Received July 16, 2004
Accepted January 6, 2005

Introduction

Androgens are required for the growth and physiology of the prostate. The circulating androgens are testosterone (T) and dihydrotestosterone (DHT). The former is produced mainly by the testis (~95%) and the

adrenal gland (~5%) (1). The conversion of T to the more potent androgen DHT by the enzyme 5 α -reductase occurs in the testis and other tissues, including the prostate. Although the normal prostate has been reported not to contribute to the circulating levels of DHT (2), there may be a contribution by this organ

in subjects with a hypertrophic prostate (3). Both T and DHT bind to the same androgen receptor (AR) with different affinities and apparently with different transcriptional activities.

Circulating T, but not DHT, is converted to estrogen (E2) in several tissues by the enzyme aromatase. Apart from interest in the physiological role of E2 in males, these hormones have gained importance because they may have deleterious effects on the formation of the male reproductive organ and on reproductive performance and behavior. Indeed, a hypothesis has been proposed whereby embryonic exposure to E2 is implicated as the causative agent of cryptorchidism, testis cancer, hypospadias, and a low sperm count (4).

Although the prostate is an androgen-dependent tissue, its physiology and pathology are also influenced by E2. Accordingly, E2 receptors α and β are expressed in the prostatic stroma and epithelium, respectively (5,6). Furthermore, aromatase has been identified in the human prostate, suggesting that the prostate is a site of aromatization and a possible source of E2 (7). These data suggest that E2 may be produced locally in the prostate gland and may influence both epithelial and stromal cells via its two receptors. However, E2 has a general anti-androgen effect, and negatively regulates the hypothalamus-hypophysis-testis axis, thereby reducing androgen production by Leydig cells and causing involution of the prostatic epithelium and growth of the stroma in adult animals (6,8).

The effects of E2 on the prostate are complex. Long-term treatment of adult rats with E2 causes prostatic involution (9) and ultimately leads to epithelial squamous metaplasia (10). In castrated dogs, E2 (8 mg/dog per week) has a proliferative effect on both stroma and epithelium (11). When administered to neonates, E2 causes nonmonotonic permanent changes in the prostate, with a low dose increasing puberal growth while a high dose has inhibitory effects (9,12). Fur-

thermore, E2 administration during the neonatal phase causes prostatic hyperplasia and/or dysplasia earlier in adulthood, as well as more frequent prostatitis (13-15). In the guinea pig, E2 has little ability to compete with DHT for AR but is effective in lowering the serum concentrations of T (16).

Since aromatization is the only source of E2 in the male organism, aromatase knockout mice would provide an excellent model system for studying the action of endogenous E2 in the prostate. Indeed, in such mice there is enlargement of the prostate, with an equal contribution from the epithelium and stroma based on histological analysis (17). Although this could indicate that E2 inhibited prostatic growth, serum and tissue concentration of androgens, as well as AR expression and prolactin concentrations, were increased in these mice. Under these conditions, a direct effect of E2 on the prostate could not be conclusively demonstrated.

To assess the direct effects on the prostate, Jarred et al. (18) developed an *in vitro* assay using cultured whole ventral prostates from neonates and testing the effect of E2 in a constant androgen environment, thus avoiding the anti-androgen effect of E2. Under these conditions, E2 inhibited prostate growth, epithelial branching and ductal canalization. Bianco et al. (19) also examined the direct effect of E2 on prostatic growth by using the hypogonadal (hpg) mouse model which is gonadotropin deficient, and showed that E2 caused proliferation and prostatic growth when administered to adult mice. However, the results also proved that part of the prostatic growth was associated with dysplastic epithelium. Epithelial growth in male and female reproductive organs occurs through paracrine mechanisms mediated by stromal receptors. Cunha et al. (20) showed that androgen-induced epithelial proliferation in the prostate gland is indirect, being mediated by mesenchymal/stromal AR-positive cells.

Taken together, these studies show that the hormonal control of prostatic develop-

ment and function is complex and depends on both a balance between steroid hormones and epithelial-stromal interactions. The pathways in this network are still poorly understood and their analysis is hampered by the predominant effect of androgens.

Androgen deprivation elicited by surgical or chemical castration induces apoptosis in the prostatic epithelium. In the ventral prostate of the rat, epithelial apoptosis reaches its peak three days after androgen withdrawal (21). By seven days after surgical castration the rat prostate undergoes rapid involution. Basal and secretory cellular subtypes persist. However, the number of glandular cells is significantly reduced (a 66% decrease) (22) and secretory activity is severely attenuated.

More recently, a study on tissue recombinants using epithelial cells from the testicular feminization mutant mouse demonstrated that epithelial cell apoptosis is not a direct response to low levels of T, but results from paracrine interactions with the stromal cells (21). In the proposed model, the lack of androgen stimulation would result in either impairment of the production of epithelial survival factors usually produced by the stroma or the production of death signals, which would induce epithelial cell death.

Epithelial apoptosis in the rat ventral prostate is secondary to the restriction in blood supply (and hence a diminished nutrient and a putative hypoxic condition) and apoptosis of endothelial cells. Endothelial cells undergo apoptosis as early as 24 h after castration (23). Revascularization is a key event in the restoration of prostatic physiology after androgen administration to castrated animals and emphasizes the importance of blood vessels in the prostate (24).

To investigate the early effects of E2 on the prostate, in the present study we administered a high dose of E2 to castrated and non-castrated rats and examined the behavior of different tissue compartments and the induction of epithelial cell death. Histologi-

cal analyses associated with unbiased stereology and determination of the apoptotic index were done in the rat ventral prostate over a 7-day period. This approach allowed us to identify a threshold for epithelial regression within the first week of androgen deprivation and demonstrated that E2 and castration contributed to apoptotic cell death via distinct and independent mechanisms.

Material and Methods

Animal protocol

Sixty adult male Wistar rats (90 days old) were maintained in a controlled environment with free access to food and water. The experiments were carried out according to the Guide for Care and Use of Laboratory Animals and were approved by the Committee for Ethics in Animal Experimentation of UNICAMP.

A single dose of 17 β -estradiol (E2; Sigma, St. Louis, MO, USA; 0.0367 mmol, corresponding to a high dose of 25 mg/kg body weight) was injected subcutaneously in 0.4 ml of corn oil. Control rats received only corn oil. The rats were divided into four experimental groups: intact rats receiving vehicle (control), non-castrated rats treated with E2, castrated rats treated with E2, and castrated rats with no further treatment. Analyses were performed on days 1, 2, 3, 5, and 7 (N = 3).

At 91, 92, 93, 95, and 97 days of age, the different groups of rats were weighed and then killed by cervical dislocation within 5 s after being removed from their cages. The testis, seminal vesicle, ventral prostate, and coagulating gland (the ventral lobe and coagulating gland were carefully separated from the other lobes and from the seminal vesicle, respectively) were excised and weighed. The ventral prostate was dissected out and immediately fixed by immersion in 4% formaldehyde in phosphate-buffered saline for 24 h. The samples were then washed, dehydrated and embedded in JB4 histo-resin (Leica,

Nussloch, Heidelberg, Germany) for stereological analysis.

Total plasma testosterone levels

Plasma T levels were estimated by radioimmunoassay. Blood samples were obtained by cardiac puncture immediately before death. The plasma was separated by centrifugation and stored at -20°C for subsequent hormone assays. T concentration was measured in plasma samples using a Coat-A-Count kit (Diagnostic Products, Los Angeles, CA, USA). Serum samples were assayed in duplicate and sensitivity to T was 0.94 ng/dl. The intra-assay and interassay variation was 5.36 and 5.10%, respectively.

Stereological analysis

Two-micrometer sections were obtained and stained with hematoxylin and eosin. Six microscope fields were analyzed in sections from at least 2 rats from each group. The sections were photographed and stereology was done using Weibel's system and a 168-point grid, as applied to the rat ventral prostate by Huttunen et al. (25). Microscopic fields representing predominantly proximal or distal ductal regions were avoided because of the predominance of muscular and epithelial compartments in each of these regions, respectively (26). The volume densities of the epithelium, lumen, smooth muscle, and non-muscular stroma were determined. The total stroma was the sum of the smooth muscle and non-muscular stroma. As part of an exploratory analysis, the total volume of each of these compartments was determined based on the mean prostatic weight for each group, considering a 1:1 weight to volume correlation (25).

Detection of apoptosis and determination of the apoptotic index

DNA fragmentation was detected using a fluorescein apoptosis detection system (Pro-

mega, Madison, WI, USA) according to manufacturer instructions. The apoptotic nuclei were identified using a Zeiss Axioskop microscope (Jena, Germany) equipped for fluorescence microscopy and micrographs were obtained using Kodak 400 Kodacolor film.

Histoiresin sections were subjected to Feulgen's reaction. Sections were subjected to hydrolysis with 4 N HCl for 75 min and then treated with Schiff's reagent for 40 min. After extensive washing, the sections were dehydrated and mounted in Canada balsam. Six microscopic fields from at least 2 rats were analyzed and the apoptotic index was determined by dividing the number of apoptotic nuclei by the total number of nuclei found in the microscope field, using a 40X objective. Apoptotic nuclei were identified by the characteristic pyknosis and/or nuclear fragmentation, as reported by Kerr and Searle (27). The number of nuclei counted was 1290 to 2657 for the different experimental conditions. Only the epithelium was considered for these counts.

Statistical analysis

Data are reported as means \pm SEM, where appropriate. One-way analysis of variance (ANOVA) was used to compare the measurements obtained after each treatment with control measurements. Differences were considered significant when $P \leq 0.05$.

Results

Table 1 shows the variation in body, testis and accessory gland weights on day 7 after the different treatments. Castration or the administration of E2 to non-castrated and castrated rats caused small, nonsignificant reductions in body weight. E2 significantly reduced testis weight, whereas E2 and castration caused similar reductions in accessory gland weight. Although significant, the reduction in seminal vesicle weight was less pronounced than in the other glands

after treatment with E2. The administration of E2 to castrated rats did not affect the reduction in prostatic weight caused by castration alone.

Table 2 shows the quantitative data for total plasma T concentration after castration and treatment with E2. Castration almost completely reduced plasma T levels 24 h after surgical removal of the testes. Treatment with E2 also resulted in a marked decrease in plasma T levels. However, there was a residual amount of T (5-6% of the control value) 24 and 48 h after E2 administration. T was not detected after 72 h.

Histological analysis of the rat ventral prostate revealed a simple, cylindrical epithelium with basal nuclei. The stroma was scarce, with few smooth muscle cells (SMC) and fibroblasts (Figure 1A). Treatment with E2 resulted in shorter epithelial cells at day 7. The SMC formed a dense bundle below the epithelium (Figure 1B). Seven days of

androgen deprivation by surgical castration resulted in loss of the apical cytoplasm and shorter epithelial cells. The stroma was more prominent, with a denser array of SMC, fibroblasts and other cell types (Figure 1C). Castrated rats treated with E2 showed a histological organization intermediate between that seen in castrated rats and E2-treated rats, especially with respect to the SMC (Figure 1D).

Stereology was used to follow the changes of different tissue compartments in the various hormonal situations. Treatment with E2 resulted in a marked reduction in the volume density of the epithelial compartment two days after the beginning of the treatment (from 47 to ~32%). This loss was maintained up to day 5 and was then partially restored at day 7 (Figure 2A). E2 caused an immediate increase in the volume density of the lumen by day 2 followed by a progressive decrease up to day 7 (Figure 2B). Castration and E2

Table 1. Effect of hormonal conditions on the body weight, testis and accessory gland weight in male rats 7 days after estrogen treatment or castration.

Group	Body	Testes	Ventral prostate	Seminal vesicle	Coagulating gland
Control	337.0 ± 11.0	3.67 ± 0.09	0.585 ± 0.003	0.598 ± 0.035	0.370 ± 0.014
Castrated	292.6 ± 5.24	-	0.277 ± 0.007*	0.330 ± 0.013*	0.237 ± 0.001*
E2 treated	308.3 ± 2.33	2.72 ± 0.05*	0.293 ± 0.014*	0.403 ± 0.026*	0.262 ± 0.010*
Castrated + E2 treated	291.6 ± 8.33	-	0.281 ± 0.006*	0.397 ± 0.026*	0.296 ± 0.023*

Data are reported as means ± SEM in grams. E2 = estradiol.

*P < 0.005 compared to control (one-way analysis of variance).

Table 2. Total serum testosterone concentration.

		Days after castration				
		1	2	3	5	7
Control	350.5 ± 61.1					
Castrated		<0.94 ^a	<0.94 ^a	<0.94 ^a	<0.94 ^a	<0.94 ^a
E2 treated		11.15 ± 5.1*	17.7 ± 3.4*	<0.94 ^a	<0.94 ^a	<0.94 ^a

Data are reported as means ± SEM in ng/dl. ^aBelow the detection limit.

*P < 0.001 compared to control (one-way analysis of variance).

administration to castrated rats resulted in no such variation of the lumen, although there was a slight, progressive decrease in its volume density (Figure 2B).

Castration and E2 increased the volume density of the stroma (Figure 2C), and there was also a progressive increase in stromal volume after day 2, with a pronounced contribution of the SMC in all hormonal conditions when compared to control (Figure 2C,D).

The absolute volume showed more dramatic changes in the prostatic tissue compartments. Castration, E2, and E2 administration to castrated rats resulted in a decrease

in the absolute volume of the epithelium (Figure 2E). E2 caused an increase in the luminal compartment at day 2 followed by a progressive reduction up to day 7. A reduction was noted in the luminal (Figure 2F), stromal (Figure 2G) and SMC (Figure 2H) compartments, regardless of treatment, compared to control.

TUNEL labeling was used to detect DNA strand breaks, a reliable indicator of apoptosis in the rat ventral prostate (28). There was virtually no apoptosis in the control rats (Figure 3A), but marked apoptosis was seen in E2-treated (Figure 3B) and castrated (Figure 3C) rats. The apoptotic indices revealed different kinetics for cell death for each treatment (Figure 4). Castration resulted in a peak of apoptosis on day 3. Treatment with E2 resulted in apoptotic cell death that reached a plateau on day 2 and was maintained up to day 5. The apoptotic index observed on day 3 was similar to that obtained by castration. E2 administration to castrated rats resulted in an increase in apoptotic cell death that was significantly greater than that observed after castration alone ($P < 0.05$). Curiously, the curve profile corresponded to a summation of the results obtained by castration and treatment with E2 separately.

Discussion

Prostate development and function are influenced by E2. These hormones exert a general effect by negatively regulating the hypothalamus-hypophysis-testis axis and then reducing T production by the testis (29). However, the identification of E2 receptors α and β in prostatic cells indicates that E2 might have a direct effect on the prostate. This conclusion is further supported by the fact that the prostate is also able to convert T to E2 (7). Determining the effects of E2 on the prostate is important because E2 is a necessary agent in the control of androgen-insensitive prostate cancer (30,31).

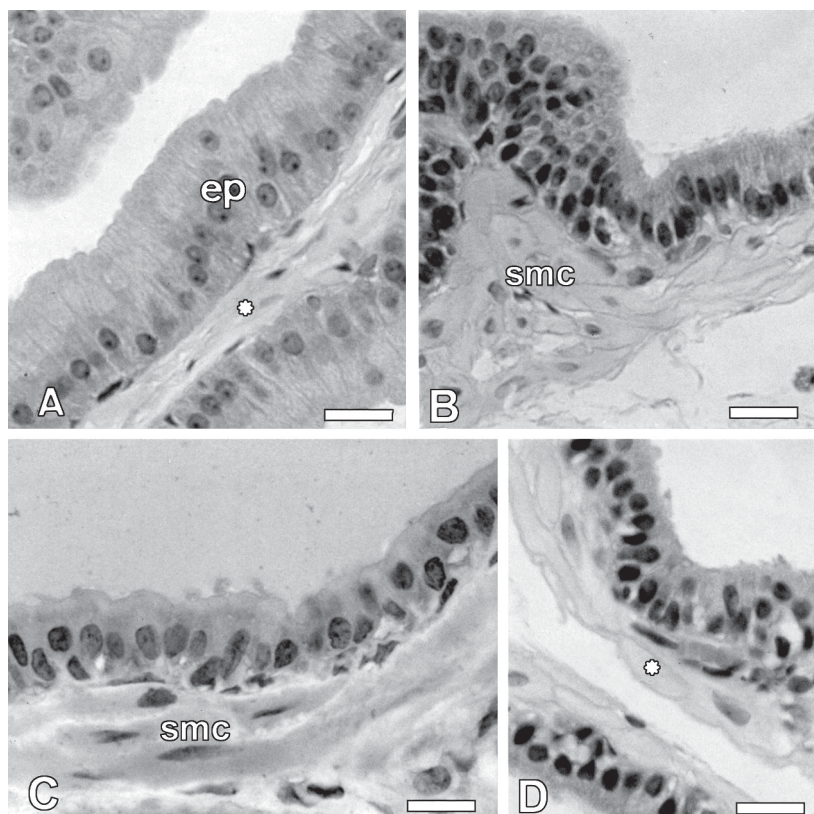


Figure 1. Hematoxylin and eosin-stained sections of the rat ventral prostate 7 days after receiving estrogen (E2) or being castrated. A, The control prostate shows characteristic cylindrical epithelial cells (ep) with a basal nucleus and a prominent nucleolus. The stroma is reduced and shows a few elongated smooth muscle cells (smc, asterisk) beneath the epithelium. B, E2 treatment resulted in reduction of the apical cytoplasm and an increase in the stroma. smc occupied a larger area of the stroma and appeared to be hyperplastic. C, Castration resulted in shortening of the epithelial cells and thickening of the stroma, with a greater contribution by smc, blood vessels and other cell types. D, E2 administration to castrated rats did not change the basic aspects seen in castrated animals, including those related to the smc (asterisk). Bar = 25 μ m (A-D).

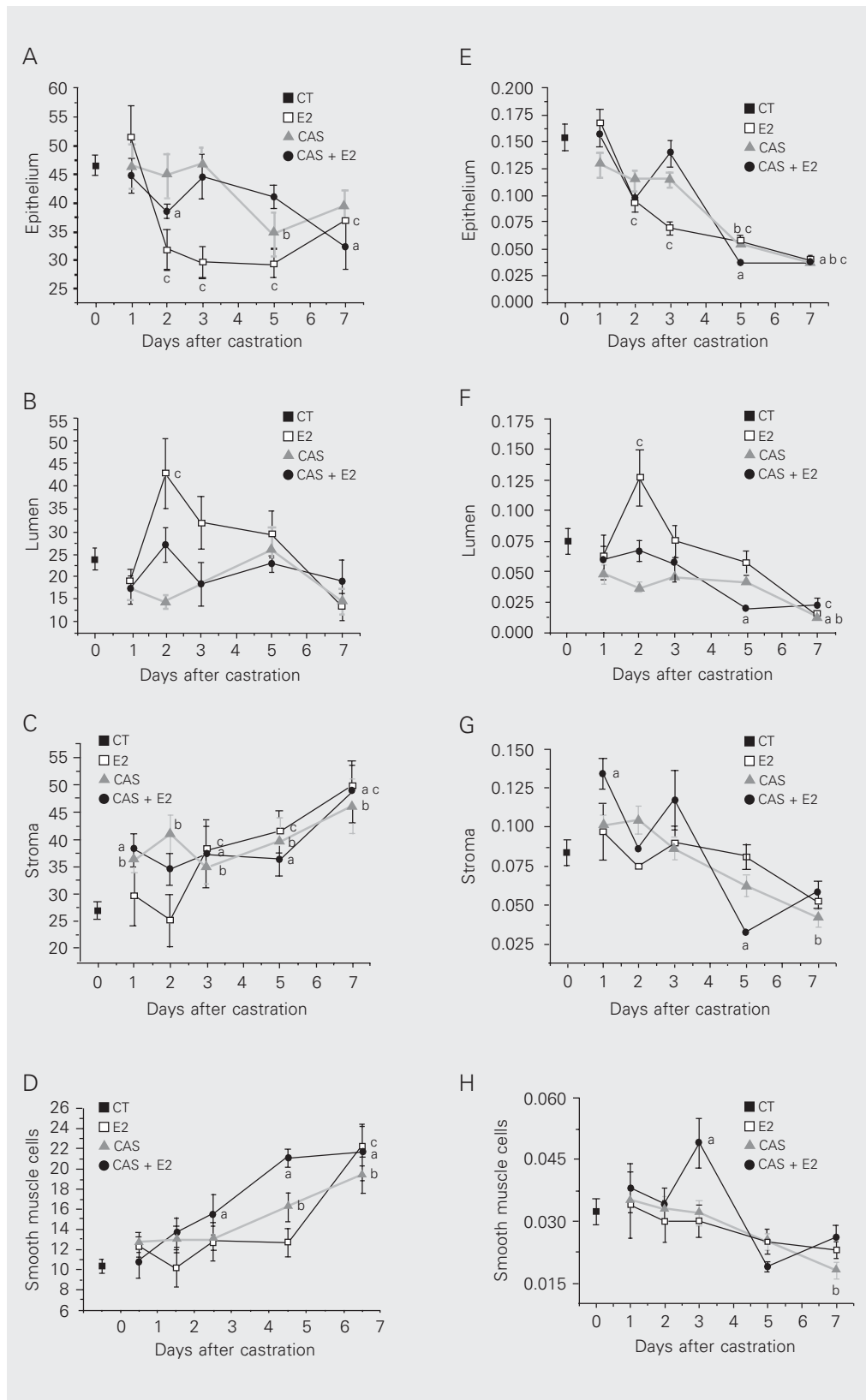


Figure 2. Stereological analysis of the rat ventral prostate compartments. A-D correspond to the relative volume (%) of each compartment and E-H are the absolute volume (ml) of each compartment. CT = control; E2 = control rats treated with estrogen; CAS = castrated rats; CAS + E2 = castrated rats treated with E2; 1-7 represent the days after the beginning of treatment. The indices in the figure indicate values statistically different from the control (a, castrated rats; b, castrated rats; c, E2-treated rats) at P < 0.05 (one-way analysis of variance).

When administered neonatally, E2 causes several defects in prostatic development, including an increased susceptibility to prostatitis (15,32) and to the occurrence of prostatic metaplasia (33). Long-term treatment of adult rats with E2 causes prostatic involution (9) and ultimately leads to epithelial squamous metaplasia (10). Moreover, there appears to be a dose-dependent variation in the effects of E2. Low doses have a stimulatory effect on the growth of the epithelium

and stroma, while high doses have an inhibitory effect (9,12,34).

In the present investigation, we studied the early effects of a high dose of E2 in adult rats and compared them with those promoted by androgen ablation following castration. We used a high dose in order to exacerbate the effects of E2 on the prostate and to detect possible acute responses in the different tissue compartments. One pitfall of this approach is that at high concentrations E2 may compete with T and DHT for the AR, at least *in vitro* (16). Such antagonist effect cannot be excluded here and may have contributed to the observed effects of E2.

E₂ caused a general reduction in testicular weight, in agreement with the ability of this hormone to reduce gonadotropin secretion. In addition, E2 also reduced the ventral prostate and coagulating gland to an extent that was comparable to the effect of castration. The seminal vesicle was also affected, but to a lesser extent.

All treatments reduced the relative and absolute volume of the epithelium, although the final absolute volume was similar after 7 days for each treatment, and corresponded to ~32% of the organ. However, E2 caused a progressive reduction in epithelial volume that was observed as early as 24 h after hormone administration. This contrasted with the reduction in epithelial volume caused by castration, which appeared later and was more evident on days 5 and 7. Thus, the kinetics of epithelial volume reduction differed between castration and treatment with E2. The regressive effect of the high dose of E2 used here contrasts with the stimulatory action of a low dose in castrated rats (35).

The epithelial reduction resulted partly from epithelial cell loss by apoptosis. These results agree with previous studies indicating that epithelial apoptosis peaks on the third day after castration (36). In contrast, the high dose of E2 increased the apoptotic index within 24 h after dosing; there was an additional slight increase after 48 h, which

Figure 3. Detection of DNA fragmentation in the rat ventral prostate. Control rats (A) showed no reaction, while treatment with estrogen (B) and castration (C) resulted in DNA fragmentation (arrows). Representative micrographs obtained on day 3. Bar = 50 μ m (A-C).

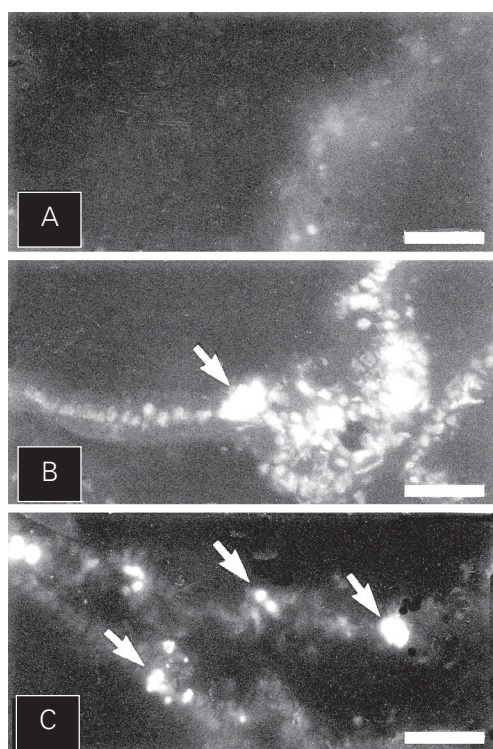
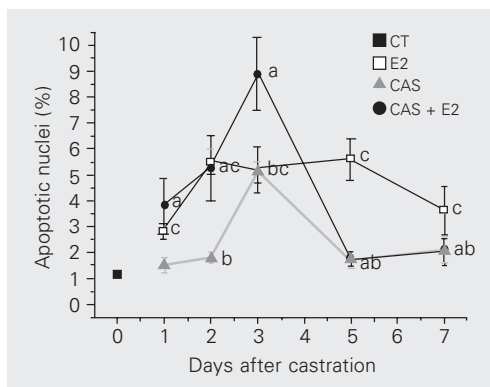


Figure 4. Apoptotic indices for prostatic epithelial cells. Castration resulted in a peak of apoptotic cell death on day 3. E2 caused the premature death of epithelial cells and showed a sustained effect. E2 administration to castrated rats resulted in an increased incidence of apoptosis, but preserved the peak apoptotic nuclei on day 3. CT = control; E2 = rats treated with estrogen; CAS = castrated rats; CAS + E2 = castrated rats treated with E2. The indices in the figure indicate values statistically different from the control (a, castrated rats treated with E2; b, castrated rats; c, E2-treated rats) at $P < 0.05$ (one-way analysis of variance).



was then maintained up to 72 h post-treatment. The rapidity of this response to E2 suggests that this hormone may have a direct action on epithelial cells (which express E2 receptor β), in contrast to apoptosis induced by androgen ablation, which involves paracrine regulation via stromal cells (21). E2 had an additive effect on the apoptotic index obtained following castration, which suggests that the two treatments induced epithelial apoptosis through distinct and probably independent apoptotic pathways.

It is unclear why the increase in apoptosis seen in castrated rats treated with E2 did not result in a greater reduction in epithelial volume and ventral prostate weight after 7 days when compared to that caused by either castration or E2 treatment alone. Indeed, there was no difference in the luminal, stroma or SMC compartments of the rat ventral prostate on day 7 after either treatment.

Castration, E2 administration, and E2 administration to castrated rats also increased the relative volume and slightly decreased the absolute volume of the SMC. A similar reduction in SMC volume after castration has been reported before (37) and was suggested to be the result of cellular atrophy or cell loss by apoptosis.

Zhao et al. (38) reported that the most obvious alteration in the ventral prostate in response to E2 was a reduction in luminal volume. In addition we have also observed a sudden increase in the volume of the lumen. This oscillation in luminal volume was specific for E2 and may be attributed to an immediate loss of the epithelium rather than to an increased secretory activity. Lumen regression will be seen later, when the organ compensates for epithelial inactivity and loss.

Since E2 has an anti-androgen effect that is mediated by down-regulation of the hypothalamus-hypophysis-testis axis, it is difficult to define the direct effects of this hormone on the prostate. In an *in vitro* system, E2 diminished prostatic growth without affecting cell proliferation (18). A stimulatory

effect of E2 on the male accessory sex glands in hypogonadal mice has been reported (19). This growth reflected increments in the epithelium of the anterior prostate and seminal vesicle, but not in the ventral prostate. Squamous metaplasia and inflammation were common responses to E2 in the absence of androgen.

It is worth mentioning at this point that we have assessed the number of PCNA-positive cells in the experimental groups used here and found that castration, E2 treatment and E2 plus castration resulted in the complete elimination of proliferative cells (data not shown).

The present results clearly show that E2 has an immediate effect on the prostatic epithelium, and induces apoptotic cell death as early as 24 h after treatment. By this time point, circulating T levels have been reduced to about 5%. However, the effect of E2 cannot be attributed solely to a decrease in T levels. Were this the case, the cell death kinetics would be expected to be similar to that observed for androgen ablation.

Defining the molecular mechanism of E2 action on the prostate has proven difficult, despite the growing number of experimental models and treatment protocols. The use of a high dose of E2 was helpful in defining the initial early effects of E2 and represents a good model system for investigating the mechanisms involved in the direct action of E2 in the prostate gland. Refinement of the protocol used here could be helpful for distinguishing between the effects of E2 on the hypothalamus-hypophysis-testis axis, its actions as an antagonist competing with T and DHT for the AR, and the involvement of E2 receptor β . Further attempts to characterize the effect of E2 and castration on the prostate must consider that, while castration causes an important increase, E2 causes a marked reduction in protein synthesis in both epithelium and stroma (39).

Androgen ablation and a high dose of E2 cause prostatic epithelial cell apoptosis

through distinct and apparently independent pathways. Prostatic involution is dependent on early effects that are more prominent in the epithelium, with minor contributions from the stroma and SMC. Even though E2 caused an accelerated loss of the epithelial cells and this effect was exacerbated in E2-treated castrated rats, there was a threshold for epi-

thelial loss within the first week. Further weight loss will depend on other alterations of the gland that cannot be anticipated by E2. Most likely, E2 was unable to anticipate later stromal changes seen in castrated animals (37,40), which may be necessary for further prostatic involution.

References

- Coffey DS (1992). The molecular biology, endocrinology and physiology of the prostate and seminal vesicles. In: Walsh PC, Retik AB, Stamey TA & Vaughn JED (Editors), *Campbell's Urology*. 6th edn. W.B. Saunders Co., Philadelphia, PA, USA, 1381-1428.
- Toorians AW, Kelleher S, Gooren LJ, Jimenez M & Handelsman DJ (2003). Estimating the contribution of the prostate to blood dihydrotestosterone. *Journal of Clinical Endocrinology and Metabolism*, 88: 5207-5211.
- Ghanadian R, Lewis JG, Chisholm GD & O'Donoghue EP (1977). Serum dihydrotestosterone in patients with benign prostatic hypertrophy. *British Journal of Urology*, 49: 541-544.
- Sharpe RM (2003). The 'oestrogen hypothesis' - where do we stand now? *International Journal of Andrology*, 26: 2-15.
- Leav I, Lau KM, Adams JY, McNeal JE, Taplin ME, Wang J, Singh H & Ho SM (2001). Comparative studies of the estrogen receptors beta and alpha and the androgen receptor in normal human prostate glands, dysplasia, and in primary and metastatic carcinoma. *American Journal of Pathology*, 159: 79-92.
- Weihua Z, Warner M & Gustafsson J-A (2002). Estrogen receptor beta in the prostate. *Molecular and Cellular Endocrinology*, 193: 1-5.
- Tsugaya M, Harada N & Tozawa K (1996). Aromatase mRNA levels in benign prostatic hyperplasia and prostate cancer. *International Journal of Urology*, 3: 292-296.
- Thompson SA, Rowley DR & Heidger PM (1979). Effects of estrogen upon the fine structure of epithelium and stroma in the rat ventral prostate gland. *Investigative Urology*, 17: 83-89.
- Vom Saal FS, Timms BG & Montano MM (1997). Prostate enlargement in mice due to fetal exposure to low doses of estradiol or diethylstilbestrol and opposite effects at high doses. *Proceedings of the National Academy of Sciences, USA*, 94: 2056-2061.
- Tunn U, Senge T, Schenck B & Neumann F (1979). Biochemical and histological studies on prostates in castrated dogs after treatment with androstenediol, oestradiol and cyproterone acetate. *Acta Endocrinologica*, 91: 373-384.
- Merk FB, Leav I, Kwan PW & Ofner P (1980). Effects of estrogen and androgen on the ultrastructure of secretory granules and intercellular junctions in regressed canine prostate. *Anatomical Record*, 197: 111-132.
- Putz O, Schwartz CB, Kim S, LeBlanc GA, Cooper RL & Prins GS (2001). Neonatal low- and high-dose exposure to estradiol benzoate in the male rat. I. Effects on the prostate gland. *Biology of Reproduction*, 65: 1496-1505.
- Prins GS, Birch L & Greene GL (1992). Androgen receptor localization in different cell types of the adult rat prostate. *Endocrinology*, 129: 3187-3199.
- Santti R, Newbold RR, Makela S, Pylkkanen L & McLachlan JA (1994). Developmental estrogenization and prostatic neoplasia. *Prostate*, 24: 67-78.
- Stoker TE, Robinette CL & Cooper RL (1999). Perinatal exposure to estrogenic compounds and the subsequent effects on the prostate of the adult rat: evaluation of inflammation in the ventral and lateral lobes. *Reproductive Toxicology*, 13: 463-472.
- Neubauer B, Blume C, Cricco R, Greiner J & Mawhinney M (1981). Comparative effects and mechanisms of castration, estrogen anti-androgen, and anti-estrogen-induced regression of accessory sex organ epithelium and muscle. *Investigative Urology*, 18: 229-234.
- McPherson SJ, Wang H, Jones ME, Pedersen J, Iismaa TP, Wreford N, Simpson ER & Risbridger GP (2001). Elevated androgens and prolactin in aromatase-deficient mice cause enlargement, but not malignancy, of the prostate gland. *Endocrinology*, 142: 2458-2467.
- Jarred RA, Cancilla B, Prins GS, Thayer KA, Cunha GR & Risbridger GP (2000). Evidence that estrogens directly alter androgen-regulated prostate development. *Endocrinology*, 141: 3471-3477.
- Bianco JJ, Handelsman DJ, Pedersen JS & Risbridger GP (2002). Direct response of the murine prostate gland and seminal vesicle to estradiol. *Endocrinology*, 143: 4922-4933.
- Cunha GR, Alarid ET, Turner T, Donjacour AA, Boutin EL & Foster BA (1992). Normal and abnormal development of the male urogenital tract. Role of androgens, mesenchymal-epithelial interactions, and growth factors. *Journal of Andrology*, 13: 465-475.
- Kurita T, Wang YZ, Donjacour AA, Zhao C, Lydon JP, O'Malley BW, Isaacs JT, Dahiya R & Cunha GR (2001). Paracrine regulation of apoptosis by steroid hormones in the male and female reproductive system. *Cell Death and Differentiation*, 8: 192-200.
- English HF, Santen RJ & Isaacs JT (1987). Response of glandular versus basal rat ventral prostatic epithelial cells to androgen withdrawal and replacement. *Prostate*, 11: 229-242.
- Buttayan R, Ghafar MA & Shabsigh A (2000). The effects of androgen deprivation on the prostate gland: cell death mediated by vascular regression. *Current Opinion in Urology*, 10: 415-420.
- Franck-Lissbrant I, Haggstrom S, Damber JE & Bergh A (1998). Testosterone stimulates angiogenesis and vascular regrowth in the ventral prostate in castrated adult rats. *Endocrinology*, 139: 451-456.
- Huttunen E, Romppanen T & Helminen HJ (1981). A histoquantitative study on the effects of castration on the rat ventral prostate lobe. *Journal of Anatomy*, 132: 357-370.
- Lee C, Sensibar JA, Dudek SM, Hiipakka RA & Liao S (1990). Prostatic ductal system in rats: regional variation in morphological and functional activities. *Biology of Reproduction*, 43: 1079-1086.
- Kerr JF & Searle J (1973). Deletion of cells by apoptosis during castration-induced involution of the rat prostate. *Virchows Archiv*.

- B, Cell Pathology*, 13: 87-102.
28. English HF, Kyprianou N & Isaacs JT (1990). Relationship between DNA fragmentation and apoptosis in the programmed cell death in the rat prostate following castration. *Prostate*, 15: 233-250.
 29. Cook JC, Johnson L, O'Connor JC, Biegel LB, Krams CH, Frame SR & Hurtt ME (1998). Effects of dietary 17 β -estradiol exposure on serum hormone concentrations and testicular parameters in male Crl:CD BR rats. *Toxicological Sciences*, 44: 155-168.
 30. Oh W (2002). The evolving role of estrogen therapy in cancer therapy. *Clinical Prostate and Cancer*, 1: 81-89.
 31. Sayed Y & Taxel P (2003). The use of estrogen therapy in men. *Current Opinion in Pharmacology*, 3: 650-654.
 32. Naslund MJ, Strandberg JD & Coffey DS (1988). The role of androgens and estrogens in the pathogenesis of experimental nonbacterial prostatitis. *Journal of Urology*, 140: 1049-1053.
 33. Arai Y (1970). Nature of metaplasia in rat coagulating glands induced by neonatal treatment with estrogen. *Endocrinology*, 86: 918-920.
 34. Hayward SW & Cunha GR (2000). The prostate: development and physiology. *Radiologic Clinics of North America*, 38: 1-14.
 35. Pelletier G (2002). Effects of estradiol on prostate epithelial cells in the castrated rats. *Journal of Histochemistry and Cytochemistry*, 50: 1517-1523.
 36. Isaacs JT, Furuya Y & Berges R (1994). The role of androgen in the regulation of programmed cell death/apoptosis in normal and malignant prostatic tissue. *Seminars in Cancer Biology*, 5: 391-400.
 37. Antonioli E, Della-Colleta HH & Carvalho HF (2004). Smooth muscle cell behavior in the ventral prostate of castrated rats. *Journal of Andrology*, 25: 50-56.
 38. Zhao GQ, Holterthus PM, Dammshäuser I, Hoffbauer G & Aumüller G (1992). Estrogen-induced morphological and immunohistochemical changes in stroma and epithelium of rat ventral prostate. *Prostate*, 21: 183-199.
 39. Zhao GQ, Bacher M, Friedrichs B, Schmidt W, Rausch U, Groebel HW, Tuohimaa P & Aumüller G (1993). Functional properties of isolated stroma and epithelium from rat ventral prostate during androgen deprivation and estrogen treatment. *Experimental and Clinical Endocrinology*, 101: 69-77.
 40. Carvalho HF, Vilamaior PSL & Taboga SR (1997). Elastic system of the rat ventral prostate and its modifications following orchiectomy. *Prostate*, 32: 27-34.