

# Thoracic tuberculosis misdiagnosed as lumbar compression fracture and treated with percutaneous kyphoplasty (PKP): a case report and literature review

Xiangran SUN<sup>1</sup>, Jian YANG<sup>1</sup>, Ling YU<sup>1</sup>, Yubo SHI<sup>1</sup>, Weichun GUO<sup>1\*</sup> 

## Abstract

Thoracolumbar tuberculosis is a common clinical disease. In this study, a 63 years old female patient had back pain after physical work. X-ray examination showed that the 8<sup>th</sup> thoracic vertebra was compressed. MR showed that the signal of the 8<sup>th</sup> thoracic vertebra was abnormal, and T2 showed an obviously high signal. Then, she was misdiagnosed as compression fracture of the thoracic spine at first diagnosis and treated with percutaneous balloon kyphoplasty (PKP) and the pain was gradually aggravated 3 months after the operation; then, lower extremity neurological symptoms began to appear. After that, she was finally diagnosed with tuberculosis of the thoracic spine and received surgery again and then the symptoms were ameliorated significantly, and the muscle strength of both lower limbs recovered. For patients with thoracolumbar compression fractures, we should fully understand the disease history of the disease and perform a detailed examination. The tuberculosis and even tumors should be considered to avoid misdiagnosis.

**Keywords:** spinal tuberculosis; pathogenesis; diagnosis; medication; surgical.

**Practical Application:** To promote the diagnosis and treatment of thoracic tuberculosis and deepen the understanding of the disease.

## 1 Introduction

Spinal tuberculosis is the most common secondary tuberculosis outside the lung, accounting for approximately 50% of cases of bone and joint tuberculosis. If it is not diagnosed and treated in time, spinal tuberculosis will easily cause spinal cord and nerve compression as well as paralysis. Among all types of spinal tuberculosis, thoracic tuberculosis (48.03%) and lumbar tuberculosis (42.36%) are most common, followed by thoracic and lumbar tuberculosis (29.58%), while cervical tuberculosis (5.39%) and sacral tuberculosis (4.22%) are relatively rare (Shi et al., 2016). Spinal tuberculosis often causes abscess formation, spinal cord dysfunction, spinal instability, kyphosis and other complications. Most cases of spinal tuberculosis can be cured with nonsurgical treatment. Surgical treatment is the ultimate treatment approach with the purpose to clear the foci, relieve the compression of the spinal cord and nerves, correct kyphosis and reconstruct the stability of the spine.

## 2 Case presentation

This study was approved by the Ethics Committee of Renmin Hospital of Wuhan University and the patient had provided informed consent.

A 63-year-old female patient suffered from thoracolumbar pain after physical work. X-ray examination of the thoracic vertebrae in the outpatient department showed compression changes in the 8<sup>th</sup> thoracic vertebra, and MR examination showed abnormal signal of the 8<sup>th</sup> thoracic vertebra (Figure 1A-D). The bone marrow

was obviously edematous, and there was percussion pain in the back. Then, a diagnosis of thoracic compression fracture was made and recommended PKP treatment (Figure 2A, B). The pain symptoms were partially relieved, but the back pain was not.

Three months after operation, the pain symptoms gradually increased. Subsequently, the muscle strength of both lower limbs decreased. The muscle strength of the bilateral iliopsoas and quadriceps femoris muscles as well as the tibialis anterior muscles reached level 3 and level 4 strength, respectively. The sensation decreased below the level of navel. MR examination showed obvious abnormal signals in the 8<sup>th</sup> thoracic vertebra and a large number of abscesses around the vertebra. X-ray, CT and MR of the thoracic vertebrae showed destruction of the 8<sup>th</sup> vertebra as well as cement displacement of the chest bone and partial penetration into the spinal canal (Figure 2C-H).

Laboratory examination showed the following: T-SPOT (+), PPD test (+), ESAT-6 > 50, CFP-10 > 50, and ESR 83.00 mm/h. After excluding tumors, the patient was finally diagnosed as thoracic tuberculosis. Then, the patient was treated with antituberculosis drugs for two weeks, and the ESR of the patient was 43 mm/h. After patient's condition was stable, the thoracic vertebral foci were cleared, bone grafting and pedicle screw internal fixation were performed (Figure 3A-C). Pathological report showed some coagulative necrosis with dead bone formation under microscope and positive acid-fast staining (Figure 3D, E). After operation, the symptoms were significantly ameliorated and the muscle strength of both lower limbs was recovered.

Received 10 May, 2021

Accepted 17 May, 2021

<sup>1</sup>Department of Orthopedics, Renmin Hospital of Wuhan University, Wuhan, Hubei Province, China

\*Corresponding author: weichunguo11@163.com

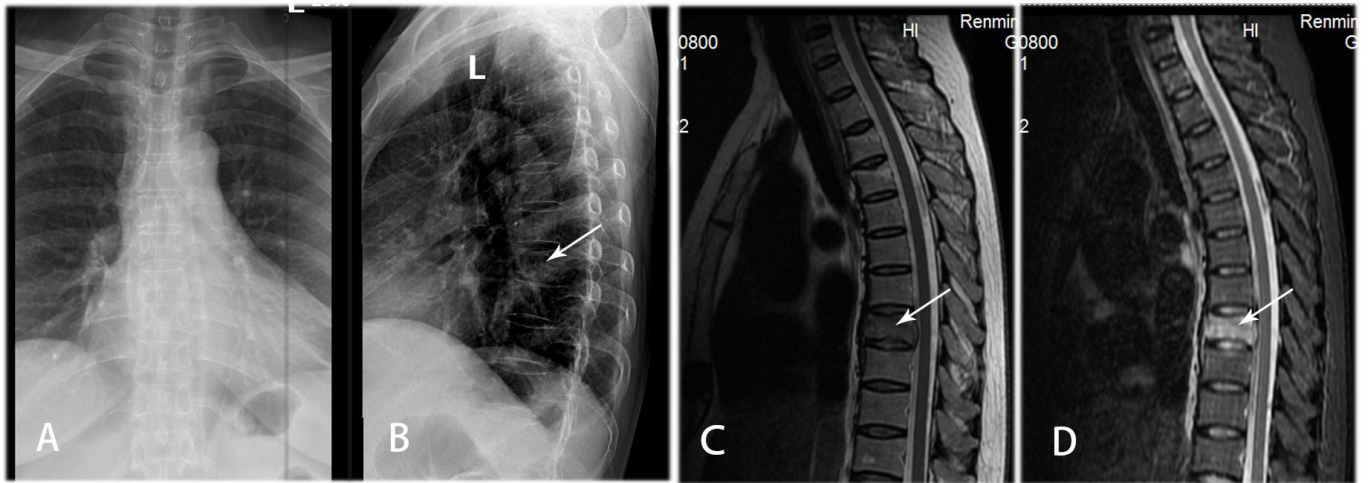


Figure 1. A-D show compression changes in the 8<sup>th</sup> thoracic vertebra, and the signal is abnormal.

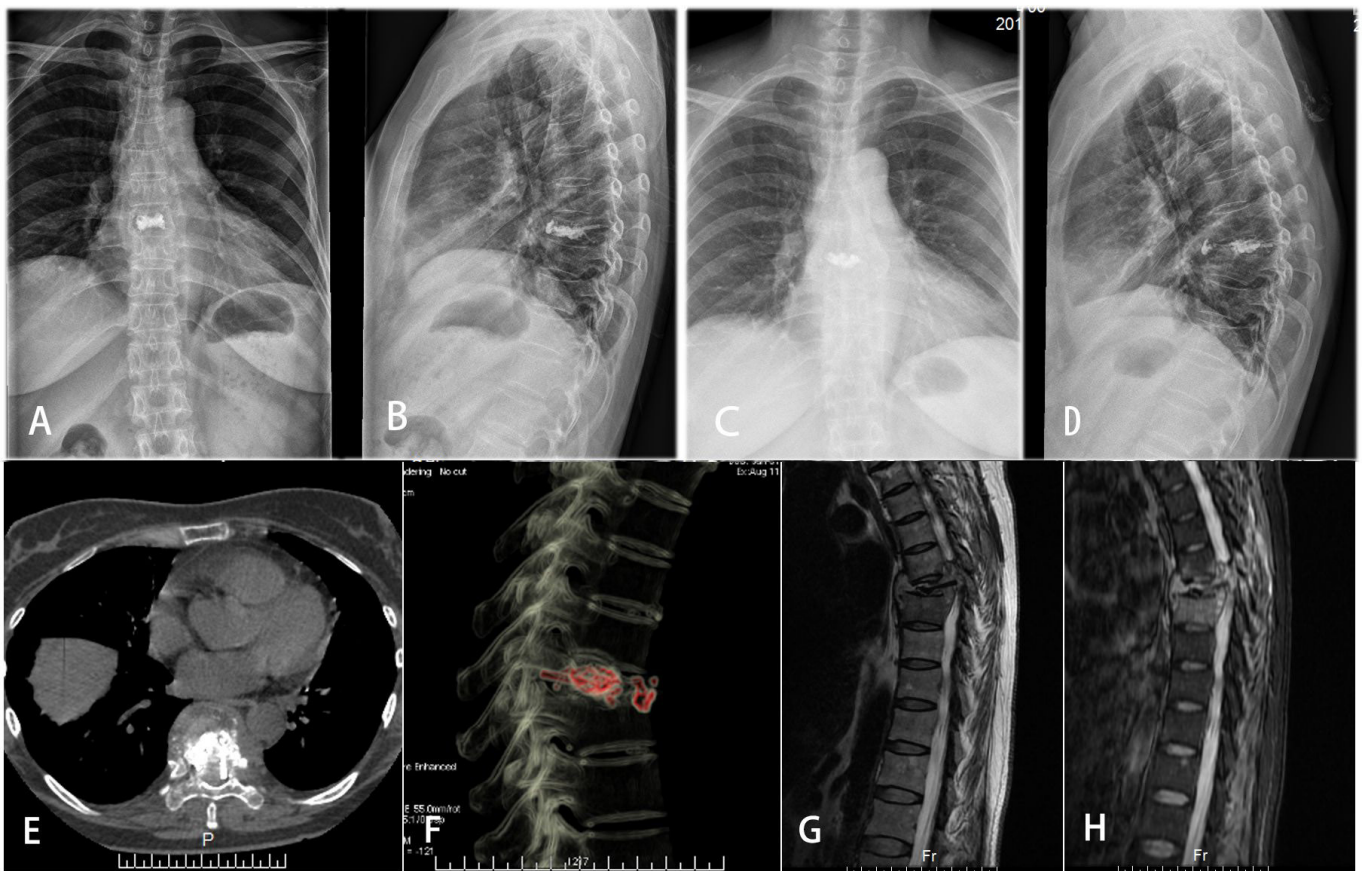
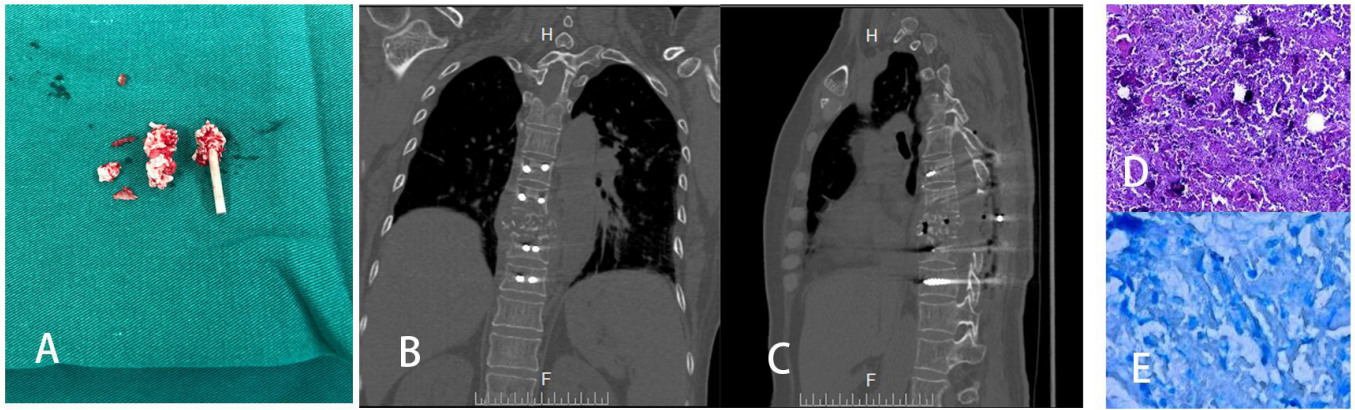


Figure 2. (A) and (B) imaging manifestations after PKP; (C)-(H) X-ray, CT and MR of thoracic vertebrae show destruction of the 8<sup>th</sup> vertebra with cement displacement of the chest bone and partial penetration into the spinal canal.

### 3 Discussion

Spinal tuberculosis is caused by the destruction of spinal bone and intervertebral discs after the body is infected by *Mycobacterium tuberculosis*, and it can further involve the surrounding accessory and paravertebral muscles, causing tissue degeneration and necrosis. Tuberculous abscess can form after liquefaction of the necrotic tissue. If the lesion is further

aggravated, large abscesses that form locally often compresses the spinal cord backward. Meanwhile, bone destruction causes kyphosis deformities of the spine, resulting in a decrease in spinal canal volume and a further increase in spinal canal pressure. In addition, the inflammatory reaction caused by the lesion leads to injury of the corresponding ganglion segment in the body, thus resulting in symptoms due to nerve function damage. In serious



**Figure 3.** (A) shows the implanted bone cement material; (B) and (C) show the imaging manifestations after the second operation; (D) and (E) show some coagulative necrosis with dead bone formation seen under the microscope and positive acid-fast staining.

cases, spinal tuberculosis can lead to paraplegia, incontinence and other severe complications. At the same time, the abscess can spread along the paravertebral space due to the effect of gravity, forming a cold abscess in the distant part of the space.

### 3.1 Diagnostic basis of spinal tuberculosis

#### Laboratory examinations

Laboratory tests for spinal tuberculosis include measurements of the ESR, CRP level, and TB antibodies; the tuberculin test; T-Spot-TB technology; TB culture + drug sensitivity; the Xpert test; the gene chip method; etc. (Oommen & Banaji, 2017; Chauhan et al., 2018). Several factors can cause the ESR to change, such as menstruation, pregnancy, old age and other physiological factors, as well as bacterial infections, autoimmune diseases, tissue necrosis caused by trauma, anemia, malignant tumors and other pathological factors. Tuberculosis antibodies were first reported by related researchers (Zhang et al., 2018). During the onset of spinal tuberculosis, the body will produce different immunoglobulins, first IgM and then a large amount of IgG, due to the activation of the human autoimmune system. However, the positive rate of the TB antibody test is related to the storage of reagents and the technical level of personnel. The PPD skin test is convenient, economical and easy for patients to undergo. It is often used in large areas with a general survey in certain areas, and it can be an effective means of identifying tuberculosis patients. T-Spot-TB technology (Doan et al., 2017) detects T cells stimulated by TB-specific antigens for releasing interferon  $\gamma$  (IFN- $\gamma$ ) into the peripheral blood, and it has a high sensitivity and specificity.

#### 3.2 Imaging examination

DR can show bone destruction and intervertebral space stenosis or disappearance caused by spinal tuberculosis. Because of its excellent high-density resolution, CT can not only accurately show changes in spinal bone (such as destruction, hyperplasia, sclerosis, and calcification) and the boundary of the lesion but also show the involvement of the intervertebral disc and vertebral accessory structures. Meanwhile, CT can show the extent and degree of stenosis in spinal tuberculosis, and it is helpful for the classification of spinal tuberculosis.

MRI can accurately show the extent of bone marrow edema as well as intervertebral disc and paravertebral soft tissue damage caused by inflammation. Moreover, for suspected soft tissue damage, further enhanced scanning can be performed to make a clear diagnosis (Shi, 2018). B ultrasound is mainly used for the diagnosis and location of paravertebral or psoas major muscle abscesses in spinal tuberculosis.

### 3.3 Chemical treatment of spinal tuberculosis

The chemical drugs used for the treatment of spinal tuberculosis are mainly divided into first-line drugs, second-line drugs and other types of antituberculosis drugs. The first-line drugs include isoniazid (INH), rifampin (RFP), pyrazinamide (PZA), streptomycin (SM), ethambutol (EMB), and thiosemicarbazide (TB1). The second-line drugs mainly include aminosalicyclic acid, ethylthioisonicotinic amine, capreomycin, rifampicin, kanamycin, etc.

### 3.4 Indications and surgical methods of spinal tuberculosis

The indications for the surgical treatment of spinal tuberculosis are as follows (Yin et al., 2016; Jain et al., 2008): ① obvious destruction of vertebral structure, secondary spinal instability; ② compression of the spinal cord and cauda equina, or paraplegia; ③ large dead bones, cavities and cold abscess, long-lasting sinus; ④ serious or progressive kyphosis; ⑤ poor effect of nonsurgical treatment; and ⑥ drug resistance or multidrug resistance. In addition, to save nerve function, Mak et al. (2013) proposed the following indications for emergency surgery in spinal tuberculosis: ① progressive deterioration of nerve function; ② continuous deterioration of spinal deformity; ③ failure of nonsurgical treatment, combined with continuous deterioration of nerve function and spinal deformity or severe pain caused by abscess and spinal instability; ④ diagnosis was difficult to confirm (it could not be obtained by microscopy, culture or PCR, etc., for accurate microbiological diagnosis).

### 3.5 Surgical approach

Because most of the spinal tuberculosis focus is located in the vertebral body, it is easy to enter the tuberculosis focus directly with the anterior approach, and the focus can be completely

removed, decompressed and reconstructed with a bone graft under the condition of direct vision (He et al., 2014; Li et al., 2011). In addition, Chen et al. (2012) successfully treated 9 cases of thoracolumbar tuberculosis with a large paravertebral abscess (paravertebral abscess involving more than 3 vertebrae) by anterior debridement, bone grafting and internal fixation. Liu et al. (2015) studied 60 cases of spinal tuberculosis (30 cases of thoracic tuberculosis and 30 cases of lumbar tuberculosis) according to three surgical methods (10 cases of thoracic tuberculosis and 10 cases of lumbar tuberculosis in each group) and found that the vertebral height reconstruction rate with anterior approach was 1.9 times that with posterior approach and the anterior-posterior combined approach. Zeng et al. (2015) found that the correction rate of anterior surgery in terms of the Cobb angle of kyphosis was significantly lower than that of posterior surgery and anterior and posterior combined surgery, which was consistent with the results of Hassan & Elmorshidy (2016). Additionally, Ling et al. (2015) also pointed out that the ability of the anterior approach to correct kyphosis was limited, and the Cobb angle from the anterior approach for treating spinal tuberculosis should be less than 30°.

Through the analysis of related literature and clinical practice, we summarized the indications of the combined anterior and posterior approach as follows: ① the structure of the anterior and middle columns of the spine is destroyed, accompanied by severe kyphosis; ② multisegment spinal tuberculosis; ③ extensive paravertebral abscess, flow abscess and necrotic bone; and ④ it is difficult to perform anterior internal fixation or failure to perform anterior internal fixation. In addition, because of trauma and complexity of the operation, we suggest that elderly patients and patients with poor basic conditions should receive this treatment cautiously. At the same time, the operation also has higher requirements for the technical level of the operators.

#### 4 Conclusion and prospect

For surgery on spinal tuberculosis patients, we should understand the timing of preoperative antituberculosis treatment and the opportunity for flexible operations. At present, three kinds of conventional operations have advantages and disadvantages. There is not a “universal operation” in clinical practice, so we cannot blindly pursue and focus on a certain operation approach. When choosing operation mode, clinicians should understand the advantages, disadvantages. With the wide application of minimally invasive technology in clinical disciplines and the improvement, there will be a breakthrough in the treatment of spinal tuberculosis.

#### Abbreviations

PKP: percutaneous balloon kyphoplasty. CT: computed tomography. MRI: magnetic resonance imaging. ESR: erythrocyte sedimentation rate. CRP: C-reactive protein. RFP: rifampin. INH: isoniazid. PZA: pyrazinamide. EMB: ethambutol. SM: streptomycin.

#### Conflict of interest

None.

#### Funding

None.

#### Author contributions

Conceptualization: Xiangran Sun, Ling Yu, Yubo Shi, and Weichun Guo. Investigation: Xiangran Sun, Ling Yu, Jian Yang, Yubo Shi, and Weichun Guo. Resources: Xiangran Sun, Ling Yu, Jian Yang and Yubo Shi. Writing – original draft: Xiangran Sun, Ling Yu, and Yubo Shi. Writing – review & editing: Xiangran Sun, Ling Yu, Yubo Shi, and Weichun Guo.

#### References

- Chauhan, D. S., Sharma, R., Parashar, D., Das, R., Sharma, P., Singh, A. V., Singh, P. K., Katoch, K., & Katoch, V. M. (2018). Rapid detection of ethambutol-resistant Mycobacterium tuberculosis in clinical specimens by real-time polymerase chain reaction hybridisation probe method. *Indian Journal of Medical Microbiology*, 36(2), 211-216. [http://dx.doi.org/10.4103/ijmm.IJMM\\_14\\_304](http://dx.doi.org/10.4103/ijmm.IJMM_14_304). PMID:30084413.
- Chen, M., Zhao, J. M., Li, B., Peng, X. Z., Su, W., Sha, K., & Wu, Z. G. (2012). The clinical study of anterior approach operation for the thoracic and lumbar tuberculosis with huge abscess. *Zhongguo Jizhu Jisui Zazhi*, 22(5), 433-438.
- Doan, T. N., Eisen, D. P., Rose, M. T., Slack, A., Stearnes, G., & McBryde, E. S. (2017). Interferon-gamma release assay for the diagnosis of latent tuberculosis infection: a latent-class analysis. *PLoS One*, 12(11), e0188631. <http://dx.doi.org/10.1371/journal.pone.0188631>. PMID:29182688.
- Hassan, K., & Elmorshidy, E. (2016). Anterior versus posterior approach in surgical treatment of tuberculous spondylodiscitis of thoracic and lumbar spine. *European Spine Journal*, 25(4), 1056-1063. <http://dx.doi.org/10.1007/s00586-016-4451-2>. PMID:26922735.
- He, M., Xu, H., Zhao, J., & Wang, Z. (2014). Anterior debridement, decompression, bone grafting, and instrumentation for lower cervical spine tuberculosis. *The Spine Journal*, 14(4), 619-627. <http://dx.doi.org/10.1016/j.spinee.2013.06.076>. PMID:24314763.
- Jain, A. K., Dhammi, I. K., Prashad, B., Sinha, S., & Mishra, P. (2008). Simultaneous anterior decompression and posterior instrumentation of the tuberculous spine using an anterolateral extrapleural approach. *The Journal of Bone and Joint Surgery. British Volume*, 90-B(11), 1477-1481. <http://dx.doi.org/10.1302/0301-620X.90B11.20972>. PMID:18978269.
- Li, M., Du, J., Meng, H., Wang, Z., & Luo, Z. (2011). One-stage surgical management for thoracic tuberculosis by anterior debridement, decompression and autogenous rib grafts, and instrumentation. *The Spine Journal*, 11(8), 726-733. <http://dx.doi.org/10.1016/j.spinee.2011.06.009>. PMID:21798815.
- Ling, T., Liu, L., Yang, X., Qiang, Z., Hu, X., & An, Y. (2015). Revision surgery for spinal tuberculosis with secondary deformity after treatment with debridement, instrumentation, and fusion. *European Spine Journal*, 24(3), 577-585. <http://dx.doi.org/10.1007/s00586-014-3742-8>. PMID:25542385.
- Liu, P., Sun, M., Li, S., Wang, Z., & Ding, G. (2015). A retrospective controlled study of three different operative approaches for the treatment of thoracic and lumbar spinal tuberculosis: three years of follow-up. *Clinical Neurology and Neurosurgery*, 128, 25-34. <http://dx.doi.org/10.1016/j.clineuro.2014.10.019>. PMID:25462091.
- Mak, K. C., & Cheung, K. M. (2013). Surgical treatment of acute TB spondylitis: indications and outcomes. *European Spine Journal*,

- 22(Suppl. 4), 603-611. <http://dx.doi.org/10.1007/s00586-012-2455-0> PMID:22895736.
- Oommen, S., & Banaji, N. (2017). Laboratory diagnosis of tuberculosis: advances in technology and drug susceptibility testing. *Indian Journal of Medical Microbiology*, 35(3), 323-331. [http://dx.doi.org/10.4103/ijmm.IJMM\\_16\\_204](http://dx.doi.org/10.4103/ijmm.IJMM_16_204). PMID:29063875.
- Shi, G. C. (2018). Application of Different Imaging Methods in Diagnosis of Spinal Tuberculosis. *Chinese Journal of Ct & Mri*, 23(16), 86-89.
- Shi, T., Zhang, Z., Dai, F., Zhou, Q., He, Q., Luo, F., Hou, T., & Xu, J. (2016). Retrospective Study of 967 Patients With Spinal Tuberculosis. *Orthopedics*, 39(5), e838-e843. <http://dx.doi.org/10.3928/01477447-20160509-03>. PMID:27172367.
- Yin, X. H., Liu, S. H., Li, J. S., Chen, Y., Hu, X. K., Zeng, K. F., Yu, H. G., Zhou, Z. H., & Zhang, H. Q. (2016). The role of costotransverse radical debridement, fusion and postural drainage in the surgical treatment of multisegmental thoracic spinal tuberculosis: a minimum 5-year follow-up. *European Spine Journal*, 25(4), 1047-1055. <http://dx.doi.org/10.1007/s00586-015-4283-5>. PMID:26467341.
- Zeng, H., Shen, X., Luo, C., Xu, Z., Zhang, Y., Liu, Z., & Wang, X. (2015). Comparison of three surgical approaches for cervicothoracic spinal tuberculosis: a retrospective case-control study. *Journal of Orthopaedic Surgery and Research*, 10(1), 1-10. <http://dx.doi.org/10.1186/s13018-015-0238-0>. PMID:26135121.
- Zhang, Q., Zhang, Q., Sun, B. Q., Liu, C., Su, A. N., Wang, X. H., Liu, N., Zhang, J., Kang, J., & Hou, G. (2018). GeneXpert MTB/RIF for rapid diagnosis and rifampin resistance detection of endobronchial tuberculosis. *Respirology (Carlton, Vic.)*, 23(10), 950-955. <http://dx.doi.org/10.1111/resp.13316>. PMID:29691960.