

Superficial keratectomy and 360° conjunctival flap for bullous keratopathy in a dog: a case report

[*Recobrimento conjuntival em 360° e ceratectomia superficial na ceratite bolhosa em cão: relato de caso*]

J.P.D. Ortiz, C.B.S. Lisboa, F.L.C. Brito, B. Martins, J.L. Laus

Faculdade de Ciências Agrárias e Veterinárias - UNESP
Via de Acesso Prof. Paulo Donato Castellane, s/n
14884-900 – Jaboticabal, SP

ABSTRACT

A case of a two-year-old male Pinscher with a history of discomfort in the right eye was reported. The left eye had been enucleated by the referring veterinarian due to the same symptom with unsuccessful clinical treatment. The Schirmer tear test value was elevated and a decreased intraocular pressure was observed by applanation tonometry. Biomicroscopy revealed profuse corneal edema and keratoconus and fluorescein staining was negative. Gonioscopy and ophthalmoscopy did not provide any relevant data due to the corneal alterations. Bullous keratopathy was diagnosed. Surgery was performed in two steps: 1) superficial keratectomy and 360° conjunctival flap, and 2) superficial keratectomy to restore corneal transparency. Thirty days after the second superficial keratectomy, the third eyelid flap was removed. Conjunctivalization of the upper nasal quadrant of the cornea was observed. The axial portion of the cornea was transparent and vision was restored.

Keywords: dog, bullous keratopathy, superficial keratectomy, 360° conjunctival flap

RESUMO

Relata-se o caso ocorrido em um cão, da raça Pinscher, com dois anos de idade e histórico de desconforto no olho direito. O olho esquerdo havia sido enucleado por outro profissional, por apresentar os mesmos sinais, cujo tratamento clínico instituído não lograra êxito. O valor do teste da lágrima de Schirmer encontrava-se aumentado e identificou-se diminuição da pressão intraocular à tonometria de applanção. Observaram-se, à biomicroscopia, edema corneal profuso e ceratocone, e o teste da fluoresceína foi negativo. Gonioscopia e oftalmoscopia não lograram fornecer dados relevantes dadas as condições da córnea. Diagnosticou-se ceratite bolhosa. Optou-se pelo tratamento cirúrgico, que fora realizado em duas etapas: 1- ceratectomia superficial e “flap” conjuntival de 360°; 2- ceratectomia superficial para devolver transparência à córnea. Transcorridos 30 dias da segunda ceratectomia superficial, o “flap” de terceira pálpebra foi desfeito. Observou-se conjuntivalização do quadrante nasal superior da córnea, córnea clara no eixo visual e retorno da visão.

Palavras-chave: cão, ceratopatia bolhosa, ceratectomia superficial, recobrimento conjuntival em 360°

INTRODUCTION

Bullous keratopathy is observed as corneal edema and by the epithelial or subepithelial bullae formation as a result of endothelial decompensation, which causes stromal hyperhydration, pain, and vision loss (Kirschner

et al., 1989; Severin, 1995). The accumulation of fluids into the stroma can lead to a five-fold increase in corneal thickness (Severin, 1995). The embedded stroma detaches from the epithelium, creating the corneal bullae. Associated epithelial rupture and ulceration have been reported (Cooley and Dice, 1990; Whitley and Gilger, 1999).

The most frequently reported clinical signs of bullous keratopathy include an abnormal corneal curvature (keratoconus) and neovascularization in some cases. The disease can be uni- or bilateral (Whitley and Gilger, 1999) and affects all breeds, most frequent Boston Terriers and Chihuahuas since they have fewer endothelial cells (Martin and Dice, 1982). Triggering factors are events that could lead to endothelial cells loss (Severin, 1995; Whitley and Gilger, 1999). The most common conditions are uveitis, intraocular surgery, traumas, and decreased endothelial cell density due to aging (Gwin *et al.*, 1982).

Treatment goal is restoring vision and reduce ocular discomfort. Depending on its cause, clinical or surgical approaches can be chosen. Possible treatments include topical 5% sodium chloride, topical steroids, antiglaucoma drugs, therapeutic contact lenses, biological membrane grafts, anterior stromal puncture, and penetrating keratectomy (Pires *et al.*, 1999; Whitley and Gilger, 1999).

Superficial keratectomy consists on the excision of a corneal lamella (epithelium and approximately the anterior half of the stroma). This surgery is indicated for feline corneal sequestration; stromal abscesses; corneal tumors; corneal degenerations, melanosis, and dermoids (Arentsen, 1993).

A 360° conjunctival flap is recommended for geographic corneal lesions, (superficial and extensive lesions). A 360° conjunctival flap is placed by the excision of 360° of the bulbar conjunctiva from the limbus and pushed to cover the cornea, followed by suture of its borders. The procedure offers trophic support, accelerating corneal repair (Nasise, 1985; Helper, 1989).

CASE REPORT

A two-year-old male Pinscher was referred to a veterinary Teaching Ophthalmology Service, with a history of swelling of the right eye bulb, discomfort, and visual deficit. The left eye had been enucleated by another veterinarian due to the onset of the same clinical signs. Schirmer tear test (TLS Schirmer: Ophthalmos, Brasil) value was elevated and applanation tonometry revealed a decreased intraocular pressure (Tono pen XL – Mentor Medical Systems). Slit lamp biomicroscopy (Slit Lamp SL – 14 – Kowa Company Ltd.) revealed diffuse corneal edema

and keratoconus (Figures 1 and 2). The fluorescein test (Fluorescein Strips – Ophthalmos, Brasil) was negative. Gonioscopy and ophthalmoscopy were not possible to be performed due to severe corneal edema.

Surgical treatment was chosen in order to preserve the animal vision, and it was performed in two steps: 1) superficial keratectomy (Figure 3) followed by a 360° conjunctival flap maintained for 60 days; 2) superficial keratectomy 120 days after the first procedure in order to restore corneal transparency. The patient received 0.5mg/kg levomepromazine (Neozine - Rhodia Farma Ltda.) and 5mg/kg meperidine (Meperidine - Hoechst Marion Roussel.) as pre-anesthetic medication. Anesthesia was induced with 6mg/kg propofol (Deprivan - Zeneca Farmacêutica do Brasil Ltda.) and was maintained with isoflurane (Forane - Abbott Labs do Brasil Ltda.) in a closed circuit. The eye was fixed with three conjunctival sutures using unabsorbable synthetic 3-0 suture. Anesthetic eyedrops (Anesthetic – Sterile Ophthalmic Solution.) were instilled and superficial keratectomy was performed using the quadrant technique. Next, a 360° conjunctival flap was placed and the conjunctival borders were sutured. During postoperative period, 3% chondroitin sulfate A eyedrops (Dunason - Alcon Labs. do Brasil Ltda.) were administered at regular 8-hour intervals and 3% tobramycin eyedrops (Tobrex eyedrops - Alcon Labs. do Brasil Ltda.) were instilled at 4-hour intervals, both for 30 consecutive days. In addition, topical 1% atropine (Atropine eyedrops 1% - Allergan – Frumtost.) was administered every 24 hours during four days.

Postoperative evaluation showed good adherence of the conjunctival flap to the cornea. Sixty days after the procedure, bulbar conjunctiva not adhered to the cornea was excised. A second superficial keratectomy was performed 120 days after the first procedure (Figure 4), followed by placement of third eyelid flap. Postoperative therapy consisted on the same therapeutic protocol as used in the first surgery. Third eyelid flap was removed 30 days after the second superficial keratectomy. Pigmentation of the temporal nasal quadrant of the cornea and conjunctivalization in the inferior nasal quadrant were observed. Axial cornea was transparent (Figure 4).

Superficial keratectomy...

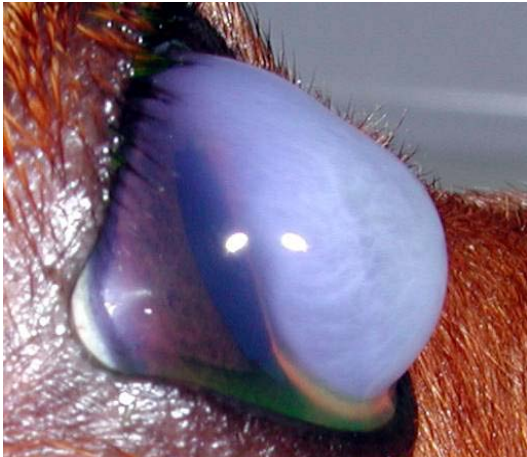

Figure 1. Photograph of the right eye of an adult Pinscher with bullous keratitis. Note the presence of corneal edema, irregularities in corneal curvature (keratoconus), and the absence of fluorescein staining.

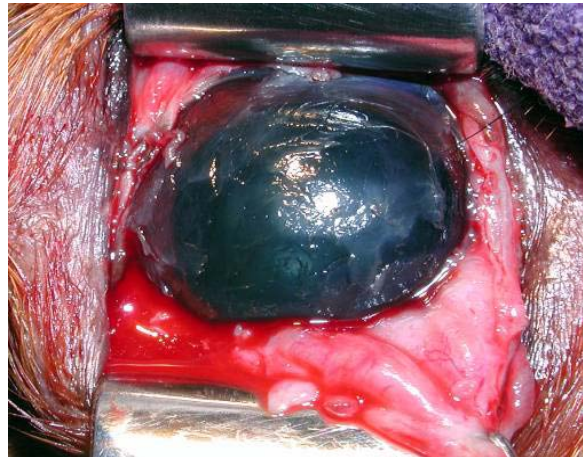


Figure 2. Photograph of the right eye of an adult Pinscher immediately after the first superficial keratectomy and excision of the bulbar conjunctiva.

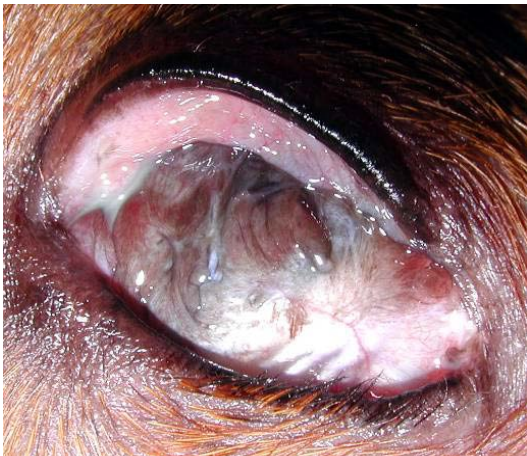

Figure 3. Photograph of the right eye of an adult Pinscher 60 days after superficial keratectomy and placement of a 360° conjunctival flap. Note the extensive conjunctivalization.

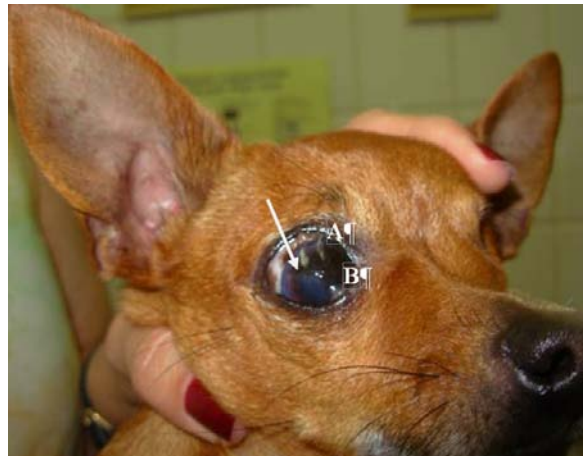

Figure 4. Photograph of the right eye of an adult Pinscher after removal of the nictitating membrane flap. Note the presence of a transparent cornea at visual axis (white arrow), secondary corneal melanosis in the remaining visual axis (A), and remnants of conjunctivalization (B).

DISCUSSION

Frequent clinical signs of bullous keratopathy, also observed in the present case, include intense corneal edema, corneal deformation (keratoconus), and visual acuity deficiency (Kirschner *et al.*, 1989; Severin, 1995). Corneal deturgescence is mediated by endothelial cells (sodium/potassium pump) and epithelial activity. Alterations in both endothelium and epithelium can lead to corneal edema. In addition, stromal

hyperhydration may cause ulcers (Cooley and Dice, 1990; Whitley and Gilger, 1999). However, corneal ulcers were not observed in the present case.

Endothelial decompensation normally results from damage to endothelial cells which exhibit poor regeneration. Hazardous conditions include uveitis, intraocular surgery, and spontaneous trauma (Severin, 1995; Whitley and Gilger, 1999). However, in the present case, the clinical

history showed no evidence of any type of damage. A reduction in endothelial cell density due to aging (Gwin *et al.*, 1982), which is equally responsible for keratoconus, cannot be implied in the present case since the animal was young.

Penetrating keratectomy has been recognized as an elective treatment for bullous keratopathy. However, the procedure is not routinely performed and is associated with numerous complications. Other therapeutic options such as the administration of 5% sodium chloride, topical steroids, and antiglaucoma preparations; therapeutic contact lenses; biological membrane grafts, and anterior stroma puncture present poor outcomes (Pires *et al.*, 1999; Whitley and Gilger, 1999).

Superficial keratectomy is indicated for conditions such as feline corneal sequestration, stromal abscesses, tumors, degenerations, melanosis, and dermoids (Arentsen, 1993), but not for bullous keratitis. Several techniques are available but the most frequently performed in veterinary practice is the quadrant technique (Nasissse, 1985; Helper, 1989). This approach was used in the present study in combination with a conjunctival flap with good results. Placement of a 360° conjunctival flap offers trophic support and the technique is indicated as therapeutic approach to ulcerative keratitis (Nasissse, 1985; Helper, 1989; Severin, 1995; Whitley and Gilger, 1999). In the present case, the flap was placed immediately after superficial keratectomy.

Non-adhered bulbar conjunctiva was excised from the cornea 60 days after the procedure, since the minimum recommended period is three to four weeks (Nasissse, 1985). After 120 days, another superficial keratectomy was performed to restore transparency in the conjunctivalized visual axis. This procedure was followed by a nictitating membrane flap placement, which offers protection and is indicated for superficial ulcerations. In addition, third eyelid flaps permit a longer action of ocular topical drugs and should be maintained for a minimum period of 15 days (Nasissse, 1985; Blogg, 1989; Helper, 1989; Severin, 1995; Whitley and Gilger, 1999). After removing the flap, a transparent central cornea was observed. Dazzle, menace, and direct pupillary reflexes were observed on that

occasion. The nasal and temporal fields were pigmented and corneal conjunctivalization was observed at six o'clock position.

A third superficial keratectomy for excision of the remnant pigmented cornea was not necessary since the central cornea was transparent. Moreover, the risk of perforation due to the reduction in corneal thickness was imminent

The reasons why endothelial decompensation did not reoccur are unknown. One may speculate that the repeated interventions also exerted some beneficial effect on the corneal endothelium, a hypothesis that should be confirmed in future studies by specular microscopy. Despite the good results obtained in the present case, further detailed investigations are necessary to identify and characterize the endothelial events that result from repeated superficial keratectomies and conjunctival flaps.

REFERENCES

- ARENSEN, J.J. Lamellar grafting. In: BRIGHTBILL, F.S.; MCGHEE, C.N.J.; McDONNELL, P.J. *Corneal Surgery – theory, technique and tissue*. 2.ed. St. Louis: Mosby-Year Book, 1993. p.360-370.
- BLOGG, J.R.; DUTTON, A.G.; STANLEY, R.G. Use of third eyelid flaps to repair full-thickness defects in the cornea and sclera. *J. Am. Anim. Hosp. Assoc.*, v.25, p.505-512, 1989.
- COOLEY, P.L.; DICE, P.F. II. Corneal dystrophy in the dog and cat. *Vet. Clin. N. Am.: Small Anim. Pract.*, v.20, p.681-692, 1990.
- GWIN, R.M.; LERNER, I.; WARREN, J.K. *et al.* Decrease in canine corneal endothelial cell density and increase in corneal thickness as function of age. *Invest. Ophthalmol. Visual Sci.*, v.22, p.267-271, 1982.
- HELPER, L.C. Diseases and surgery of the cornea and sclera. In: _____. *Magrane's Canine Ophthalmology*. 4.ed. Philadelphia: Lea & Febiger, 1989. p.102-149.
- KIRSCHNER, S.E.; NIYO, Y.; BETTS, D.M. Idiopathic persistent corneal erosions: clinical and pathological findings in 18 dogs. *J. Am. Anim. Hosp. Assoc.*, v.25. p.84-90, 1989.

Superficial keratectomy...

MARTIN, C.L.; DICE, P.E. Corneal endothelial dystrophy in the dog. *J. Am. Anim. Hosp. Assoc.*, v.18, p.327-336, 1982.

NASISSE, M.P. Canine ulcerative keratitis. *Comp. Contin. Educ.*, v.7, p.686-701, 1985.

PIRES, R.T.; TSENG, S.C.; PRABHASAWAT, P. *et al.* Amniotic membrane transplantation for symptomatic bullous keratopathy. *Arch. Ophthalmol.*, v.117, p.1271-1291, 1999.

SEVERIN, G.A. Cornea. In: MAWHINEY, H. (Ed). *Severin's veterinary ophthalmology notes*. Fort Collins: GA Severin, 1995. p.285-325.

WHITLEY, R.D.; GILGER, B.C. Diseases of the canine cornea and sclera. In: GELATT, K.N. (Ed). *Veterinary ophthalmology*. Baltimore: Lippincott Williams & Wilkins, 1999. p.635-662.