

## B-mode and Doppler ultrasonography of adrenal glands of healthy dogs

[*Ultrassonografia modo B e Doppler das glândulas adrenais de cães saudáveis*]

S. Fernandez<sup>1</sup>, M.A.R. Feliciano<sup>1\*</sup>, S.B. Crivellenti<sup>2</sup>, L.Z. Crivellenti<sup>2</sup>, A.P.R. Simões<sup>1</sup>, M.C. Maronezi<sup>1</sup>, R.R. Uscategui<sup>1</sup>, C.R. Capela<sup>1</sup>, C. Gilor<sup>3</sup>, A.E. Santana<sup>1</sup>, W.R.R. Vicente<sup>1</sup>

<sup>1</sup>Faculdade de Ciências Agrárias e Veterinárias - UNESP - Jaboticabal, SP

<sup>2</sup>Universidade de Franca - (UNIFRAN) - Franca, SP

<sup>3</sup>The Ohio State University - Columbus, United States

### ABSTRACT

The aim of this study was to determine the vascular indices of adrenal blood flow in healthy dogs (systolic velocity – SV; diastolic velocity – DV; resistance index - RI). Eighteen dogs (thirty six adrenal) were studied. Physical examination, biochemical profile and dexamethasone suppression test were performed to determine general health status. Echotexture, size, contours and margins, and overall shape of the adrenal gland (right and left) were assessed via ultrasound. By spectral Doppler of the phrenic-abdominal artery, the SV, DV, and RI were acquired. Animals did not show alterations in clinical and laboratory examination and suppression of cortisol. Normal homogeneous and echotexture, regular contours and margins and normal shape and size were verified via B mode. Spectral Doppler of the phrenic-abdominal artery showed monophasic-patterned waves and low vascular resistance and systolic peak evident with means values: left adrenal – SV = 31.34cm/s, DV = 9.54cm/s and RI = 0.69; and right adrenal - SV = 27.83cm/s, DV = 7.71cm/s and RI = 0.68. Doppler evaluation of adrenal was easily implemented and may provide base line data in the study, allowing for the use of this technique as a diagnostic tool for diseases of the dog's adrenal.

Keywords: canine, adrenal glands, ultrasound, vascularization

### RESUMO

*Objetivou-se determinar os índices vasculares do fluxo sanguíneo das glândulas adrenais de cães saudáveis (velocidade sistólica - VS; velocidade diastólica - VD; o índice de resistência - IR). Foram utilizados neste estudo 18 cães (36 adrenais). Foram realizados exame físico, perfil bioquímico e teste de supressão com dexametasona para determinar o estado geral de saúde (higidez). Ecotextura, ecogenicidade, tamanho, contornos e margens e o formato das glândulas adrenais (direito e esquerdo) foram avaliados por meio da ultrassonografia convencional. Ao Doppler espectral da artéria frênico-abdominal, foram adquiridos a VS, a VD e o IR. Os animais não apresentaram alterações aos exames clínico, laboratorial e de supressão do cortisol. Ao exame ultrassonográfico, foram verificados ecotextura homogênea, ecogenicidade, formato e tamanhos normais, além de os contornos e as margens serem regulares. Ao Doppler espectral da artéria frênico-abdominal, verificaram-se ondas com padrão monofásico, com resistência vascular baixa e pico sistólico evidente, sendo os valores médios: adrenal esquerda – VS = 31,34cm/s, VD = 9,54cm/s e IR = 0,69; e adrenal direita – VS = 27,83cm/s, VD = 7,71cm/s e IR = 0,68. A avaliação Doppler das adrenais foi facilmente implementada e pode fornecer dados de referência, permitindo a utilização dessa técnica como uma ferramenta de diagnóstico para doenças das adrenais em cães.*

*Palavras-chave: canino, glândulas adrenais, ultrassom, vascularização*

---

Recebido em 3 de agosto de 2015

Aceito em 11 de fevereiro de 2016

\*Autor para correspondência (*corresponding author*)

E-mail: marcusfeliciano@yahoo.com.br

## INTRODUCTION

Doppler ultrasound is a diagnostic technique used to evaluate the hemodynamics and other characteristics of blood vessels (presence of vascularization, type, direction of flow and vascular indices) in various tissues in real time. Beyond the field of cardiology, this technique has been used in veterinary medicine (Carvalho *et al.*, 2008a), for example in the assessment of gestation in bitches (Feliciano *et al.*, 2014a), differentiation of mammary neoplasms (Feliciano *et al.*, 2012), and evaluation of animals with cataracts (Feliciano *et al.*, 2013a).

The vascularization of the canine adrenal is different from other species and include: branches from the phrenic-abdominal artery (main vessel - blood nutrition), cranial adrenal branch, abdominal aorta, middle adrenal artery, branches from the renal artery, caudal adrenal branch and abdominal branches of the lumbar artery (Pey *et al.*, 2011). There are no reports on the assessment of cranial phrenic-abdominal artery in dogs via color and spectral Doppler.

The left and right adrenal glands are located in the retroperitoneal, cranially and medially to the corresponding kidney, near the thoraco-lumbar junction. The adrenal glands secrete a number of hormones that are essential for the homeostasis of the organism and its survival in stressful situations (Cunningham 2004; Dyce *et al.*, 2004), which demonstrates the great importance of maintenance of an adequate blood flow to these structures, indispensable to its proper functioning. The adrenal glands have one of the greatest blood supplies per gram of tissue of any organ and in dogs the blood is supplied to the adrenal glands through small branches of the aorta, the phrenic-abdominal vessels (Dyce *et al.*, 2004; Kealy *et al.*, 2012).

Neoplastic disorders of the adrenal glands are common. They are most commonly associated with excess of at least one hormone and the respective clinical and clinicopathological abnormalities. Local invasion and remote metastasis are not uncommon as well. The treatment and prognosis of adrenal tumors vary considerably depending on the type of tumor but the exact diagnosis can be challenging. Changes in blood flow may be useful in pre-surgical

diagnosis as is the case in other tissues (Davis *et al.*, 2012).

Considering the importance of evaluation of the adrenal glands in dogs with clinical signs of adrenal dependent hyperadrenocorticism pituitary dependent hyperadrenocorticism and hypoadrenocorticism, and the novelty of the Doppler evaluation to characterize the vascularization of these structures in small animals, the aim of this study was to determine the vascular indices of blood flow of adrenal glands in healthy dogs, measuring the values for systolic velocity (SV), end diastolic velocity (RV) and resistance index (RI).

## MATERIAL AND METHODS

This study was performed with the approval of the Animal Ethics and Welfare Committee of the Faculdade de Ciências Agrárias e Veterinárias, UNESP – Universidade Estadual Paulista, Campus Jaboticabal, Brazil (protocol no 018.897/13).

Eighteen adult and intact healthy dogs (thirty six adrenal glands) were studied (twelve female and six males), not castrated, one to five years of age (mean age =  $3.0 \pm 1.44$  years), from small to medium size and weighing between 2.0 at 15.0kg (mean =  $8.5 \pm 3.19$ kg), with a body condition score of 6 (on a scale of 1 - 9) (Laflamme *et al.*, 2001).

Physical examination and evaluation of the CBC and biochemical profile (including urea, creatinine, alanine aminotransferase, alkaline phosphatase, cholesterol, triglycerides, total protein and albumin) were performed on all dogs to determine general health status. A dexamethasone suppression test was performed to ensure the normal function of the hypothalamic-pituitary-adrenal axis. Serum samples were obtained by venipuncture from the jugular vein to determine baseline cortisol. Subsequently, dexamethasone was administered intravenously at a dose of 0.01mL/kg. Serum was sampled again for evaluation of cortisol concentrations at 4 and 8 hours after dexamethasone administration.

After the animals were selected, the abdominal region was clipped and ultrasound gel applied for ultrasonography. No sedation was needed.

### B-mode and Doppler...

The ultrasonography was performed by a single evaluator with experience in ultrasonography examinations. B-Mode ultrasonography was performed with a 9.0 MHz linear transducer using ACUSON S2000/SIEMENS ultrasound equipment (Siemens, Munich, Germany). The echotexture (homogeneous or heterogeneous; hypo, hyperechoic or mixed) of the parenchyma, size (gland length and width of the cranial and caudal pole), contours and margins (regular or irregular) and overall shape of the adrenal gland (right and left) were assessed and categorized via B Mode ultrasound in longitudinal section.

Doppler analysis was performed after locating the largest and possibly longitudinal or oblique section of the phrenic-abdominal artery, and the angle between the Doppler beam and the long axis of the vessel was never over 60°. Color gain was adjusted to reduce excessive color noise when blood flow was too slow. A gate between 2 and 3 mm (equivalent to 2/3 of the vessel's diameter) was positioned in a central area of the vessel with apertures to measure the spectral trace of flow, spectral curve and vascular index, which were obtained automatically following software identification of the ultrasonic scanner for each waveform. A minimum of three subsequent waves were obtained to perform its evaluation. The parameters studied in the phrenic-abdominal artery were: peak systolic velocity (PSV, cm / s); end-diastolic velocity

(EDV, cm/s); and resistive index ( $RI = (V_{max} - V_{min}) / V_{max}$ ).

R Software® (R Foundation for Statistical Computing, Vienna, Austria) was used for statistical analysis. Results were initially analyzed for normality (Shapiro-Wilk test). Raw or transformed data were evaluated using ANOVA to compare right and left values, if equality was confirmed, the Pearson correlation and regression between quantitative values were made, and the general average, confidence interval and descriptive statistical were calculated. 95% significance was fixed for all tests.

### RESULTS

Clinical and laboratory examination of the dogs showed no alterations and were considered healthy. Adequate suppression of cortisol production by dexamethasone (4 and 8-hour cortisol concentration  $<1.4\mu\text{g/dL}$ ) was observed in all dogs.

At the ultrasound examination, the animals showed normal adrenal glands, with homogeneous echotexture, normal echogenicity (hypoechoic in relation to adjacent tissue – renal cortex), regular contours, and margins and normal shape and size (Table 1).

Table 1. Values (mean±standard deviation) for size of the adrenal glands of healthy dogs

Adrenal glands	Length (cm)	Width – cranial pole (cm)	Width – caudal pole (cm)
Left adrenal	1.53±0.42	0.40±0.10	0.45±0.09
Right adrenal	1.63±0.35	0.43±0.11	0.49±0.15

cm: centimeters

Doppler ultrasonography was reliably performed in all dogs, yielding images of good quality. On color Doppler, the phrenic-abdominal artery was observed in the hilar region (body) of the adrenal glands. Spectral Doppler examination of the phrenic-abdominal artery showed monophasic-patterned waves and low vascular resistance and systolic peak evident (Figure 1). The values for the vascular indices of right and left phrenic-abdominal artery are shown in Table 2.

Vascular indices of the right and left adrenal glands did not differ significantly (Table 2). Negative correlation was observed between body weight (BW), SV ( $r = -0.5159$ ;  $P = 0.009$ ;  $R^2 =$

26%;  $SV = 46.9 - 1.19 * BW$  (kg)), and DV ( $r = -0.55676$ ;  $P = 0.0038$ ;  $R^2 = 32\%$ ;  $VD = 17.6 - 0.640 * BW$  (kg)). Body weight of the animals does not present correlation with the size of the gland, but presents negative correlation with SV and DV explained by the quadratic model for SV:  $[SV = 39.5 + 0.3 \times (\text{Weight}) - 0.07 \times (\text{Weight}^2)]$ ; and the cubic model for DV:  $[DV = 16.9 \times (\text{Weight}) - 0.8 \times (\text{Weight}^2) - 0.002 (\text{Weight}^3)]$ . Additionally, the age of the animals did not correlate with any of the parameters studied and among these the SV correlate with DV ( $P = 0.009$ ); the length with the height of the gland ( $P = 0.01$ ); and RI with DV ( $P < 0.001$ ) (Figure 2).

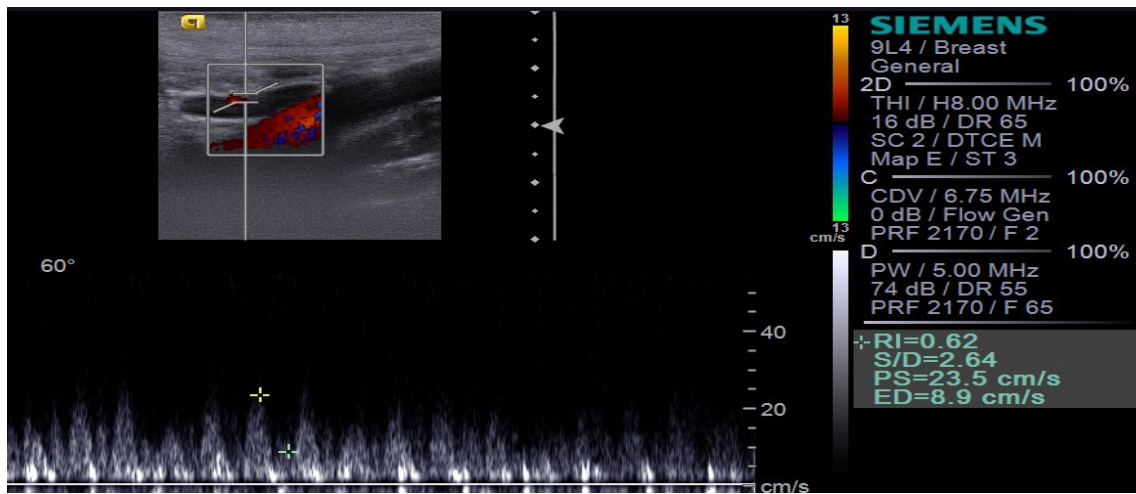


Figure 1. Color and spectral Doppler ultrasound image of adrenal in the longitudinal section of a French bulldog dog with 16.9 kg of body weight. Note the Doppler assessments to determine vascular indices in the phrenic-abdominal artery.

Table 2. Values (mean±standard deviation) for vascular indices of the phrenic-abdominal artery in adrenal glands of healthy dogs

	Doppler ultrasonography				
	Left adrenal	CI 95%	Right adrenal	CI 95%	P 5%
Systolic velocity (cm/s)	31.34±5.79	27.83 – 34.84	34.25±8.18	29.52 – 38.98	0.29
Diastolic velocity (cm/s)	9.54±3.03	7.71 – 11.38	10.72±3.75	8.55 – 12.89	0.38
Resistance index	0.69±0.07	0.65 – 0.74	0.68±0.10	0.62 – 0.74	0.68

\*5% of significance level; CI: confidence interval 95%; cm: centimeters; s: seconds

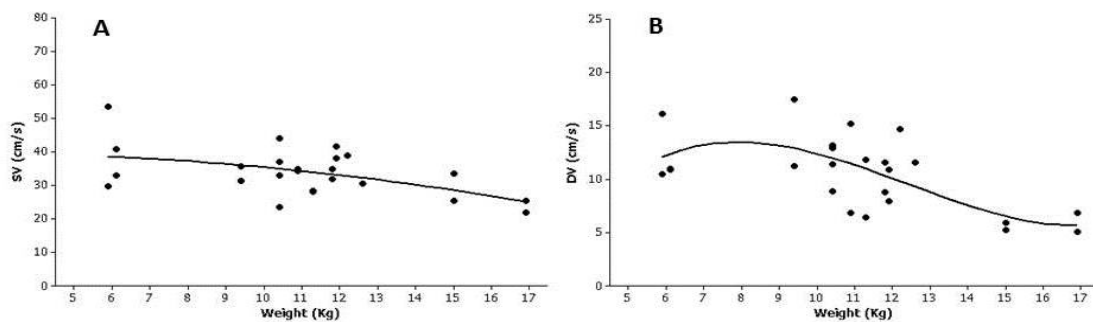


Figure 2. Graphic representation of the negative correlation between body weight of the animals and systolic velocity (SV; A) and diastolic (DV; B) of the adrenal glands in canines.

### DISCUSSION

The ultrasound B-mode is used as diagnostic method of hyperadrenocorticism (differentiation between pituitary-dependent and adrenal-dependent disease) (Behrend *et al.*, 2013), adrenal neoplasms (Davis *et al.*, 2012), and hypoadrenocorticism in dogs (Wenger *et al.*, 2010). The sonographic findings considered for the diagnosis of these diseases are based on the evaluation of the size of the glands, vascular

invasion, extent of lesions or the presence of necrosis and degeneration areas (Soulsby *et al.*, 2015). This study provides new information on the applicability of the Doppler technique to assess the blood flow of the adrenal glands of dogs, which can be addressed in the future in the study of diseased animals.

It is important to mention that conventional ultrasound cannot always be considered as a sensitive method for detection of alterations in

the adrenal gland of dogs because some patients with hyperadrenocorticism show symmetric glands with normal (normal size, echogenicity and echotexture). In part, this is related to variations in weight, age and breed that are often not taken into account in the assessment of the size of these structures (Soulsby *et al.*, 2015). As an alternative diagnostic, the Color Doppler technique has a sensitivity of 100% and specificity of 96% for the detection of vascular invasion in dogs with adrenal tumors and characterization of 86% of tumors, however, the identification of subtle vascular changes is still considered a challenge (Davis *et al.*, 2012). This justifies the study on the applicability of new techniques such as spectral Doppler and the determination of vascular indices for evaluation of the adrenal of small animals.

The spectral Doppler technique and determination of vascular indices have been widely studied in small animals, for evaluation of abdominal vessels (Carvalho *et al.*, 2008b), kidneys of canine's fetuses (Feliciano *et al.*, 2014b), maternal-fetal interaction in bitches (Feliciano *et al.*, 2014a), feline testicle (Brito *et al.*, 2015), canine fetal brain (Feliciano *et al.*, 2013b), canine eyes (Feliciano *et al.*, 2013a), and also for differentiation between malignant and benign mammary tissues (Feliciano *et al.*, 2012), and other tissues.

In the study reported here, the observed characteristics of the Doppler tracing in phrenic-abdominal arteries were similar to that described in literature (Carvalho *et al.*, 2008b) for the evaluation of blood flow in the abdominal aorta of canines. The velocity described (Carvalho *et al.*, 2008b) for the systolic velocity of the abdominal aorta varied from 44.00cm/s and 135.18cm/s and the diastolic velocity between 76.20cm/s and 84.40cm/s. These values are higher than the results obtained in the study reported here (Table 2), which can be explained by the difference in vessel diameter that is proportional to the values of vascular indices (Kamikawa and Bombonato 2007).

A negative relationship found between body weight and blood velocities has been reported previously in the carotid artery of healthy young adult humans (Yoshizaki *et al.*, 2007) and has been explained by increase in blood pressures that is associated with greater body weight.

Future studies would need to assess the impact of this relationship in a wider variety of breeds and sizes, specifically in dogs weighing >15kg's. These results provide relevant information that improve the data obtained by Soulsby *et al.* (2015) that have observed a difference between the size and body weight of the animals, specifically in size of the thickness of the caudal pole (0.54cm for dogs <10kg; 0.68cm for dogs 10–30kg; and 0.80cm for dogs >30kg).

It is important to comment on some limitations of this study. First, there is an inherent difficulty in measuring the phrenic-abdominal arteries because they are small structures, and because of interference related to the presence of gas content in the gastrointestinal tract and constant movement from breathing. A second limitation is the relatively small number of dogs studied and the narrow range of body weights and breeds. Still, this pilot study provides important information on the validation of the technique and on how to obtain reference values for canines. However, is necessary to conduct a study with a larger number of animals and in particular, to evaluate dogs of different breeds, body weights, sex and age ranges to verify the interference of these variables on the findings of Doppler in the canine adrenal.

We hypothesize that after the standardization of the reference values of the adrenal gland Doppler in healthy dogs and with a larger sample size, the differences in characteristics of vascularization in diseased tissues would be useful for differentiating benign and malignant adrenal tumors in dogs, as previously in tissues in small animals, such as the mammary glands in bitches (Feliciano *et al.*, 2012). On the other hand, Doppler evaluation would be important to detect adrenal atrophy in dogs with hypoadrenocorticism, considering that continuous administration of dexamethasone is able to induce a dramatic breakdown of plasmatic ACTH levels, and cause regression of the adrenal tissue and vasculature (Thomas *et al.*, 2004).

## CONCLUSION

The use of the Doppler technique in the evaluation of phrenic-abdominal arteries of healthy adult dogs was performed with success and can contribute to baseline data, allowing the

use of this technique as a diagnostic tool for diseases of the dog's adrenal glands.

#### ACKNOWLEDGEMENTS

The authors thank FAPESP for the research grant and Jovem Pesquisador (processes 2012/16635-2 and 2013/06443-1).

#### REFERENCES

BEHREND, E.N.; KOOISTRA, H.S.; NELSON, R. *et al.* Diagnosis of spontaneous canine hyperadrenocorticism: 2012 ACVIM consensus statement (small animal). *J. Vet. Intern. Med.*, v.27, p.1292-1304, 2013.

BRITO, M.S.B.; FELICIANO, M.A.R.; COUTINHO, L.N. *et al.* Doppler and contrast-enhanced ultrasonography of testicles in adult domestic felines. *Reprod. Domest. Anim.*, v.5, p.730-734, 2015.

CARVALHO, C.F.; CHAMMAS, M.C.; CERRI, G.G. Physical principles of Doppler ultrasonography. *Ciênc. Rural*, v.38, p.872-879, 2008a.

CARVALHO, C.F.; CHAMMAS, M.C.; STERMANN, F.A. *et al.* Ultra-sonografia dúplex-Doppler na avaliação morfológica e hemodinâmica das artérias aorta e mesentérica cranial em cães. *Braz. J. Vet. Res. Anim. Sci.*, v.45, p.24-31, 2008b.

CUNNINGHAM J.G. Glândulas endócrinas e suas funções. In: \_\_\_\_\_. (Ed.). *Tratado de fisiologia veterinária*. 3.ed. Rio de Janeiro: Guanabara Koogan, 2004. cap.33. p.350-381.

DAVIS, M.K.; SCHOCHET, R.A.; WRIGLEY, R. Ultrasonographic identification of vascular invasion by adrenal tumors in dogs. *Veterinary Radiology & Ultrasound*, v.53, n.4, p.442-445, 2012.

DYCE, K.M.; SACK, W.O.; WENSING, C.J.G. Glândulas adrenais. In: DYCE, K.M.; SACK, W.O.; WENSING, C.J.G. (Eds.). *Tratado de anatomia veterinária*. 3.ed. Rio de Janeiro: Elsevier, 2004. p.213-214.

FELICIANO, M.A.R.; ABRAHIM, M.A.; PEIXOTO, R.V.R. *et al.* Contribution of ocular B-mode and triplex Doppler in the evaluation of 10 Poodle dogs with cataracts. *Arq. Bras. Med. Vet. Zootec.*, v.65, p.359-363, 2013a.

FELICIANO, M.A.R.; CARDILLI, D.J.; NEPOMUCENO A.C. *et al.* Echobiometrics kidney and renal artery triplex Doppler of canine fetuses. *Arq. Bras. Med. Vet. Zootec.*, v.6, p.445-449, 2014a.

FELICIANO, M.A.R.; NEPOMUCENO, A.C.; CARDILLI, D.J. *et al.* Triplex Doppler ultrasonography in prenatal of pregnant bitches. *Acta. Sci. Vet.*, v.42, p.1172-1176, 2014b.

FELICIANO, M.A.R.; NEPOMUCENO, A.C.; CRIVELARO, R.M. *et al.* Foetal echoencephalography and Doppler ultrasonography of the middle cerebral artery in canine fetuses. *J. Small Anim. Pract.*, v.54, p.149-152, 2013b.

FELICIANO, M.A.R.; VICENTE, W.R.R.; SILVA, M.A.M. Conventional and Doppler ultrasound for the differentiation of benign and malignant canine mammary tumours. *J. Small Anim. Pract.*, v.53, p.332-337, 2012.

KAMIKAWA, L.; BOMBONATO, P.P. Ultrassonografia da aorta abdominal e de seus ramos em cães. *Ciênc. Rural*, v.37, p.412-417, 2007.

KEALY, J.K.; MCALLISTER, H.; GRAHAM, J.P. O abdomen. In: \_\_\_\_\_. (Eds.). *Radiografia e ultrassonografia do cão e do gato*. 5.ed. Rio de Janeiro: Elsevier, 2012. p.123-126.

LAFLAMME, D.P.; HUME, E.; HARRISON, J. Evaluation of zoometric measures as an assessment of body composition of dogs and cats. *Compend. Cont. Educ. Pract.*, v.23, p.88, 2001.

PEY, P.; VIGNOLI, M.; HAERS, H. *et al.* Contrast-enhanced ultrasonography of the normal canine adrenal gland. *Vet. Radiol. Ultrasound*, v.52, p.560-567, 2011.

SOULSBY, S.N.; HOLLAND, M.; HUDSON J.A. *et al.* Ultrasonographic evaluation of adrenal gland size compared to body weight in normal dogs. *Vet. Radiol. Ultrasound*, v.56, p.317-326, 2015.

THOMAS, M.; KERAMIDAS, M.; MONCHAUX, E. *et al.* Dual hormonal regulation of endocrine tissue mass and vasculature by adrenocorticotropin in the adrenal cortex. *Endocrinology*, v.145, p.4320-4329, 2004.

WENGER, M.; MUELLER, C.; KOOK, P.H.; REUSCH, C.E. Ultrasonographic evaluation of adrenal glands in dogs with primary hypoadrenocorticism or mimicking disease. *Vet. Rec.*, v.167, p.207-210, 2010.

YOSHIZAKI, K.; OBARA, S.; NOMURA, M. *et al.* Effect of gender on blood flow velocities and blood pressure: role of body weight and height. In: ANNUAL INTERNATIONAL CONFERENCE OF THE INSTITUTE OF ELECTRICAL AND ELECTRONICS ENGINEERS, 29., 2007, Lyon. *Proceedings...* Lyon: IEEE, 2007. P.967-970.