



## Radiographic evaluation of tracheal collapse in dogs by compressive technique

[Avaliação radiográfica do colapso de traquéia em cães pela técnica compressiva]

K.G. Beltrán<sup>1</sup>, J.P.E. Pascon<sup>2\*</sup>, M.L.A. Mistieri<sup>2</sup>

<sup>1</sup>Aluno de pós-graduação – Universidade Federal do Pampa – Uruguaiiana, RS

<sup>2</sup>Universidade Federal do Pampa – Uruguaiiana, RS

### ABSTRACT

The purpose of this study was to verify the applicability of the compressive radiographic technique (pressures of 5, 10, 15 and 20mmHg) in the diagnosis of tracheal collapse in small breed dogs, in lateral cervicothoracic radiography. Out of the 50 dogs evaluated, 25 presented tracheal collapse (TG group), 23 did not present tracheal collapse (CG) and two were excluded because they did not tolerate a pressure of 20 mmHg. The TG group presented a smaller internal diameter of the trachea in the region of the fourth cervical vertebra (D4) and at the entrance of the thorax (TDE) compared to the CG group, in all the radiographic projections performed, as well as within the TG group where the compressive technique differed from conventional. Furthermore, there was a correlation between the clinical sign of coughing during cervical collar use and the presence of radiographic tracheal collapse at a pressure of 20 mmHg. It was concluded that the compressive radiographic technique was feasible and efficient in confirming the diagnosis of tracheal collapse in dogs, especially in the pressure of 20 mmHg, where it was associated with clinical signs, and can be used in isolation or complementary to the conventional technique.

Keywords: Tracheal collapse, cough, canine, small breeds

### RESUMO

O objetivo deste trabalho foi verificar a aplicabilidade da técnica radiográfica compressiva no diagnóstico do colapso de traquéia em cães de raças pequenas, por meio da comparação do diâmetro da traquéia durante a radiografia cervicotorácica lateral convencional e sobre influência da compressão externa com pressões de 5, 10, 15 e 20mmHg (técnica compressiva). Dos 50 cães avaliados, 25 apresentaram colapso de traquéia (grupo TG), 23 não apresentaram o colapso traqueal (grupo controle – CG) e dois foram excluídos por não tolerarem a pressão de 20mmHg. Os diâmetros internos da traquéia na região da quarta vértebra cervical (D4) e na entrada do tórax (DET) foram menores no grupo TG em relação ao CG, em todas as projeções radiográficas realizadas, bem como dentro do grupo TG, no qual a técnica compressiva diferiu da convencional. Houve correlação entre o sinal clínico de tosse durante o uso de coleira cervical e a presença do colapso de traquéia radiográfico, na pressão de 20mmHg. Concluiu-se que a técnica radiográfica compressiva foi exequível e eficiente na confirmação do diagnóstico do colapso de traquéia em cães, especialmente na pressão de 20mmHg, em que houve associação com sinais clínicos, podendo ser utilizada de forma isolada ou complementar à técnica convencional.

Palavras-chave: colapso de traquéia, tosse, canino, raças pequenas

### INTRODUCTION

Tracheal Collapse (TC) is one of the most recurring respiratory affections suffered by small-breed dogs, fostering several clinical symptoms ranging from sporadic coughing to

syncopal episodes (Tappin, 2016). In spite of the clinical diagnosis being apparently simple, the confirmation of the illness can be performed with different diagnostic exams. One of them, is carried out by lateral radiograph (X-ray) detection of a tracheal segmental collapse in the cervicothoracic region (Macready *et al.*, 2007),

Recebido em 5 de fevereiro de 2019

Aceito em 26 de setembro de 2019

\*Autor para correspondência (*corresponding author*)

E-mail: joaopascon@unipampa.edu.br

although the disease is detectable using fluoroscopy (Johnson *et al.*, 2015), computed tomography (Heng *et al.*, 2017), ultrasonography (Eom *et al.*, 2008), or tracheoscopy (Johnson and Fales, 2001).

The plain radiographic technique has been extensively used to detect tracheal disorders, due to low cost and less risk to patients (Maggiore, 2014). In addition to exhibiting a percentage sensitivity of 57.14% and a specificity percentage of 71.43%, by the diagnosis of tracheal collapse in dogs (Singh *et al.*, 2012; Johnson and Pollard, 2010), the low percentage is caused by the static nature of the exam or diagnosis, for the dynamic movement of the tracheal lumen, which is subject to the constant variations in the internal pressure due to the respiratory cycle (inspiration and expiration), additionally to the atmospheric pressures (Macready *et al.*, 2007).

The radiographic exam (X-ray) exhibits a low reliability by the tracheal fragility leading to inappropriate diagnostics, (Maggiore, 2014). However, application of external pressures upon the trachea during X-ray has shown to improve the diagnostic of the tracheal collapse in dogs with clinical symptoms (Canola and Borgues, 2005).

Nevertheless, the radiographic compression technique has several obstacles. For instance, due to the subjectivity in the measurement of external pressures and the subsequent interpretation, inasmuch as the criterion deemed to point out tracheal collapse among other tracheal disorders is the actual drop in size of the tracheal lumen by 50% or more. Although this parameter is currently used as the radiographic criterion of choice to diagnose this illness (Macready *et al.*, 2007), the outlined specificity range does not take into account the exertion of external pressures as an actual means to either decrease the tracheal lumen's diameter in healthy dogs or to be considered as a variable that may have an influence on the outcomes of the survey.

Therefore, the purpose of this trial was to perform a radiographic-driven evaluation of the behavior of small-breed dogs' tracheal lumen comparing the conventional lateral cervicothoracic radiography with the four levels of pressure (5, 10, 15, and 20 mmHg) of the

compressive technique. Furthermore, the trial intended to assess the applicability of this technique in the diagnosis of tracheal collapse, and to establish any correlation between several clinical findings and radiographic diagnostic of tracheal collapse.

## MATERIALS AND METHODS

The survey involved the participation of 50 small-breed dogs without previous diagnosis of tracheal collapse or other respiratory disease, randomly selected from the hospital routine: 34 females and 16 males (average weight:  $5.85 \pm 2.26$  kg; average age:  $6.37 \pm 3.73$  years). All participating dogs underwent a clinical and radiographic evaluation as approved by the governing Animal Care and Use Committee (Protocol 017/2016).

The clinical evaluation of each individual included a general physical examination, thoracic auscultation and manual compression of the trachea (cough reflex). However, episodes of cough that occur at different times such as excitement, exercise, excessive heat and/or use of the cervical collar were taken into account from a questionnaire applied to dog tutors. Therefore, no real episodes were observed, and the accuracy of the data was strictly based on the responses provided by the tutors.

Otherwise, all the cervicothoracic tracheal radiography evaluations were based on the right lateral projections (Alexander, 2014), focused on thoracic entrance, and the x-rays beams colimed between larynges and cranial border of diaphragm, without taking into account the respiratory moment. The conventional radiography was taken first, followed by compressive radiographies in a crescent order of pressure at 5, 10, 15, and 20 mmHg (Fig. 1). The radiographic images were taken with radiographic equipment (Aquila plus 300, Phillips®) equipped with a digital reading system (Carestream Directview CR®).

Tree blind evaluators independently defined the diagnostic of tracheal collapse in all radiographies, considering only the complete closure of the tracheal tract as a positive criterion, in order to avoid inaccurate results due to secondary decreases in the tracheal tract caused by external compressions. Building on

### Radiographic evaluation...

the radiographic imagery thus generated, individual dogs were divided into two main groups: A control group (CG), featuring those dogs that did not display a complete closure of any tracheal segment in any of the five radiographic screenings; and, a tracheal collapse group (TG), featuring those dogs that displayed a complete closure of the trachea in at least one of the five radiographic screenings.

In the same way, to provide more information about the compression effect on all tracheal

diameter segments, it may be crucial to use the compressive technique to define the best stent size (Montgomery *et al.*, 2015), the quantitative variables of tracheal diameter were measured as follows (Fig. 2): tracheal internal diameter in the first zone of the tracheal ring (D1); tracheal internal diameter in the region between the fourth and fifth cervical vertebrae (D4); tracheal internal diameter at the thoracic inlet (DET); and, tracheal internal diameter in the second intercostal space region (DIC).

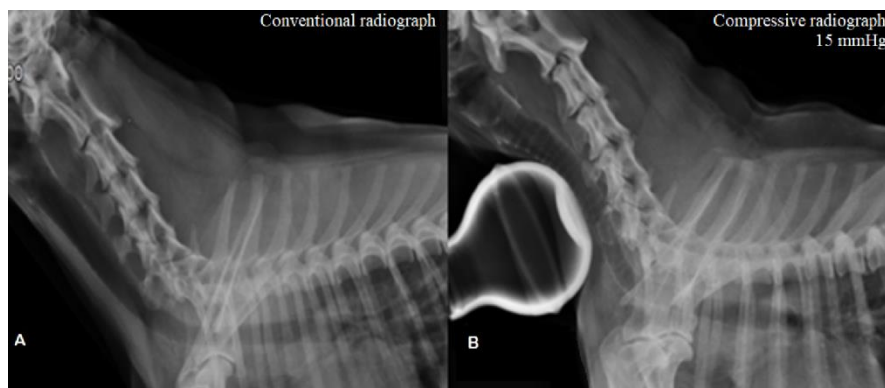


Figure 1. Radiographic images of the cervicothoracic region via a lateral right-facing screening of a dog with no tracheal closure. A: Conventional radiograph (plain), revealing a normal tracheal lumen. B: Compressive radiograph at a 15mmHg pressure level.

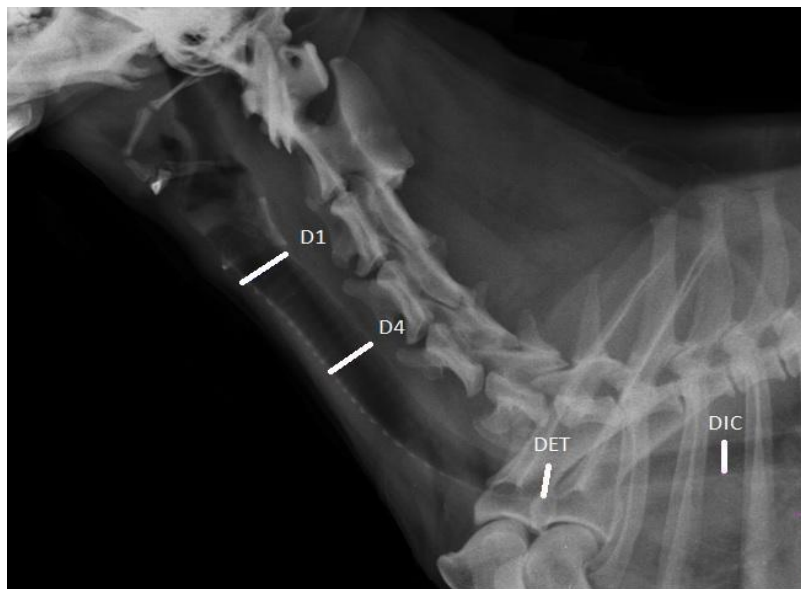

Figure 2. Radiographic image of the cervicothoracic region via a lateral right-facing screening that reveals the localized readings for all variables involved in the measurement of the trachea's internal diameter. D1 (tracheal internal diameter at the first tracheal ring zone); D4 (tracheal internal diameter at the region between the fourth and fifth cervical vertebrae); DET (tracheal internal diameter at the thoracic inlet); and, DIC (tracheal internal diameter at the second intercostal space region).

Compression strength was controlled via a closed circuit engulfing a conventional calibrated manometer attached to a rubber bulb – as per Canola and Borges (2005) – via a 25cm plastic sleeve (Fig. 3). All radiographic images were further analyzed in a DICOM (digital imaging and communication in medicine) format via specific software (Onís 2.5 free version).



Figure 3. Equipment used to control external pressure exerted upon the ventral surface of the cervical trachea during the application of the compressive technique.

The analysis, performed on the radiographic evaluation established by the three evaluators of tracheal collapse, was accomplished by applying Kappa tests. All quantitative variables involved in the different radiographic techniques were subjected to an Analysis of Variance (ANOVA) with a significance level of 95%, and were additionally compared as part of the analysis of the CG and TG groups, as well as within each one of these groups, through the Tukey HSD test (GraphPad Prism®, edition 5.0 for Windows®, GraphPad software, San Diego - California, USA).

Additionally, the relationship between radiographic diagnosis and clinical findings, gender, age and body weight was validated via the Chi-squared test, specifically via the Pearson's test (for five or more samples) and the Fisher's test (for less than five samples) (SPSS®

18.0 Edition for Windows®, PASW Software, Chicago, USA).

## RESULTS AND DISCUSSION

50 dogs were evaluated, however two individuals (one male and one female) could not complete the study, because of serious discomfort during the radiographic examination with external compression of 20mmHg. The remaining 48 dogs were examined effectively and generated a total of 240 radiographs that presented almost perfect compliance ( $K = 0.861$ ) among the three evaluators (Landis and Koch, 1977), while applying the criteria for the positive diagnosis of tracheal collapse (complete segmented tracheal lumen closure). As a result, 25 dogs were included in the TG group (52.1%), which included individuals ranging from 2.5 to 15 years of age, and from 2.6 to 10 kg of body weight; This group was composed of 17 females and eight males of the following breeds: Indefinite (7), Yorkshire Terrier (6), Poodle (4), Maltese (3), Miniature Pinscher (2), Shih Tzu (2), Lhasa Apso (2) and Fox Paulistinha (1). On the other hand, the CG group was composed of 23 dogs (47.9%), which ranged between 2.0 and 14 years, and between 2.0 and 11 kg of body weight; This group included 16 females and seven males of the following breeds: Indefinite (7), Shih Tzu (4), Dachshund (3), Poodle (3), Yorkshire Terrier (2), Fox Paulistinha (1), Pekinese (1), Miniature Pinscher (1) and French Bulldog (1).

In the TG group, none of the dogs presented complete closure of the tracheal lumen (positivity criteria) on the radiograph without compression and only five showed a slight reduction of the lumen. In general terms, mild tracheal compression (5mmHg) was well tolerated by participating individuals, obtaining a radiographic diagnosis of tracheal collapse in 14 cases (29.2%).

As the pressure increased, the number of cases also increased: 19 (39.6%) at the pressure level of 10mmHg; 24 (50%) at the pressure level of 15mmHg; and 25 (52.1%) at a pressure level of 20 mmHg. All dogs that exhibited collapse at a level of 5mmHg maintained such behavior at higher pressure levels (10, 15 and 20mmHg). Similarly, all dogs that collapsed at 10 mmHg showed the same behavior at 15 and 20 mmHg, and so on among the 25 individuals that make up the TG group.

### *Radiographic evaluation...*

The 23 dogs in the CG group did not show a complete closure of the tracheal lumen in any of the radiographic examinations, even under maximum pressure (20mmHg, a level considered as intense). These results suggest that, in healthy conditions, the trachea of a dog can withstand external pressures of up to 20 mmHg, which validates the findings of Knudson and Knudson (1975), who concluded that the anatomical parts of the tracheas of healthy dogs can show a strong resistance under internal pressures of up to 73mmHg (100cmH<sub>2</sub>O), as was demonstrated by them with the induction of acetylcholine for tracheal muscle contraction.

Although the present study does not delve into the actual measurement of the internal tracheal pressures involved and recognizes the fact that tracheal resistance to external pressures has not been previously studied, it proceeds under the belief that, as previous studies suggest, tracheal resistance in healthy dogs is strong enough to take external pressures of 20 mmHg and that any collapse actually recorded in this study could be considered as a side effect of fragility in cartilaginous rings of dogs diagnosed with tracheal collapse. According to Pozzan *et al.* (2014), tracheal collapse is the only disorder suggested by these radiographic findings.

However, dogs in some stages of tracheal collapse generally show a minor decrease in the size of the tracheal lumen, which makes radiographic detection of this disorder difficult by conventional methods (Montgomery *et al.*, 2015). In this specific study, the mean variables of the tracheal diameter in both the fourth region of the cervical vertebrae (D4) and the thoracic entry region (DET), were of less value for those dogs included in the TG group that were subjected to a simple radiography (Table 1). However, under this radiographic technique, the reduction in tracheal diameter averaged less than 32% compared to the CG group in variable D4, and 24% compared to the same group in the DET variable, which makes the diagnosis established from the 50% reduction criterion.

Additionally, during the four radiographic evaluations performed with compression, the difference between the diameters in regions D4 and DET was amplified for both the CG group and the TG group as the pressure exerted

increased (Table 1), evidencing a decrease in the average variable when changing from 77.6% to 97.7% in D4, and from 39.3% to 47.1% in DET. Despite this, no difference was observed in the mean variables D4 and DET during the application of compression in the CG group ( $P > 0.05$ ), these variables decreased in the compression tests with respect to the simple radiography of the TG group ( $P < 0.05$ ).

In the TG group, the variable DET was the same at all pressure moments (5, 10, 15 and 20mmHg), while variable D4 presented lower values during the application of 20 mmHg than those recorded at the pressure of 5mmHg ( $P < 0.05$ ). Otherwise, the mean variable D1 (Table 1), measured in the first region of the tracheal ring, was lower in the TG group than in the CG group when radiographic examinations were performed with pressures of 5, 10 and 15mmHg levels. In the TG group, the mean variable D1 was lower in the 15mmHg evaluations compared to the other pressure levels. In spite of that, in the CG group, there were no differences between the different pressures.

In contrast to the other findings of the other variables involved, the DIC variable did not show differences between the CG group and the TG group and also within each group, regardless of the radiographic technique. These results suggest that the variables measured in the cervical segment of the trachea (DIC, D4, DET) are more affected by tracheal collapse, which validates the different findings that show that dogs suffer from a more severe morphological alteration of the cervical region (Johnson and Fales, 2001) when they present tracheal collapse.

Likewise, the behavior of variables D4 and DET, allowed more precise measurements of the internal diameter of the tracheal lumen, probably by anatomical position (Mims *et al.*, 2008; Kaye *et al.*, 2015) as well as the presence of trachea collapse in small breed dogs (Maggiore, 2014; Tappin, 2016). The reduction of these variables was significant from 5mmHg in the dogs of the TG group, in relation to simple radiography. However, only the DET variable maintained the same behavior in the four pressures performed and the D4 variable was lower in 20 mmHg when compared to 5mmHg.

Table 1. Means and standard deviations of the tracheal diameter D1, D4, DET and DIC (mm) tracheal variables of the control dogs (CG) and tracheal collapse group (TG), in the plain radiography (without compression) and in the four pressures evaluated

|            | CG          | TG           |
|------------|-------------|--------------|
| <b>D1</b>  |             |              |
| Plain      | 11.01±1.74a | 9.43±2.51b   |
| 5mmHg      | 10.73±1.95a | 8.42±2.27b*  |
| 10mmHg     | 9.97±1.92a  | 7.56±2.07b*  |
| 15mmHg     | 9.94±2.01a  | 7.19±2.43a*  |
| 20mmHg     | 9.68±1.88a  | 7.74±3.06b   |
| <b>D4</b>  |             |              |
| Plain      | 10.10±1.55a | 6.96±2.49c*  |
| 5mmHg      | 9.77±1.77a  | 2.18±2.65b*  |
| 10mmHg     | 9.43±1.66a  | 1.52±2.50ab* |
| 15mmHg     | 9.14±1.62a  | 0.49±1.03ab* |
| 20mmHg     | 9.01±1.73a  | 0.20±0.20a*  |
| <b>DET</b> |             |              |
| Plain      | 8.15±1.38a  | 6.18±1.15b*  |
| 5mmHg      | 7.96±1.48a  | 4.83±1.59a*  |
| 10mmHg     | 7.39±1.12a  | 4.76±1.52a*  |
| 15mmHg     | 7.25±1.21a  | 4.11±1.54a*  |
| 20mmHg     | 7.25±1.22a  | 3.83±1.11a*  |
| <b>DIC</b> |             |              |
| Plain      | 8.08±1.30a  | 7.73±1.58a   |
| 5mmHg      | 7.79±1.14a  | 6.52±1.76a   |
| 10mmHg     | 7.93±1.09a  | 7.02±1.65a   |
| 15mmHg     | 8.08±1.54a  | 6.99±1.77a   |
| 20mmHg     | 7.99±1.26a  | 6.68±1.83a   |

\* Statistical difference by Tukey test ( $p < 0.05$ ) between the CG and TG groups, within each radiographic technique. Different letters represent a statistically significant difference ( $p < 0.05$ ) between different radiographic techniques, within two CG and TG groups. D1- tracheal internal diameter at the first tracheal ring zone; D4 - tracheal internal diameter at the region between the fourth and fifth cervical vertebrae; DET - tracheal internal diameter at the thoracic inlet; DIC - tracheal internal diameter at the second intercostals space region.

These results suggest that the DET variable was not affected by the increase in pressure applied during the performance of the radiographic compression technique and that the D4 variable was only somewhat different at the lowest and highest pressure levels (5 mmHg and 20 mmHg) within the TG group. The difference mentioned above is probably due to the resistance threshold exhibited by the trachea of each individual against an exerted pressure and the difference that the trachea collapse can have according to the level of disease (in a range of I to IV) (Johnson, 2000).

At the same time, although the behavior of the DIC variable may not be indicated for the diagnosis of the disease, its participation in the standardization of the tracheal tract diameter and in the selection of suitable intratracheal prosthesis sizes (Montgomery *et al.*, 2015) could

be reliable, even when applying the radiographic compression technique. That being said, future studies should evaluate the applicability of the radiographic compression technique as a means to improve the effectiveness of this treatment method.

As for clinical symptoms, radiographic diagnoses were correlated to coughing episodes occurring in periods of high temperature, exercise, restlessness or the use of a cervical collar. To do so, dog tutors were asked to fill out a questionnaire and dogs had to undergo a physical examination to identify any cough reflex. However, correlation between diagnosis of tracheal collapse (TG) and coughing was only evidenced on the use a cervical collar with at radiographic procedure at a 20mmHg pressure level.

### *Radiographic evaluation...*

In these particular circumstances, cough could be considered a defense reflex that arises from the activation of tracheal and bronchial receptors under chemical, inflammatory, thermal or mechanical stimuli (Hawkins, 2010). In dogs suffering from tracheal collapse, the use of a cervical collar could exacerbate this reflex, due to the mechanical stimulation of the trachea through compression of the collar (Maggiore, 2014; Tappin, 2016). The results of this study show that radiographic collapse and cough in response to the use of a collar are directly related, which underlines the presence of this tracheal disorder in dogs that comprise the TG group. No correlation was found between the groups evaluated and the age, sex or body weight of the dogs ( $p>0.05$ ), which reinforces the homogeneity of the group evaluated (limited only to small breed dogs).

Based on these observations, the present study allows for the evaluation of the radiographic performance of the tracheal diameter when undergoing a compression technique that applies several levels of pressure, from mild (5mmHg) to strong (20 mmHg), to support the precise diagnosis of tracheal collapse in dogs. The positivity criterion (complete segmented closure) carried out in this study proved to be reliable, since it showed that increases in pressure levels applied to dogs are directly related to an increase in the number of cases of tracheal collapse effectively detected. This differs from the findings of Canola and Borges (2005), who reported that diagnoses of tracheal collapse were confirmed in all cases in which dogs had been previously examined at the clinical level and were considered suspected of having this disorder (20), although only a reduction of tracheal lumen of more than 50% was considered as a significant figure to be considered in light of the effort of an unmeasured level of pressure on the ventral cervical region of the trachea.

Although the results of Canola and Borges (2005) were promising, their inability to define a clinical criterion that could be applicable to tracheal collapse, as well as the subjective nature of the pressure levels applied as part of the auxiliary method and the obvious inclusion of subclinical cases for this disease (Johnson, 2000; Maggiore, 2014) contributed to raise doubts about the reliability of this technique.

The similar behavior of the tracheal diameter in the GC dogs of the present study, during all the pressures tested, associated with the clinical correlation of cough to the cervical collar at the pressure of 20 mmHg, in the dogs of the TG group, reinforces the reliability of the diagnosis of trachea collapse, as well as the importance of using the highest pressure (20 mmHg) for the definition of radiographic diagnosis.

However, considering the tracheoscopy as a gold standard method for diagnosis of tracheal collapse, future investigations should compare the sensibility and specificity of the compressive technique, proposed in this issue, and the tracheoscopy, also highlighting the cost and risk of both diagnostic methods.

### **CONCLUSIONS**

In the conditions in which the test was carried out, it is possible to say that the radiographic compression technique is able to reliably confirm tracheal closure in dogs suffering from tracheal collapse (TG group) as a function of the decrease in value means of the variables D4 and DET when subjected to external pressure, particularly when a pressure level of 20 mmHg is applied. Together the use of the cervical belt was associated with the increase in cough. Therefore, the use of this radiographic technique as an isolated application technique (particularly at the pressure level of 20 mmHg) should be considered appropriate to support the diagnosis of tracheal collapse in dogs.

### **REFERENCES**

- ALEXANDER, K. Laringe, faringe e traqueia. In: THRALL, D.E. *Diagnóstico de radiologia veterinária*. [Rio de Janeiro]: Elsevier, 2014. p.489-499.
- CANOLA, J.C.; BORGES, N.C. Compressão traqueal como método auxiliar no diagnóstico radiológico do colapso de traqueia cervical. *Braz. J. Vet. Res. Anim. Sci.*, v.42, p.414-418, 2005.
- EOM, K.; MOON, K.; SEONG, Y.; OH, T. *et al.* Ultrasonographic evaluation of tracheal collapse in dogs. *J. Vet. Sci.*, v.9, p.401-405, 2008.

- HAWKINS, E.C.; CLAY, L.D.; BRADLEY, J.M.; DAVIDIAN, M. Demographic and historical findings, including exposure to environmental tobacco smoke, in dogs with chronic cough. *J. Vet. Intern. Med.*, v.24, p.825-831, 2010.
- HENG, H.G.; LIM, C.K.; GUTIERREZ-CRESPO, B.; GUPTILL, L.F. Radiographic and computed tomographic appearance of tracheal collapse with axial rotation in four dogs. *J. Small Anim. Pract.*, v.59, p.53-58, 2017.
- JOHNSON, L. Tracheal collapse. Diagnosis and medical and surgical treatment. *Vet. Clin. N. Am. Small Anim. Pract.*, v.30, p.1253-1267, 2000.
- JOHNSON, L.R.; FALES, W.H. Clinical and microbiologic findings in dogs with bronchoscopically diagnosed tracheal collapse: 37 cases (1990-1995). *J. Am. Vet. Med. Assoc.*, v.219, p.1247-1250, 2001.
- JOHNSON, L.R.; POLLARD, R.E. Tracheal collapse and bronchomalacia in dogs: 58 cases (7/2001-1/2008). *J. Vet. Intern. Med.*, v.24, p.298-305, 2010.
- JOHNSON, L.R.; SINGH, M.K.; POLLARD, R.E. Agreement among radiographs, fluoroscopy and bronchoscopy in documentation of airway collapse in dogs. *J. Vet. Intern. Med.*, v.29, p.1619-1626, 2015.
- KAYE, B.M.; BOROFFKA, S.A.; HAAGSMAN, A.N.; HAAR, G.T. Computed tomographic, radiographic, and endoscopic tracheal dimensions in English bulldogs with Grade 1 clinical signs of brachycephalic airway syndrome. *Vet. Radiol. Ultrasound*, v.56, p.609-616, 2015.
- KNUDSON, R.J.; KNUDSON, D.E. Effect of muscle constriction on flow-limiting collapse of isolated canine trachea. *J. Appl. Physiol.*, v.38, p.125-131, 1975.
- LANDIS, J.R.; KOCH, G.G. An application of hierarchical kappa-type statistics in the assessment of majority agreement among multiple observers. *Biometrics*, v.33, p.363-374, 1977.
- MACREADY, D.M.; JOHNSON, L.R.; POLLARD, R.E. Fluoroscopic and radiographic evaluation of tracheal collapse in dogs: 62 cases (2001-2006). *J. Am. Vet. Med. Assoc.*, v.230, p.1870-1876, 2007.
- MAGGIORE, A.D. Tracheal and airway collapse in dogs. *Vet. Clin. N. Am. Small Anim. Pract.*, v.44, p.117-127, 2014.
- MIMS, H.L.; HANCOCK, R.B.; LEIB, M.S.; WALDRON, D.R. Primary tracheal collapse in a cat. *J. Am. Anim. Hosp. Assoc.*, v.44, p.149-153, 2008.
- MONTGOMERY, J.E.; MATHEWS, K.G.; MARCELLINTOLITTLE, D.J. Comparison of radiography and computed tomography for determining tracheal diameter and length in dogs. *Vet. Surg.*, v.44, p.114-118, 2015.
- POZZAN, M.; PALUDO, G.; DADIN, M.; PRATI, L.A. Diagnóstico radiográfico de colapso de traqueia em canino com tosse crônica. In: CONGRESSO REGIONAL DE MEDICINA VETERINÁRIA, 2., 2014, Joaçaba. *Anais...*, Joaçaba: Unoesc, 2014. v.1, n.1, p.26.
- SINGH, M.K.; JOHNSON, L.R.; KITTLESON, M.D.; POLLARD, R.E. Bronchomalacia in dogs with myxomatous mitral valve degeneration. *J. Vet. Intern. Med.*, v.26, p.312-319, 2012.
- TAPPIN, S.W. Canine tracheal collapse. *J. Small Anim. Pract.*, v.57, p.9-17, 2016.