



Applicability of ARFI elastography in the evaluation of canine prostatic alterations detected by b-mode and Doppler Ultrasonography

[Aplicabilidade da elastografia ARFI na avaliação de alterações prostáticas caninas detectadas pela ultrassonografia modo-B e Doppler]

C.A. Cintra¹, M.A.R. Feliciano², V.J.C. Santos¹, M.C. Maronezi¹, I.K. Cruz¹,
B. Gasser¹, P. Silva¹, L.Z. Crivellenti³, R.A.R. Usategui⁴

¹Faculdade de Ciências Agrárias e Veterinárias – Universidade Estadual Paulista – Jaboticabal, SP

²Universidade Federal de Santa Maria - Santa Maria, RS

³Universidade de Franca - Franca, SP

⁴Universidade Federal dos Vales do Jequitinhonha e Mucuri - Teófilo Otoni, MG

ABSTRACT

The aim of this study was to assess the applicability of ARFI elastography for the complementary diagnosis of canine prostatic alterations. Twenty-two healthy dogs and 45 with prostatic alterations were diagnosed by the association of general and specific physical exams. Complete blood count, B-mode and Doppler ultrasound were performed. For the elastography study, tissue homogeneity and deformity were verified using the elastogram, and the shear velocities of the left and right lobes of all prostates were obtained. The change in tissue homogeneity was observed in 62.2% of the animals, while the shear speed was significantly higher in dogs with prostatic alterations, with a cut-off point > 2.35m/s as an indication of change. All animals in both groups were non-deformable. It was concluded that ARFI elastography is capable of providing qualitative and quantitative results that assist in the diagnosis of canine prostatic alterations in a non-invasive way.

Keywords: dogs, prostatic changes, ARFI elastography

RESUMO

O objetivo deste estudo foi avaliar a aplicabilidade da elastografia ARFI na complementação diagnóstica das alterações prostáticas em cães. Foram avaliados 22 cães saudáveis e 45 com alterações prostáticas, diagnosticadas pela associação de exames físicos geral e específico, hemograma, ultrassonografia modo B e Doppler. No estudo elastográfico, foram verificadas a homogeneidade e a deformidade tecidual, pelo elastograma, e obtidas as velocidades de cisalhamento dos lobos esquerdo e direito de todas as próstatas. A alteração de homogeneidade tecidual foi observada em 62,2% dos animais, enquanto a velocidade de cisalhamento se mostrou significativamente maior em cães com alterações prostáticas, com ponto de corte >2,35m/s como indicativo de alteração. Todos os animais de ambos os grupos se apresentaram não deformáveis. Concluiu-se que a elastografia ARFI é capaz de fornecer resultados qualitativos e quantitativos que auxiliam no diagnóstico das alterações prostáticas caninas de forma não invasiva.

Palavras-chave: cães, alterações prostáticas, elastografia ARFI

INTRODUCTION

Prostate diseases have a high casuistry in dogs, most frequently: benign prostatic hyperplasia, prostatitis, prostatic and paraprostatic cysts, abscesses and neoplasms (Souza *et al.*, 2019). The

clinical signs of these conditions are often nonspecific and there is a need for additional tests to obtain an accurate diagnosis (Mussel *et al.*, 2010). The definitive diagnosis of these conditions is obtained by means of cytological or histopathological tests; however, both are

Recebido em 1 de julho de 2020

Aceito em 25 de agosto de 2020

E-mail: cristianeacindra@yahoo.com.br

invasive and with considerable risk of complications during the collection of material for analysis (Souza *et al.*, 2019). Thus, non-invasive methods that provide information regarding the organ's morphology and hemodynamics, such as B-mode and Doppler ultrasound, are routinely used to assist the diagnosis and therapeutic choices, for allowing the detection of abnormalities in the prostate and the monitoring of the disease (Matton and Nyland, 2005; Cruzeiro *et al.*, 2008; Alonge *et al.*, 2017). However, despite being used on a large scale, these ultrasound techniques provide unspecific results (Souza *et al.*, 2017).

Acoustic radiation force impulse elastography (ARFI) is an ultrasound technique that allows assessment of tissue elasticity in a safe and non-invasive way, providing quantitative and qualitative measures of the rigidity of various organs (Dudea *et al.*, 2011; Gennisson *et al.*, 2013). In veterinary medicine, the use of ARFI elastography is novel, and reference values for prostatic evaluation in young, adult and senior dogs have already been determined (Feliciano *et al.*, 2015). In medicine, elastography has been used to assist in the diagnosis of prostatic neoplasms (D'anastasi *et al.*, 2011; Dudea *et al.*, 2011), with these tissues showing greater rigidity than the normal parenchyma and benign lesions (Ophir *et al.*, 2002; Zaleska *et al.*, 2014).

Taking into account that the definitive diagnosis of canine prostatic alterations is often not obtained and that a large share of the cases are presumptively diagnosed by the association of the history and the findings of physical and ultrasound examination, the use of other non-invasive methods that can increase the diagnostic accuracy is justified. Thus, the objective of this study was to verify the applicability of ARFI elastography in the diagnostic complementation of canine prostatic alterations verified by means of B-mode and Doppler ultrasonography.

MATERIALS AND METHODS

This study was approved by the Animal Ethic and Welfare Committee of the institution where the study took place, under protocol No. 023705/12. Sixty-seven dogs, whole, of different breeds, aged between one and 14 years and weighing between five and forty kilograms were included. Forty-five came from the institution's Veterinary

Reproduction and Obstetrics Service and were already diagnosed with prostatic diseases, while 22 healthy dogs were given under free and informed consent by the tutors.

The animals' health was established based on the results of physical, specific exams (palpation of the prostate), blood count, B-mode and Doppler ultrasonography (color and pulsed wave). Animals were considered healthy if they did not have a history of prostatic changes or in parameters evaluated in physical examination or palpation, as well as any change in blood count. According to B-mode ultrasonography, healthy prostates were hypoechogenic compared to adjacent tissues, homogeneous and of regular shape (Matton and Nyland, 2005; Smith, 2008; Moxon *et al.*, 2016) and dimensions, as already described in the literature by Atalan *et al.* (1999). According to Color Doppler, vascularization is normal when seen around the prostate or not identified. The spectral doppler obtained the values of peak systolic velocity, end diastolic velocity, and vascular resistivity index of the prostatic artery, taking as reference the values described by Freitas *et al.* (2015). Prostates that showed any change in echogenicity, echotexture, regularity, dimensions, vascularity and doppler velocimetric indices were classified abnormal.

After being classified as healthy or sick, the dogs were referred for evaluation with ARFI elastography. The animals were subjected to a previous 8-hour fast, so that there was no presence of fecal or gaseous content in the colonic portion so there would not interfere on the evaluation of the prostate. Bladder retention was necessary for at least two hours before examination. Sedation of the animals was not necessary. Wide trichotomy of the abdominal region and application of ultrasound conductive gel was done to facilitate the procedure and promote greater contact between the transducer and the animal's skin.

The exams were performed by a single experienced operator (15 years of experience), using the ACUSON S2000 ultrasound equipment (Siemens, Munich, Germany) and a 9.0MHz linear multifrequency transducer. Software for qualitative characterization and quantification ARFI (Virtual Touch Tissue Quantification, 2D-SWE technique) was used. Firstly, images of the prostate were taken in longitudinal sections to obtain a gray scale elastogram. Tissue

homogeneity (homogeneous soft, homogeneous hard or heterogeneous hard) and deformity (deformable or non-deformable) were verified, based on the relative rigidity of the parenchyma, where lighter tones (white) corresponded to more elastic tissues (soft) and darker tones (black) represented more rigid tissues (hard).

Secondly, a quantitative assessment of tissue stiffness was performed by measuring the shear velocity (SWV)m/s) of the prostatic parenchyma in a transversal orientation. The average was calculated for six samples from the right lobe and six from the left lobe, with depth 1.5 to 2.5cm (Feliciano *et al.*, 2015).

The statistical analysis was performed with IBM SPSS Statistics 20 software (International Business Machines Corp, São Paulo, Brazil) and for all of the analyzes, a significance level of 95% ($P \leq 0.05$) was used. The association between elastography homogeneity and the presence of disease was verified by logistic regression and sensitivity, specificity and accuracy were calculated for the result obtained. Tissue deformity was demonstrated in percentages. Mann Whitney test was performed to check if there was an association between SWV of both lobes and the presence of prostatopathy, so that their cutoff point and predictive values

(sensitivity, specificity and area under the curve) were obtained using the ROC curve.

RESULTS

The elastogram revealed that 100% of healthy prostates were characterized with homogeneous hard parenchyma, while only 35.5% (n=16) of sick dogs had such a classification. Only one sick prostate presented a soft homogeneous parenchyma (Table 1) and the other animals were classified as heterogeneous hard (62.2%). There was a significant association between elastographic heterogeneity and presence of disease ($P < 0.001$), with a sensitivity of 64.44%, specificity of 100% and accuracy of 76.11%. All prostates in both groups were classified as non-deformable.

Quantitative elastography showed that the average shear velocity (SWV) obtained in the healthy group was 1.93 ± 0.42 m/s (left prostatic lobe) and 1.88 ± 0.32 m/s (right prostatic lobe), while the sick group (Table 1.) presented 2.24 ± 0.88 m/s (left lobe) and 2.35 ± 0.78 m/s (right lobe), with a significant difference between groups ($P < 0.001$) (Figure 1). Thus, it is indicative of prostatic disease when the SWV of the prostate is greater than or equal to 2.35 m/s, with a sensitivity of 84.4%, specificity of 68.2% and accuracy of 70.1%.

Table 1. Predictive, qualitative and quantitative values, mean and standard deviation, obtained by means of ARFI elastography for determining prostatic changes

Qualitative	Healthy Animals		Sick Animals	
	n* animals	(%)	n* animals	(%)
Homogeneous hard	22	100	16	35.5
Homogeneous soft	none		1	2.2
Heterogeneous hard			28	62.2
Quantitative	Mean	SD*	Mean	SD*
Left lobe (SWV)m/s	1.93	0.42	2.24	0.88
Right lobe (SWV)m/s	1.88	0.32	2.35	0.78
Parameters	P Value	*Sens. (%)	*Spec. (%)	*AUC (%)
Left lobe (SWV)m/s	0.026	84.4	68.2	63
Right lobe (SWV)m/s	0.001	88.4	60	70

*AUC= accuracy, Spec.= specificity, SD= Standard deviation, n= number of animals, Sens.= sensibility, SWV= shear wave velocity.

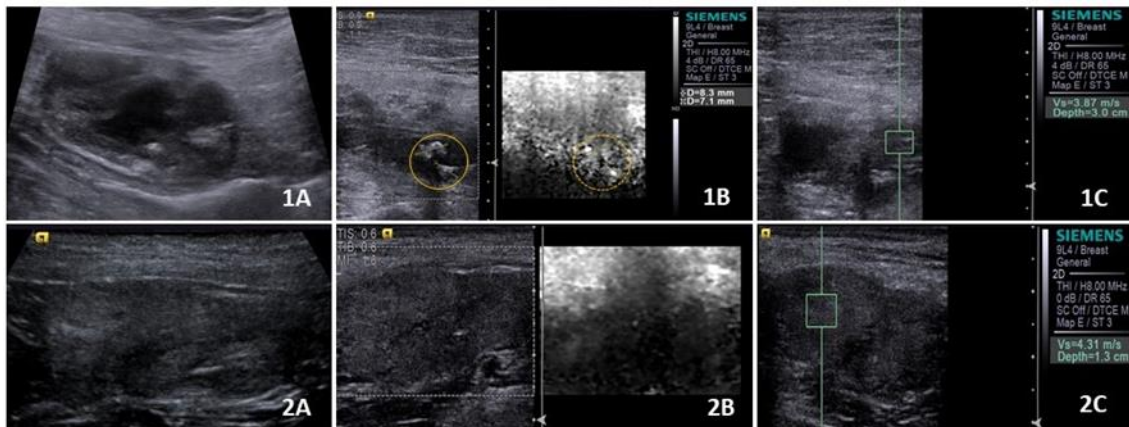


Figure 1. B-mode ultrasound images and ARFI elastography of abnormal canine prostatic tissue. In 1A, prostate with mixed echogenicity and heterogeneous echotexture, in a dog with suppurative prostatitis; 1B) Elastogram showing heterogeneous stiffness, with echogenic areas in B-mode (yellow circle) presenting less rigidity to the elastogram (dotted yellow circle), suggesting areas of tissue necrosis; 1C) Shear wave velocity of 3.87m/s in abnormal prostate tissue, revealing increased tissue stiffness; In 2A, prostate with mixed echogenicity and heterogeneous echotexture, in a dog with prostatic intraepithelial neoplasia; 2B) Elastogram showing homogeneous and increased stiffness (dark tint); 2C) Shear wave velocity of 4.31 m/s in altered prostate tissue, showing increased tissue stiffness.

DISCUSSION

This is the first description of the use of elastography (ARFI) in the evaluation of dogs with a presumptive diagnosis of prostatic pathologies. The changes observed in B-mode and Doppler are nonspecific and may be present in most diseases that affect the prostate (Lévy *et al.*, 2014; Souza *et al.*, 2017) making it difficult to discriminate between different prostatic alterations due to the lack of pathognomonic characteristics (Zelli *et al.*, 2013). Therefore, further investigation is needed through other diagnostic methods, such as the ARFI elastography, which demonstrated applicability through qualitative and quantitative assessments in this study.

In this study, the elastogram of all of the healthy animals showed homogeneity compatible with that described by Feliciano *et al.* (2015) who demonstrated the normal elastographic characteristics of dogs' prostates of different ages. On the other hand, there was a change in this characteristic only in sick animals. This change in homogeneity and increased tissue stiffness verified by the elastogram in sick prostates may be related to tissue repair resulting from a prostatic lesion (whether of physiological or pathological origin) which involves several

mechanisms, and tissue regeneration (recovery of functional activity may occur) or healing, forming a fibrotic matrix. In cases of chronic or neoplastic lesions, the healing process interferes negatively, causing functional tissue loss (Balbino *et al.*, 2005).

The tissue repair characteristics also justify the increase in SWV observed in the diseased prostates of this study. Although SWV values of altered prostate in dogs are not described, this change has already been observed in men with different types of prostatic alterations for example, in cases of benign prostatic hyperplasia, where it was found that the increase in SWV is directly related with the severity of the disease (Alan *et al.*, 2016). Sigrist *et al.* (2017) cite that the greater the stiffness of the tissue, the greater the shear speed.

The presence of cystic structures and prostatic atrophy present in advanced cases of prostatic hyperplasia (as well as cases of prostatitis and neoplasia) are easily identified in B-mode (Shimomura *et al.*, 2009) and according to Feliciano *et al.* (2015), these can alter the stiffness of the prostatic parenchyma tissue and subsequently promote changes in the shear velocity values. It is important to highlight that, like other organs, the prostate also has some

limitations capable of affecting elastographic results, due to the structures present in the tissue, such as cystic components, or even the experience of the operator (Hoskins, 2011; Jeon *et al.*, 2015; Nowicki and Dobruch-Sobczak, 2016).

In addition, even if predictive values were obtained to identify prostatic alterations through ARFI elastography in this study, it should be emphasized that this method does not replace the performance of cyto and histopathological exams, since only these are able to provide the definitive diagnosis and to discriminate the types of prostatic alterations (Domostawska *et al.*, 2018). Therefore, elastography should be used together, and can assist in the early diagnosis of different prostatic changes that affect dogs. Based on the results obtained, ARFI elastography proved to be an appropriate and accurate method for detecting prostatic alterations, with high predictive performance variables. The shear speed was significantly higher in the tissues of the group of animals that presented clinical symptoms of prostatic disease when compared to the group of healthy animals.

CONCLUSIONS

The findings of this study may provide a baseline for clinical investigation, as ARFI elastography brings additional information to B-mode Doppler, assisting in the presumptive diagnosis of canine prostatic alterations.

ACKNOWLEDGMENTS

The present study was supported by FAPESP (São Paulo State Foundation Research) in the form thematic project (2017/14957-6 and 2019/09197-8) and CNPq (National Council for Scientific and Technological Development) in the form of productivity scholarship (process number 309199/2017-4). The authors also thank Jair Matos and Siemens Healthineers for technical assistance.

REFERENCES

ALAN, B.; UTANGAÇ, M.; GÖYA, C.; DAĞGÜLLI, M. Role of Acoustic Radiation Force Impulse (ARFI) elastography in determination of severity of benign prostate hyperplasia. *Med. Sci. Monit.*, v.22, p.4523-4528, 2016.

ALONGE, S.; MELANDRI, M.; FANCIULLO, L. *et al.* Prostate vascular flow: The effect of the ejaculation on the power Doppler ultrasonographic examination. *Reprod. Dom. Anim.*, v.25, p.1-6, 2017.

ATALAN, G.; BARR, F.J.; HOLT, P.E. Comparison of ultrasonographic and radiographic measurements of canine prostate dimensions. *Vet. Radiol. Ultrasound*, v.40, p.408-412, 1999.

BALBINO, C.A.; PEREIRA, L.M.; CURI, R. Mecanismos envolvidos na cicatrização:

CRUZEIRO, R.S.; SILVA, J.C.P.; BRIZZOTTI, M.M. *et al.* Determinação das mensurações prostáticas de cães pela ultra-sonografia transabdominal. *Rev. Ceres*, v.55, p.461-466, 2008.

D'ANASTASI, M.; SCHNEEVOIGT, B.S.; TROTTMANN, M. *et al.* Acoustic radiation force impulse imaging of the testes: a preliminary experience. *Clin. Hemorheol. Microcirc.*, v.49, p.105-114, 2011.

DOMOSŁAWSKA, A.; ZDUŃCZYK, S.; JURCZAK, A.; JANOWSKI, T. Elastography as a diagnostic tool in the prostate tumour detection in Labrador retriever. *Andrologia*, v.50, p.1-3, 2018.

DUDEA, S.M.; GIURGIU, C.R.; DUMITRIU, D. *et al.* Value of ultrasound elastography in the diagnosis and management of prostate carcinoma. *Med. Ultrason*, v.13, p.45-53, 2011.

FELICIANO, M.A.R.; MARONEZI, M.C.; SIMÕES, A.P.R. *et al.* Acoustic radiation force impulse elastography of the prostate and testes of dogs: initial results. *J. Small Anim. Pract.*, v.56, p.320-324, 2015.

FREITAS, L.A.; PINTO, J.N.; SILVA, H.V.; SILVA, L.D. Two-dimensional and Doppler sonographic prostatic appearance of sexually intact French bulldogs. *Theriogenology*, v.83, p.1140-1146, 2015.

GENNISSON, J.L.; DEFFIEUX, T.; FINK, M.; TANTER, M. Ultrasound elastography: principles and techniques. *Diagn. Interv. Imaging*, v.94, p.487-495, 2013.

HOSKINS, P.R. Principles of ultrasound elastography. *Ultrasound*, v.20, p.8-15, 2011.

- JEON, S.; LEE, G.; LEE, S.K. *et al.* Ultrasonographic elastography of the liver, spleen, kidneys, and prostate in clinically normal beagle dogs. *Vet. Radiol. Ultrasound*, v.56, p.425-431, 2015.
- LÉVY, X.; NIŻAŃSKI, W.; VON HEIMENDAHL, A.; MIMOUNI, P. Diagnosis of common prostatic conditions in dogs: an update. *Reprod. Domest. Anim.*, v.49, p.50-57, 2014.
- MATTOON, J.S.; NYLAND, T.G. Próstata e testículos. In: MATTOON, J.S.; NYLAND, T.G. *Ultra-som diagnostic em pequenos animais*. 2.ed. São Paulo: Roca, 2005. p.255-272.
- MOXON, R.; WHITESIDE, H.; ENGLAND, G.C. Prevalence of ultrasound-determined cystic endometrial hyperplasia and the relationship with age in dogs. *Theriogenology*, v.86, p.976-980, 2016.
- MUSSEL, C.; MELO, R.F.; LUME, H.; MULINARI, F. Métodos de diagnóstico para a detecção de prostatopatias caninas. *Ciênc. Rural*, v.40, p.2616-2622, 2010.
- NOWICKI, A.; DOBRUCH-SOBCZAK, K. Introduction to ultrasound elastography. *J. Med. Ultrason*, v.65, p.113-124, 2016.
- OPHIR, J.; ALAM, S.K.; GARRAB, S. *et al.* Elastography: Imaging the elastic properties of soft tissues with ultrasound. *J. Med. Ultrason*, v.29, p.155-171, 2002.
- SHIMOMURA, J.Z.; EUGÊNIO, F.R.; LUVIZOTTO, M.C.R.; PERRI, S.H.V. Benign prostatic hyperplasia in dog: comparison diagnosis methods. *Vet. Zootec.*, v.16, p.117-126, 2009.
- SIGRIST, R.M.S.; LIAU, J.; KAFFAS, A.E.; *et al.* Ultrasound Elastography: Review of Techniques and Clinical Applications. *Theranostics*, v.7, n.5, p.1303-1329, 2017.
- SMITH J. Canine prostatic disease: a review of anatomy, pathology, diagnosis, and treatment. *Theriogenology*, v.70, p.375-383, 2008.
- SOUZA, M.B.; GASSER, B.; RODRIGUES, M.G.K. Sistema reprodutor masculino. In: FELICIANO, M.A.R.; ASSIS, A.R.; VICENTE, W.R.R. *Ultrassonografia em cães e gatos*. São Paulo: MedVet, 2019. p.135-176.
- SOUZA, M.B.; SILVA, L.D.M.; MOXON, R. *et al.* Ultrasonography of the prostate gland and testes in dogs. *In Pract.*, v.39, p.21-32, 2017.
- uma revisão. *Braz. J. Pharm. Sci.*, v.41, p.27-51, 2005.
- ZALESKA, D.U.; KACZOROWSKI, K.; PAWLUŚ, A. *et al.* Ultrasound elastography - review of techniques and its clinical applications. *Adv. Clin. Exp. Med.*, v.23, p.645-655, 2014.
- ZELLI, R.; ORLANDI, R.; TROISI, A. *et al.* Power and pulsed Doppler evaluation 344 of prostatic artery blood flow in normal and benign prostatic hyperplasia-affected dogs. *Reprod. Domest. Anim.*, v.48, p.768-773, 2013.