



Facial restoration after trauma - nasolabial in monkey bugio – *Alouatta caraya* (Humboldt, 1812) – first case report

[*Restauração facial pós trauma nasolabial em macaco bugio –
alouatta caraya* (Humboldt, 1812) – relato de caso]

L. Cazati^{1,2,4}, A.C. Csermak Júnior², F.C. Jacoby³, G.R. Araújo^{1,2}, T.D. Souza^{1,2}

¹ Aluno de pós-graduação – Universidade Federal de Mato Grosso do Sul – Campo Grande, MS

² Instituto Reprocon – Campo Grande, MS

³ Aluno de graduação – Universidade Federal de Mato Grosso do Sul – Campo Grande, MS

⁴ Centro de Reabilitação de Animais Silvestres – CRAS/ IMASUL – Campo Grande, MS

ABSTRACT

In the last decades in the State of Mato Grosso do Sul – Brazil, the reduction in the preservation of areas due to the degradation of the biome and destruction of the natural environment has caused animals, mainly in the order of non-human primates, to come closer to towns and highways, increasing the number of accidents and in some cases, deaths. New surgical techniques have been developed that favor these species as explained in this report. The howler monkey patient was traumatized in the facial region damaging important vital structures such as facial muscle groups responsible for swallowing food, chewing, breathing, defense, and communication (vocalization and mimicry), in addition to the cartilaginous nasal structures. However, reconstructive facial surgical techniques, used on humans, showed satisfactory results from an anatomical, functional, and aesthetic point of view in howler monkey, with acceptance of the animal with a safe postoperative period for a full recovery of the primate patient.

Keywords: wild animals, surgical techniques, reconstructive surgery

RESUMO

Nas últimas décadas, no estado do Mato Grosso do Sul - Brasil, a redução de áreas preservadas pela degradação de biomas e pela destruição de habitat naturais tem favorecido a aproximação de animais – muitos desses, primatas não humanos – em cidades e rodovias, aumentando o número de acidentes e, em alguns casos, de mortes. Novas técnicas cirúrgicas têm sido desenvolvidas, favorecendo essas espécies, como reportado neste trabalho. O paciente macaco bugio foi traumatizado em região facial, envolvendo importantes estruturas vitais, como grupos musculares faciais responsáveis pela apreensão alimentar, mastigação, respiração, defesa e comunicação (vocalização e mímicas), além das estruturas cartilaginosas nasais. No entanto, técnicas cirúrgicas reconstrutivas em face aplicadas e descritas em humanos apresentaram resultados satisfatórios dos pontos de vista anatômico, fisiológico e visual nos macacos bugio, com aceitação deles diante do estresse, com pós-operatório seguro, resultando na reabilitação do paciente primata.

Palavras-chave: animais silvestres, técnicas cirúrgicas, cirurgia reconstrutiva

INTRODUCTION

Alouatta caraya – popularly known as the howler monkey, it is a primate of the new world. In Brazil it is distribution area covers in the states of Bahia, Distrito Federal, Goiás, Maranhão, Pará, Mato

Grosso, Mato Grosso do Sul, Minas Gerais, Piauí, Paraná, Rio Grande do Sul, Rondônia, Santa Catarina, São Paulo and Tocantins (Ludwig *et al.*, 2015). Its distribution also comprises the northeast and north of Argentina, the north, south and east of the Paraguayan Chaco and the east and

Recebido em 9 de novembro de 2020

Aceito em 19 de março de 2021

E-mail: cazatilucas@gmail.com

north of Bolivia and other neighboring countries (Giordano and Ballard, 2010). The Chico Mendes Institute for Biodiversity Conservation – ICMBio points out that, through the mischaracterization of the environment, animal trafficking and anthropic actions imposed by the advancement of activities in natural environments, the Bugio is classified as “Vulnerable” (Bressan et al., 2009).

Many factors led the animals to captivity, mainly the traffic of wild animals, loss and fragmentation of the habitat and illegal hunting (Peres, 2001). Currently, the increase in the occurrence of howler monkeys due to accidents involving electrocution or being run over has generated a demand for knowledge that helps in the maintenance of these wild animals in captivity. Also, domestic animals such as dogs and cats abandoned or semi-domiciled (Miranda and Hirano, 2011), restricted to a home have been identified as potential threats to native fauna. Cases of attack and predation of wild animals by domestic animals are reported daily and studies have been published to estimate the damage of these attacks to native fauna in Brazil (Brickner, 2003; Rangel and Neiva, 2013; Hughes, & Macdonald, 2013).

In the last 5 years, the State of Mato Grosso do Sul, at the Wild Animal Rehabilitation Center - CRAS / IMASUL, received 32 howler monkeys of the *Alouatta caraya* species with different age groups, the vast majority of them, resulting from trauma caused by pedestrian accidents, burn injuries, bacterial or fungal skin diseases and trafficking. Many suffered serious injuries, such as lacerations and amputations of secondary limbs due to dog attacks. Thus, the description of occurrences and treatments that were successful in accidents with primates by domestic animals is necessary, for the identification of injuries and prognosis of the animal, in the face of similar cases. The aim of this study is to describe a veterinary emergency and howler treatment with facial trauma and laceration of nasolabial structures.

CASUISTRY

The Wild Animal Rehabilitation Center - CRAS/IMASUL, City of Campo Grande, in the State of Mato Grosso do Sul - Brazil received a young female, howler monkey (*Alouatta caraya*), initial weight 350g, through voluntary delivery.

Upon delivery, it was informed that the animal was found bruised and bleeding heavily, having at the time been contained in a T-shirt, and taken to CRAS for emergency relief. At the time of the initial care, the animal had trauma to the facial region, compromising the nasal and labial structures, with partial rupture of the orbicularis oris muscles and an elevation of the upper lip, with exposure of the nasal turbinates (Figure 1).

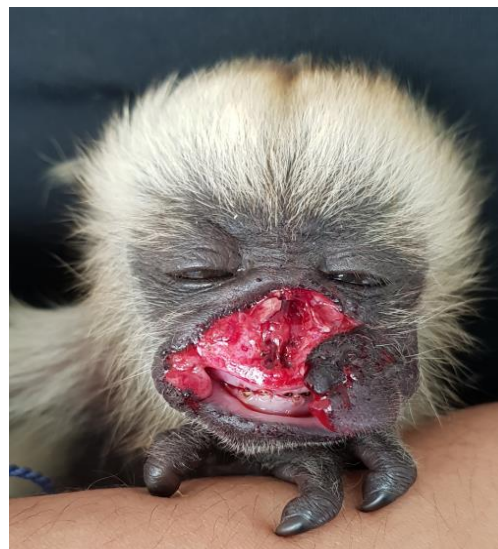


Figure 1. Howler Monkey - *Alouatta caraya*, received at the Wild Animal Rehabilitation Center CRAS / IMASUL - MS, with a severe lesion in the facial region, note the muscles: mouth orbicularis, buccinator and nasal partially ruptured.

During clinical examination, vital signs revealed significant changes of emergency. The animal was in a stupor, with severe hemorrhage on the face and enophthalmia. In addition, it was hypothermic (29.8°C). General clinical features suggested the presence of hypotension secondary to the hemorrhagic picture. The trauma presented by the Howler Monkey advocated an emergency action to control the bleeding, reduce the degree of contamination of the wound and control of pain, so the primate was immediately sent to the surgery center. Initially, venous access for fluid therapy with Ringer Lactate was performed and the patient was stabilized.

Subsequently hemostasis was initiated with Tranexamic Acid (Transamin 14mg / kg. Tranexamic Acid – Nikkho - Brazil) intramuscularly. Then a pain control protocol was

Facial restoration...

instituted, with the combination of (Dipyron 0.25mg/kg/IM Dipyron IBASA - Brazil), (Maxican 0.2% Meloxicam - Ourofino - Brazil) injectable in concentration 2mg/ml, dose of 0.1ml/kg/IM. The animal was sedated through a multimodal protocol using (Zoletil Tiletamine Hydrochloride 25mg/ml with Zolazepan Hydrochloride 25mg/ml - Virbac, Brazil) at a dose of 2mg/kg/IM of each anesthetic, associated with these was (Tramadol - Tramadol Hydrochloride 50mg/ml 0.02mg/kg intramuscularly was used Cristália - Brazil). Anesthetic maintenance was used inhalation anesthesia with (Vetflurano, Isoflurane - Virbac, Brazil) through the universal vaporizer (Verona and Pissinatti, 2017).

The surgical technique employed was soft tissue repair, with correction of muscle avulsion. Procedures were started with antisepsis in the injured and adjacent region with 0.05 % chlorhexidine, and then the tissue was separated and organized by diaeresis. With the idea of making breathing via the nostrils feasible, due to partial avulsion of the musculature and injury to the nasal cartilages, a suture was performed with separate simple stitches for better apposition of the edges of the wound. Latter a second suture line of simple stitches was made parallel to the first one, bringing the skin closer to the subcutaneous tissue to reduce dead space. The nasal hole was made by a small incision (Figure 2).

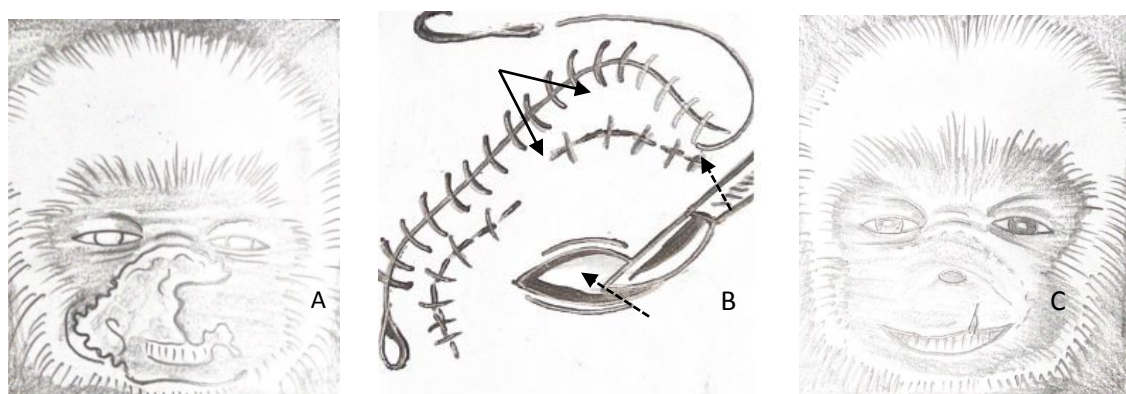


Figure 2. Schematic representation of the facial reconstruction in *Alouatta caraya*. Nasolabial lesion with massive soft tissue lost (A); separate simple stitches for wound edges approximation (wide arrow) and for dead space reduction (dashed arrow), and incision for nasal hole opening (B); wound appearance after healing (C).

The total surgery time was approximately 80 minutes. After the recovery of the surgical procedure, the Howler Monkey was sent to the maternity sector of CRAS and received the microchip implant. By veterinary medical recommendation, artificial heat was provided to the animal, with an average temperature of 37 °C. During the postoperative period of hospitalization, the animal had two episodes of seizure 48 hours after treatment, it was administered intramuscularly, (Fenocris, Fenobarbital, Cristália, - Brazil) 5mg/kg. After 138 treatment, there was complete remission of the signs.

The recommended supportive therapy in the postoperative period was: (Dipyron, Dipyron

IBASA - Brazil) 0.25mg/kg/IM - (twice a day) for 7 days, (Maxican, Meloxicam 0.2% - Ourofino - Brazil) injectable in a concentration of 2mg/ml, dose of 0.1ml/kg/ IM - (once daily) for 4 days, (Cephalexin 250mg/5ml - Cephalexin EMS, Brazil) Suspension dose of 24mg/kg - three times a day for 10 days, and topical therapy, used (Vetaglos, gentamicin [Sulfate] 0.5g, Sulfanilamide 5.0g, Sulfadiazine 5.0g, Urea 5.0g, Vitamin A 120,000 IU - VETNIL- Brazil). As nutritional support, two formulations were used, which were provided every two hours alternately. Diet I consisted of Zero Lactose (Piracanjuba® milk - Brazil); Diet II, on the other hand, consisted of fruits such as apples, papayas, bananas, water as shown in the image below.



Figure 3. Howler Monkey feeding after 33 days of recovery. During this period, the animal already performed lip sucking movements.

DISCUSSION

In our report, we present an unprecedented case of reconstruction of naso-labial structures in a non-human primate (*Alouatta caraya*) with severe facial trauma (Figure 3). Lips are muscular structures that serve as a gateway to the gastrointestinal tract, retain saliva and food during chewing, exhibit facial expressions. According to Miranda and Hirano (2011), that in this species and in a primate family, it is necessary to harmonize the group as in categories of feeding behavior, contact and alert play. Thus, the anatomical and physiological conservation of these structures is essential for maintaining the patient's quality of life.

When it is necessary to repair a lip structure, it must be considered that any alteration from the anatomical point of view will be easily noticeable, mainly to its movement. Therefore, a lip restoration should result in good function. According to Alves and Alves (2011) the imperfection must be repaired with a tissue with similar characteristics, such as color, texture and thickness. As a priority, we must use neighborhood tissues, or remaining tissues in case of full total plane resection, or tissue on the other lip, or distant flaps and free flaps.

According to Alves and Alves (2011) the reconstruction of the upper lip is more difficult than that of the lower lip due to the fact that it is less mobile, for this it is recommended that you use the lip tissue itself for its reconstruction. The

choice for a simple suture (fixed separately) isolated between the structures, aimed to avoid infection in muscle injuries, promote hemostasis and prevent muscle loss, because in facial regions, there are countless blood capillaries, movements of facial and chewing mimics that put constant tension on the skin suture. In addition, monkeys are extremely skilled with their limbs, and can easily interfere with a suture. With separate suture if the monkey to break the single suture at some point of the injury, it wouldn't unviable the entire synthesis.

The healing process is essential in the protective response of the epidermal lesion through tissue repair, where a tissue with traumatic injury is replaced by vascularized connective tissue. In this sense, knowledge about such a process is essential to maximize the healing process (Abreu *et al.*, 2011). Therefore, the use of healing ointment containing gentamicin (Sulfate) 0.5g, Sulfanilamide 5.0g, Sulfadiazine 5.0g, Urea 5.0g and Vitamin A 120,000 IU, was a decisive factor in the healing of the injured region, providing epithelial regeneration (Figure 4). Wounds in the nasal region can be of traumatic or pathological origin. The reconstruction of these imperfections is highly complex due to the nasal region being important from the functional and aesthetic point of view. Nasal fractures have significant functional and aesthetic implications. Bone traumas are commonly accompanied by septal cartilage lesions, since these structures are closely linked (Borguese *et al.*, 2011).



Figure 4. Healing is noted from the third day, after facial surgical intervention with muscular rearrangement and with the use of healing ointment.

In this patient, during palpation of the physical examination, no crackles were observed in the nasal bones, only injuries to the musculature. There is still a discussion about the timing and the most appropriate technique for the surgical approach, it is believed that decisions should be based on variables such as injury complexity, presence of other fractures on the face, and presence of septal injury. The most commonly used treatment for nasal fractures has been closed reduction with local anesthetic, the result being often considered satisfactory by the doctor and the patient (Borguese *et al.*, 2011). In pediatric patients, such as this baby howler monkey and, due to some complications (hypovolemic shock and a small puppy), a careful evaluation by trauma using local anesthesia or physical restraint has become difficult to make more specific decisions in the face of the condition. For this reason, sedation in non-human primates is essential for the success of facial correction.

The type of anesthesia used varies in the literature. There are authors who advocate the widespread use of general anesthesia, arguing that it allows intranasal examination and surgical manipulation exempt from the patient's defense reaction (Borguese *et al.*, 2011). Our experience with our case mentioned in this study also proves that general anesthesia is favorable to manipulation

and surgery with bone exposure and absence of nasal cartilage. The technique to be used in the facial region must fundamentally aim at cure and healing the lesion, restoring the function that was injured, allowing for good respiratory permeability and, finally, providing an aesthetic closer to the natural (Lima *et al.*, 2007).

In addition to the prescribed medications, the diet used was of great importance for the animal's recovery. The foods considered functional for the howlermin treatment were selected based on their nutritional needs (Tognon, 2007). According to his injuries and the mother's permanent absence, not only to ensure the guaranteed levels (MS%) of the diet, but also to accelerate the healing process, facilitate swallowing and promote the strengthening of the specimen's immunity in the postoperative period. It was also based on adapting the animal's nutrition from the approximate age, clinical condition and the food eaten by the species in free life. The patient's bowel movements (quantity, odor, color and consistency), food leftovers, body score, body weight, hair quality, as well as the individual's behavior to assess the response to nutritional treatment were observed.

Nutrients are available in a heterogeneous way between foods and combining food items to meet nutritional and energy needs is a major challenge. The limited relationship between data on nutritional needs, feeding behavior and the selectivity of food in captivity, associated with the isolated use of information on eating habits while living free, are some of the factors that interfere with the quality of the diet (Félix *et al.*, 2010). Primates of the genus *Alouatta* are the leafiest among the species of neotropical primates, possessing a diet considered opportunistic, being thus called behavioral leaf eaters (Miranda & Passos, 2004). Young primates like the animal assisted depend entirely on their mother. Therefore, elaborating and adapting the diet close to the natural (food provided by the mother) is necessary. Thinking about it, the method of feeding alternately in two diets, offering it every day, reached a satisfactory nutritional balance in this baby.

Howler, with safe levels of metabolizable energy, appreciating the expected clinical and surgical evolution, resulting in a marked evolution in score body weight (710grams), hair shine and weight

gain with demonstration of food independence. Significantly, adequate nutrition is essential for the treatment and recovery of the non-human primate patient. The animal showed a good response to the treatment applied and 28 days after the surgical procedure and the beginning of the clinical treatment it has already presented a considerable improvement in the condition. In view of the improvement of the clinical picture and considering that the CRAS must be a place of

temporary maintenance of animals, the patient was transferred to the Zoo of Bonito City - Mato Grosso do Sul 60 days after being attended. In the new institution, he was placed in an enclosure and adopted by another group of primates of the same species and is clinically well (Figure 4). The monkey receives food on an equal basis with other individuals of the same species and is exposed in the park visitor grounds. (Figure 5).



Figure 5 - Still young, the Howler Monkey was transferred by the Wild Animal Rehabilitation Center to Bonito City Zoo - MS, BIOPARK. She was inserted in an enclosure and adopted by another group of primates of the same species and is clinically well. Check it out at: <https://www.facebook.com/bioparkbonitoms/photos/a.303098310422394/361514147914143/?type=3>. Accessed in Jan. 2019.

CONCLUSION

Facial trauma to the nasolabial region in non-human primates posed a major emergency challenge for the veterinary surgeon. The knowledge of surgical techniques promoted a satisfactory aesthetic and functional muscular rearrangement for the howler monkey, maintaining good respiratory permeability and chewing capacity.

ACKNOWLEDGEMENTS

This study was fully funded by the Environment Institute of Mato Grosso do Sul / IMASUL - Brazil.

REFERENCES

ABREU, J.A.C.; SOUSA, A.L.; ALVES, C.L.G.F.; NUNES J.T. Análise histológica da cicatrização de feridas cutâneas experimentais sob ação do laser de baixa potência. *Sci. Med.*, v.21, p.96-100, 2011.

ALVES, P.J.; ALVES, S.S.T. Reconstrução labial superior com retalho de pedículo subcutâneo Upper lip reconstruction with subcutaneous pedicle flap. *Rev. Bras. Cir. Plást.*, v.26, p.254-258, 2011.

BORGUESE, B.; CALDERONI, D.R.; PASSERI, L.A. Estudo retrospectivo da abordagem das fraturas nasais no Hospital de clínicas da Unicamp. *Rev. Bras. Cir. Plast.*, v.26, p.608-612, 2011.

BRESSAN, P.M.; KIERULFF, M.C.M.; SUGIEDA, A.M. (Coords.). *Fauna ameaçada de extinção do estado de São Paulo: vertebrados*. São Paulo: Fundação Parque Zoológico de São Paulo, São Paulo. Secretaria de Meio Ambiente do Estado de São Paulo, 2009. 645p.

BRICKNER, I. The impact of domestic dogs (*Canis familiaris*) on wildlife welfare and conservation: a literature review. With a situation summary from Israel. University of Harare, Zimbabwe, p.1-28p, 2002.

- FÉLIX, G.A.; ABOT, A.R.; SAAD, C.E.P. *et al.* Manejo nutricional dos primatas calitriquídeos (*Leontopithecus*) em cativeiro. SIMPÓSIO DE CIÊNCIAS DA UNIVERSIDADE PAULISTA, ENCONTRO DE ZOOTECNIA, 7., 2010, Dracena. *Anais...* Dracena: [UNESP], 2010.
- GIORDANO, A.J.; BALLARD, W.B. Noteworthy record of a black howler monkey (*Alouatta caraya*) from the central dry chaco of Paraguay. *Neotrop. Primates*, v.17, p.74-75, 2010.
- HUGHES, J.; MACDONALD, D.W. A review of the interactions between free-roaming domestic dogs and wildlife. *Biol. Cons.*, v.157, p.341-351, 2013.
- LIMA, B.S.; ABDALLA, S.C.; ACCIOLI Z.V. *et al.* Reconstrução nasal com retalho frontal: nossa experiência. *Arq. Catarinense Med.*, v.36, p.103-105, 2007.
- LUDWIG, G.; BICCA-MARQUES, C.; RÍMOLE, J. *et al.* Avaliação do risco de extinção de *Alouatta caraya* (Humboldt, 1812) no Brasil. Processo de avaliação do risco de extinção da fauna brasileira. ICMBio. 2015. Disponível em: <http://www.icmbio.gov.br/portal/biodiversidade/fauna-brasileira/estado-de-conservacao/7176-mamiferos-alouatta-caraya-bugio-preto.html>. Acessado em: 13 abr, 2020.
- MIRANDA, J.M.D.; PASSOS, F.C. Hábito alimentar de *Alouattagariba* (Humboldt) (Primates, Atelidae) em Floresta de Araucária, Paraná, Brasil. *Rev. Bras. Zool.*, v.21, p.821-826, 2004.
- MIRANDA, J.M.D.; HIRANO, Z.M.B. Processo de habituação de um grupo de *Callithrix flaviceps* (Thomas, 1903) na Reserva Biológica Augusto Ruschi, Santa Teresa, Espírito Santo. *A Primatologia no Brasil*, p.2. 2011.
- PERES, C.A. Synergistic effects of subsistence hunting and habitat fragmentation on Amazon forest vertebrates. *Cons. Biol.*, v.15, p.1490-1505, 2001.
- RANGEL, C.H.; NEIVA, C.H.M.B. Predação de vertebrados por cães *Canis lupus F. Familiaris* (Mammalia: Carnivora) no Jardim Botânico do Rio de Janeiro. *Biodiversidade Bras.*, v.3, p.261-269, 2013.
- TOGNON, F.R. *Comportamento alimentar de um grupo de bugios-pretos (Alouatta caraya, Humboldt, 1812 – Primates, Atelidae) em um fragmento de mata no Município de Jardinópolis – SP.* 2007. Dissertação (Mestrado) - Faculdade de Filosofia, Ciências e Letras de Ribeirão Preto, SP.
- VERONA, C.E.; PISSINATTI, A. Primates – primatas do novo mundo (Sagui, Macaco-prego, Macaco-aranha, Bugio e Muriqui). In: CUBAS, Z.S.; SILVA, J.C.R.; CATAO-DIAS, J.L. *Tratado de animais selvagens – medicina veterinária.* 2.ed. São Paulo: Roca, 2017. Cap.34, p.727.