

FIXATION OF FRACTURES OF THE DISTAL EXTREMITY OF THE RADIUS USING THE MODIFIED KAPANDJI TECHNIQUE: EVALUATION OF THE RADIOLOGICAL RESULTS

Antonio Piva Neto¹, Fabio Colla Lhamby²

ABSTRACT

Objective: To demonstrate a simple and efficacious option for treating fractures of the distal extremity of the radius using Kirschner wires. **Methods:** Between September 2008 and April 2009, 48 patients with fractures of the distal extremity of the radius, classified as A3 according to the AO classification, were treated surgically using a modification of the Kapandji technique. **Results:** Out of the 48 wrists operated, 42 (87.5%) presented postoperative measurements within the acceptable limits. We used the parameters of McQuenn and Caspers who considered that the radial angulation should be wider than 19° and the volar angulation should be narrower than -12°. All the postoperative volar inclination measurements

were narrower than -3°. The mean preoperative radial inclination was 13.14° and the mean postoperative value was 21.18°. The mean preoperative volar inclination was 28.75° and the mean postoperative value was 3.31°. The mean preoperative radial height was 5.25 mm and the mean postoperative value was 9.48 mm. **Conclusion:** The technique described here had excellent stability for treating fractures of the distal extremity of the radius classified as A3. It was easy to implement and minimally invasive, with minimal surgical complications, and it was inexpensive.

Keywords - Radius Fractures/surgery; Radius Fractures/radiography; Bone Wires

INTRODUCTION

In fractures of the distal extremity of the radius that present displacement and instability, some loss of the reduction initially obtained will occur unless the case is adequately managed. Percutaneous fixation and plaster-cast immobilization are a simple and widely used method among trauma surgeons.

Today, several types of osteosynthesis devices are available on the market to aid surgeons in managing the different types of fracture encountered. However, Kirschner wires have their place in treating fractures of the distal extremity of the radius and still constitute one of the most common methods for fracture fixation, combined with plaster-cast immobilization.

The main disadvantages of fracture fixation using Kirschner wires are the need for postoperative immobilization, the need to remove the wires after fracture consolidation, the possibility of fracture displacement after percutaneous fixation and the possibility of tears in the extensor tendons.

Fixation of unstable fractures of the wrist using Kirschner wires was popularized over recent decades in an attempt to improve the result from conservative reduction treatment with plaster-cast immobilization. Many methods for fracture fixation using percutaneous Kirschner wires have been described. In all of them, the wires are used to maintain the reduction among the fragments (interfocal fixation), or to pro-

1 – Resident Physician at the Passo Fundo Orthopedics Hospital, Passo Fundo, RS, Brazil.

2 – Orthopedist and Traumatologist in the Hand Group, Passo Fundo Orthopedics Hospital, Passo Fundo, RS, Brazil.

Work performed at the Passo Fundo Orthopedics Hospital, Passo Fundo, RS, Brazil.

Correspondence: Hospital Ortopédico de Passo Fundo/RS. Rua Sete de Setembro, 817 – 99010-121 – Passo Fundo, RS. E-mail: fabiolhamby@hotmail.com

Work received for publication: August 18, 2010; accepted for publication: March 22, 2011.

The authors declare that there was no conflict of interest in conducting this work

This article is available online in Portuguese and English at the websites: www.rbo.org.br and www.scielo.br/rbort

vide support through sustaining the distal fragments and thus preventing displacement and shortening on these bone pieces (intrafocal fixation).

The surgical method described in the present study, with combined intrafocal and interfocal fixation with Kirschner wires, for fractures of the distal radius, had the aim of alleviating some of the complications associated with the intrafocal fixation method that was described by Adalbert I. Kapandji. Through modifying Kapandji's original technique, our objective was to improve the stability of fracture fixation and demonstrate a simple and effective treatment option, with fewer complications.

MATERIALS AND METHODS

Between September 2008 and April 2009, a prospective analysis was conducted on 48 patients with fractures of the distal radius who were treated surgically at Hospital São Vicente de Paulo and the City Hospital, in Passo Fundo, Rio Grande do Sul.

Measurements were made on radiographs produced before the operation, immediately after the operation and six months after the operation (at the time when the synthesis material was removed).

All the cases were evaluated by two traumatologists, of whom one was a hand surgeon, using the Arbeitsgemeinschaft für Osteosynthesefragen (AO) classification.

Only fractures classified as A3 were included in this study, which were the fractures capable of receiving treatment through the technique presented, according to the proposed method.

The exclusion criteria were the following: fractures without the AO classification of A3, fractures with volar deviation, "die punch" fractures, exposed fractures, bilateral fractures and multiple fractures. Multiple trauma patients were also excluded.

Fourteen patients were men and 34 were women. The patients' ages ranged from 20 to 89 years, with a mean age of 55 years. The left wrist was affected in 27 patients and the right wrist in 21 patients.

All the fractures were evaluated before and after the operation in the posteroanterior (PA) and lateral radiographic views. The height and inclination angle of the radius were measured on PA radiographs (Figure 1), and the volar tilt was measured on lateral radiographs (Figure 2). The presence of joint steps and ulnar variance were also assessed.

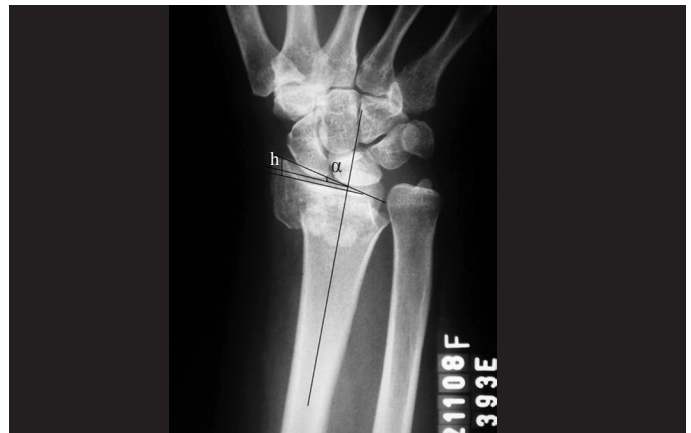

Figure 1 – Preoperative radiograph on wrist in posteroanterior (PA) view, showing an extra-articular fracture of the distal radius with metaphyseal comminution and diminished radial inclination. The radial inclination (α) and radial height (h) are demonstrated on the radiograph.

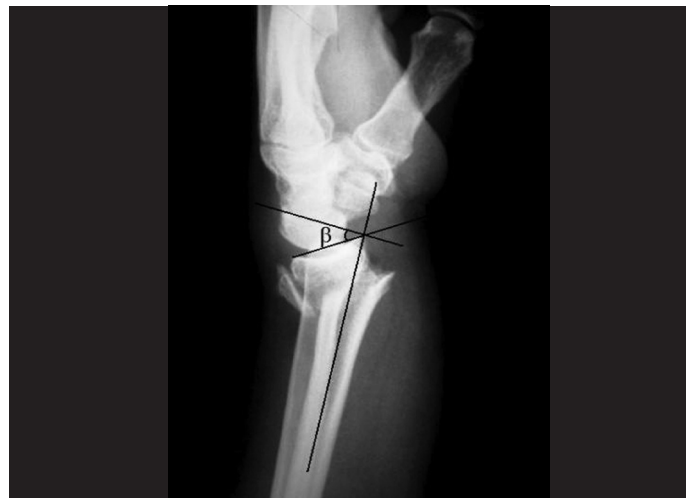

Figure 2 – Preoperative radiograph on wrist in lateral view, showing a fracture of the distal radius with metaphyseal dorsal comminution and dorsal deviation. The volar tilt (β) is demonstrated on the radiograph.

We used the postoperative radiographic parameters established by McQueen and Caspers for evaluating the results. These authors considered that the results would be adequate if the radial angle was greater than or equal to 19° (normal: 24°) and if the volar angle was less than -12° (normal: between 4° and 12°).

SURGICAL TECHNIQUE

Under axillary block or general anesthesia, and after exsanguination of the upper limb to be operated, the first step was to reduce the fracture (under fluoroscopy), using traction and counter-traction, in association with ulnar flexion and deviation. After

the reduction maneuver, the locations for inserting the Kirschner wires were marked out.

Application of traction and ulnar flexion and deviation converted the dorsal angle to neutral and recovered the height of the radius through ligamentotaxis, thereby aiding in defining the locations for inserting the Kirschner wires.

After achieving an acceptable reduction, the first intrafocal Kirschner wire was placed at the lateral margin of the radius, by means of a small incision between the first and second compartments of the extensor tendons, one centimeter proximally to the fracture line. This Kirschner wire, which was used as a lever, as described by Kapandji, recovered and maintained the height of the distal radius, thus achieving correct alignment of the distal metaphysis over the diaphysis of the radius, in PA view.

With the aim of reduction of the dorsal deviation, another Kirschner wire was used as a level in the focus of the fracture. This second intrafocal wire is placed on the dorsum of the radius, between the third and fourth compartments of the extensor tendon. A small incision was made distally to the focus of the fracture in order to avoid skin traction and tension. Care was required, to ensure that the entire zone of dorsal comminution was situated distally to the wire.

Following this, another three static (transosseous) Kirschner wires were inserted. Through a small radial incision, the first of these wires was positioned at the apex of the radial styloid process and was introduced as far as the opposite cortical bone, thereby complementing the fixation of the radial styloid. The other two Kirschner wires were placed on the dorsum of the radius. The path of the wires started on the dorsal rim of the joint, making use of the denser structure of the subchondral bone in order to achieve better support for the assembly. The reference points used for introducing the wires were the intervals between the extensor compartments that have been described for arthroscopic portals. The first Kirschner wire was positioned in portal 3-4 of the wrist, which is located between the third and fourth compartments of the extensor tendon, distally to Lister's tubercle. This wire was placed proximally, going in the volar direction, to go through the opposite cortical bone. The next static Kirschner wire was used to complement the dynamic fixation of the ulnar fragment of the fracture and was

introduced into the portal 6R, which is located in the sixth compartment of the extensor tendon, and was directed proximally and radially. All the Kirschner wires were positioned subcutaneously and the incisions were sutured (Figures 3 and 4).

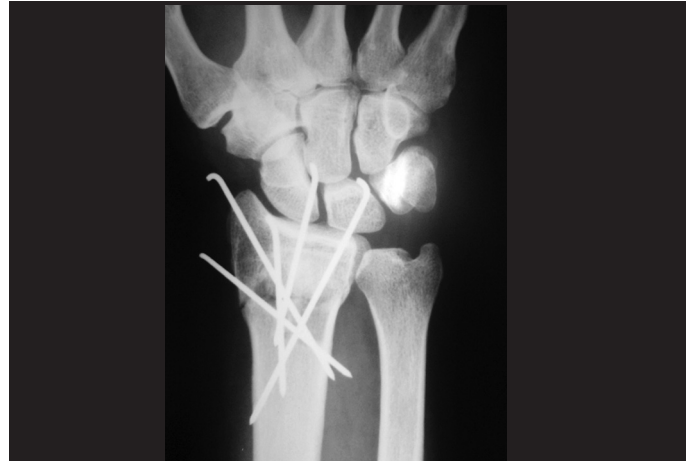

Figure 3 – Radiograph on wrist showing the immediate postoperative result in posteroanterior view, after fixation of the fracture of the distal radius using Kirschner wires, with correction of the radial angulation and restoration of the radial height.

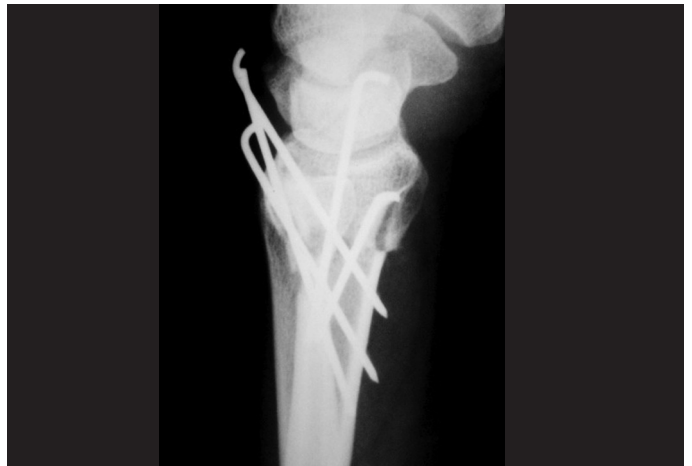

Figure 4 – Radiograph on wrist showing the immediate postoperative result in lateral view, with correction of the dorsal deviation of the distal radius.

The wrist was immobilized using a brace from the axilla to the palm for one week, to control rotation and minimize skin irritation caused by the Kirschner wires. After this period, the splint was removed and, after producing a control radiograph, it was replaced by a plaster cast from the axilla to the palm.

Three weeks after the surgery, the plaster cast was replaced by a plaster-cast glove, thus releasing the elbow.

The plaster-cast glove and the percutaneous wires were removed in the sixth week of immobilization, as an outpatient procedure under local anesthesia. The final radiograph was produced at that time and physiotherapy was then started.

RESULTS

The radiographic parameters before the operation and six weeks afterwards (Figures 5 and 6) were measured and compared (Table 1). It needs to be emphasized that all the patients achieved measurements in the immediate postoperative period that were considered adequate.

Out of the 48 wrists that were treated surgically, 42 (87.5%) presented postoperative measurements within the limits that were considered adequate according to McQueen and Caspers. All the postoperative

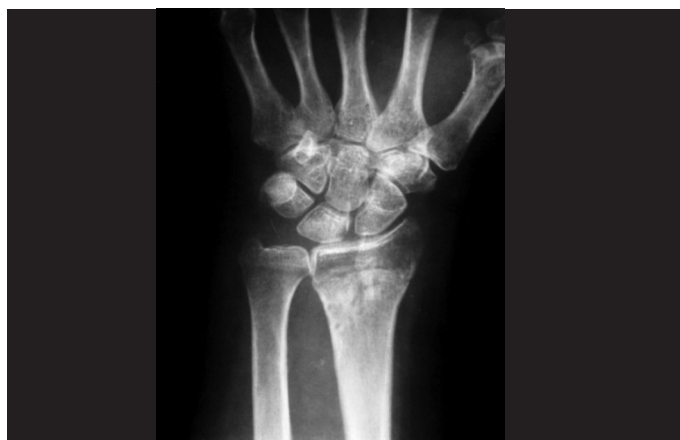

Figure 5 – Radiograph on wrist in posteroanterior view after removal of the Kirschner wires, showing the final result from treatment of the fracture of the distal radius.

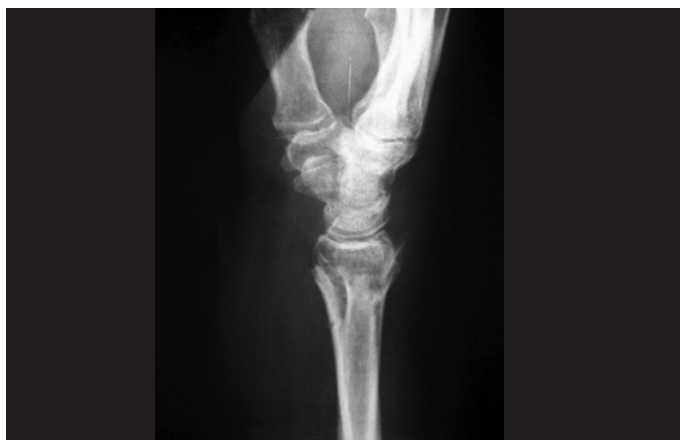

Figure 6 – Radiograph on wrist in lateral view after removal of the synthesis material, showing correction of the volar angulation of the distal radius.

Table 1 – Change in radiographic values from before to after the operation.

	Before operation	After operation	Mean correction
Radial inclination (°)	4 to 26	15 to 28	8.47
Volar tilt (°)	-5 to -48	12 to -5	32.41
Radial height (mm)	0 to 10	7 to -15	4.2

measurements on the volar tilt were less than -3° (range: -2° to 12°), with a mean correction of the deformity of dorsal deviation of 32.41° . The six wrists that did not achieve the postoperative targets presented smaller gains in radial inclination, although all of them presented values that were close to acceptable (16° , 18° , 17° , 15° , 18° and 17°). The ulnar variance was neutral in all these six wrists. In just one wrist, there was a loss of 3° in radial inclination, which went from 23° on the preoperative radiograph to 20° in the postoperative measurement.

The mean preoperative radial inclination was 13.14° (range: 4° to 26°) and the mean postoperative measurement after removal of the Kirschner wires was 21.18° (range: 15° to 28°), with a mean correction of 8.47° . The mean preoperative volar tilt was 28.75° (range: 5° to 48° of dorsal deviation). The volar tilt measurement after removal of the Kirschner wires was 3.31° (range: 5° of dorsal tilt to 12° of volar tilt), with a mean correction of 32.41° (Figure 7).

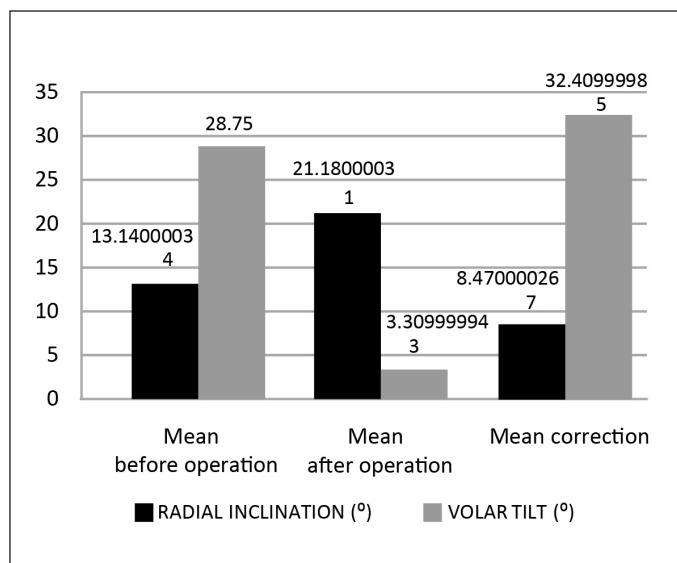


Figure 7 – Mean values before and after the operation and mean correction of radial inclination and volar tilt.

There was a mean correction of radial height of 4.2 mm (range: 1 to 9 mm), with a preoperative mean of 5.25 mm (range: 0 to 10 mm) and a postoperative mean of 9.48 mm (range: 7 to 15 mm) (Figure 8).

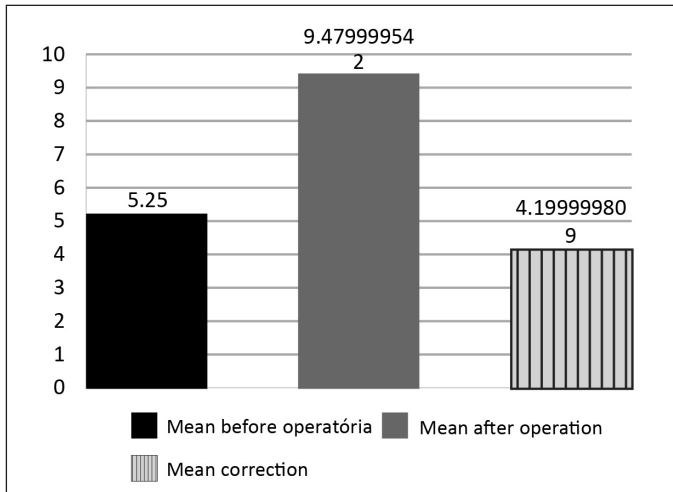


Figure 8 – Mean values for radial height before and after the operation and mean correction.

It was observed in five cases that there was some loss of the initial reduction seen on radiographs produced immediately after the operation, when these were compared with radiographs produced six weeks after the operation. In none of these cases was there any volar displacement of the distal fragment of the fracture. In one case, there was some loss of the initial postoperative volar angle, which went from 2° of volar tilt to 5° of dorsal tilt.

There were no cases of torn extensor tendons or nerve injuries. Five patients (10.4%) presented skin lesions adjacent to the Kirschner wires. There was one case of superficial infection in one of the patients who presented skin lesions. There were no cases of deep or bone infection.

DISCUSSION

Adalbert I. Kapandji described a technique for fixation of fractures of the distal extremity of the radius using intrafocal Kirschner wires⁽¹⁻³⁾. This technique was initially recommended for young patients. Because of its success, its use has spread and the indications have increased^(4,5).

Kirschner wires constitute one of the most commonly used methods for fixation of fractures of the distal extremity of forearm bones. Their use creates

the need for postoperative plaster-cast immobilization. One of the criticisms of percutaneous fixation is that it does not provide stability, i.e. it is difficult to maintain the postoperative reduction⁽⁶⁻⁸⁾. The fracture tends to collapse. Geatting and Bisshop⁽⁹⁾ used the Kapandji technique in elderly individuals and observed that the deformity recurred⁽¹⁰⁻¹²⁾.

In the present study, we observed that losses of the initial reduction occurred in patients with marked dorsal comminution in which the support provided by the dorsal cortical bone was lost. Some loss of the initial reduction was also expected in elderly patients due to the osteopenia and comminution that are commonly present in such patients⁽¹³⁾. Our objective through modifying Kapandji's technique was to improve the stability of fixation by bringing in transosseous wires, with the aim of diminishing the displacements and thus the complications coming from treating this type of fracture.

In only two (4.1%) of the 48 cases presented were there losses of the initial reduction. In one of the wrists, the loss was in the volar angle, which was initially a volar tilt of 2° and became a dorsal tilt of 5°. This patient presented a high degree of osteopenia and major comminution in the dorsal cortical bone of the distal radius, which demanded special care in relation to this type of fracture. In another 13 wrists (27%) with significant dorsal comminution, no losses of the reduction in volar tilt were observed. In another case of loss of the initial reduction, there was a loss of radial inclination from 23° to 20°, although this value was still within the desired range.

Several authors⁽¹⁴⁾ attempted to implement early mobilization and obtained unsatisfactory results, ending up with a variety of complications such as intense pain, reflex sympathetic dystrophy, loss of the initial reduction and torn tendons, among others. In the cases that we analyzed, there were no cases of extensor tendon tears or of nerve injuries. Five patients (10.4%) presented skin lesions adjacent to the Kirschner wires. There was one case of superficial infection in a patient who presented skin lesions. There were no cases of deep or bone infection.

It is known that there is a significant correlation between maintaining good radiological reduction until fracture consolidation is achieved and presenting good function. Moreover, wrist function depends on

the degree of destructuring caused by loss of the normal palmar angulation of the distal radial, which is difficult to restore and maintain through the methods of closed reduction and immobilization⁽¹⁵⁾. In this regard, the surgeon's main aim is to achieve an anatomical reduction that is maintained until consolidation, independent of the patient's age⁽¹⁶⁾.

The method demonstrated here achieved this objective. Out of the 48 wrists operated, six did not attain parameters that would be considered ideal, but the values achieved were very close to the ideal. None of these wrists attained the desired radial inclination measurement, but were very close to the ideal value. The distal radioulnar joints were congruent and the ulnar variance measurements were neutral in all of them, thus indicating that the problems of mobility and ulnocarpal impaction were avoided.

Another of the possible complications from Kapandji's technique is that anterior displacement of the distal fragment of the fracture may occur through exacerbated reduction^(5,17-19). Associated use of the technique of intrafocal fixation with transosseous wires attempts to improve the stability of the fixation, thereby avoiding this type of problem. In one wrist in this series (2%), this problem occurred. This case was analyzed, and it was perceived that the displacement was already present on the radiograph produced

immediately after the operation. Thus, we concluded that because of exacerbated reduction force (leverage on the dorsal intrafocal wire), volar displacement of the distal portion of the radius occurred. This could be corrected before performing the transosseous fixation.

Regarding the Kirschner wires used in this technique, it is known that there is no significant difference in the final stability provided by wires of 2.0 or 1.6 mm in diameter. For this reason, we chose to use wires of 1.6 mm, which are more malleable and therefore less aggressive towards the bone fragments^(20,21).

From the results obtained, it was demonstrated that this variation in the technique described originally by Dr. Adalbert I. Kapandji is viable. It is a minimally invasive procedure that is simple to perform and fast. It can be done by trauma surgeons and produces acceptable radiological results. The complications encountered with the original method can be avoided.

CONCLUSION

We have presented an alternative surgical technique for treating wrist fractures. This operation is easy to carry out and minimally invasive, with minimal surgical complications. It is a low-cost method and produces reliable bone stability.

REFERENCES

- Kapandji A. Focal pinning of radial distal fractures. *Cahier Chirurg.* 1987; 63:25-8.
- Cooney WP 3rd, Linscheid RL, Dobyns JH. External pin fixation for unstable Colles' fractures. *J Bone Joint Surg Am.* 1979;61(6A):840-5.
- Stoffelen DV, Broos PL. Closed reduction versus Kapandji-pinning for extra-articular distal radial fractures. *J Hand Surg Br.* 1999;24(1):89-91.
- Board T, Kocalkowski A, Andrew G. Does Kapandji wiring help in older patients? A retrospective comparative review of displaced intra-articular distal radial fractures in patients over 55 years. *Injury.* 1999;30(10):663-9.
- Hollevoet N, Verdonk R. Anterior fracture displacement in Colles' fractures after Kapandji wiring in women over 59 years. *Int Orthop.* 2007;31(3):397-402.
- Rosati M, Bertagnini S, Digrandi G, Sala C. Percutaneous pinning for fractures of the distal radius. *Acta Orthop Belg.* 2006;72(2):138-46.
- Barton T, Chambers C, Lane E, Bannister G. Do Kirschner wires maintain reduction of displaced Colles' fractures? *Injury.* 2005;36(12):1431-4.
- Glickel SZ, Catalano LW, Raia FJ, Barron OA, Grabow R, Chia B. Long-term outcomes of closed reduction and percutaneous pinning for the treatment of distal radius fractures. *J Hand Surg Am.* 2008;33(10):1700-5.
- Greatting MD, Bishop AT. Intrafocal (Kapandji) pinning of unstable fractures of the distal radius. *Orthop Clin North Am.* 1993;24(2):301-7.
- Haas J L, Caffiniere de la J Y. Fixation of distal radial fractures: intramedullary pinning versus external fixation. In: Saffar P, Cooney WP, editors. *Fractures of the distal radius.* London: Martin Dunitz; 1995; p. 229-39.
- Oskam J, Kingma J, Bart J, Klases HJ. K-wire fixation for redislocated Colles' fractures. Malunion in 8/21 cases. *Acta Orthop Scand.* 1997;68(3):259-61.
- Snow M, Kelly M, Jeyam M, Fahmy N. Functional versus position: a randomized controlled trial of interfocal Kirschner wiring of unstable distal radial fractures. *Eur J Trauma Emerg Surg.* 2007;33(1):81-6.
- Board T, Kocalkowski A, Andrew G. Does Kapandji wiring help in older patients? A retrospective comparative review of displaced intra-articular distal radial fractures in patients over 55 years. *Injury.* 1999;30(10):663-9.
- Lenoble E, Dumontier C, Goutallier D, Apoil A. Fracture of the distal radius. A prospective comparison between trans-styloid and Kapandji fixations. *J Bone Joint Surg Br.* 1995;77(4):562-7.
- McQueen MM, Hajducka C, Court-Brown CM. Redisplaced unstable fractures of the distal radius: a prospective randomised comparison of four methods of treatment. *J Bone Joint Surg Br.* 1996;78(3):404-9.
- Kumar S, Penematsa S, Sadri M, Deshmukh SC. Can radiological results be surrogate markers of functional outcome in distal radial extra-articular fractures? *Int Orthop.* 2008;32(4):505-9.
- Lenoble E, Dumontier C, Goutallier D, Apoil A. Fracture of the distal radius. A prospective comparison between trans-styloid and Kapandji fixations. *J Bone Joint Surg Br.* 1995;77(4):562-7.
- Nonnenmacher J, Kempf I. [Role of intrafocal pinning in the treatment of wrist fractures]. *Int Orthop.* 1988;12(2):155-62.
- Peyroux LM, Dunaud JL, Caron M, Ben Slamia I, Kharrat M. The Kapandji technique and its evolution in the treatment of fractures of the distal end of the radius. Report on a series of 159 cases. *Ann Chir Main.* 1987;6(2):109-22.
- Naidu SH, Capo JT, Moulton M, Ciccone W 2nd, Radin A. Percutaneous pinning of distal radius fractures: a biomechanical study. *J Hand Surg Am.* 1997;22(2):252-7.
- Mittelmeier W, Braun C, Schäfer R. The Kapandji technique for fixation of distal radius fractures—a biomechanical comparison of primary stability. *Arch Orthop Trauma Surg.* 2001;121(3):135-8.