

TOTAL KNEE ARTHROPLASTY IN A PATIENT WITH HOFFA FRACTURE PSEUDARTHROSIS: CASE REPORT

Rodrigo Pires e Albuquerque¹, Vincenzo Giordano², Ney Pecegueiro do Amaral³, Antônio Carlos Pires Carvalho⁴, João Maurício Barretto⁵

ABSTRACT

A rare occurrence of a case of Hoffa fracture pseudarthrosis in an alcoholic patient with genu valgum associated with venous insufficiency who underwent total knee arthroplasty is reported. The literature is reviewed and the main factors for surgical indication of total

knee arthroplasty after a fracture of the knee are discussed. Total knee arthroplasty was a viable option in a 60-year-old patient with Hoffa fracture pseudarthrosis and comorbidities.

Keywords - Arthroplasty, Replacement, Knee; Femoral Fractures; Pseudarthrosis; Knee Joint

INTRODUCTION

Total knee arthroplasty is a high-complexity surgical procedure that is basically indicated for patients with a diagnosis of knee osteoarthritis or rheumatic diseases. This surgical procedure has been constantly evolving since its creation. Implants with more modern designs that resemble the anatomy of the normal knee as much as possible, together with instruments that are increasingly precise and cause less aggression to soft tissue, have been making the coverage of surgical indications ever wider.

The good results obtained after carrying out total knee arthroplasty (TKA) have been well documented in the literature, with regard both to pain relief and to maintenance of these results over long-term follow-up⁽¹⁻⁶⁾.

Hoff fractures are rare injuries. Pseudarthrosis of coronal fractures of the lateral femoral condyle gives rise to pain and valgus deviation of the knee. Since the knee is a weight-bearing area, it presents greater risk of developing early osteoarthritis.

The aim of this study was to present a case of Hoffa fracture pseudarthrosis in an alcoholic patient with

genu valgum in association with venous insufficiency who underwent total knee arthroplasty (TKA).

Case Report

The patient was a 60-year-old man with a condition of intense pain in his left knee and secondary osteoarthritis due to pseudarthrosis of a Hoffa fracture with two years of evolution, along with genu valgum of the knee and venous insufficiency. This patient underwent total knee arthroplasty on the left knee in August 2008, at the Orthopedics and Traumatology Service of Miguel Couto Municipal Hospital. The prosthesis used was made in Brazil (Baumer S/A, Mogi Mirim, São Paulo; Total Knee Arthroplasty model with preservation of the posterior cruciate ligament). During the patient's hospital stay prior to the surgery, he developed abstinence syndrome (the patient had not informed us of his previous history of alcohol dependence). In the immediate postoperative period, we observed that pain relief and functional improvement of the knee had been achieved. The patient returned to his professional activities, satisfied with the surgical procedure that had been accomplished (Figures 1 to 12).

1 - MSc and PhD in Medicine. Coordinator of the Knee Surgery Sector, Miguel Couto Municipal Hospital, Rio de Janeiro, Brazil.

2 - MSc in Medicine, Coordinator of the Medical Residence Program, Miguel Couto Municipal Hospital, Rio de Janeiro, Brazil.

3 - MSc in Medicine. Head of the Orthopedics and Traumatology Service, Miguel Couto Municipal Hospital, Rio de Janeiro, Brazil.

4 - MSc and PhD in Medicine. Adjunct Professor of the Radiology Service, Federal University of Rio de Janeiro (UFRJ), Rio de Janeiro, Brazil.

5 - MSc and PhD in Medicine. Head of the Orthopedics Service, Santa Casa da Misericórdia, Rio de Janeiro, Brazil.

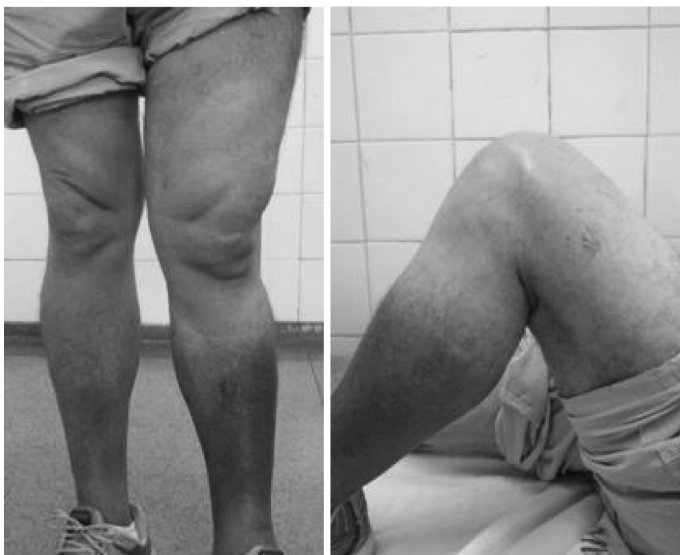Work performed at the Professor Nova Monteiro Orthopedics and Traumatology Service, Miguel Couto Municipal Hospital, Rio de Janeiro.

Correspondence: Av. Henrique Dodsworth, 83/105 – Copacabana, RJ – E-mail: rodalbuquerque@ibest.com.br

Work received for publication: April 23, 2010; accepted for publication: March 21, 2011.

The authors declare that there was no conflict of interest in conducting this work

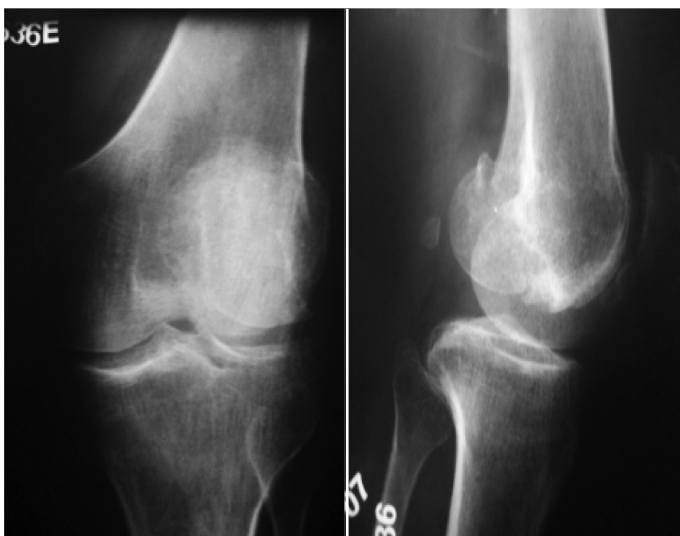
This article is available online in Portuguese and English at the websites: www.rbo.org.br and www.scielo.br/rbort



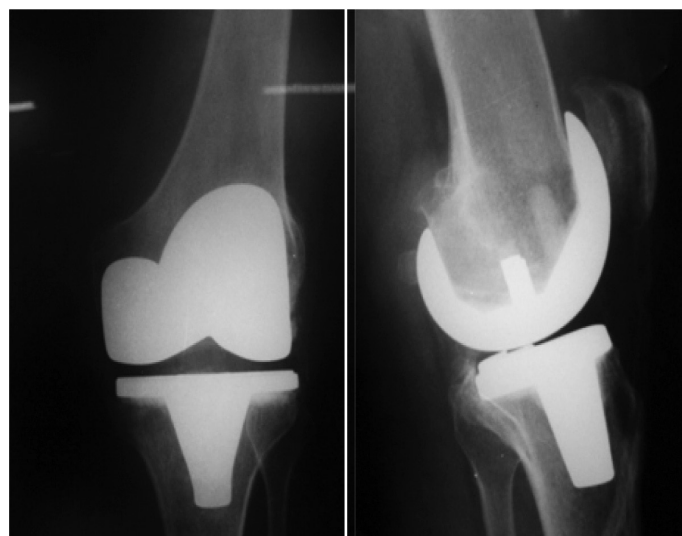
Figures 1 and 2 – Preoperative clinical evaluation.

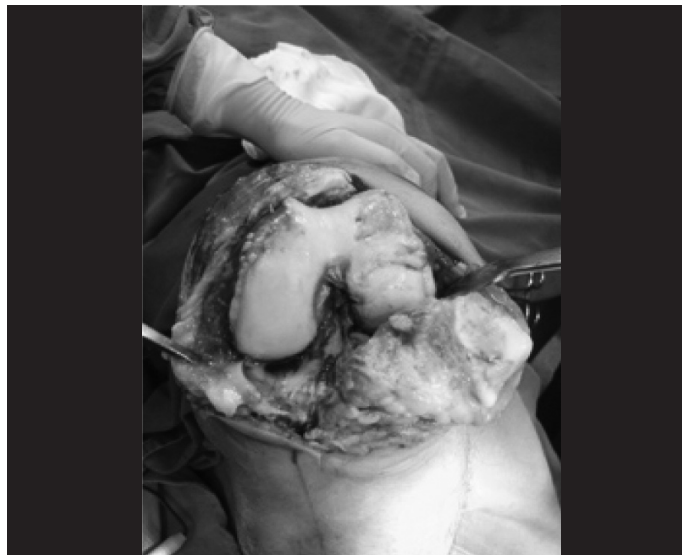

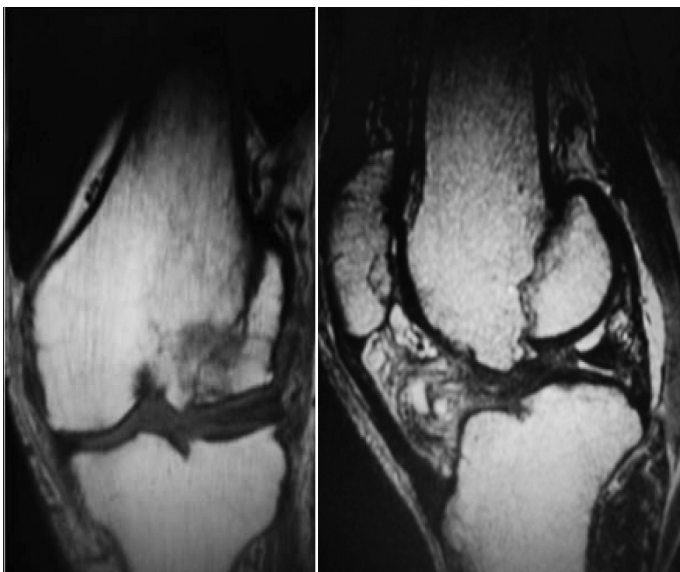
Figure 7- Intraoperative analysis.



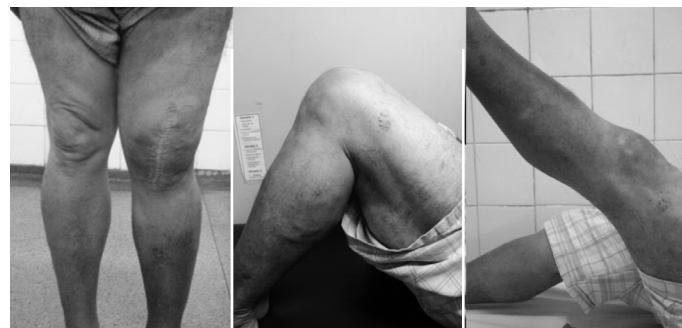Figures 3 and 4 – Preoperative radiographs.



Figures 8 and 9 – Postoperative radiographs.



Figures 5 and 6 – Preoperative magnetic resonance images.



Figures 10, 11 and 12 – Postoperative clinical evaluation.

DISCUSSION

Because Hoffa fractures are extremely rare injuries⁽⁷⁾, the percentage presenting pseudarthrosis is so far unknown⁽⁸⁾. The treatment for this type of lesion encompasses many particular features that have

caused controversy in the literature⁽⁹⁾. Yoshino et al signaled that in treating patients with distal femoral fractures associated with knee osteoarthritis, the type of fracture and the systemic condition should be taken into consideration⁽¹⁰⁾. In our opinion, a 60-year-old patient with Hoffa fracture pseudarthrosis associated with venous insufficiency and early arthrosis would achieve greatest benefit through TKA. When we discovered that our patient was an alcoholic, our indication gained further validation.

With regard to the etiology of the joint degeneration process, we believe that it is useful to differentiate primary osteoarthritis from conditions that are secondary to knee fractures, because we take the view that the fracture pattern may give rise to bone stock changes. There are several studies in the literature in which prostheses with greater constriction were used for distal femoral fractures⁽¹¹⁻¹⁶⁾. Osteoarthritis secondary to knee fractures causes bone losses that may give rise to technical difficulties because of unusual anatomy. For this reason, it is prudent to carry out a good preoperative evaluation (both clinical and radiographic), and sometimes to request implant revision.

Single-compartment arthroplasty was another option considered, but the long-term results from TKA have been well established in the worldwide literature. Moreover, within our setting, Camanho et al⁽¹⁷⁾ did not recommend lateral single-compartment arthroplasty.

The advantage of TKA over osteosynthesis for Hoffa fractures is the early return to walking and rapid return to normal daily life. It should be borne in mind that our patient was 60 years old and had a history of alcoholism. Alcohol not only is a risk factor for pseudarthrosis but also makes such patients undisciplined, in that they often start walking earlier than advised. In TKA cases, alcohol use has been correlated with a higher infection rate because such patients are generally malnourished⁽¹⁸⁾. The approach taken for the TKA on our patient included conventional prophylaxis with cefazolin for 24 hours. The patient's condition of intense pain was what motivated us to continue with the indication of TKA.

With regard to venous insufficiency, prevention

of thromboembolism was achieved through general measures (compressive bandaging, elevation of the lower limbs, partial weight-bearing on the second postoperative day and early physiotherapy) and through drug therapy consisting of enoxaparin 40 mg subcutaneously for two weeks.

There are many articles in the literature showing correlations of distal femoral fractures after TKA⁽¹⁹⁻²⁸⁾. On the other hand, in a review of the literature than we conducted, to correlate the use of TKA following Hoffa fracture pseudarthrosis, we found that there was currently no literature.

Pearse et al reported that TKA is a reasonable choice for elderly patients with distal femoral fractures⁽²⁹⁾. Worldwide, life expectancy is continually increasing, thus turning elderly people into active people who require rapid recovery with knees that are close to normal.

Wolfgang⁽³⁰⁾ affirmed that TKA is an appropriate surgical choice for patients with intercondyle fractures of the femur and rheumatoid arthritis. We believe that we have validated this author's affirmation, although attention is required with regard to the greater postoperative complication rate^(31,32).

Kress et al⁽³³⁾ concluded that pseudarthrosis of the distal femur could be treated by means of total knee arthroplasty, through using a long nail without cement, fitted under pressure together with the bone graft. In our view, revision implants are an option to be considered, depending on the fracture pattern, although it becomes necessary to use bone cement.

Rosen et al⁽³⁴⁾ took the view that the geriatric population has relative indications for undergoing TKA in situations of distal femoral fracture: intra-articular fracture, severe joint damage, preexisting arthrosis, severe osteopenia, delayed consolidation or pseudarthrosis. We corroborate this thinking and also advocate this.

Anderson et al⁽³⁵⁾ proved that TKA with long nails was effective for treating pseudarthrosis of distal femoral fractures. We believe that indications for these implants exist, although in our case we chose to use a conventional TKA. We emphasize that TKA is a soft-tissue surgical procedure in which ligament balance is fundamental for good functional results. In our case, because it consisted of pseudarthrosis of a lateral condylar fracture, we chose to use a prosthesis

that would preserve the posterior cruciate ligament. We believe that the posterior cruciate ligament does not interfere with the anatomy of the lateral condyle, and therefore we chose to use a prosthesis that would preserve the bone stock more.

CONCLUSION

Total knee arthroplasty is a viable option for 60-year-old patients with Hoffa fracture pseudarthrosis and comorbidities.

REFERENCES

- Font-Rodriguez DE, Scuderi GR, Insall JN. Survivorship of cemented total knee arthroplasty. *Clin Orthop Relat Res.* 1997;(345):79-86.
- Ritter MA. The Anatomical Graduated Component total knee replacement: a long-term evaluation with 20-year survival analysis. *J Bone Joint Surg Br.* 2009;91(6):745-9.
- Ritter MA, Herbst SA, Keating EM, Faris PM, Meding JB. Long-term survival analysis of a posterior cruciate-retaining total condylar total knee arthroplasty. *Clin Orthop Relat Res.* 1994;(309):136-45.
- Rand JA, Ilstrup DM. Survivorship analysis of total knee arthroplasty. Cumulative rates of survival of 9200 total knee arthroplasties. *J Bone Joint Surg Am.* 1991;73(3):397-409.
- Insall JN, Kelly M. The total condylar prosthesis. *Clin Orthop Relat Res.* 1986;(205):43-8.
- Gandhi R, Tsvetkov D, Davey JR, Mahomed NN. Survival and clinical function of cemented and uncemented prostheses in total knee replacement: a meta-analysis. *J Bone Joint Surg Br.* 2009;91(7):889-95.
- Holmes SM, Bomback D, Baumgaertner MR. Coronal fractures of the femoral condyle: a brief report of five cases. *J Orthop Trauma.* 2004;18(5):316-9.
- McDonough PW, Bernstein RM. Nonunion of a Hoffa fracture in a child. *J Orthop Trauma.* 2000;14(7):519-21.
- Mallina R, Kanakaris NK, Giannoudis PV. Peri-articular fractures of the knee: an update on current issues. *Knee.* 2010;17(3):181-6.
- Yoshino N, Takai S, Watanabe Y, Fujiwara H, Ohshima Y, et al. Primary total knee arthroplasty for supracondylar/condylar femoral fracture in osteoarthritic knees. *J Arthroplasty.* 2001;16(4):471-5.
- Bell KM, Johnstone AJ, Court-Brown CM, Hughes SP. Primary knee arthroplasty for distal femoral fractures in elderly patients. *J Bone Joint Surg Br.* 1992;74(3):400-2.
- In Y, Koh HS, Kim SJ. Cruciate-retaining stemmed total knee arthroplasty for supracondylar-intercondylar femoral fractures in elderly patients: a report of three cases. *J Arthroplasty.* 2006;21(7):1074-9.
- Appleton P, Moran M, Houshian S, Robinson CM. Distal femoral fractures treated by hinged total knee replacement in elderly patients. *J Bone Joint Surg Br.* 2006;88(8):1065-70.
- Nau T, Pfelegerl E, Erhart J, Vecsei V. Primary total knee arthroplasty for periarticular fractures. *J Arthroplasty.* 2003;18(8):968-71.
- Weiss NG, Parvizi J, Hanssen AD, Trousdale RT, Lewallen DG. Total knee arthroplasty in post-traumatic arthrosis of the knee. *J Arthroplasty.* 2003;18(3 Suppl 1):23-6.
- Papadopoulos EC, Parvizi J, Lai CH, Lewallen DG. Total knee arthroplasty following prior distal femoral fracture. *Knee.* 2002;9(4):267-74.
- Camanho GL, Viegas AC, Camanho LF, Camanho CR, Forgas A. Artroplastia unicompartimental no tratamento da artrose medial do joelho. *Rev Bras Ortop.* 2007;42(9):285-9.
- Pulido L, Ghanem E, Joshi A, Purtill JJ, Parvizi J. Periprosthetic joint infection: the incidence, timing, and predisposing factors. *Clin Orthop Relat Res.* 2008;466(7):1710-5.
- Bezuada HP, Neubauer P, Baker J, Israelite CL, Johanson NA. Periprosthetic supracondylar femur fractures following total knee arthroplasty. *J Arthroplasty.* 2004;19(4):453-8.
- Tharani R, Nakasone C, Vince KG. Periprosthetic fractures after total knee arthroplasty. *J Arthroplasty.* 2005;20(4 Suppl 2):27-32.
- Kim KI, Egol KA, Hozack WJ, Parvizi J. Periprosthetic fractures after total knee arthroplasties. *Clin Orthop Relat Res.* 2006;446:167-75.
- Su ET, Kubiak EN, Dewal H, Hiebert R, Di Cesare PE. A proposed classification of supracondylar femur fractures above total knee arthroplasties. *J Arthroplasty.* 2006;21(3):405-8.
- Fujii R, Ueda T, Tamai N, Myoui A, Yoshikawa H. Salvage surgery for persistent femoral nonunion after total knee arthroplasty using a megaprosthesis. *J Orthop Sci.* 2006;11(4):401-4.
- Parvizi J, Jain N, Schmidt AH. Periprosthetic knee fractures. *J Orthop Trauma.* 2008;22(9):663-71.
- Kendoff DO, Fragomen AT, Pearle AD, Citak M, Rozbruch SR. Computer navigation and fixator-assisted femoral osteotomy for correction of malunion after periprosthetic femur fracture. *J Arthroplasty.* 2010;25(2):333.e13-9.
- Bobak P, Polyzois I, Graham S, Gamie Z, Tsiridis E. Nailed cementoplasty: a salvage technique for rorabeck type II periprosthetic fractures in octogenarians. *J Arthroplasty.* 2010;25(6):939-44.
- Mortazavi SM, Kurd MF, Bender B, Post Z, Parvizi J, Purtill JJ. Distal femoral arthroplasty for the treatment of periprosthetic fractures after total knee arthroplasty. *J Arthroplasty.* 2010;25(5):775-80.
- Alencar PGC, De Bortoli G, Vieira IFV, Uliana CS. Fraturas periprotéticas em artroplastia total de joelho. *Rev Bras Ortop.* 2010;45(3):230-5.
- Pearse EO, Klass B, Bendall SP, Railton GT. Stanmore total knee replacement versus internal fixation for supracondylar fractures of the distal femur in elderly patients. *Injury.* 2005;36(1):163-8.
- Wolfgang GL. Primary total knee arthroplasty for intercondylar fracture of the femur in a rheumatoid arthritic patient. A case report. *Clin Orthop Relat Res.* 1982;(171):80-2.
- Lonner JH, Pedlow FX, Siliski JM. Total knee arthroplasty for post-traumatic arthrosis. *J Arthroplasty.* 1999;14(8):969-75.
- Bedi A, Haidukewych GJ. Management of the posttraumatic arthritic knee. *J Am Acad Orthop Surg.* 2009;17(2):88-101.
- Kress KJ, Scuderi GR, Windsor RE, Insall JN. Treatment of nonunions about the knee utilizing custom total knee arthroplasty with press-fit intramedullary stems. *J Arthroplasty.* 1993;8(1): 49-55.
- Rosen A, Strauss E. Primary total knee arthroplasty for complex distal femur fractures in elderly patients. *Clin Orthop Relat Res.* 2004;(425):101-5.
- Anderson SP, Matthews LS, Kaufer H. Treatment of juxtaarticular nonunion fractures at the knee with long-stem total knee arthroplasty. *Clin Orthop Relat Res.* 1990;(260):104-9.