

# OSTEOID OSTEOMA IN THE ILIAC BONE: REPORT ON TWO CASES

Elmano de Araújo Loures<sup>1</sup>, Bruno Fajardo do Nascimento<sup>2</sup>, Marcelo de Carvalho Amorim<sup>2</sup>, Clarice Naya Loures<sup>3</sup>

## ABSTRACT

Osteoid osteoma is a benign bone tumor that generally presents with nighttime pain among young adults and is relieved by rest and salicylates. It can affect any bone, but occurrences in the iliac are unusual. The authors describe two cases of intramedullary osteoid osteoma next to the sacroiliac joint, with symptoms that simulated sciatic pain. The cases were diagnosed late, although the initial radiographs showed sclerotic lesions in both cases. The diagnosis was confirmed by means

of CT scan and the nidus was excised surgically through en bloc resection. The definitive diagnosis was given by means of histopathological examination. Over long-term follow-up, both cases remained asymptomatic and complete bone remodeling at the surgical site was observed. The authors highlight the typical characteristics of the tumor, the unusual location, the differential diagnosis and the treatment.

**Keywords** – Osteoma, Osteoid; Bone Neoplasms; Ilium; Sacroiliac Joint

## INTRODUCTION

Osteoid osteoma was first described by Jaffe in 1935 and is a benign lesion<sup>(1)</sup> that preferentially affects adolescents and young adults, in the approximate male-to-female proportions of 2:1<sup>(2,3)</sup>. The lesions are generally small, not exceeding one centimeter in diameter, and present a well delimited rim and usually a peripheral zone of reactive bone neoformation. They predominantly affect the appendicular skeleton, especially the femur and tibia<sup>(4)</sup>. Their presence has been reported in practically all the bones of the skeleton, including the cranium, face and spine<sup>(5)</sup>. They only rarely occur in the pelvis: just 1 to 3% of all cases are located in this region, and the majority of pelvic lesions are found in the acetabulum<sup>(6)</sup>.

Macroscopically, they are characterized by a friable vascular niche (nidus) with sandy consistency, surrounded by sclerotic bone in association with thick vascular periosteum. Microscopically, the nidus consists of osteoid tissue, with vascular stroma surrounded by dense bone<sup>(7)</sup>.

The diagnosis can be made by means of simple

radiography in 75% of the cases<sup>(8)</sup>. The typical image comprises a nidus that appears in the form of a small oval or rounded focus that is generally radiotransparent. This is surrounded by a zone of variable density corresponding to reactive bone sclerosis and, on some occasions, this zone may be very intense and cause difficulty in viewing the nidus. In such cases, bone scintigraphy, computed tomography or magnetic resonance can be used to determine the exact location of the nidus<sup>(9,10)</sup>.

The typical clinical evolution is characterized by pain, predominantly during the night, probably because of increased synthesis of prostaglandins triggered by the tumor. In most cases, aspirin and other non-steroidal anti-inflammatory drugs (NSAIDs) that act by blocking prostaglandin synthesis provide transitory but significant pain relief. It is rare for the lesions to be painless<sup>(11)</sup>. Regarding their location within the bone, subperiosteal, intracortical, endosteal and intramedullary lesions can be identified, among which intramedullary lesion are the least frequent<sup>(12)</sup>.

1 – Specialist in Orthopedics and Traumatology; Supervisor of the Medical Residence Program in Orthopedics and Traumatology, Department of Orthopedics and Traumatology, University Hospital, Federal University of Juiz de Fora, Juiz de Fora, MG, Brazil.

2 – Resident in the Department of Orthopedics and Traumatology, University Hospital, Federal University of Juiz de Fora, Juiz de Fora, MG, Brazil.

3 – Undergraduate Medical Student, Department of Morphology, Institute of Biological Sciences and School of Medicine, Federal University of Juiz de Fora, Juiz de Fora, MG, Brazil.

Work performed at the University Hospital, Federal University of Juiz de Fora, and the Orthopedics Center, Rio Branco Medical Center, Juiz de Fora, MG.

Correspondence: Av. Olegário Maciel 297/1101, 36015-350 Juiz de Fora, MG. E-mail: loures.elmano@oi.com.br

Work received for publication: May 24, 2011; accepted for publication: June 3, 2011.

The authors declare that there was no conflict of interest in conducting this work

This article is available online in Portuguese and English at the websites: [www.rbo.org.br](http://www.rbo.org.br) and [www.scielo.br/rbort](http://www.scielo.br/rbort)

The present study had the aim of presenting a report on two cases of intramedullary osteoid osteoma with unusual locations and clinical presentations. Reference is also made to the importance of the differential diagnosis (in these cases, with lumbalgia and pain of sciatic origin), in comparison with the data in the literature.

## CASE REPORTS

### Case 1

The patient was a 38-year-old male carpenter. His pain started in the lumbar and sacroiliac region, with intermittent irradiation to the right buttock, i.e. a picture similar to pain of sciatic origin. He underwent clinical treatment with physiotherapy and analgesics for one year, with any satisfactory result. Imaging examinations on the lumbar spine showed normal results. There was a partial improvement through using NSAIDs, but the pain worsened through exertion relating to his profession. He described nocturnal pain and insomnia. Simple radiography on the pelvis in AP view showed a lesion with central radiopacity in the iliac wing, with an intense sclerotic halo that extended as far as the sacroiliac joint. The diagnosis was confirmed by means of computed tomography. HLA B-27 investigation and other laboratory tests produced normal results (Figures 1 and 2). The treatment implemented was en-bloc resection of the lesion, in February 1998. The nidus was located intraoperatively by means of radiographs. There was complete remission of the symptoms, and follow-up examinations after 10 years of evolution showed that complete bone remodeling had taken place at the site of the operation, and the individual remained free from symptoms.

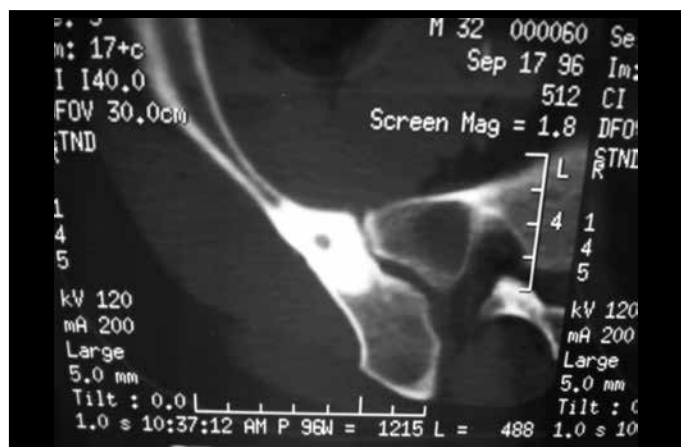

Figure 1 – Case 1: computed tomography.

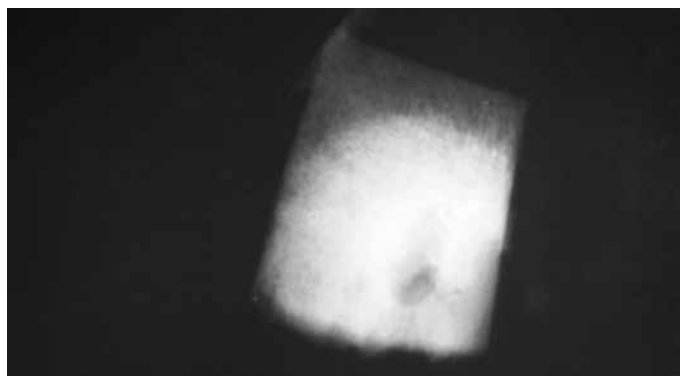


Figure 2 – Case 1: radiograph of the surgical specimen from the right iliac bone. Note the resected nidus and the bone sclerosis.

### Case 2

The patient was a 46-year-old female housewife. She had had constant pain in the lumbar and right sacroiliac regions for eight months, with poorly defined irradiation to the buttock and posterior face of the right thigh, thus simulating pain of sciatic origin. Clinical treatment during this period, with physiotherapy sessions and analgesics, was fruitless. Imaging examinations in the lumbar region showed a mild degree of spondylodiscoarthrosis. Simple radiography on the pelvis showed a sclerotic lesion in the iliac that impinged in the margin of the sacroiliac joint, without a clear nidus. The diagnosis was confirmed by means of computed tomography (Figure 3). Laboratory tests showed normal results, including in relation to HLA B-27. The treatment proposed was en-bloc resection of the lesion, which was performed in May 2000. The nidus was located intraoperatively by means of radiographs. There was complete remission of the symptoms, and follow-up examinations after 10 years of evolution showed that complete bone remodeling had taken place at the site of the operation, and the individual remained free from symptoms.

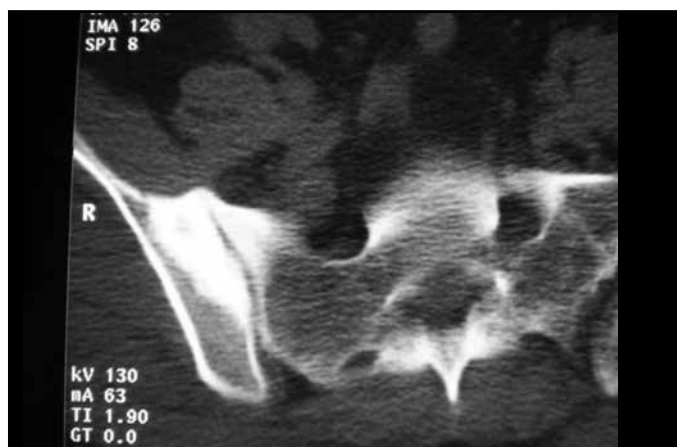


Figure 3 – Case 2: computed tomography on the right iliac bone.

## DISCUSSION

In the cases reported here, the patients consulted several specialists until a confirmed diagnosis was achieved, proven through histopathological analysis. The diagnostic hypothesis of osteoid osteoma as the cause of insidious nocturnal bone pain that is of long duration and is alleviated by salicylates and NSAIDs should be considered in the differential diagnosis of any painful state involving the skeleton<sup>(13)</sup>. The lesion can often only be identified by means of conventional radiographic examination, but computed tomography and magnetic resonance imaging are necessary to elucidate and/or confirm the diagnosis, and they are useful for surgical planning<sup>(10)</sup>. In a bibliographic review in Medline and Latin American Lilacs, only 14 reports on cases of osteoid osteoma located in the iliac bone between 1945 and 2010 were found.

Spontaneous cure has been well documented in some studies. The pain and radiological findings were observed to gradually disappear, although some degree of bone sclerosis remained<sup>(14)</sup>. The natural history of this disease is unpredictable and prolonged, and surgical intervention is indicated<sup>(15)</sup>.

Radiofrequency ablation guided by computed tomography is an alternative that has been used with very promising results, especially in regions that are difficult to access through conventional surgery<sup>(16,17)</sup>.

The literature indicates that the preferred treatment is en-bloc surgical resection, including the nidus<sup>(18)</sup>. Consequently, determining the exact location of the nidus during the operation is crucial for the success of the intervention, which was done in the present cases using conventional radiological markers.

## CONCLUSION

The possibility that osteoid osteoma can occur in any bone at any location highlights the overwhelming need for careful assessment of imaging examinations and recognition of the importance of the clinical condition. Involvement of the iliac bone is very uncommon, and osteoid osteoma in unusual locations generally leads to late diagnosis, with the possibility of confounding this with other pathological conditions. In the cases reported here, en-bloc surgical resection of the lesion was shown to be an effective and safe method, as reported in the literature.

## REFERENCES

- Broadfoot J, Chapman G. The use of computed tomography in diagnosis of osteoid osteoma. *Australas Radiol.* 1988;32(3):463-7.
- Schaefer MP, Smith J. The diagnostic and therapeutic challenge of femoral head osteoid osteoma presenting as thigh pain: a case report. *Arch Phys Med Rehabil.* 2003;84(6):904-5.
- Sinha S, Housden P. Discrete synchronous multifocal osteoid osteoma of the femur: a case report and review of literature. *Pediatr Radiol.* 2004;34(3):280.
- Radcliffe SN, Walsh HJ, Carty H. Osteoid osteoma: the difficult diagnosis. *Eur J Radiol.* 1998;28(1):67-79.
- Iffenecker C, Rocher P, Rabia MH, Dhina Z, Bobin S, Quillard J, et al. Osteoid osteoma of the petrous bone. *Neuroradiology.* 1997;39(11):821-3.
- Ishikawa Y, Okada K, Miyakoshi N, Takahashi S, Shimada Y, Itoi E, et al. Osteoid osteoma of the scapula associated with synovitis of the shoulder. *J Shoulder Elbow Surg.* 2005;14(3):329-32.
- Akhlaghpour S, Aziz Ahari A, Arjmand Shabestari A, Alinaghizadeh MR. Radiofrequency ablation of osteoid osteoma in atypical locations: a case series. *Clin Orthop Relat Res.* 2010;468(7):1963-70.
- Swee RG, McLeod RA, Beabout JW. Osteoid osteoma. Detection, diagnosis, and localization. *Radiology.* 1979;130(1):117-23.
- Pratali R, Zuiani G, Inada M, Hanasilo C, Reganin L, Etchebehere E, et al. Open resection of osteoid osteoma guided by a gamma-probe. *Int Orthop.* 2009;33(1):219-23.
- Barros Filho TEP, Oliveira RP, Cristante AF, Barbarini AF. Tratamento de osteoma osteoide de corpo vertebral da coluna lombar por ablação por radiofrequência. *Acta Ortop Bras.* 2006;14(2):103-5.
- Lee EH, Shafi M, Hui JH. Osteoid osteoma: a current review. *J Pediatr Orthop.* 2006;26(5):695-700.
- Kayser F, Resnick D, Haghighi P, Pereira Edo R, Greenway G, Schweitzer M, et al. Evidence of the subperiosteal origin of osteoid osteomas in tubular bones: analysis by CT and MR imaging. *AJR Am J Roentgenol.* 1998;170(3):609-14.
- Hartmann T, Preis C, Gabriel A, Rath T, Ilias W. An osteoid osteoma as an undiagnosed cause of three years of severe pain. *Anesth Analg.* 1997;85(6):1344-5.
- Kneisl JS, Simon MA. Medical management compared with operative treatment for osteoid-osteoma. *J Bone Joint Surg Am.* 1992;74(2):179-85.
- Baptista PPR, Próspero JD, Volpe Neto F, Polesello GC, Barros MGA, Sanmartín Fernández M, et al. Osteoma osteoide: planejamento diagnóstico e técnica cirúrgica. *Rev Bras Ortop.* 1996;31(11):883-7.
- Cioni R, Armillotta N, Bargellini I, Zampa V, Cappelli C, Vagli P, et al. CT-guided radiofrequency ablation of osteoid osteoma: long-term results. *Eur Radiol.* 2004;14(7):1203-8.
- Sung KS, Seo JG, Shim JS, Lee YS. Computed-tomography-guided percutaneous radiofrequency thermoablation for the treatment of osteoid osteoma-2 to 5 years follow-up. *Int Orthop.* 2009;33(1):215-8.
- Kronbauer FL, Ortiz R, Kronbauer AL, Zylbersztejn S. Osteoma osteoide no osso ilíaco: relato de caso. *Rev Bras Ortop.* 1997;32(12):985-8.