

OSTEOID OSTEOMA IN SCAPHOID: CASE REPORT

Antônio Lourenço Severo¹, Raimundo de Araújo Filho¹, Rulby Puentes¹, Marcelo Barreto Lemos¹, Paulo Faiad Piluski¹, Osvandré Lech²

ABSTRACT

Osteoid osteoma is a benign osteoblastic tumor that is unusual in the hand. A location in the carpal bones is infrequent, which leads to errors in diagnosing it because of polymorphism of the clinical symptoms. Reviewing the literature shows that nine cases of osteoid osteoma in the

scaphoid have been reported. Here, one case of osteoid osteoma in the scaphoid that was initially treated as De Quervain's stenosing tenosynovitis is reported, with a definitive diagnosis that was delayed for five years.

Keywords – Osteoma, Osteoid; Scaphoid Bone; Diagnostic Imaging

INTRODUCTION

Osteoid osteoma is a benign osteoblastic tumor that was first described by Jaffe and Moyer in 1935 *apud* Ozalp *et al*⁽¹⁾ and Laffosse *et al*⁽²⁾. It usually occurs between the second and third decades of life, with greater frequency among men (2:1)^(1,2). The usual location is in the long bones, while it occurs infrequently in the carpal bones, which leads to diagnostic errors due to polymorphism of the clinical signs⁽²⁾. The present study examines a case of osteoid osteoma in the scaphoid that was previously diagnosed as De Quervain's tenosynovitis and was treated surgically. From reviewing the literature, 10 cases of osteoid osteoma in the scaphoid have been reported, including this one^(1,3-5).

This was a retrospective investigation on osteoid osteoma in the hand, which is rare at this site, especially in the scaphoid, and it is often confounded with other clinical entities.

CASE REPORT

The patient was a 47-year-old male who was an administrator. He presented pain in the region of the left anatomical snuffbox that had evolved over a five-year period. He had undergone previous surgical treatment in another institution with a diagnosis of De

Quervain's tenosynovitis, without any benefits from the procedure (Figure 1). He evolved with worsening of the symptoms, particularly at night. Ingestion of acetylsalicylic acid was used as a clinical test, which produced improvement of the symptoms. Simple radiographic examination demonstrated a suspicious well-delimited oval radiolucent area of approximately 1 cm in diameter, with a central dark point (niche) in the left scaphoid (Figure 2). Magnetic resonance imaging (MRI) demonstrated reactive sclerosis surrounding the central radiolucency (niche), which led to a diagnostic hypothesis of osteoid osteoma in the scaphoid (Figure 3). Excisional resection with curettage was performed using the same dorsolateral access as used for the previous incision (Figures 4 and 5). The histopathological examination confirmed the diagnosis of osteoid osteoma (Figure 6). Immediately after the operation, the symptoms disappeared. After 15 months of follow-up, there was no recurrence and the patient remained free from pain (Figure 7).

DISCUSSION

Osteoid osteoma is a benign solitary bone tumor that is usually located in the cortical bone tissue of the long bones, particularly in the proximal femur and tibia, which account for 50% of the cases. Another

1 – Orthopedist in the Upper-Limb Surgical Center, Institute of Orthopedics and Traumatology, Passo Fundo, RS, Brazil.

2 – Orthopedist and Head of Medical Residence at the Institute of Orthopedics and Traumatology, Passo Fundo, RS, Brazil.

Work performed at the Hospital of the Institute of Orthopedics and Traumatology (HIOT) in association with Hospital São Vicente de Paulo (HSVP), Passo Fundo, RS, Brazil.

Correspondence: Rua Uruguai 2050, 99010-112 Passo Fundo, RS, Brazil. E-mail: al.severo@terra.com.br

Work received for publication: June 19, 2011; accepted for publication: August 15, 2011.

The authors declare that there was no conflict of interest in conducting this work

This article is available online in Portuguese and English at the websites: www.rbo.org.br and www.scielo.br/rbort

30% are located in the spine, pelvis, feet and hands. The hands account for 8% of the cases, with greatest frequency in the proximal phalange, while the carpus and metacarpus are infrequent sites^(1,2,4). This condition is diagnosed through clinical, radiographic,

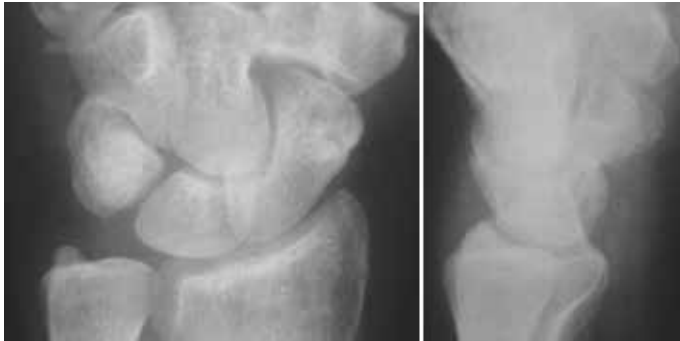

Figure 1 – Previous surgical incision in left wrist for treatment as De Quervain's stenosing tenosynovitis.

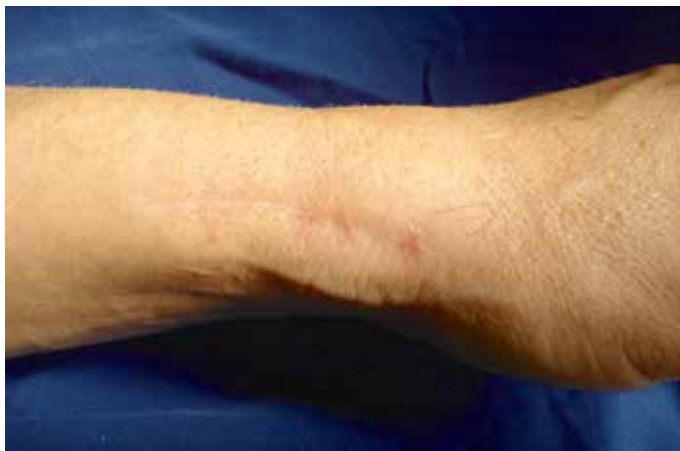

Figure 2 – Simple radiographic examination showing a suspicious well-delimited oval radiolucent area of approximately 1 cm in diameter, with a central dark point (niche) in the left scaphoid.

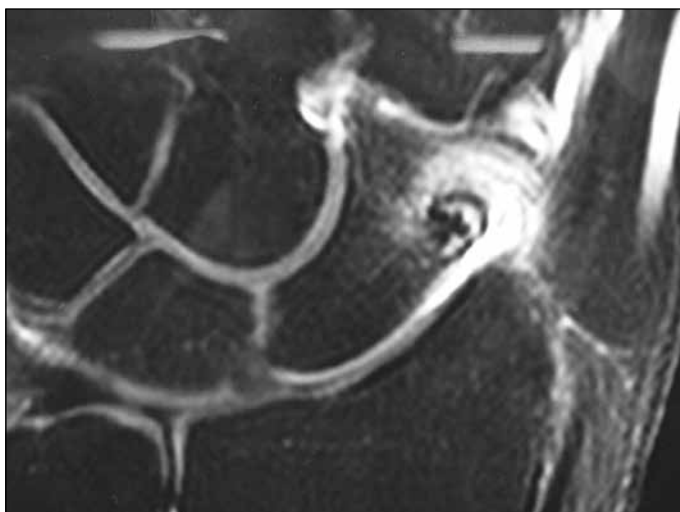


Figure 3 – Magnetic resonance imaging demonstrating reactive sclerosis surrounding central radiolucency (niche), thus leading to the diagnostic hypothesis of osteoid osteoma in the scaphoid.

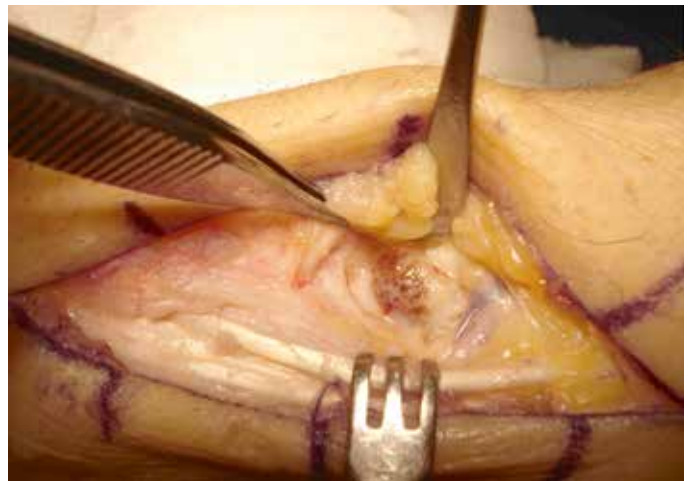


Figure 4 – Excisional resection with curettage by means of the same dorso-lateral access as used for the previous incision.

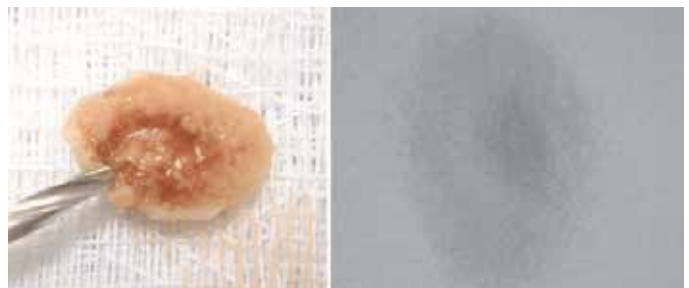


Figure 5 – Surgical specimen with radiographic representation by means of image intensifier.

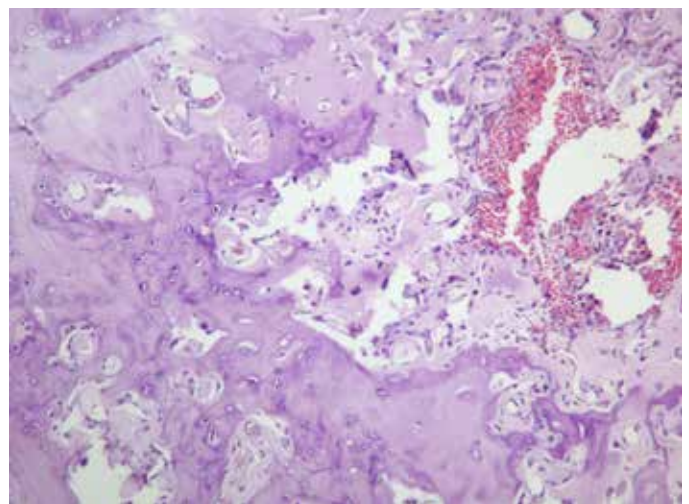


Figure 6 – Histological image of the resected lesion.

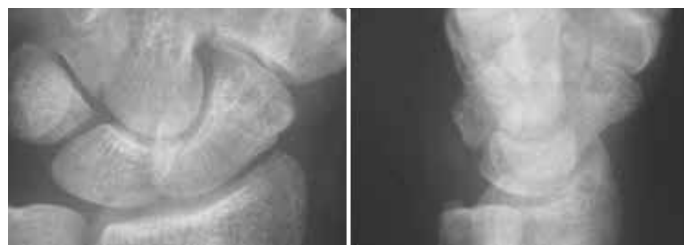

Figure 7 – Radiographic examination after follow-up of 15 months, showing absence of lesions.

scintigraphic, computed tomography, magnetic resonance imaging and histopathological examinations⁽¹⁾. In 80% of the cases, this pathological condition characteristically produces insidious pain located in the affected area and local edema, with worsening at night and with alcohol ingestion, while it is ameliorated through use of acetylsalicylic acid and prostaglandin-inhibiting anti-inflammatory agents⁽³⁾. In hands, the diagnosis may be delayed due to nonspecific symptoms⁽¹⁾. On magnetic resonance imaging, the condi-

tion presents as an annular spectrum in the format of an island (niche) composed of small and richly vascularized tissue, with different rounded peripheral levels of radiolucency^(2,3).

Histopathological analysis shows small irregularities of peripheral bone trabeculation, in irregular waves, with a ring of stroma of richly vascularized connective tissue⁽³⁾. The definitive treatment for osteoid osteoma is surgical excision with curettage, with or without associated bone grafting⁽¹⁾.

REFERÊNCIAS

- Ozalp T, Yercan H, Okcu G. Osteoid osteoma of the scaphoid bone: a case report. *Firat Tıp Dergisi*. 2008;13(1):59-61.
- Laffosse JM, Tricoire JL, Cantagrel A, Wagner A, Puget J. Osteoid osteoma of the carpal bones. Two case reports. *Joint Bone Spine*. 2006;73(5):560-3.
- Themistocleous GS, Chloros GD, Mavrogenis AF, Khaldi L, Papagelopoulos PJ, Efsthathopoulos DG. Unusual presentation of osteoid osteoma of the scaphoid. *Arch Orthop Trauma Surg*. 2005;125(7):482-5.
- Bednar MS, McCormack RR Jr, Glasser D, Weiland AJ. Osteoid osteoma of the upper extremity. *J Hand Surg Am*. 1993;18(6):1019-25.
- Nascimento RJ, Varney TE, Kasparyan NG, Warhold LG. Intracortical osteoid osteoma of the scaphoid. *Orthopedics*. 2007;30(7):573-4.