



Original Article

Treatment of chronic plantar fasciitis with extra corporeal shock wave therapy: ultrasonographic morphological aspect and functional evaluation[☆]

Roberto Androsani*, Alfonso Apostólico Netto, Rafael Rocha Macedo, Ricardo Pozzi Fasolin, Guilherme Boni, Rodrigo Fileto Gavalvão Moreira

Hospital IFOR, São Bernardo do Campo, SP, Brazil

ARTICLE INFO

Article history:

Received 2 April 2013

Accepted 11 April 2013

Keywords:

Fasciitis, plantar
High energy shock
waves/therapeutic use
Ultrasonography
Evaluation
Morphology

ABSTRACT

Objective: This paper has the purpose to analyze prospectively the treatment results in patients with chronic plantar fasciitis resistant to conservative treatment who underwent extracorporeal shock wave therapy (ESWT).

Methods: We evaluated 30 patients (36 feet); 16 (53.3%) patients were male and 14 (47.7%) female with mean age of 48.7 y.o., varying from 33 to 78 y.o.; 16 (53.3%) present the problem on the left side, 14 (46.7%) on the right ones and 6 (20%) bilateral; the symptomatology varied from 6 to 60 months, with the average of 13.58 months. These patients were submitted to a weekly ESWT session for 4 consecutive weeks. We measured the plantar fascia thickness millimeters with ultrasound and we applied American Orthopaedic Foot and Ankle Society (AOFAS) scale for ankle and hindfoot, and Roles & Maudsley scales in pre ESWT, after one, three and six months after and decrease in the plantar fascia thickness by the ultrasound ($p=0.011$) along the different moments studied.

Results: We observed improvement of the evaluated criteria ($p<0.001$) and plantar fascia thickness by ultrasound ($p=0.011$) at different time points studied.

Conclusion: The ESWT can be considered an important tool in the primary or adjuvant treatment of the chronic plantar fasciitis when associated with conventional therapies. This methodology is safe, non-invasive and provides precocious rehabilitation and return to regular activities considering the results of the statistical analysis. This resource provides decrease in the thickness of the plantar fascia.

© 2013 Sociedade Brasileira de Ortopedia e Traumatologia. Published by Elsevier Editora Ltda. All rights reserved.

[☆] Work performed at Hospital IFOR, São Bernardo do Campo, SP, Brazil.

* Corresponding author.

E-mail: randrosani@ifor.com.br (R. Androsani).

Tratamento da fasciíte plantar crônica pela terapia de ondas de choque: avaliação morfológica ultrassonográfica e funcional

R E S U M O

Palavras-chave:

Fasciíte plantar
Ondas de choque de alta energia/uso terapêutico
Ultrassonografia
Avaliação
Morfologia

Objetivo: Este trabalho teve como objetivo analisar prospectivamente os resultados do tratamento com terapia de ondas de choque (TOC) em pacientes portadores de fasciíte plantar crônica resistente ao tratamento conservador.

Métodos: Obtivemos 30 pacientes (36 pés), 16 (53,3%) do sexo masculino e 14 (47,7%) do feminino, cuja idade, em média, foi de 48,37 anos, com variação de 33 a 78 anos; 16 (53,3%) apresentavam a afecção no pé esquerdo, 14 (46,7%) no direito e seis (20%) bilateralmente; a sintomatologia variou de seis a 60 meses, com média de 13,58 meses. Os pacientes foram submetidos a uma sessão semanal de TOC por quatro semanas consecutivas. Mensuramos a espessura da fásia plantar em milímetros pelo ultrassom e usamos a escala da American Orthopaedic Foot and Ankle Society (AOFAS) para tornozelo e retropé e a escala de Roles & Maudsley nos momentos pré-TOC, após o primeiro, o terceiro e o sexto meses após a aplicação.

Resultados: Observamos melhoria dos critérios avaliados ($p < 0,001$) e da espessura da fásia plantar pelo ultrassom ($p = 0,011$) nos diferentes momentos estudados.

Conclusão: A TOC pode ser considerada importante instrumento no tratamento primário ou adjuvante da fasciíte plantar crônica, quando aliada às terapias convencionais. Essa metodologia é segura, não invasiva e promove reabilitação e retorno precoces às atividades habituais pelos resultados das análises estatísticas. Proporciona também redução da espessura da fásia plantar.

© 2013 Sociedade Brasileira de Ortopedia e Traumatologia. Publicado por Elsevier Editora Ltda. Todos os direitos reservados.

Introduction

Plantar fasciitis is characterized as a degenerative condition of the proximal plantar aponeurosis. The site most frequently involved is at the medial tuberosity of the calcaneus. The pathological findings from this nosological entity include degenerative tissue changes characterized by fibroblastic proliferation and presence of inflammatory tissue.¹⁻³ It is now accepted that this fasciopathy should be classified as a type of enthesopathy, even though its physiopathology is poorly understood.

Several therapeutic options have been described, among which conservative treatment is taken to be the preferred method. Satisfactory results have thus been achieved in around 90% of the patients.

Use of anti-inflammatory medications, analgesics and local infiltration of corticoids and platelet-rich plasma (PRP) is recommended. Furthermore, use of insoles, heel supports, splints and nighttime braces, along with physiotherapy, is also recommended, with the aim of aiding in achieving remission of the inflammatory and painful condition.⁴⁻⁶

More recently, some studies have demonstrated that application of a dehydrated human amniotic membrane (dHAM) is effective. Other studies have demonstrated similar efficacy through application of high molecular weight hyaluronic acid. Changes to lifestyle habits, such as weight reduction and use of appropriate footwear, and also postural changes during work,⁷⁻¹⁰ are further recommendations.

The other 10% of the patients, whose condition is not resolved through conservative treatment, can be considered to be cases of recalcitrant fasciopathy. In these cases, surgical

treatment may be useful, in order to achieve open or endoscopic release of the plantar fascia,¹¹ with excision of the diseased tissue. In some specific cases, simultaneous nerve decompression is indicated.

In an attempt to avoid an invasive procedure, there have been many studies on shockwave therapy in chronic cases. This technique has been shown to be effective for improving the symptoms and quality of life of patients with this condition. The basic idea of shockwave therapy is to stimulate the tissue regeneration process in the bones and tendons.^{12,13} Its efficacy is noted especially in the tissues surrounding the bone and tendons, and also at the bone-tendon interface (entheses). Release of free radicals, nitric oxide (NO) and substance P at the application site, along with inhibition of the enzyme COX II, produces an anti-inflammatory effect. In experiments on tissues subjected previously to shockwave therapy, analysis under a microscope has demonstrated intensely increased neovascularization and angiogenesis.

The present study was conducted with the aim of prospectively analyzing the results from shockwave treatment on patients with recalcitrant fasciopathy, using validated evaluation methods.

Materials and methods

Firstly, a research project was designed and submitted for assessment by the Scientific Committee of Hospital IFOR. This was duly approved.

This was a prospective study in which patients with chronic plantar fasciitis that had not responded satisfactorily to conservative therapeutic measures were evaluated. Traditional

methods such as analgesic and anti-inflammatory medications, physiotherapy and additional use of braces or insoles had been systematically applied.

The inclusion criteria were that the subjects should be patients of either sex in whom a diagnosis of plantar fasciitis had been made by means of clinical and imaging evaluations, with evolution of more than six months. Individuals with the following were not included: other concomitant conditions of the foot and ankle; comorbidities such as diabetes mellitus, neuropathies or insensitive foot; previous surgery; and non-acceptance of participation in the study after having read the free and informed consent statement.

Thus, we built up a group of 30 patients (36 feet), of whom 16 (53.3%) were male and 14 (47.7%) were female, with mean age of 48.37 years, ranging from 33 to 78 years. With regard to laterality, we observed that 16 patients (53.3%) presented the condition on their left foot and 14 (46.7%) on their right foot, and that bilaterality occurred in six situations (20%). The body mass index (BMI) ranged from 20.89 to 40.60 kg/m², with a mean of 28.48 kg/m². In our sample, the length of time with symptoms ranged from six to 60 months, with a mean of 13.58 months.

We performed radiographic examinations on the feet, with weight-bearing, on the side affected by the condition. We observed that out of the 30 patients evaluated, 16 (53.3%) presented plantar osteophytes in the calcaneus. The mean length of these osteophytes was 0.5 cm, from evaluating the radiographs on the feet.

The patients underwent one weekly session of shockwave therapy for four consecutive weeks. The apparatus used in the study was the Swiss Dolorcast®, made by the Swiss company EMS. A generator of radial type was used, and 2000 impulses were produced in each session, at a pressure of 0.18 mJ/mm². The application site for this therapy was the most painful point on the foot, which had been indicated by the patient. For this application, we developed a diagram composed of four quadrants (Fig. 1). The odd quadrants (1 and 3) corresponded to the proximal and distal medial plantar region and the even quadrants (2 and 4) to the proximal and distal lateral plantar region of the calcaneus. We observed that 17 patients (56.6%) indicated that quadrant number 3 was the most painful area, nine (30%) number 1, four (13.3%) number 2 and one (3.3%) number 4.

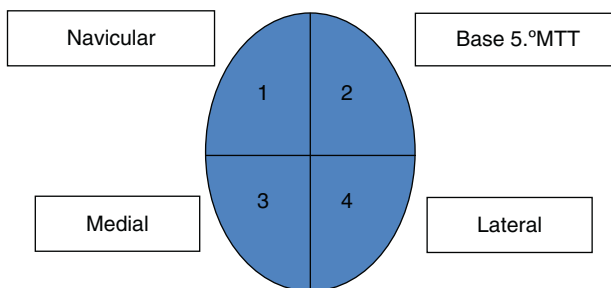


Fig. 1 – Diagram of the plantar region of the heel, divided into quadrants. Quadrant 1, distal medial plantar region; quadrant 2, distal lateral plantar region; quadrant 3, proximal medial plantar region; quadrant 4, proximal lateral plantar region.

Before
After: 1 month 3 months 6 months
1- Excellent (an excellent result without pain and with complete mobility)
2- Good (a good result with occasional pain)
3- Fair (a fair result with pain after activity)
4- Poor (a poor result with limitation on daily activities)

Fig. 2 – Roles & Maudsley evaluation.

For evaluating the results after the patients' treatment, we used the scale of the American Orthopaedic Foot and Ankle Society (AOFAS) (annex 1) for evaluating the ankle and hind-foot, and also the Roles & Maudsley score evaluation method (Fig. 2). These questionnaires were applied by a professional who had not administered the shockwave treatment.

The evaluations on the plantar fascia were performed by a single imaging diagnostics professional, using ultrasonography on the plantar region of the feet. The thickness of this anatomical structure was measured at four times: before the treatment and 30, 90 and 180 days after the treatment.

An ultrasound device with a high-frequency transducer (7–12 MHz) was used. A transversal measurement in millimeters was made on the plantar fascia, one centimeter from the point of greatest acoustic shadow, which corresponded to the calcaneal tubercle. The shockwave therapy was applied by a single professional.

The results obtained were compiled and analyzed statistically by a professional who was a specialist in this field.

Results

Table 1 demonstrates the descriptive results, which take into consideration the side affected by the condition, cases of bilaterality and the quadrants in which the shockwaves were applied.

Table 2 shows the thicknesses of the plantar fascia at the different evaluation times and the result from the statistical analysis. From analysis of variance with repeated measurements, we observed that there were significant changes in the ultrasonographic results ($p = 0.011$) between the different evaluation times. The examination performed in the first month differed from the examination in the third month ($p = 0.003$)

Table 1 – Absolute and relative frequencies of the variables.

Variable	Category	n	%
Side	R	14	48.4
	L	16	51.6
Quadrant	1	9	29.0
	2	3	12.9
	3	17	54.8
	4	1	3.2
Bilateral	No	24	77.4
	Yes	6	19.4

R, right; L, left.

Table 2 – Descriptive values from ultrasonography.

Time	n	Mean	SD	Minimum	Maximum
Before	17	0.68	0.36	0.30	2.00
1 month	17	0.64	0.19	0.38	1.10
3 months	17	0.60	0.20	0.33	1.10
6 months	17	0.57	0.18	0.28	0.97

SD, standard deviation.

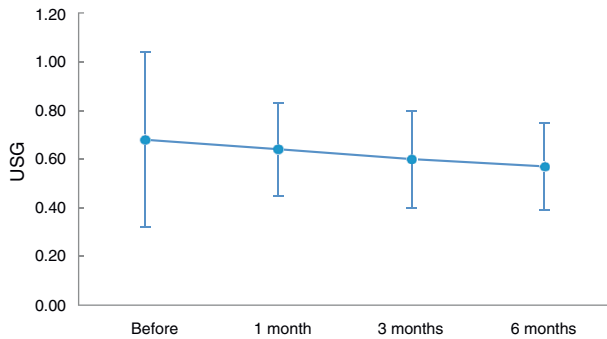


Fig. 3 – Graphical representation of the evolution of the ultrasonography (USG).

and sixth month ($p = 0.003$), with values that were significantly greater than in the other two.

Fig. 3 presents the evolution of the ultrasonographic thickness at the different times.

Table 3 shows the results from analysis of variance with repeated measurements, which indicate that there were significant changes in the results from the AOFAS scale over the course of the evaluations ($p < 0.001$). The time before the treatment presented a significant difference in relation to the other times (one month: $p < 0.001$; three months: $p < 0.001$; and six months: $p < 0.001$). The value before shockwave therapy was significantly lower than the values at the other times. There was a statistically significant difference between the first month evaluation and the other times (three months: $p < 0.001$; and six months: $p < 0.001$). In the first month, the results were significantly lower than in the third and sixth months of follow-up. The values obtained in the third month of evaluation were significantly greater than those presented in the sixth month of evaluation ($p < 0.001$).

Fig. 4 shows the results from the AOFAS scale at the different evaluation times.

Table 4 demonstrates the results from the statistical analysis on the Roles & Maudsley scale, using the Friedman

Table 3 – Descriptive values from AOFAS scale.

Time	n	Mean	SD	Minimum	Maximum
Before	30	58.87	14.26	36	83
1 month	30	68.20	9.97	44	84
3 months	30	78.23	13.53	44	97
6 months	30	82.83	17.14	36	100

SD, standard deviation.

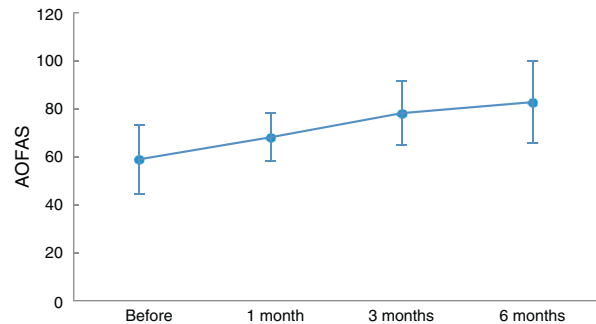


Fig. 4 – Graphical representation of the evolution of the AOFAS scale.

nonparametric test, and it shows that there were significant changes over the course of the evaluations ($p < 0.001$). The time before shockwave therapy did not present any statistically significant difference in relation to the first month of evolution ($p > 0.05$). There were differences in the third month ($p < 0.05$) and sixth month ($p < 0.05$), with significantly greater values at these two times. The results from the first month did not differ from the other times (three months: $p > 0.05$; and six months: $p > 0.05$). In addition, the results from the third month did not differ from those presented in the sixth month ($p > 0.05$).

Fig. 5 demonstrates the evolution of the results from the Roles & Maudsley scale at the different evaluation times.

Discussion

Use of shockwave therapy has been approved by the Food and Drug Administration (FDA), in the United States,¹⁴ and by the National Sanitary Surveillance Agency (Agência Nacional de Vigilância Sanitária, ANVISA), in Brazil.

The exact mechanism for the effect of shockwave therapy on conditions of the locomotor system still remains undefined.

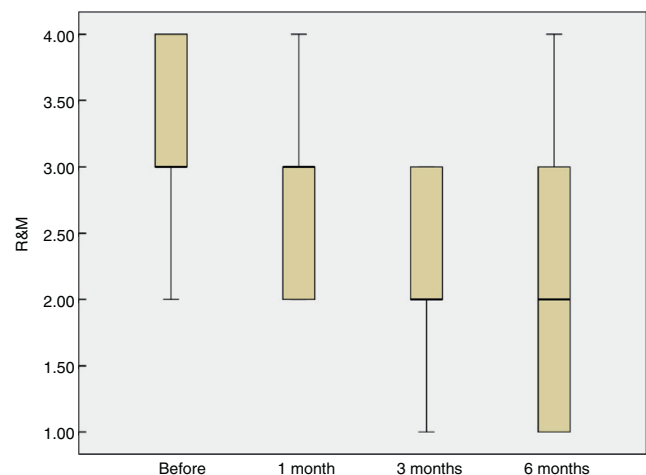


Fig. 5 – Graphical representation of the evolution of the Roles & Maudsley (R&M) scale.

Table 4 – Descriptive values from Roles & Maudsley scale.

Time	n	Mean	SD	Minimum	Maximum	P25	Median	P75
Before	30	3.28	0.59	2.00	4.00	3.00	3.00	4.00
1 month	30	2.79	0.56	2.00	4.00	2.00	3.00	3.00
3 months	30	2.31	0.76	1.00	3.00	2.00	2.00	3.00
6 months	30	2.14	1.19	1.00	4.00	1.00	2.00	3.50

SD, standard deviation.

It is believed that shockwaves promote a biological response in which several phenomena occur: neovascularization, release of proliferating cell nuclear antigen, endothelial growth factors, endothelial nitrous oxide¹⁵ (blocking of nerve impulses) and morphogenetic bone protein. These phenomena promote increased blood supply and bone and tendon repair. Local microtraumas provide stimulation and activation of the tissue healing process, which leads to activation of fibroblast proliferation and removal of calcareous deposits.¹⁶

The efficiency of shockwaves has been demonstrated in a variety of conditions of the locomotor system. Among these, pseudarthrosis can be highlighted, with a success rate of around 75%. Other indications include: bone necrosis, tendinosis (calcaneal), insertion enthesopathy, epicondylitis, bursitis and calcareous tendinitis of the shoulder.¹⁷

So far, in preliminary studies, the success rate regarding pain elimination shown by shockwave therapy has ranged from 48% to 81%.¹²

With regard to the benefit provided by shockwave therapy according to the time elapsed since application, we observed that progression of the success rates has been reported, as follows: 57% after three months,¹⁴ 48%¹⁸ to 83%¹² after six months, 58% after 12 months¹⁹ and 77.4% after 24 months.¹³

These results corroborate the data observed in our study, although we only made evaluations until the sixth month after application.

In the literature, a variety of benefits from using this therapeutic option have been indicated. Since this method is a nonoperative intervention, the potential complications inherent to surgery cease to exist. The recovery time is significantly shorter and the individual has the possibility of returning to his habitual activities on the day after application.²⁰ We also take the view that this resource could be used as a last possibility before indicating an invasive procedure. Success rates comparable with those of surgery and other conventional therapies have been demonstrated for shockwave therapy.^{8,21}

The following are contraindications against applying shockwave therapy: blood dyscrasia, use of anticoagulants, presence of tumors, presence of infectious process and children and adolescents when the growth plate is still open.

Regarding the functional aspect of walking, it was found in one study that 51% of the patients who underwent the treatment were capable of walking without pain six months later, in comparison with individuals who were not treated or who received placebo. After five years, 58% of the patients needed to undergo surgical release of their plantar fascia, while only 13% of the group treated with shockwave therapy required this action.²²

In another study in which the authors used the AOFAS scale to compare the results between two groups, no statistically

significant differences were found and the patients with chronic plantar fasciitis did not demonstrate any significant deficits of range of motion before or after the treatment.²³

In our study, when we used the AOFAS scale, we observed that there was a progressive improvement in the results between the different evaluation times (76.7%), as shown in Fig. 5.

Some studies have indicated that the ideal location for applying shockwaves would be the extremity of the calcaneus or the center of the spur of this bone structure, since this portion would correspond to the thickest part of the plantar fascia. However, others have considered that the ideal location for the application would be the point of origin of the pain.²⁴

In evaluating the exact location where the application is needed, we noted that some authors had compared the therapeutic results between determination of the application site by means of fluoroscopy and through the patient's own report. The result was that there was no significant difference in clinical evolution when different methods were used to identify the best location, and the success rates were considered to be excellent or good, according to the criteria of Roles & Maudsley, three months after the application.²⁴

Our results were similar when we used these criteria, with which we observed progressive improvement.

From the analysis on our material, we developed a diagram consisting of four quadrants, in which the region most often indicated as being painful was the posteromedial region, which corresponded to 54.8% of the areas of application. We consider that this methodology is reproducible and that it gave rise to favorable rates of good results.

Through this, it can be suggested that use of shockwave therapy should be considered to be a therapeutic option. Together with shockwave therapy, exercises should be done at home in order to stretch the posterior chain. Studies have demonstrated that the results obtained through concomitant use of shockwave therapy and stretching of the posterior chain are superior to those done separately.

In another study, magnetic resonance imaging was used to structurally evaluate the plantar fascia thickness among asymptomatic patients who had previously undergone open or endoscopic release of the plantar fascia. The thickness of this structure was two to three times greater than normal, despite complete resolution of the perifascial edema and plantar fasciitis.²⁵

In our study, we used ultrasonographic measurements that were systematized to be performed 30, 90 and 180 days after applying shockwave therapy. We observed a decrease in plantar fascia thickness in our patients, compared with the thickness before the start of the treatment. This was interpreted as a reduction in the inflammatory process and as

stretching of the plantar fascia, caused by the malleability and elasticity intrinsic to this structure.

Through this resource, we were unable to assess whether the heel spur had any influence on the distribution and absorption of shockwaves.

However, we emphasize that the high costs of magnetic resonance imaging may be diminished through using ultrasound.

From our study, we take the view that shockwave therapy can be considered to be an important instrument for primary or adjuvant treatment of chronic plantar fasciitis, when allied with conventional therapies. We consider that this methodology is safe and noninvasive, does not present significant complications and promotes rehabilitation and an early return to habitual activities.

In a society in which the pace of work is increasing alarmingly, few individuals are able to remain absent from work activities for prolonged periods. In this regard, shockwave therapy was shown to be an effective resource, through avoiding the need for a surgical procedure that would leave them off work for a long period. Another important factor to be considered is that surgical treatment implies high costs.

Conclusion

This study showed that there was a statistically significant decrease in the thickness of the plantar fascia in the patients who underwent shockwave therapy ($p = 0.011$).

According to the AOFAS scale for the hindfoot and the Roles & Maudsley scale, the patients in this study achieved statistically significant improvements in their scores ($p < 0.001$).

Conflicts of interest

The authors declare no conflicts of interest.

Appendix A.

AOFAS scale for clinical evaluation of the ankle and hindfoot

Parameter	
1. Pain (40 points)	
None	40
Mild, occasional	30
Moderate, every day	20
Severe, almost always present	0
2. Function (50 points)	
2.1. Limitation on activities and need for support	
No limitations; no supports	10
No limitations on activities, recreational limitations; no supports	7
Limitation on daily and recreational activities; use of stick	4
Significant limitation on daily activities; use of crutches, walking frame or wheelchair	0

2.2. Maximum walking distance (in blocks)	
More than 6	5
From 4 to 6	4
From 1 to 3	2
Less than 1	0
2.3. Walking surface	
No difficulty on any surface	5
Some difficulty on uneven ground, stairs or slopes	3
Severe difficulty on uneven ground, stairs or slopes	0
2.4. Gait abnormalities	
None or mild	8
Obvious	4
Severe	0
2.5. Sagittal mobility (flexion + extension)	
Normal or minimal limitation (30° or more)	8
Moderate limitation (15 to 29°)	4
Severe limitation (less than 15°)	0
2.6. Mobility of hindfoot (inversion and eversion)	
Normal or mild limitation (75 to 100%)	6
Moderate limitation (25 to 74%)	3
Severe limitation (less than 25%)	0
2.7. Stability of ankle and hindfoot (anteroposterior + varus-valgus)	
Stable	8
Unstable	0
3. Alignment (10 points)	
Good – plantigrade foot with ankle and hindfoot aligned	10
Fair – plantigrade foot with some misalignment and without pain	5
Poor – non-plantigrade foot with significant misalignment and symptoms	0

REFERENCES

- Jarde O, Diebold P, Havet E, Boulu G, Vernois J. Degenerative lesions of the plantar fascia: surgical treatment by fasciectomy and excision of the heel spur: a report on 38 cases. *Acta Orthop Belg.* 2003;69(3):267-74.
- Leach RE, Seavey MS, Salter DK. Results of surgery in athletes with plantar fasciitis. *Foot Ankle.* 1986;7(3):156-61.
- Lemont H, Ammirati KM, Usen N. Plantar fasciitis: a degenerative process (fasciosis) without inflammation. *J Am Podiatr Med Assoc.* 2003;93(3):234-7.
- Gill LH. Plantar fasciitis: diagnosis and conservative management. *J Am Acad Orthop Surg.* 1997;5(2):109-17.
- Schepers AA, Leach RE, Gorzyca J. Plantar fasciitis. Etiology, treatment, surgical results, and review of the literature. *Clin Orthop Relat Res.* 1991;(266):85-96.
- Pfeffer G, Bacchetti P, Deland J, Lewis A, Anderson R, Davis W, et al. Comparison of custom and prefabricated orthoses in the initial treatment of proximal plantar fasciitis. *Foot Ankle Int.* 1999;20(4):214-21.

7. Furey JG. Plantar fasciitis: the painful heel syndrome. *J Bone Joint Surg Am.* 1975;57(5):672-3.
8. Martin RL, Irrgang MS, Conti SF. Outcome study of subjects with insertional plantar fasciitis. *Foot Ankle Int.* 1998;19(12):803-11.
9. Shikoff MD, Figura MA, Postar SE. A retrospective study of 195 patients with heel pain. *J Am Podiatr Med Assoc.* 1986;76:71-5.
10. Wolgin M, Cook C, Graham C, Mauldin D. Conservative treatment of plantar heel pain: long-term follow-up. *Foot Ankle Int.* 1994;15(3):97-102.
11. Barrett SL, Day SV, Pignetti TT, Robinson LB. Endoscopic plantar fasciotomy: a multi-surgeon prospective analysis of 652 cases. *J Foot Ankle Surg.* 1995;34(4):400-6.
12. Hammer DS, Rupp S, Kreutz A, Pape D, Kohn D, Seil R. Extracorporeal shockwave therapy (ESWT) in patients with chronic proximal plantar fasciitis. *Foot Ankle Int.* 2002;23(4):309-13.
13. Rompe JD, Hopf C, Nafe B, Burger R. Low-energy extracorporeal shock wave therapy for painful heel: a prospective controlled single-blind study. *Arch Orthop Trauma Surg.* 1996;115(2):75-9.
14. Ogden JA, Alvarez R, Levitt R, Lee Cross GL, Marlow M. Shock wave therapy for chronic proximal plantar fasciitis. *Clin Orthop Relat Res.* 2001;387:47-59.
15. Thiel M. Application of shock waves in medicine. *Clin Orthop Relat Res.* 2001;387:18-21.
16. Kaya BK. Plantar fasciitis in athletes. *J Sport Rehabil.* 1996;5(4):305-20.
17. Benton-Weil W, Borrelli AH, Weil Jr LS, Weil Sr LS. Percutaneous plantar fasciectomy: a minimally invasive procedure for recalcitrant plantar fasciitis. *J Foot Ankle Surg.* 1998;37(4):269-72.
18. Rompe JD, Kullmer K, Eysel P, Riehle HM, Burger R, Nafe B. Niedrigenergetische extrakorporale Stobwellentherapie (ESWT) beim plantaren fersensporn. *Orthop Praxis.* 1996;32(4):271-5.
19. Krischek O, Rompe JD, Herbsthofner B, Nafe B. Symptomatische niedrig-energetische Stobwellentherapie bei Fersenschmerzen und radiologisch nachweisbarem plantaren Fersen- sporn. *Z Orthop.* 1998;136:169-74.
20. Ogden JA, Alvarez RG, Marlow M. Shockwave therapy for chronic plantar fasciitis: a meta-analysis. *Foot Ankle Int.* 2002;23(4):301-8.
21. Davies MS, Weiss GA, Saxby TS. Plantar fasciitis: how successful is surgical intervention? *Foot Ankle Int.* 1999;20(12):803-7.
22. League AC. Current concepts review: plantar fasciitis. *Foot Ankle Int.* 2008;29(3):358-66.
23. Theodore GH, Matthias B, Amendola A, Bachmann C, Fleming LL, Zingas C. Extracorporeal shock wave therapy for the treatment of plantar fasciitis. *Foot Ankle Int.* 2004;25(5):290-7.
24. Dorotka R, Sabeti M, Jimenez-Boj E, Goll A, Schubert S, Trieb K. Location modalities for focused extracorporeal shock wave application in the treatment of chronic plantar fasciitis. *Foot Ankle Int.* 2006;27(11):943-7.
25. Wang C-J, Chen H-S, Huang T-W. Shockwave therapy for patients with plantar fasciitis: a one-year follow-up study. *Foot Ankle Int.* 2002;23(3):204-7.