



Update Article

Current possibilities for hip arthroplasty^{☆,☆☆}



Giancarlo Cavalli Polesello*, Rodrigo Pereira Guimarães, Walter Ricioli Júnior, Nelson Keiske Ono, Emerson Kiyoshi Honda, Marcelo Cavalheiro de Queiroz

Faculdade de Ciências Médicas da Santa Casa de São Paulo, São Paulo, SP, Brazil

ARTICLE INFO

Article history:

Received 16 June 2013

Accepted 21 June 2013

Available online 3 April 2014

Keywords:

Hip joint/surgery

Arthroscopy

Hip injuries

ABSTRACT

Hip arthroscopy has been popularized over the last decade and, with technical advances regarding imaging diagnostics, understanding of the physiopathology or surgical techniques, several applications have been described. Both arthroscopy for intra-articular conditions and endoscopy for extra-articular procedures can be used in diagnosing or treating different conditions. This updated article has the objective of presenting the various current possibilities for hip arthroscopy.

© 2014 Sociedade Brasileira de Ortopedia e Traumatologia. Published by Elsevier Editora Ltda. All rights reserved.

Possibilidades atuais da artroscopia do quadril

R E S U M O

A artroscopia de quadril tem sido popularizada na última década e com o avanço técnico, seja no diagnóstico por imagem, no entendimento da fisiopatologia ou na técnica cirúrgica, diversas aplicações foram descritas. Tanto a artroscopia, para afecções intra-articulares, como a endoscopia, para procedimentos extra-articulares, podem ser usadas no diagnóstico ou no tratamento de diferentes afecções. Este artigo de atualização tem como objetivo apresentar diversas possibilidades atuais da artroscopia de quadril.

© 2014 Sociedade Brasileira de Ortopedia e Traumatologia. Publicado por Elsevier Editora Ltda. Todos os direitos reservados.

Palavras-chave:

Articulação do quadril/cirurgia

Artroscopia

Lesões do quadril

Introduction

Hip arthroscopy has become popular over the past decade and, with technical advances in imaging diagnostics,¹ in understanding the physiopathology or in surgical techniques, several applications have been described.^{2,3} It was first described by Burman in 1931 (in Byrd et al.⁴), who considered

that the capacity of this technique for enabling viewing was extremely limited and that this method was potentially iatrogenic. During the 1980s and 1990s, there were developments in traction techniques that facilitated access to the central compartment.^{5,6} Since then, better understanding of the arthroscopic anatomy of the peripheral compartment and use of arthroscopy without traction have provided an environment that is favorable toward wide-ranging joint exploration.⁷ Once

* Please cite this article as: Polesello GC, Pereira Guimarães R, Ricioli Júnior W, Keiske Ono N, Kiyoshi Honda E, Cavalheiro de Queiroz M. Possibilidades atuais da artroscopia do quadril. Rev Bras Ortop. 2014;49:103-110.

☆☆ Work performed in the Hip Group, Department of Orthopedics and Traumatology, School of Medical Sciences, Santa Casa de São Paulo, São Paulo, SP, Brazil.

* Corresponding author.

E-mail: giancarlopolesello@hotmail.com (G.C. Polesello).

2255-4971/\$ – see front matter © 2014 Sociedade Brasileira de Ortopedia e Traumatologia. Published by Elsevier Editora Ltda. All rights reserved. <http://dx.doi.org/10.1016/j.rboe.2014.03.021>

the understanding of the arthroscopic anatomy of these compartments had become well established, there was a natural expansion of endoscopic exploration to other compartments around the hip, such as the peritrochanteric, subgluteal and medial spaces of the hip.⁸⁻¹⁰

The arthroscopic anatomy is already well known.¹¹ Multiple portals are possible and are well defined with regard to their safety,¹² as is the anatomical technique in relation to preservation of the vascularization of the femoral neck.^{13,14}

Indications

Lesions of the acetabular labrum

This is one of the commonest indications.¹⁵ The labrum functions as a joint seal, helps in producing and enabling circulation of the synovial fluid and allows continual lubrication of the joint.¹⁶ In addition to its proprioceptive function, it adds stability to the joint because of the vacuum phenomenon, deepens the hip joint, provides greater uniformity of pressure distribution and increases the contact surface between the femoral head and the acetabulum by 22%.^{17,18}

Lesions of the acetabular labrum may occur due to direct trauma during sports activities. In fact, these lesions rarely occur in the absence of morphological alterations to bones.¹⁹ Thus, the arthroscopic results from labral debridement alone, without treating the underlying bone dysmorphism, are unsatisfactory.²⁰ In most cases, femoroacetabular impingement (FAI) makes the acetabular labrum the first structure to fail.²¹

These lesions may compromise the load absorption and stabilization function of the acetabular labrum and may lead to arthrosis, as also found with meniscal lesions.²² Finite element studies^{16,17} have demonstrated that if the sealant function of the labrum is compromised, the mechanical demands on the underlying cartilage are increased, along with shearing forces, which may contribute toward causing injury due to cartilage fatigue and subsequent arthrosis.²³

In addition to FAI, labral lesions may occur due to repetitive microtrauma, of either high or low-energy nature, especially through hip torsion mechanisms. Repetitive activities, whether in sports or not, which force the hip beyond the habitual range of motion, especially into hyperflexion of the hip, may cause injuries. These mechanisms may include activities such as performing leg press exercises, ballet, yoga, spinning exercise, other gym activities, dancing, working in a squatting position and others.²⁴⁻²⁸

The clinical condition generally consists of anterior pain in the hip, which may irradiate to the groin, trochanteric region or posterior region of the hip. One frequent clinical sign is the "C" sign, in which the patient points out the location of the pain in his hip with his hand in a "C" shape, in transverse orientation over the hip and trochanteric region, which denotes pain of intra-articular origin.²⁹

In the treatment, the major objective is to preserve as much of the viable tissue as possible, with selective debridement, reinsertion or labral reconstruction. Studies comparing clinical results from debridement versus labral repair have demonstrated that the best results are obtained through repair.^{30,31} Evidence that labral reconstruction, using either

autologous or homologous tissue, may present good results in patients with previous labral resection, ossified labra or hypotrophic labra has also started to appear.³²⁻³⁴

Femoroacetabular impingement (FAI)

Ganz recognized that FAI could lead to development of labral lesions and early arthrosis in non-dysplastic hips.^{35,36} This concept is dynamic, based on movement more than axial loading of the hip. It may result from morphological abnormalities that affect the acetabulum and proximal femur, or it may occur in patients who subject their hips to extreme and supraphysiological ranges of motion. Depending on the underlying cause, FAI may result in lesions of the labrum and acetabular cartilage.³⁷ After the injury has occurred, synovial fluid starts to circulate through the lesion, in a continuous valvular mechanism. If the low potential for healing in the intra-articular environment is added to this, these hydrodynamic alterations and the bone dysmorphism will perpetuate the acetabular chondral lesion and its delamination of the subchondral bone, until the compensatory mechanisms cease to operate, which leads to arthrosis.

Two distinct types of femoroacetabular impingement have been identified,³⁵ and they are frequently combined.³⁸ The first type is characterized by linear impingement of the acetabular rim against the femoral head-neck junction, because of local acetabular supercoverage (e.g. acetabular retroversion) or overall supercoverage (e.g. deep thigh or acetabular protrusion), called a pincer or a pinching effect. The second type occurs with compression of the non-spherical extension of the femoral head into the acetabular cavity, which is called Cam.

Changes to the femoral and acetabular anatomical format may also result from childhood diseases such as Legg-Calvé-Perthes, epiphysiolysis, changes in inclination and acetabular or femoral version.³⁹

In relation to the clinical condition, patients complain of anterior and lateral pain in the hip. In the anterior impingement test, which is done with maximum internal rotation and 90° of passive flexion of the hip, diminished internal rotation of the hip and associated pain are observed. Flexion and adduction of the hip lead to conflict between the femoral neck and the acetabular rim. Internal rotation and associated adduction cause shearing forces in the acetabular labrum, similar to those in the menisci of the knees, and stimulate the nerve ends. This causes acute inguinal pain in patients with a torn or degenerated labrum²¹ (Fig. 1).

The arthroscopic treatment for femoroacetabular impingement consists of elimination of the bone conflict and correction of the deformities, both on the acetabular side and on the femoral side, along with treatment of lesions of the chondrolabral complex by means of osteoplasty of the proximal femur, osteoplasty of the acetabular supercoverage and refixation, reconstruction or labral debridement and treatment of the chondral lesions.^{40,41}

Pyoarthritis

Early surgical intervention is essential for obtaining good results from treating septic arthritis of the hip. Arthroscopy has advantages, such as smaller incisions, shorter recovery

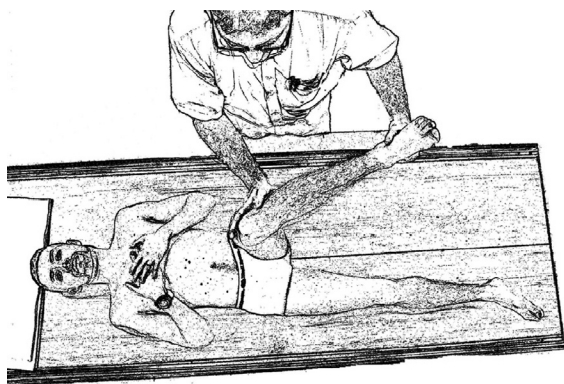


Fig. 1 – Appearance of the impingement test in the physical examination of the hip, which is done with the hip flexed at 90°, internal rotation and adduction.

time, better viewing and effective irrigation of the joint, the possibility of implanting continuous irrigation catheters, the possibility of collecting material for culturing and anatomopathological examination, and minimal morbidity.⁴²⁻⁴⁷ Although there have been few studies on arthroscopic treatment of pyoarthritis in adults, good results have been obtained provided that the intervention was early.^{48,49} Among children, some comparative studies have demonstrated the superiority of arthroscopic drainage over open drainage. The possibility of drainage of acute infection also exists with total hip arthroplasty.⁵⁰

Arthrosis

There is some controversy regarding use of arthroscopy on the hip in the presence of osteoarthritis. The results from treating FAI in the presence of advanced arthrosis, with loss of joint space, are not good.^{51,52} On the other hand, McCarthy and Lee⁵³ described good results from debridement of osteophytes and degenerated labra in cases of arthrosis in the initial stage, i.e. without loss of joint space on simple radiographs (Tönnis classification type 0 and 1).⁵⁴ Joint pinching greater than 50% compared with the contralateral side, or less than 2 mm of joint space remaining, along with limited range of motion,⁴¹ is a poor prognostic factor.⁵¹

In the light of poor results and high rates of conversion to hip arthroplasty within a three-year period, treatment for hips with arthrosis should have very restricted indications.^{55,56}

Free bodies

Hip arthroscopy is an excellent tool for removing free bodies from the hip joints, which could be bone or osteochondral fragments resulting from hip dislocation, firearm projectiles, synovial chondromatosis, broken guidewires or other types of foreign bodies of joints,⁵⁷⁻⁶⁴ thus enabling effective and complete removal of the free bodies, synovectomy and rapid rehabilitation⁶⁴⁻⁶⁹ (Fig. 2).

Tumors and other conditions

Hip arthroscopy can be used in selected cases. It is also an option for treating pigmented villonodular synovitis, synovial chondromatosis and osteoid osteoma of the hip.^{64,70-73}

Impingement of the tendon of the iliopsoas muscle/internal prominence

Compression of the tendon of the iliopsoas muscle in the anterior capsule of the hip and consequently in the acetabular labrum may cause labral lesions in the anteromedial region and even bone deformity in the femoral head, which is atypical (Fig. 3).

Audible and/or palpable internal prominences may be associated with the anterior region of the hip. For selected patients, debridement or labral repair together with tenotomy of the psoas may produce good results in patients without any improvement through conservative treatment. Internal prominences are characterized by prominence of the tendon of the iliopsoas over the iliopectineal eminence. In the absence of improvement through conservative treatment, tenotomy of the psoas can be performed, either as an intracapsular procedure or at the level of the lesser trochanter, with satisfactory results.^{74,75}

Dysplasia

Patients with dysplasia generally have hypertrophy of the acetabular labrum due to shearing of the femoral head, caused by lack of acetabular coverage. This shearing gives rise to excessive mechanical demands at the chondrolabral transition and myxoid degeneration of the acetabular labrum and/or deinsertion at the acetabular rim.⁷⁶

Some care should be taken in indicating arthroscopy for a dysplastic hip. Capsulotomy and labral disorder may result in

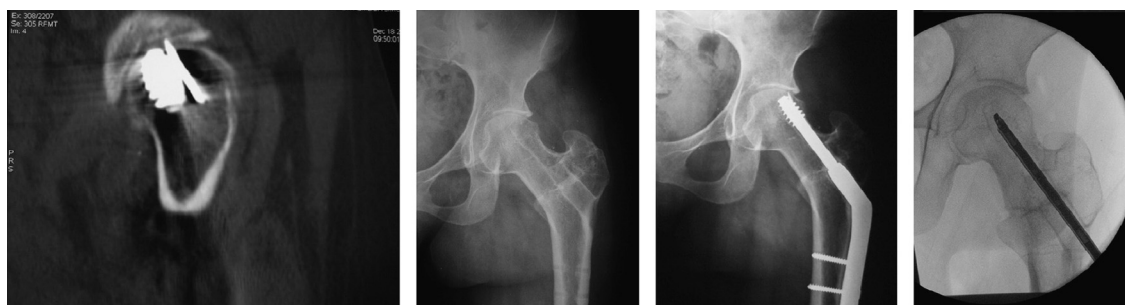


Fig. 2 – Example of a broken guidewire. Arthroscopy can be used to remove the wire.

progression of the arthrosis, worsening of the pain and joint instability. In cases of dysplasia with a Wiberg center-edge angle⁷⁷ >20°, arthroscopy can be used for repairing the labral lesion. In cases of angles smaller than 20°, arthroscopy is contraindicated and can be used as a coadjuvant for labral repair, during or after treatment aimed at correcting the acetabular coverage.⁷⁸

Chondral lesions

Chondral lesions of the hip may be acute, chronic or degenerative, with partial or full depth. They may result from repetitive trauma, direct trauma, FAI, dysplasia or osteonecrosis of the femoral head.³⁸

There are several options for arthroscopic treatment. Among these are microfracturing, debridement through abrasion, osteochondral autologous transplantation (mosaicplasty or osteochondral autologous transfer system, OATS), autologous transplantation of chondrocytes, autologous chondrogenesis induced by matrix, fresh osteochondral transplantation and osteochondroplasty of peripheral lesions of the acetabular rim.⁷⁹⁻⁸² The long-term results and superiority of one method over the others have not yet been established.⁸³ It is important to emphasize that the indication for arthroscopy in cases of osteonecrosis may be to evaluate chondral and labral lesions and assist in surgery and staging, and not as specific therapy through this method. Its indication should be limited.^{84,85}

Synovectomy and joint biopsy

Hip arthroscopy can be used for synovectomy and synovial biopsies, and it is frequently indicated in cases of rheumatological conditions and done on an outpatient basis.^{65,86}

Instability

Traumatic

Hip instability may result from low-energy trauma with subluxation of the hip, or comprise dislocation due to high-energy trauma. Removal of free bodies is the main indication,⁸⁷ but arthroscopy can also be used for treating chondral and labral lesions.⁸⁸

Non-traumatic

Hip instability may result from capsule-ligament laxity and consequent injury of the chondrolabral or osteochondral complex of the acetabulum. Patients who have diseases of the connective tissue, such as Ehlers-Danlos disease or idiopathic capsule-ligament laxity, or who perform activities that require range of motion greater than what is physiologically normal, such as ballet dancers, may develop symptomatic hip instability.⁸⁹⁻⁹¹

The clinical picture generally comprises anterior and/or posterior hip pain, which may be associated with mechanical symptoms and a sensation of being "out of place". Excessive external rotation of the hip when in dorsal decubitus, and other signs of extreme laxity may be present, with or without associated pain.⁹²

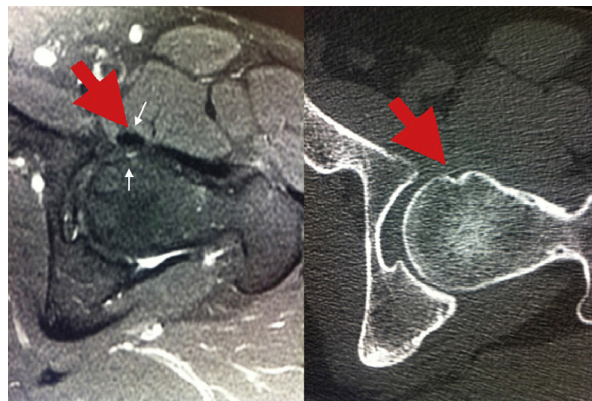


Fig. 3 – Note the appearance of the tendon of the iliopsoas muscle on magnetic resonance imaging and the bone deformation caused to the femoral head, seen on tomography.

The arthroscopic treatment consists of repairing the lesion of the chondrolabral or osteochondral complex. There is the possibility of tensioning by means of sutures or by using radio frequencies on the anterior capsule, with the aim of diminishing the anterior instability.⁸⁹

Aid for treating hip fractures

It can be used as an aid for fixing fractures of the acetabulum and femoral head.⁹³⁻⁹⁶ It is a tool for viewing the reduction, analyzing screw penetration and removing free bodies.

Injuries of the round ligament

The round ligament is a potential cause of hip pain.⁹⁷ It may become torn through traumatic causes or instability.⁹⁸ Arthroscopic debridement may lead to pain relief.⁹⁹ The possibility of reconstruction using a graft is described in the literature,¹⁰⁰ but the long-term results are unknown.

Post-arthroplasty

Cases of persistent pain subsequent to arthroplasty can be investigated and/or treated by means of arthroscopy. The indications include: tendinitis of the tendon of the iliopsoas muscle due to impingement at the edge of the acetabular component, acute prosthetic infection, investigation of breakage or loosening of the polyethylene, pseudotumors, corrosion at the head-neck junction of the prosthesis and instability.^{50,101-107}

Peritrochanteric space

Extra-articular endoscopy has evolved over recent years, especially through studies on conditions that cause trochanteric pain syndrome and deep gluteal pain syndrome.⁸

Deep gluteal pain

Patients with deep gluteal pain generally have a history of trauma in this region and complaints of pain while seated, sciatic pain and paresthesia of the affected limb due to compression of the sciatic nerve proximally or distally to the

gluteal region. Piriform syndrome can be considered to be one of the causes of deep gluteal pain.^{108,109} Arthroscopic neurectomy of the sciatic nerve has been described in cases of failure of conservative treatment, with good results.^{10,110}

Trochanteric pain syndrome

Trochanteric pain syndrome is the term used to describe chronic pain in the lateral region of the hip. There are several causal factors, such as injuries of the tendon of the gluteus medius and minimus muscles, trochanteric bursitis and external snapping.

Injuries of the gluteus medius and minimus

Injuries to the gluteus medius and minimus are analogous to injuries of the rotator cuff of the shoulder, which are both associated with advanced age and degenerative alterations of the tendons.^{111,112} The clinical condition generally consists of lateral pain in the hip that does not respond to conservative treatment and may be associated with weakness of the abductors and a positive Trendelenburg sign. If conservative treatment fails, endoscopic repair of the tendons affected can be performed.^{113,114}

Lateral (external) snapping

External snapping is defined as an audible or palpable snapping sensation in the trochanteric region during flexion and extension of the hip, commonly observed among long-distance runners. It occurs when the posterior part of the iliotibial band or the anterior part of the tendon of the gluteus maximus slides over the trochanter during hip flexion. When the hip is then extended, these structures may collide against the greater trochanter and cause audible, palpable and painful snapping. If conservative treatment fails, endoscopic treatment can be performed with the objective of diminishing the tension of these structures above the greater trochanter. Ilizaliturri et al.¹¹⁵ described creation of a defect in the iliotibial band above the greater trochanter, with 90% resolution of the snapping and pain. Polesello et al.¹¹⁶ described endoscopic tenotomy of the gluteus maximus, with 88% resolution of the snapping and lateral pain.

Bursectomy

The clinical picture of trochanteric bursitis comprises chronic pain over the lateral region of the greater trochanter. Pain on palpation is characteristic. In cases that are refractory to conservative treatment, endoscopic bursectomy can be performed.¹¹⁷⁻¹²⁰ It is important to emphasize that the diagnosis of trochanteric bursitis needs to have special attention, given that because of lack of knowledge of the differential diagnoses, other causes of pain in the region may go unnoticed.^{8,121}

Hamstring tendons

Hamstring injuries may range from muscle distension to complete avulsion. Different open techniques for reinsertion have been described, although the possibility of arthroscopic rein-

sertion also exists.^{122,123} It has been reported that early repair has better results than late repair, especially among high-performance athletes.¹²⁴

Adjuvant in femoral or periacetabular osteotomy for dysplasia and complex deformities of the hip

There is a discussion in the literature regarding the indications for hip arthroscopy before or after osteotomy, especially in relation to Ganz's periacetabular osteotomy. Those who advocate arthroscopy state that associated treatment for joint lesions would be beneficial.^{125,126} On the other hand, it has been observed that a large proportion of the patients who undergo periacetabular osteotomy remain asymptomatic after the operation, without the need for any new intervention.^{126,127}

Children

Hip arthroscopy for children has gained prominent space over recent years.^{39,128-131} Its indications include: investigation of the pediatric hip; biopsy; joint cleaning; septic arthritis⁴³; hip dysplasia, which could be for the purposes of joint cleaning to facilitate reduction, assisting in pelvic osteotomy, exploring joint incongruence, performing debridement of the labrum and cartilage fragments, or releasing fibrosis after the operation; Legg-Calvé-Perthes disease, for removal of free bodies, synovectomy, debridement of the round ligament, labrum or cartilage fragments and treatment of femoroacetabular impingement; tenotomy of the iliopsoas; epiphysiolytic, to treat FAI or aid in removing broken screws⁵⁹; and trapezoidal osteotomy of the femoral neck.¹³²

Conflicts of interest

The authors declare that there were no conflicts of interest.

Acknowledgements

The authors thank Dr. Sheila Ingham, for help in revising the text.

REFERENCES

1. Polesello GC, Nakao TS, Queiroz MCd, Daniachi D, Ricioli Junior W, Guimarães RP, et al. Proposta de padronização do estudo radiográfico do quadril e da pelve. *Rev Bras Ortop.* 2011;46(6):634-42.
2. Lynch TS, Terry MA, Bedi A, Kelly BT. Hip arthroscopic surgery: patient evaluation, current indications, and outcomes. *Am J Sports Med.* 2013;41(5):1174-89.
3. Bedi A, Kelly BT, Khanduja V. Arthroscopic hip preservation surgery: current concepts and perspective. *Bone Joint J.* 2013;95-B(1):10-9.
4. Byrd JW. Hip arthroscopy utilizing the supine position. *Arthroscopy.* 1994;10(3):275-80.
5. Glick JM, Sampson TG, Gordon RB, Behr JT, Schmidt E. Hip arthroscopy by the lateral approach. *Arthroscopy.* 1987;3(1):4-12.

6. Byrd JW, Chern KY. Traction versus distension for distraction of the joint during hip arthroscopy. *Arthroscopy*. 1997;13(3):346-9.
7. Dienst M, Gödde S, Seil R, Hammer D, Kohn D. Hip arthroscopy without traction: in vivo anatomy of the peripheral hip joint cavity. *Arthroscopy*. 2001;17(9):924-31.
8. Verhelst L, Guevara V, De Schepper J, Van Melkebeek J, Pattyn C, Audenaert EA. Extra-articular hip endoscopy: a review of the literature. *Bone Joint Res*. 2012;1(12):324-32.
9. Griffiths EJ, Khanduja V. Hip arthroscopy: evolution, current practice and future developments. *Int Orthop*. 2012;36(6):1115-21.
10. Martin HD, Shears SA, Johnson JC, Smathers AM, Palmer JJ. The endoscopic treatment of sciatic nerve entrapment/deep gluteal syndrome. *Arthroscopy*. 2011;27(2):172-81.
11. Dvorak M, Duncan CP, Day B. Arthroscopic anatomy of the hip. *Arthroscopy*. 1990;6(4):264-73.
12. Robertson WJ, Kelly BT. The safe zone for hip arthroscopy: a cadaveric assessment of central, peripheral, and lateral compartment portal placement. *Arthroscopy*. 2008;24(9):1019-26.
13. Sussmann PS, Ranawat AS, Shehaan M, Lorich D, Padgett DE, Kelly BT. Vascular preservation during arthroscopic osteoplasty of the femoral head-neck junction: a cadaveric investigation. *Arthroscopy*. 2007;23(7):738-43.
14. Gautier E, Ganz K, Krügel N, Gill T, Ganz R. Anatomy of the medial femoral circumflex artery and its surgical implications. *J Bone Joint Surg Br*. 2000;82(5):679-83.
15. Kelly BT, Weiland DE, Schenker ML, Philippon MJ. Arthroscopic labral repair in the hip: surgical technique and review of the literature. *Arthroscopy*. 2005;21(12):1496-504.
16. Ferguson SJ, Bryant JT, Ganz R, Ito K. An in vitro investigation of the acetabular labral seal in hip joint mechanics. *J Biomech*. 2003;36(2):171-8.
17. Ferguson SJ, Bryant JT, Ganz R, Ito K. The influence of the acetabular labrum on hip joint cartilage consolidation: a poroelastic finite element model. *J Biomech*. 2000;33(8):953-60.
18. Kim YT, Azuma H. The nerve endings of the acetabular labrum. *Clin Orthop Relat Res*. 1995;(320):176-81.
19. Wenger DE, Kendall KR, Miner MR, Trousdale RT. Acetabular labral tears rarely occur in the absence of bony abnormalities. *Clin Orthop Relat Res*. 2004;(426):145-50.
20. Kim KC, Hwang DS, Lee CH, Kwon ST. Influence of femoroacetabular impingement on results of hip arthroscopy in patients with early osteoarthritis. *Clin Orthop Relat Res*. 2007;456:128-32.
21. Ito K, Leunig M, Ganz R. Histopathologic features of the acetabular labrum in femoroacetabular impingement. *Clin Orthop Relat Res*. 2004;(429):262-71.
22. Ikeda T, Awaya G, Suzuki S, Okada Y, Tada H. Torn acetabular labrum in young patients. Arthroscopic diagnosis and management. *J Bone Joint Surg Br*. 1988;70(1):13-6.
23. McCarthy JC, Noble PC, Schuck MR, Wright J, Lee J, The Otto E, Aufranc award: the role of labral lesions to development of early degenerative hip disease. *Clin Orthop Relat Res*. 2001;(393):25-37.
24. Polesello GC, Cinagawa EHT, Cruz PDSS, Queiroz MCd, Borges CJ, Ricioli Junior W, et al. Tratamento cirúrgico para impacto femoroacetabular em um grupo que realiza agachamento. *Rev Bras Ortop*. 2012;47(4):488-92.
25. Polesello GC, Ono NK, Bellan DG, Honda EK, Guimarães RP, Riccioli Junior W, et al. Artroscopia do quadril em atletas. *Rev Bras Ortop*. 2009;44(1):26-31.
26. Polesello GC, Queiroz MC, Ono NK, Honda EK, Guimarães RP, Riccioli Junior W. Tratamento artroscópico do impacto femoroacetabular. *Rev Bras Ortop*. 2009;44(3):230-8.
27. Byrd JW, Jones KS. Arthroscopic management of femoroacetabular impingement in athletes. *Am J Sports Med*. 2011;39 Suppl.:7S-13S.
28. Byrd JW, Jones KS. Hip arthroscopy in athletes: 10-year follow-up. *Am J Sports Med*. 2009;37(11):2140-3.
29. Domb BG, Brooks AG, Byrd JW. Clinical examination of the hip joint in athletes. *J Sport Rehabil*. 2009;18(1):3-23.
30. Larson CM, Giveans MR. Arthroscopic debridement versus refixation of the acetabular labrum associated with femoroacetabular impingement. *Arthroscopy*. 2009;25(4):369-76.
31. Larson CM, Giveans MR, Stone RM. Arthroscopic debridement versus refixation of the acetabular labrum associated with femoroacetabular impingement: mean 3.5-year follow-up. *Am J Sports Med*. 2012;40(5):1015-21.
32. Matsuda DK, Burchette RJ. Arthroscopic hip labral reconstruction with a gracilis autograft versus labral refixation: 2-year minimum outcomes. *Am J Sports Med*. 2013;41(5):980-7.
33. Sierra RJ, Trousdale RT. Labral reconstruction using the ligamentum teres capitis: report of a new technique. *Clin Orthop Relat Res*. 2009;467(3):753-9.
34. Philippon MJ, Briggs KK, Hay CJ, Kuppersmith DA, Dewing CB, Huang MJ. Arthroscopic labral reconstruction in the hip using iliotibial band autograft: technique and early outcomes. *Arthroscopy*. 2010;26(6):750-6.
35. Ganz R, Parvizi J, Beck M, Leunig M, Nötzli H, Siebenrock KA. Femoroacetabular impingement: a cause for osteoarthritis of the hip. *Clin Orthop Relat Res*. 2003;(417):112-20.
36. Ganz R, Leunig M, Leunig-Ganz K, Harris WH. The etiology of osteoarthritis of the hip: an integrated mechanical concept. *Clin Orthop Relat Res*. 2008;466(2):264-72.
37. Bedi A, Kelly BT. Femoroacetabular impingement. *J Bone Joint Surg Am*. 2013;95(1):82-92.
38. Beck M, Kalhor M, Leunig M, Ganz R. Hip morphology influences the pattern of damage to the acetabular cartilage: femoroacetabular impingement as a cause of early osteoarthritis of the hip. *J Bone Joint Surg Br*. 2005;87(7):1012-8.
39. Kocher MS, Kim YJ, Millis MB, Mandiga R, Siparsky P, Micheli LJ, Kasser JR. Hip arthroscopy in children and adolescents. *J Pediatr Orthop*. 2005;25(5):680-6.
40. Philippon MJ, Schenker ML. Arthroscopy for the treatment of femoroacetabular impingement in the athlete. *Clin Sports Med*. 2006;25(2):299-308.
41. Sampson TG. Arthroscopic treatment of femoroacetabular impingement: a proposed technique with clinical experience. *Instr Course Lect*. 2006;55:337-46.
42. El-Sayed AM. Response to Uri Givon Treatment of early septic arthritis of the hip in children: comparison of results of open arthrotomy versus arthroscopic drainage. *J Child Orthop*. 2008;2(6):497.
43. Chung WK, Slater GL, Bates EH. Treatment of septic arthritis of the hip by arthroscopic lavage. *J Pediatr Orthop*. 1993;13(4):444-6.
44. Kim SJ, Choi NH, Ko SH, Linton JA, Park HW. Arthroscopic treatment of septic arthritis of the hip. *Clin Orthop Relat Res*. 2003;(407):211-4.
45. Nusem I, Jabur MK, Playford EG. Arthroscopic treatment of septic arthritis of the hip. *Arthroscopy*. 2006;22(8):902.e1-3.
46. Bould M, Edwards D, Villar RN. Arthroscopic diagnosis and treatment of septic arthritis of the hip joint. *Arthroscopy*. 1993;9(6):707-8.
47. Blitzer CM. Arthroscopic management of septic arthritis of the hip. *Arthroscopy*. 1993;9(4):414-6.
48. Yamamoto Y, Ide T, Hachisuka N, Maekawa S, Akamatsu N. Arthroscopic surgery for septic arthritis of the hip joint in 4 adults. *Arthroscopy*. 2001;17(3):290-7.

49. Lee YK, Park KS, Ha YC, Koo KH. Arthroscopic treatment for acute septic arthritis of the hip joint in adults. *Knee Surg Sports Traumatol Arthrosc.* 2012 [Epub ahead of print].
50. Hyman JL, Salvati EA, Laurencin CT, Rogers DE, Maynard M, Brause DB. The arthroscopic drainage, irrigation, and debridement of late, acute total hip arthroplasty infections: average 6-year follow-up. *J Arthroplasty.* 1999;14(8):903-10.
51. Larson CM, Giveans MR, Taylor M. Does arthroscopic FAI correction improve function with radiographic arthritis? *Clin Orthop Relat Res.* 2011;469(6):1667-76.
52. Walton NP, Jahromi I, Lewis PL. Chondral degeneration and therapeutic hip arthroscopy. *Int Orthop.* 2004;28(6):354-6.
53. McCarthy JC, Lee JA. Arthroscopic intervention in early hip disease. *Clin Orthop Relat Res.* 2004;(429):157-62.
54. Tönnis D, Heinecke A. Acetabular and femoral anteversion: relationship with osteoarthritis of the hip. *J Bone Joint Surg Am.* 1999;81(12):1747-70.
55. Horisberger M, Brunner A, Herzog RF. Arthroscopic treatment of femoroacetabular impingement of the hip: a new technique to access the joint. *Clin Orthop Relat Res.* 2010;468(1):182-90.
56. Ilizaliturri Jr VM. Complications of arthroscopic femoroacetabular impingement treatment: a review. *Clin Orthop Relat Res.* 2009;467(3):760-8.
57. Teloken MA, Schmiel I, Tomlinson DP. Hip arthroscopy: a unique inferomedial approach to bullet removal. *Arthroscopy.* 2002;18(4):E21.
58. Schindler A, Lechevallier JJ, Rao NS, Bowen JR. Diagnostic and therapeutic arthroscopy of the hip in children and adolescents: evaluation of results. *J Pediatr Orthop.* 1995;15(3):317-21.
59. Ilizaliturri Jr VM, Zarate-Kalfopulos B, Martinez-Escalante FA, Cuevas-Olivo R, Camacho-Galindo J. Arthroscopic retrieval of a broken guidewire fragment from the hip joint after cannulated screw fixation of slipped capital femoral epiphysis. *Arthroscopy.* 2007;23(2):e1-4, 227.
60. Sozen YV, Polat G, Kadioglu B, Dikici F, Ozkan K, Unay K. Arthroscopic bullet extraction from the hip in the lateral decubitus position. *Hip Int.* 2010;20(2):265-8.
61. Gupta RK, Aggarwal V. Late arthroscopic retrieval of a bullet from hip joint. *Indian J Orthop.* 2009;43(4):416-9.
62. Lee GH, Virkus WW, Kapotas JS. Arthroscopically assisted minimally invasive intraarticular bullet extraction: technique, indications, and results. *J Trauma.* 2008;64(2):512-6.
63. Singleton SB, Joshi A, Schwartz MA, Collinge CA. Arthroscopic bullet removal from the acetabulum. *Arthroscopy.* 2005;21(3):360-4.
64. Polesello GC, Ono NK, Honda EK, Guimarães RP, Ricioli Junior W, Souza BGS, et al. Tratamento artroscópico da osteocondromatose sinovial no quadril. *Rev Bras Ortop.* 2009;44(4):320-3.
65. Krebs VE. The role of hip arthroscopy in the treatment of synovial disorders and loose bodies. *Clin Orthop Relat Res.* 2003;(406):48-59.
66. Zini R, Longo UG, de Benedetto M, Loppini M, Carraro A, Maffulli N, Denaro V. Arthroscopic management of primary synovial chondromatosis of the hip. *Arthroscopy.* 2013;29(3):420-6.
67. Lee JB, Kang C, Lee CH, Kim PS, Hwang DS. Arthroscopic treatment of synovial chondromatosis of the hip. *Am J Sports Med.* 2012;40(6):1412-8.
68. Marchie A, Panuncialman I, McCarthy JC. Efficacy of hip arthroscopy in the management of synovial chondromatosis. *Am J Sports Med.* 2011;39 Suppl.: 126S-31S.
69. Boyer T, Dorfmann H. Arthroscopy in primary synovial chondromatosis of the hip: description and outcome of treatment. *J Bone Joint Surg Br.* 2008;90(3):314-8.
70. Alvarez MS, Moneo PR, Palacios JA. Arthroscopic extirpation of an osteoid osteoma of the acetabulum. *Arthroscopy.* 2001;17(7):768-71.
71. Chang BK, Ha YC, Lee YK, Hwang DS, Koo KH. Arthroscopic excision of osteoid osteoma in the posteroinferior portion of the acetabulum. *Knee Surg Sports Traumatol Arthrosc.* 2010;18(12):1685-7.
72. Khapchik V, O'Donnell RJ, Glick JM. Arthroscopically assisted excision of osteoid osteoma involving the hip. *Arthroscopy.* 2001;17(1):56-61.
73. Schröder e Souza BG, Dani WS, Honda EK, Ricioli W, Guimarães RP, Ono NK, et al. En bloc arthroscopic resection of osteoid osteoma in the hip: a report of four patients and literature review. *Curr Orthop Pract.* 2010;21(3):320-6.
74. Ilizaliturri Jr VM, Villalobos Jr FE, Chaidez PA, Valero FS, Aguilera JM. Internal snapping hip syndrome: treatment by endoscopic release of the iliopsoas tendon. *Arthroscopy.* 2005;21(11):1375-80.
75. Contreras ME, Dani WS, Endges WK, De Araujo LC, Berral JF. Arthroscopic treatment of the snapping iliopsoas tendon through the central compartment of the hip: a pilot study. *J Bone Joint Surg Br.* 2010;92(6):777-80.
76. Leunig M, Podeszwa D, Beck M, Werlen S, Ganz R. Magnetic resonance arthrography of labral disorders in hips with dysplasia and impingement. *Clin Orthop Relat Res.* 2004;(418):74-80.
77. Wiberg G. Studies on dysplastic acetabula and congenital subluxation of the hip joint. *Acta Orthop Scand Suppl.* 1939;83(58):5-135.
78. Byrd JW, Jones KS. Hip arthroscopy in the presence of dysplasia. *Arthroscopy.* 2003;19(10):1055-60.
79. Yen YM, Kocher MS. Chondral lesions of the hip: microfracture and chondroplasty. *Sports Med Arthrosc Rev.* 2010;18(2):83-9.
80. Fontana A. A novel technique for treating cartilage defects in the hip: a fully arthroscopic approach to using autologous matrix-induced chondrogenesis. *Arthrosc Techn.* 2012;1(1):e63-8.
81. Akimau P, Bhosale A, Harrison PE, Roberts S, McCall IW, Richardson JB, et al. Autologous chondrocyte implantation with bone grafting for osteochondral defect due to posttraumatic osteonecrosis of the hip - a case report. *Acta Orthop.* 2006;77(2):333-6.
82. Ellender P, Minas T. Autologous chondrocyte implantation in the hip: case report and technique. *Oper Techn Sports Med.* 2008;16(4):201-6.
83. Fontana A, Bistolfi A, Crova M, Rosso F, Massazza G. Arthroscopic treatment of hip chondral defects: autologous chondrocyte transplantation versus simple debridement - a pilot study. *Arthroscopy.* 2012;28(3):322-9.
84. Ruch DS, Sekiya J, Dickson Schaefer W, Koman LA, Pope TL, Poehling GG. The role of hip arthroscopy in the evaluation of avascular necrosis. *Orthopedics.* 2001;24(4):339-43.
85. Ellenrieder M, Tischer T, Kreuz PC, Frohlich S, Fritsche A, Mittelmeier W. Arthroscopically assisted therapy of avascular necrosis of the femoral head. *Oper Orthop Traumatol.* 2013;25(1):85-94.
86. Dorfmann H, Boyer T. Arthroscopy of the hip: 12 years of experience. *Arthroscopy.* 1999;15(1):67-72.
87. Mullis BH, Dahners LE. Hip arthroscopy to remove loose bodies after traumatic dislocation. *J Orthop Trauma.* 2006;20(1):22-6.
88. Philippon MJ, Kuppersmith DA, Wolff AB, Briggs KK. Arthroscopic findings following traumatic hip dislocation in 14 professional athletes. *Arthroscopy.* 2009;25(2):169-74.
89. Domb BG, Philippon MJ, Giordano BD. Arthroscopic capsulotomy, capsular repair, and capsular plication of the hip: relation to atraumatic instability. *Arthroscopy.* 2013;29(1):162-73.

90. Shu B, Safran MR. Hip instability: anatomic and clinical considerations of traumatic and atraumatic instability. *Clin Sports Med.* 2011;30(2):349-67.
91. Duthon VB, Charbonnier C, Kolo FC, Magnenat-Thalmann N, Becker CD, Bouvet C, et al. Correlation of clinical and magnetic resonance imaging findings in hips of elite female ballet dancers. *Arthroscopy.* 2013;29(3):411-9.
92. Shindle MK, Ranawat AS, Kelly BT. Diagnosis and management of traumatic and atraumatic hip instability in the athletic patient. *Clin Sports Med.* 2006;25(2):309-26.
93. Matsuda DK, rare fracture A. an even rarer treatment: the arthroscopic reduction and internal fixation of an isolated femoral head fracture. *Arthroscopy.* 2009;25(4):408-12.
94. Yamamoto Y, Ide T, Ono T, Hamada Y. Usefulness of arthroscopic surgery in hip trauma cases. *Arthroscopy.* 2003;19(3):269-73.
95. Lansford T, Munns SW. Arthroscopic treatment of Pipkin type I femoral head fractures: a report of 2 cases. *J Orthop Trauma.* 2012;26(7):e94-6.
96. Gotz LP, Schulz R. Arthroscopically controlled screw placement for osteosynthesis of acetabular fractures. *Unfallchirurg.* 2013;116(11):1033-5.
97. Wettstein M, Garofalo R, Borens O, Mouhsine E. Traumatic rupture of the ligamentum teres as a source of hip pain. *Arthroscopy.* 2005;21(3):382.
98. Kusma M, Jung J, Dienst M, Goedde S, Kohn D, Seil R. Arthroscopic treatment of an avulsion fracture of the ligamentum teres of the hip in an 18-year-old horse rider. *Arthroscopy.* 2004;20 Suppl. 2:64-6.
99. Haviv B, O'Donnell J. Arthroscopic debridement of the isolated Ligamentum Teres rupture. *Knee Surg Sports Traumat Arthrosc.* 2011;19(9):1510-3.
100. Philippon MJ, Pennock A, Gaskill TR. Arthroscopic reconstruction of the ligamentum teres: technique and early outcomes. *J Bone Joint Surg Br.* 2012;94(11):1494-8.
101. Fontana A, Zecca M, Sala C. Arthroscopic assessment of total hip replacement and polyethylene wear: a case report. *Knee Surg Sports Traumat Arthrosc.* 2000;8(4):244-5.
102. Khanduja V, Villar RN. The role of arthroscopy in resurfacing arthroplasty of the hip. *Arthroscopy.* 2008;24(1), 122 e1-3.
103. McCarthy JC, Jibodh SR, Lee JA. The role of arthroscopy in evaluation of painful hip arthroplasty. *Clin Orthop Relat Res.* 2009;467(1):174-80.
104. Cuellar R, Aguinaga I, Corcuera I, Ponte J, Usabiaga J. Arthroscopic treatment of unstable total hip replacement. *Arthroscopy.* 2010;26(6):861-5.
105. Van Riet A, De Schepper J, Delpont HP. Arthroscopic psoas release for iliopsoas impingement after total hip replacement. *Acta Orthopa Belg.* 2011;77(1):41-6.
106. Pattyn C, Verdonk R, Audenaert E. Hip arthroscopy in patients with painful hip following resurfacing arthroplasty. *Knee Surg Sports Traumat Arthrosc.* 2011;19(9):1514-20.
107. Bajwa AS, Villar RN. Arthroscopy of the hip in patients following joint replacement. *J Bone Joint Surg Br.* 2011;93(7):890-6.
108. Hwang DS, Kang C, Lee JB, Cha SM, Yeon KW. Arthroscopic treatment of piriformis syndrome by perineural cyst on the sciatic nerve: a case report. *Knee Surg Sports Traumat Arthrosc.* 2010;18(5):681-4.
109. Dezawa A, Kusano S, Miki H. Arthroscopic release of the piriformis muscle under local anesthesia for piriformis syndrome. *Arthroscopy.* 2003;19(5):554-7.
110. Polesello GC, Queiroz MC, Linhares JPT, Amaral DT, Ono NK. Variação anatômica do músculo piriforme como causa de dor glútea profunda: diagnóstico por neurografia RM e seu tratamento. *Rev Bras Ortop.* 2013;48(1):114-7.
111. Bunker TD, Esler CN, Leach WJ. Rotator-cuff tear of the hip. *J Bone Joint Surg Br.* 1997;79(4):618-20.
112. Kagan A. Rotator cuff tears of the hip. *Clin Orthop Relat Res.* 1999;(368):135-40.
113. Voos JE, Shindle MK, Pruett A, Asnis PD, Kelly BT. Endoscopic repair of gluteus medius tendon tears of the hip. *Am J Sports Med.* 2009;37(4):743-7.
114. Lachiewicz PF. Abductor tendon tears of the hip: evaluation and management. *J Am Acad Orthop Surg.* 2011;19(7):385-91.
115. Ilizaliturri Jr VM, Martinez-Escalante FA, Chaidez PA, Camacho-Galindo J. Endoscopic iliotibial band release for external snapping hip syndrome. *Arthroscopy.* 2006;22(5):505-10.
116. Polesello GC, Queiroz MC, Domb BG, Ono NK, Honda EK. Surgical technique: endoscopic gluteus maximus tendon release for external snapping hip syndrome. *Clin Orthop Relat Res.* 2013;471(8):2471-6.
117. Fox JL. The role of arthroscopic bursectomy in the treatment of trochanteric bursitis. *Arthroscopy.* 2002;18(7):E34.
118. Wiese M, Rubenthaler F, Willburger RE, Fennes S, Haaker R. Early results of endoscopic trochanter bursectomy. *Int Orthop.* 2004;28(4):218-21.
119. Baker Jr CL, Massie RV, Hurt WG, Savory CG. Arthroscopic bursectomy for recalcitrant trochanteric bursitis. *Arthroscopy.* 2007;23(8):827-32.
120. Farr D, Selesnick H, Janecki C, Cordas D. Arthroscopic bursectomy with concomitant iliotibial band release for the treatment of recalcitrant trochanteric bursitis. *Arthroscopy.* 2007;23(8):e1-5, 905.
121. Ho GW, Howard TM. Greater trochanteric pain syndrome: more than bursitis and iliotibial tract friction. *Curr Sports Med Rep.* 2012;11(5):232-8.
122. Sallay PI, Ballard G, Hamersly S, Schrader M. Subjective and functional outcomes following surgical repair of complete ruptures of the proximal hamstring complex. *Orthopedics.* 2008;31(11):1092.
123. Dierckman BD, Guanche CA. Endoscopic proximal hamstring repair and ischial bursectomy. *Arthrosc Techn.* 2012;1(2):e201-7.
124. Sarimo J, Lempainen L, Mattila K, Orava S. Complete proximal hamstring avulsions: a series of 41 patients with operative treatment. *Am J Sports Med.* 2008;36(6):1110-5.
125. Ross JR, Zaltz I, Nepple JJ, Schoenecker PL, Clohisey JC. Arthroscopic disease classification and interventions as an adjunct in the treatment of acetabular dysplasia. *Am J Sports Med.* 2011;39 Suppl.:72S-8S.
126. Kim KI, Cho YJ, Ramteke AA, Yoo MC. Peri-acetabular rotational osteotomy with concomitant hip arthroscopy for treatment of hip dysplasia. *J Bone Joint Surg Br.* 2011;93(6):732-7.
127. Fujii M, Nakashima Y, Noguchi Y, Yamamoto T, Mawatari T, Motomura G, et al. Effect of intra-articular lesions on the outcome of periacetabular osteotomy in patients with symptomatic hip dysplasia. *J Bone Joint Surg Br.* 2011;93(11):1449-56.
128. DeAngelis NA, Busconi BD. Hip arthroscopy in the pediatric population. *Clin Orthop Relat Res.* 2003;(406):60-3.
129. Jayakumar P, Ramachandran M, Youm T, Achan P. Arthroscopy of the hip for paediatric and adolescent disorders: current concepts. *J Bone Joint Surg Br.* 2012;94(3):290-6.
130. Roy DR. Arthroscopy of the hip in children and adolescents. *J Child Orthop.* 2009;3(2):89-100.
131. Berend KR, Vail TP. Hip arthroscopy in the adolescent and pediatric athlete. *Clin Sports Med.* 2001;20(4):763-78.
132. Akkari M, Santili C, Braga SR, Polesello GC. Trapezoidal bony correction of the femoral neck in the treatment of severe acute-on-chronic slipped capital femoral epiphysis. *Arthroscopy.* 2010;26(11):1489-95.