



Case Report

Garré's sclerosing osteomyelitis: case report^{☆,☆☆}

Frederico Barra de Moraes^{a,*}, Tainá Melo Vieira Motta^a, Alessandra Assis Severin^a,
Deniel de Alencar Faria^a, Fernanda de Oliveira César^a, Siderlei de Souza Carneiro^b

^a Department of Orthopedics and Traumatology, School of Medicine, Universidade Federal de Goiás, Goiânia, GO, Brazil

^b Anatomopathology Service, School of Medicine, Universidade Federal de Goiás, Goiânia, GO, Brazil

ARTICLE INFO

Article history:

Received 22 April 2013

Accepted 12 July 2013

Available online 24 April 2014

Keywords:

Osteomyelitis/diagnosis

Osteomyelitis/surgery

Osteomyelitis/therapy

ABSTRACT

The aim of this study was to report on a rare case of Garré's sclerosing osteomyelitis. The patient was a 54-year-old woman with a history of treatment for lupus using corticoids for 20 years, and for osteoporosis using alendronate for five years. She presented edema and developed a limitation of left knee movement one year earlier, with mild effusion and pain on metaphyseal palpation, but without fever. She was in a good general state, without local secretion. Images of her knee showed trabecular osteolysis of the distal metaphysis of the femur and a periosteal reaction in both proximal tibias and both distal femurs, compatible with chronic osteomyelitis of low virulence and slow progression. Magnetic resonance imaging showed T2 hypersignal in the femur and tibia. Curettage was performed on the left distal femur, with release of secretion, but this was negative on culturing. A biopsy showed chronic infection and inflammation, fibrosis, xanthogranulomatous reaction and foci of suppuration. Antibiotic therapy was administered for six months. The etiology was not clarified: bacterial infection was suspected, but culturing was generally negative. The chronic process was maintained by low-virulence infection or even after treatment. The differential diagnoses were fibrous dysplasia, syphilis, pustulosis palmoplantaris, rectocolitis, Crohn's disease, SAPHO (synovitis, acne, pustulosis, hyperostosis and osteitis) and Paget's disease. The unifocal diseases were osteoid osteoma, Ewing's disease, osteosarcoma and eosinophilic granuloma.

© 2014 Sociedade Brasileira de Ortopedia e Traumatologia. Published by Elsevier Editora Ltda. All rights reserved.

Osteomielite esclerosante de Garrè: relato de caso

RESUMO

Relatar um caso raro de osteomielite esclerosante de Garrè. Paciente feminino, 54 anos, com história de tratamento de lúpus com corticoide havia 20 anos e osteoporose, em uso de alendronato havia cinco anos. Apresentava edema e limitação do joelho esquerdo havia um ano, derrame leve, dor à palpação metafisária, afebril, bom estado geral, sem secreção local. Imagens do joelho evidenciaram osteólise trabecular da metafise distal do fêmur e reação periosteal nas duas tíbias proximais e nos dois fêmures distais, compatíveis com

Palavras-chave:

Osteomielite/diagnóstico

Osteomielite/cirurgia

Osteomielite/terapia

[☆] Please cite this article as: de Moraes FB, Motta TMV, Severin AA, de Alencar Faria D, de Oliveira César F, de Souza Carneiro S. Osteomielite esclerosante de Garrè: relato de caso. Rev Bras Ortop. 2014;49:401-404.

^{☆☆} Work performed in the Department of Orthopedics and Traumatology, School of Medicine, Universidade Federal de Goiás, Goiânia, GO, Brazil.

* Corresponding author.

E-mail: frederico_barra@yahoo.com.br (F.B. de Moraes).

osteomielite crônica, de baixa virulência e progressão lenta. Hipersinal em T2 no fêmur e tibia à ressonância. Curetagem do fêmur distal esquerdo, com saída de secreção, mas cultura negativa. Biópsia evidenciou infecção e inflamação crônica, fibrose, reação xantogranulomatosa e focos de supuração. Feita antibioticoterapia por seis meses. Etiologia não esclarecida, suspeita de infecção bacteriana, mas geralmente a cultura é negativa, processo crônico mantido por infecção de baixa virulência ou mesmo após o tratamento. Diagnósticos diferenciais: displasia fibrosa, sífilis, pustulose palmoplantar, retocolite, Crohn, Sapho (sinovite, acne, pustulose, hiperostose, osteíte) e Paget. Unifocais: osteoma osteoide, Ewing, osteossarcoma e granuloma eosinofílico.

© 2014 Sociedade Brasileira de Ortopedia e Traumatologia. Publicado por Elsevier Editora Ltda. Todos os direitos reservados.

Introduction

Garré's osteomyelitis is a rare inflammatory disease of chronic nature, characterized by periosteal reactions, which induces bone neof ormation. It mainly affects the region of the mandible and, in rare cases, may be located in the metaphyseal region of the long bones. This disease is also known as Garré's sclerosing osteomyelitis (GSO), chronic osteomyelitis with proliferative periostitis, chronic sclerosing osteomyelitis, ossifying periostitis or non-suppurative chronic sclerosing osteomyelitis.¹⁻³ The clinical condition is characterized by an insidious start, with local pain and reaction in the affected bone. The symptoms have an episodic non-progressive nature and may persist for several months. On the other hand, the duration of GSO is very variable among patients, who may present the disease for several years. The function of the affected bone is generally preserved and, during the interval between crises, most patients are seen to be healthy.^{4,5}

The aim of this study was to report on a rare case of Garré's sclerosing osteomyelitis, in which the proximal region of the tibiae and distal region of the femurs were affected in a 54-year-old patient.

Case report

The patient was a 54-year-old woman with a history of treatment for lupus using corticoid, over the preceding 20 years. She presented severe osteoporosis and had been using alendronate for five years. The specific clinical condition had been evolving over the preceding year, with pain, edema and chronic limitation of movement in her left knee, which presented slight joint effusion and pain on palpation of the distal femoral metaphysis. She was not febrile, in a good general state and without reddening or discharge of secretions at the site.

Radiographs and tomographic scans were produced on the left knee. The images showed trabecular osteolysis of the distal metaphysis of the left femur and periosteal reaction in both proximal tibiae and both distal femurs. This was compatible with chronic osteomyelitis, of low virulence and slow progression (Figs. 1A-C, 2A-C and 3A-B). The imaging diagnosis was complemented by means of magnetic resonance, which showed T2 hypersignal both in the femur and in the tibia, thus indicating GSO.

Surgical treatment consisting of curettage of the left distal femur was performed. Puncturing the knee joint did not show any purulent secretion. The bone window thus made subsequently discharged secretion, but this produced negative cultures. The material obtained from the surgery was sent for biopsy analysis, which showed infection and chronic inflammation marked by fibrosis, xanthogranulomatous reaction, foci of suppuration and absence of acid-alcohol resistant bacilli (AARB), fungi or signs of malignancy (Fig. 4).

The patient underwent venous antibiotic therapy with oxacillin (4 g/day) and subsequently oral medication consisting of cephalexin (2 g/day for six months), with improvement of inflammation in the left knee.

Discussion

Carl Alois Philipp Garré was a Swiss surgeon and bacteriologist who in 1893 published an article dealing with the manifestations of osteomyelitis. His name became associated with the disease, which became known as Garré's sclerosing osteomyelitis, although he was not responsible for describing it.^{1,2} He reported that there was peripheral formation of a bone reaction due to irritation or mild infection, which resulted in thickening of the periosteum of long bones. The etiology of this disease has still not been fully clarified. Bacterial infection is suspected, but the cultures are generally negative and the chronic process may be maintained through low-virulence infection or even after the infection has been treated. If the germ cannot be detected through culturing, investigation by means of the polymerase chain reaction (PCR) should be requested.³

A multifocal sclerosing bone reaction with clinical, radiological and histological characteristics similar to GSO may be encountered in several diseases, such as fibrous dysplasia, syphilis, pustulosis palmoplantaris, ulcerative rectocolitis, Crohn's disease, SAPHO syndrome (synovitis, acne, pustulosis, hyperostosis and osteitis) and Paget's disease. Additional differential diagnoses in cases of unifocal sclerosing bone reaction may include osteoid osteoma, Ewing's disease, osteosarcoma and eosinophilic granuloma.^{3,4}

The osteoporosis presented by our patient may have contributed toward the start of the infectious/inflammatory process that originated GSO, since the bone hypovascularization that occurs in osteoporosis facilitates inflammation, followed by necrosis of this tissue. Lupus, which is a chronic systemic disease, seems to facilitate the establishment of

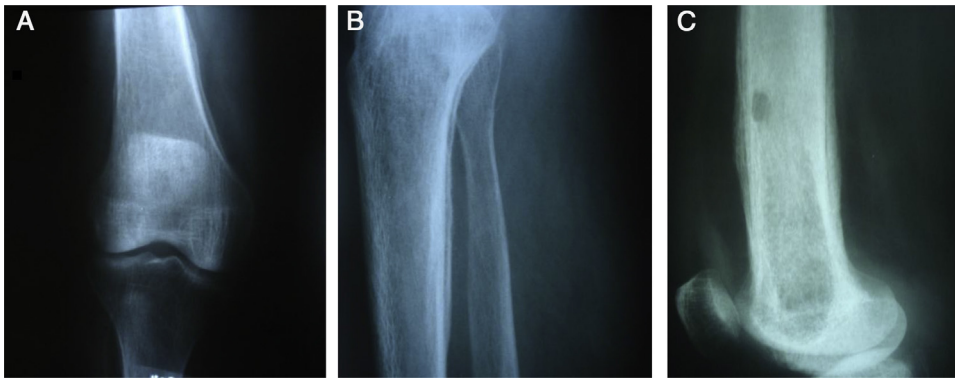


Fig. 1 – Radiographic appearance of the lesion. (A) Radiograph in anteroposterior view showing periosteal reaction in the femur. (B) Radiograph in lateral view showing periosteal reaction in the tibia. (C) Radiograph in lateral view showing distal femur after the operation, with a bone window for drainage, curettage, culturing and biopsy, and showing the various layers of the periosteal reaction.

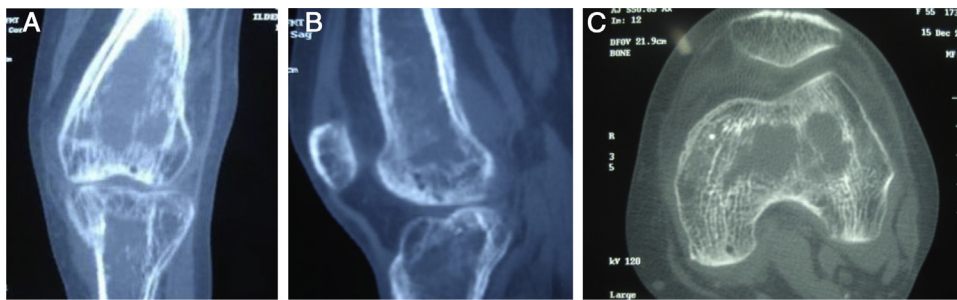

Fig. 2 – Computed tomography of the left knee, with bone window, showing trabecular osteolysis and periosteal reaction. Coronal (A), sagittal (B) and axial slice (C).

osteomyelitis.^{5,6} Another point of interest in the present case can be highlighted: use of corticoids is an important triggering factor for osteoporosis. Thus, it is reasonable to suppose that the treatment for lupus in the present case may have contributed toward the appearance of osteoporosis and, together, the two diseases may have favored development of GSO.

Chronic osteomyelitis presents low mortality but high morbidity. Clinically, the chronic phase is always preceded by an

acute infectious process, with phlogistic signs (pain, heat, redness, tumor growth, deformity and limitation). However, in patients who have become debilitated through other diseases, as was the case in our patient, the initial condition may be masked, which has the consequence that the diagnosis will only become possible in the chronic phase.⁷

In relation to the imaging diagnosis, Vasiliev et al.⁸ evaluated 121 patients between the ages of 4 and 74 years,

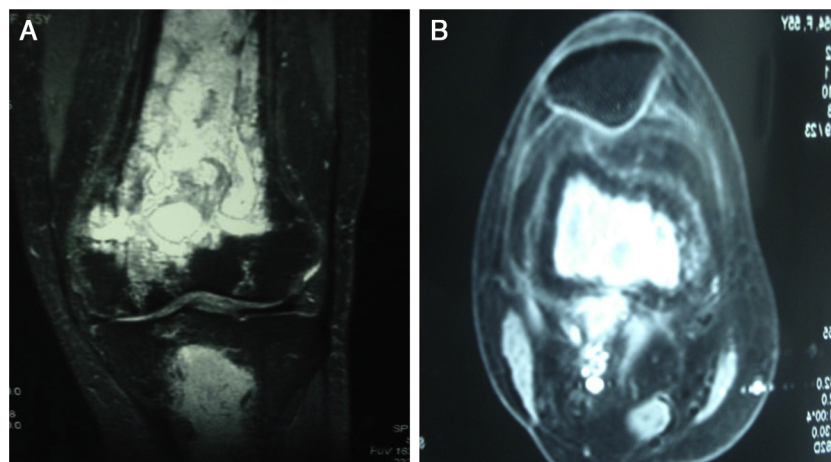


Fig. 3 – Magnetic resonance of the left knee. Coronal (A) and axial (B) T2 slices showing hypersignal indicative of purulent secretion.

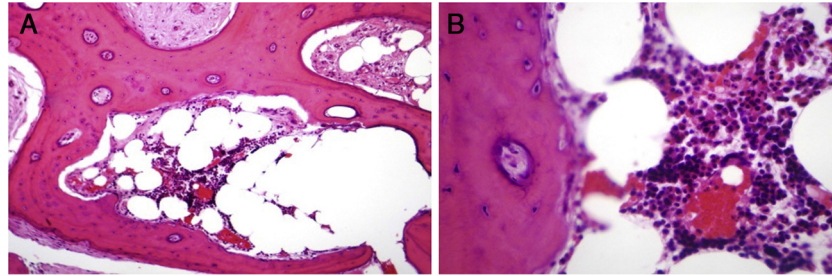


Fig. 4 – Histological study on bone biopsy from the left femur, in hematoxylin-eosin (A) and (B), showing infection and chronic inflammation marked by fibrosis, xanthogranulomatous reaction and foci of suppuration indicative of GSO.

with a diagnosis of osteomyelitis in limbs. The most precise examination was spiral computed tomography, which had an accuracy of 96.7%, sensitivity of 99.1% and specificity of 80%, while radiographs presented 81.8, 84.9 and 60%, respectively. In the beginning, a combination of sclerotic areas and cystic areas could be observed in the region of the lesions, and the latter is gradually replaced by sclerotic areas. During exacerbations, bone formation due to periosteal reaction could be seen, resembling an onion skin. Thus, the disease is marked by thickening and sclerosis of the affected bone.^{3,8}

Surgical treatment in association with antibiotic therapy is the best option for chronic osteomyelitis. Antibiotic therapy alone is ineffective, independent of the administration route, because the “bone sequestration” found in the chronic disease comprises fragments of necrotic bone and thus does not present a blood supply that would allow antibiotic to arrive at the infected tissue.^{3,7}

Conflicts of interest

The authors declare no conflicts of interest.

REFERENCES

1. Garrè CA, Borchard A. *Lehrbuch der Chirurgie*. London: Oxford University Press; 1920.
2. Wood RE, Nortjé CJ, Grotepass F, Schmidt S, Harris AM. Periostitis ossificans versus Garrè's osteomyelitis. Part I. What did Garrè really say? *Oral Surg Oral Med Oral Pathol*. 1988;65(6):773-7.
3. Vienne P, Exner GU. Garrè sclerosing osteomyelitis. *Orthopade*. 1997;26(10):902-7.
4. Bernard-Bonnin AC, Marton D, Brochu P. Chronic sclerosing osteomyelitis (so-called Garrè's). Review of 12 cases. *Arch Fr Pediatr*. 1987;44(4):277-82.
5. Vieira CL, Ayres de Melo VEV. Osteomielite: relato de caso clínico. *Int J Dent*. 2006;1(1):35-40.
6. Xavier R, Vecchi AA. Infecções osteoarticulares. In: Hebert S, Xavier R, Pardini Júnior AG, Barros Filho TEP, editors. *Tratado de ortopedia e traumatologia: princípios e práticas*. 3rd ed. Porto Alegre: Artmed; 2007. p. 822-30.
7. Suma R, Vinay C, Shashikanth MC, Subba Reddy VV. Garrè's sclerosing osteomyelitis. *J Indian Soc Pedod Prev Dent*. 2007;25 Suppl.:S30-3.
8. Vasiliev AI, Bulanova TV, Onishchenko MP. Spiral computed tomography in the diagnosis of limb osteomyelitis. *Vestn Rentgenol Radiol*. 2003;(6):44-9.