



## Original Article

# Results from surgical treatment of Morel-Lavallée lesions: prospective cohort study<sup>☆</sup>



Evandro Pereira Palacio\*, Gabriel Guimarães Di Stasi,  
Ewerton Henrique Rodrigues Teixeira Lima, Roberto Ryuiti Mizobuchi,  
Alcides Durigam Júnior, José Antônio Galbiatti

Faculdade de Medicina de Marília, Marília, SP, Brazil

## ARTICLE INFO

## Article history:

Received 23 February 2014

Accepted 20 March 2014

Available online 28 February 2015

## Keywords:

Wounds and injuries

Soft-tissue injuries/pathology

Soft-tissue injuries/surgery

Multiple trauma

## ABSTRACT

**Objective:** To present the results from early diagnosis and delayed surgical treatment of a cohort of patients who were diagnosed with Morel-Lavallée lesions.

**Methods:** Between January 2006 and December 2013, we performed delayed surgical debridement on Morel-Lavallée lesions, after delimitation of the local tissue necrosis, followed by closure through second intention and/or use of grafts/flaps.

**Results:** All the patients evolved with complete closure of the lesion after the delayed debridement, granulation of the operative wound and primary suturing or construction of pedunculated flaps. Three patients (50%) evolved with deep infectious processes due to the successive operative procedures.

**Conclusion:** Whatever the treatment methods used are, they should be performed in a radical manner. If not, the patient will be at risk of evolution to septicemia and death.

© 2015 Sociedade Brasileira de Ortopedia e Traumatologia. Published by Elsevier Editora Ltda. All rights reserved.

## Resultados do tratamento cirúrgico da lesão de Morel-Lavallée. Estudo coorte prospectivo

## RESUMO

**Objetivo:** apresentar os resultados do diagnóstico precoce e do tratamento cirúrgico tardio de uma coorte de pacientes diagnosticada com a lesão de Morel-Lavallée (LML).

**Métodos:** de janeiro de 2006 a dezembro de 2013 os autores fizeram o desbridamento cirúrgico tardio da LML, após a delimitação da necrose tecidual local, seguido de fechamento por segunda intenção e/ou enxertos/retalhos.

**Resultados:** todos os pacientes evoluíram com fechamento total da lesão após o desbridamento tardio a granulação da ferida operatória e a(os) sutura primária/retalhos pediculados. Três pacientes (50%) evoluíram com processo infeccioso profundo devido aos sucessivos procedimentos operatórios.

## Palavras-chave:

Ferimentos e lesões

Lesões dos tecidos moles/patologia

Lesões dos tecidos moles/cirurgia

Traumatismo múltiplo

<sup>☆</sup> Work developed at the Department of Orthopedics and Traumatology, Faculdade de Medicina de Marília, Marília, SP, Brazil.

\* Corresponding author.

E-mail: [palacio@famema.br](mailto:palacio@famema.br) (E.P. Palacio).

<http://dx.doi.org/10.1016/j.rboe.2015.02.011>

2255-4971/© 2015 Sociedade Brasileira de Ortopedia e Traumatologia. Published by Elsevier Editora Ltda. All rights reserved.

Conclusão: sejam quais forem os métodos de tratamento empregados, estes devem ser feitos de maneira radical, sob risco de evolução dos pacientes para septicemia e óbito.

© 2015 Sociedade Brasileira de Ortopedia e Traumatologia. Publicado por Elsevier Editora Ltda. Todos os direitos reservados.

## Introduction

Morel-Lavallée lesions (MLLs), also known as degloving injuries, were first described by the French physician Maurice Morel-Lavallée in 1853. They are rare soft-tissue injuries that are associated with high rates of morbidity and mortality.<sup>1-8</sup> They occur because of sudden application of high-intensity forces to a certain area of the body and their effect is to separate skin and subcutaneous tissue from the underlying muscle fascia.<sup>9,10</sup> The space thus created becomes filled with blood, lymph or necrotic fatty tissue, and this not uncommonly leads to severe inflammatory and infectious processes.<sup>3,7-10</sup>

Diagnosing MLLs is not an easy task. In the great majority of the cases, these are closed injuries and this often causes confusion or even failure to diagnose the condition. During careful clinical examination, it can be seen that in the acute phase, the volume of the area affected is greater, and this is accompanied by floating, hypermobility and hypoesthesia.<sup>4,5,7,9</sup> The lesion usually affects an area greater than the area that can initially be assessed in the course of the physical examination, during emergency attendance.<sup>3,10</sup> The circulation of the skin and subcutaneous tissue in the injured segment is commonly compromised and there is often great difficulty in determining whether these tissues are recoverable.<sup>3</sup> In normal tissues, the viability of the capillary perfusion can generally be easily estimated by means of applying local compression using a finger or through identifying active bleeding in the region affected. However, in the case of complex tissue damage, as occurs in MLL, these tests may not be the most reliable type for diagnostic purposes. Typically, the treatment comprises early radical debridement of the tissues affected, followed by second-intention healing of the wound.<sup>5-8,11,12</sup> However, some authors have taken the view that postponing the initial treatment until the time when delimitation or necrosis of the tissues has occurred is the best approach.<sup>13</sup> Whatever the therapy used, there is unanimity that such patients will often have to undergo multiple procedures and surgical revisions, with a higher risk of infection.<sup>3,5-7,9</sup>

Given the poor prognosis of this type of injury and the difficulty in making precise diagnoses and treatments, along with the complete lack of information on this topic in the various databases available, and particularly in the Brazilian orthopedic databases, the present study was proposed with the aim of evaluating the results from late diagnosis and surgical treatment of MLL.

## Patients and methods

This was a prospective cohort study that was approved by our institution's ethics committee for research involving human beings (CAAE 04497812.4.0000.5413). All the patients,

or their legal guardians, agreed to participate and signed a free and informed consent statement after having received detailed information about the content and form of the study.

The sample size was determined beforehand, by means of specific statistical tests. The  $\alpha$  risk (5%) and  $\beta$  risk (20%) were taken into consideration, along with the variability of the variables ( $p_1=0.13$  and  $p_2=0.9$ ), thus arriving at a minimum number of five individuals.

Initially, 11 patients with a diagnosis of MLL confirmed by means of tomography and/or magnetic resonance examination were selected, between January 2006 and December 2013. Patients were excluded if they presented any of the following: previous clinical or surgical treatment on the lesion in question ( $n=3$ ); general state of health that was considered to be poor or serious ( $n=1$ ); refusal to sign the free and informed consent statement ( $n=1$ ). Thus, the final cohort consisted of six patients.

All the operative procedures were performed by the same orthopedic team, always under the same pre and postoperative protocols.

After the patients had arrived at the emergency service and had gone through the advanced trauma life support (ATLS) protocol, simple radiographs of the contused regions were produced, always in two orthogonal views. On the basis of specific abnormalities seen in the clinical examination (excessive local pain that was out of line with the intensity of the trauma; extensive ecchymosis or hematomas; and especially, local/regional hypermobility of the skin), the patients then underwent tomography or magnetic resonance examinations, in order to confirm the diagnosis of MLL.

After obtaining confirmation that detachment of the skin and/or subcutaneous cellular tissue had occurred, we waited another four to five days for the lesion to become delimited with the first signs of necrosis. At that time, the patients were taken to the surgical center to undergo debridement procedures, always in association with irrigation and profuse washing (Figs. 1-5).

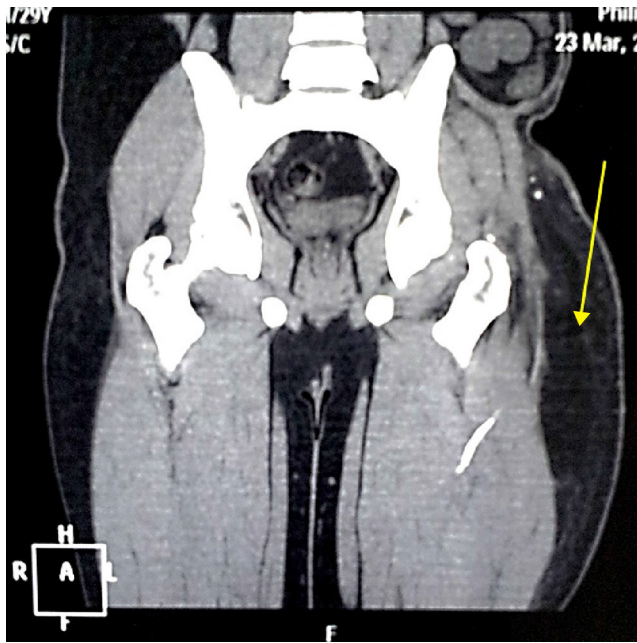
Once the infectious processes had been brought under control, granulation of the operative wound was awaited, in order to be able to construct myocutaneous flaps and/or perform primary closure of the granulated edges of the wound (Figs. 6 and 7).

## Results

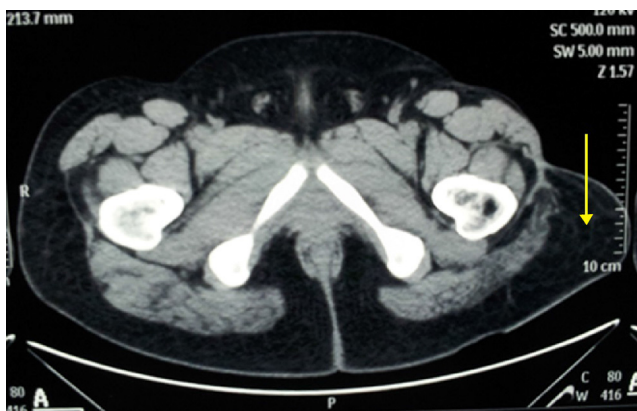Among the six patients included, four were male (66.7%) and two were female (33.3%) ( $p=0.41$ ). Their ages ranged from 25 to 55 years, with a mean of 39.8 years ( $\pm 11$  years) (minimum age: 25 years; maximum age: 55 years; 95% CI: 31-48.6 years) (Table 1).

**Table 1 – General characteristics of the patients.**

	Gender	Age	Anatomical region	Injury size	Trauma mechanism
Patient 1	Female	25	Posterior face of forearm/elbow	Approx. 20 cm	Fall from motorbike
Patient 2	Male	44	Thigh and gluteus	More than 30 cm	Fall from a height
Patient 3	Male	37	Knee/calf	Approx. 15 cm	Car accident
Patient 4	Male	31	Hip and flank	More than 30 cm	Car accident
Patient 5	Male	55	Lateral face of hip	Approx. 20 cm	Direct trauma (work accident)
Patient 6	Female	47	Anterior face of thigh	Approx. 15 cm	Car accident



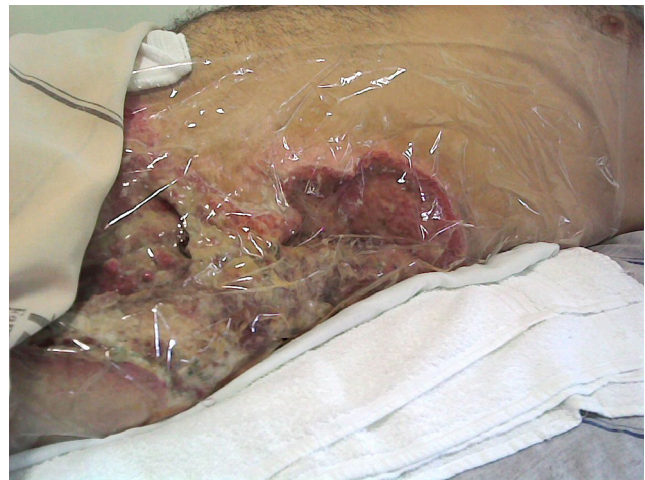**Fig. 1 – Coronal tomographic slice showing large accumulation of fluid (arrow), between the subcutaneous tissue and muscle fascia.**



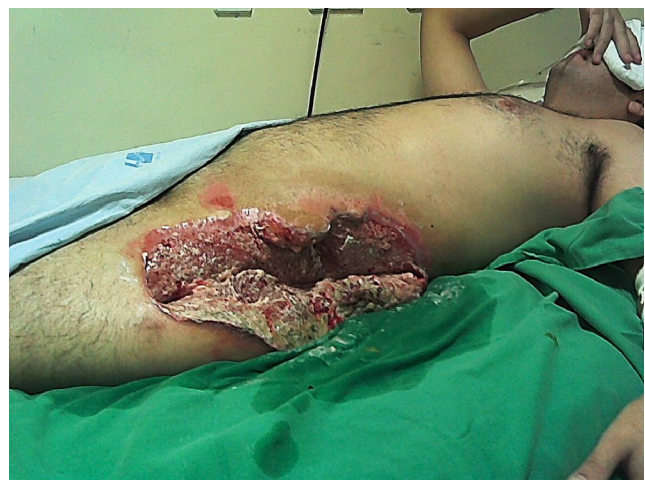**Fig. 2 – Axial tomographic slice showing large accumulation of fluid (arrow), between the subcutaneous tissue and muscle fascia.**

## Discussion

MLL, or degloving injury, is a rare form of soft-tissue injury that is associated with high morbidity.<sup>12,14,15</sup> The areas that



**Fig. 3 – Image of flank and hip after initial debridement, showing necrosis and infection.**

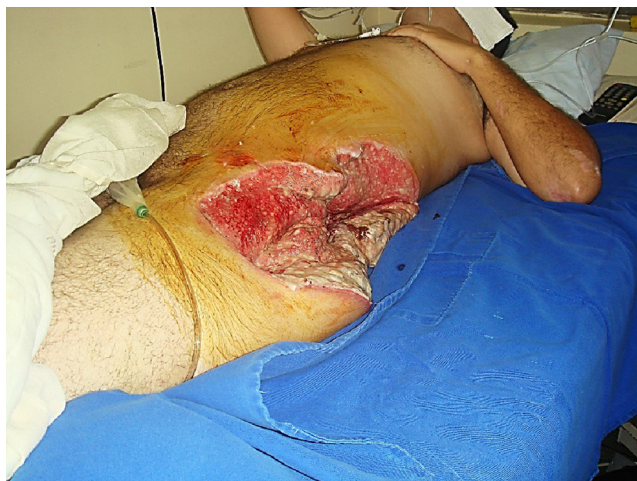

**Fig. 4 – Image of flank and hip, undergoing secondary healing process (granulation tissue).**

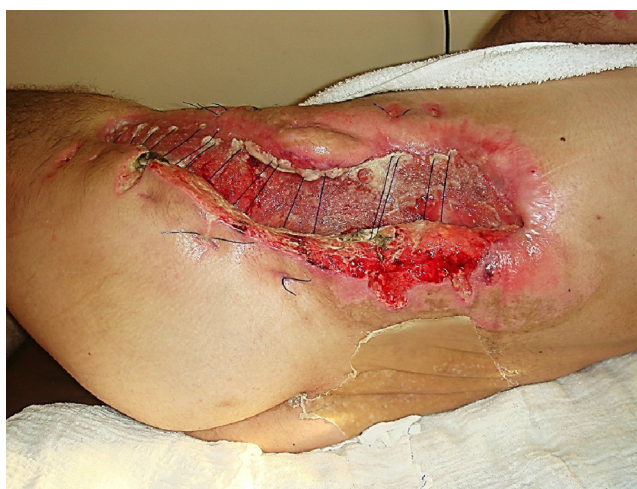are most likely to suffer such injuries are the anterolateral thigh, gluteal, lumbodorsal and scapular regions.<sup>6-8,12,14</sup>

The patients affected by MLL are generally young. In this study, the cohort of patients consisted of individuals between the ages of 25 and 55 years who were economically active. They were mostly male (Table 1).<sup>9,13</sup>

These injuries involve application of sudden high-intensity forces, which could consist of compression, stretching, torsion or friction applied to the structures.<sup>7,9,12</sup> The result is



**Fig. 5 – Image of flank and hip, undergoing secondary healing process (granulation tissue).**

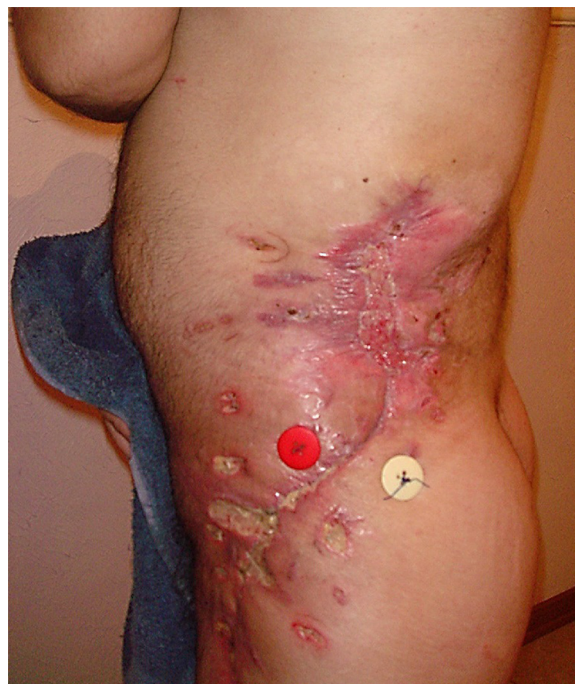

**Fig. 6 – Attempt to bring together the edges of the wound, before constructing myocutaneous flaps.**

that the subcutaneous tissue becomes detached from the muscle fascia, thereby injuring the vessels that pass through these layers.<sup>4,5,15</sup> The hemolymph fluid becomes surrounded by granulous tissue, which may lead to formation of a fibrous pseudocapsule, prevention of fluid reabsorption and predisposition toward bacterial colonization and infection.<sup>9,11-14</sup>

Historically, the treatment for such injuries has comprised serial open debridement followed by second-intention healing. Recently, methods that are less invasive have been tried out. One of these is compression by means of a Vicryl mesh, which distributes the surface tension in the region of the wound to a larger surface, thereby providing relief for the tension in the open area. However, there is no evidence that this treatment is free from sequelae.<sup>10,11,16</sup> Some lesions may persist, despite conventional treatments. In these cases, methods that are more aggressive are commonly indicated, such as serial aspiration and the use of chemical sclerosis, in cases of formation of pseudocysts.<sup>3,8,13,15</sup>

Compromised circulation in the skin and subcutaneous tissue in the injured segment is always observed and



**Fig. 7 – Final image after performing grafting.**

it is often difficult to determine whether the tissue is recoverable.<sup>3,10-12,15</sup> Cutaneous capillary filling tests and bleeding tests have dubious value in evaluating MLL cases, given that the local or regional capillary filling may remain within normal parameters for up to 36 h, due to the action of the capillary network adjacent to the injured area. The lack of reliable parameters may make the initial diagnosis of the injury difficult, thereby leading to severe conditions of necrosis and septicemia.

In this study, although the diagnosis was invariably made during the acute phase, by means of detailed physical examination and imaging examinations, it was decided to performed late debridement, four or five days after the initial injury. Over this period, local signs of tissue necrosis and consequent delimitation of the region affected could already be observed. In fact, over a seven-day period following the initial injury, three of the patients in our sample (50%) evolved with extensive areas of superficial and deep necrosis (skin, subcutaneous tissue, fascias, muscles, tendons and nerves)<sup>8,10,13-16</sup> and they presented severe infectious processes. Debridement, with radical removal of all the devitalized structures, therefore became imperative, due to the risk of septicemia and progression to death.

It was also seen that late debridement of the lesion, only after the necrotic area had become delimited, greatly diminished the chances of inadvertent removal of healthy soft tissues, i.e. those that still presented effective circulation.

The risks of severe infectious processes are worsened by the functional deficits and adhesences that multiple prolonged surgical procedures cause.<sup>12,14-16</sup> It is important to emphasize that removal of prime muscle structure because of multiple debridement procedures ends up causing joint functional deficits, with harm to the entire regional biomechanics.

Finally, scars retract in many cases, and this particularly worsens the prognosis for these patients, given that new surgical procedures are needed in order to achieve a minimum degree of joint movement.

---

## Conclusion

MLL is still a little known condition among the professionals who work on the front line of emergency services, including orthopedic surgeons. Perhaps for this reason, it is an underdiagnosed type of injury. Whatever the treatment methods used are, they should be implemented in a radical manner, because of the risk of evolution to septicemia and death.

---

## Conflicts of interest

The authors declare no conflicts of interest.

---

## REFERENCES

- Pitrez EH, Pellanda RC, Silva ME, Holz GG, Hertz FT, Hoefel Filho JR. Lesão de Morel-Lavallée: relato de caso. *Radiol Bras*. 2010;43(5):336-8.
- Demirel M, Dereboy F, Ozturk A, Turhan E, Yazar T. Morel-Lavallée lesion: results of surgical drainage with the use of synthetic glue. *Saudi Med J*. 2007;28(1):65-7.
- Mello DF, Demario LA, Solda SC, Helene Júnior A. Desenlucamentos fechados: lesão de Morel-Lavallée. *Rev Bras Cir Plast*. 2010;25(2):255-60.
- Tseng S, Tornetta P 3rd. Percutaneous management of Morel-Lavallée lesions. *J Bone Joint Surg Am*. 2006;88(1):92-6.
- Van Gennip S, van Bokhoven SC, van den Eede E. Pain at the knee: the Morel-Lavallée lesion, a case series. *Clin J Sport Med*. 2012;22(2):163-6.
- Moriarty JM, Borrero CG, Kavanagh EC. A rare cause of calf swelling: the Morel-Lavallée lesion. *Ir J Med Sci*. 2011;180(1):265-8.
- Tejwani SG, Cohen SB, Bradley JP. Management of Morel-Lavallée lesion of the knee: twenty-seven cases in the national football league. *Am J Sports Med*. 2007;35(7):1162-7.
- Luria S, Yaakov A, Yoram W, Meir L, Peyser A. Talc sclerodhesis of persistent Morel-Lavallée lesions (posttraumatic pseudocysts): case report of 4 patients. *J Orthop Trauma*. 2006;20(6):435-8.
- Anakwenze OA, Trivedi V, Goodman AM, Ganley TJ. Concealed degloving injury (the Morel-Lavallée lesion) in childhood sports: a case report. *J Bone Joint Surg Am*. 2011;93(24):e148.
- Montbrun S, Khalili K, MacLellan S, Easson A. Morel-Lavallée lesion of the lower back mimicking an abscess: a case report. *Surg Sci*. 2012;3(4):213-5.
- Gwinn DE, Morgan RA, Kumar AR. Gluteus maximus avulsion and closed degloving lesion associated with a thoracolumbar burst fracture. A case report. *J Bone Joint Surg Am*. 2007;89(2):408-12.
- Collinge C, Tornetta P 3rd. Soft tissue injuries associated with pelvic fractures. *Orthop Clin North Am*. 2004;35(4):451-6.
- Wood GW. General principles of fracture treatment. In: Canale ST, Beaty JH, editors. *Campbell's operative orthopaedics*. 11th ed. Philadelphia: Mosby Elsevier; 2008. p. 3032-5.
- Harma A, Inan M, Ertem K. The Morel-Lavallée lesion: a conservative approach to closed degloving injuries. *Acta Orthop Traumatol Turc*. 2004;38(4):270-3.
- Demirel M, Dereboy F, Ozturk A, Turhan E, Yazar T. Morel-Lavallée lesion. Results of surgical drainage with the use of synthetic glue. *Saudi Med J*. 2007;28(1):65-7.
- Hak DJ, Olson SA, Matta JM. Diagnosis and management of closed internal degloving injuries associated with pelvic and acetabular fractures: the Morel-Lavallée lesion. *J Trauma*. 1997;42(6):1046-51.