



Original Article

Safety zone for surgical access in the middle third of the clavicle: study on cadavers[☆]



Fabiano Rebouças Ribeiro, Fernanda de Marchi Bosi Porto*, Marcio Vieira Sanches Silva, Antonio Carlos Tenor Junior, Miguel Pereira da Costa, Cantidio Filardi

Hospital do Servidor Público Estadual de São Paulo, São Paulo, SP, Brazil

ARTICLE INFO

Article history:

Received 3 February 2014

Accepted 26 May 2014

Available online 17 June 2015

Keywords:

Clavicle/surgery

Clavicle/anatomy

Cadaver

ABSTRACT

Objective: The aim of this study was to establish a neurovascular safety zone for surgical access in the middle third of the clavicle, by means of dissection on cadavers.

Methods: Twenty shoulders were dissected in 10 cadavers, with deep dissection of the middle third of the clavicle. The following structures were identified: subclavian vein, upper trunk of the brachial plexus (anterior and posterior divisions) and suprascapular nerve. These structures were marked out in order to measure their distances from the most proximal point of the middle third of the clavicle.

Results: The mean distances from the middle third of the clavicle to the suprascapular nerve, subclavian vein, upper trunk, anterior division of the upper trunk and posterior division of the upper trunk were respectively, for the right side: 15.92 cm, 10.77 cm, 23.68 cm, 14.60 cm and 15.42 cm; and for the left side: 12.69 cm; 9.82 cm; 22.19 cm; 12.16 cm and 13.46 cm.

Conclusion: There was a statistical difference in the distances to the suprascapular nerve and anterior division of the upper trunk, in comparing between the right and left sides. The closest neurovascular structures to the middle third of the clavicle were the suprascapular nerve and subclavian vein.

© 2014 Sociedade Brasileira de Ortopedia e Traumatologia. Published by Elsevier Editora Ltda. All rights reserved.

Zona de segurança no acesso cirúrgico do terço médio da clavícula: estudo em cadáveres

RESUMO

Objetivo: Estabelecer uma zona de segurança neurovascular no acesso cirúrgico do terço médio da clavícula por dissecação em cadáveres.

Métodos: Foram dissecados 20 ombros de 10 cadáveres, foi feita a dissecação profunda do terço médio da clavícula e identificaram-se as seguintes estruturas: veia subclávia, tronco superior do plexo braquial (divisão anterior e posterior) e nervo supraescapular. Essas estruturas foram demarcadas para mensuração de suas distâncias até os pontos mais próximos do terço médio da clavícula.

Palavras-chave:

Clavícula/cirurgia

Clavícula/anatomia

Cadáver

[☆] Work developed in the Hospital do Servidor Público Estadual de São Paulo, São Paulo, SP, Brazil.

* Corresponding author.

E-mails: fer.bosi@hotmail.com, ricapb@gmail.com (F. de Marchi Bosi Porto).

<http://dx.doi.org/10.1016/j.rboe.2015.06.005>

2255-4971/© 2014 Sociedade Brasileira de Ortopedia e Traumatologia. Published by Elsevier Editora Ltda. All rights reserved.

Resultados: A distância média do terço médio da clavícula ao nervo supraescapular, à veia subclávia, ao tronco superior, à divisão anterior do tronco superior e à divisão posterior do tronco superior foi, respectivamente, do lado direito: 15,92 cm; 10,77 cm; 23,68 cm; 14,60 cm e 15,42 cm; do lado esquerdo: 12,69 cm; 9,82 cm; 22,19 cm; 12,16 cm e 13,46 cm.

Conclusão: Houve diferença estatística entre as distâncias do nervo supraescapular e a divisão anterior do tronco superior comparativa entre os lados direito e esquerdo. As estruturas neurovasculares mais próximas ao terço médio da clavícula foram o nervo supraescapular e a veia subclávia.

© 2014 Sociedade Brasileira de Ortopedia e Traumatologia. Publicado por Elsevier Editora Ltda. Todos os direitos reservados.

Introduction

The clavicle has important anatomical relationships with the subclavian artery, subclavian vein and brachial plexus, especially in its middle third, where the curvature is the reference point used for accessing these structures. In cases of trauma and/or surgery in the middle third of the clavicle, and especially in situations of fractures that need to be reduced and fixed by means of open surgery, using synthesis material, these structures may become injured because of their anatomical proximity.^{1,2}

The brachial plexus is formed by the roots of C5, C6, C7, C8 and T1. It originates from the cervical spine, heads toward the upper limbs and passes between the middle and anterior scalene muscles. The roots of C5 and C6 form the upper trunk, from which the suprascapular nerve emerges. Each trunk divides into anterior and posterior portions when it passes below the clavicle.³

The right subclavian artery is a branch of the brachiocephalic trunk and the left subclavian artery is a branch of the aortic arch. The reference anatomical structure for the subclavian artery is the anterior scalene muscle, and this can be found at the posteromedial border of this muscle or at its lateral border. The subclavian vein is a continuation of the axillary vein and extends from the border of the first rib to the medial border of the anterior scalene muscle, where it joins the internal jugular vein to form the brachiocephalic vein. The clavicle and the subclavian muscle are located anteriorly to the subclavian vein.¹

The aim of this study was to establish a neurovascular safety zone at the surgical access to the middle third of the clavicle, by means of dissection in cadavers.

Methods

Ten recently chilled cadavers were selected. Three were female and seven were male. Their mean age was 63.6 years (range: 55-73), mean height 1.67 m (1.58-1.73), mean weight 62 kg (40.4-77) and mean BMI 22.1 kg/m² (16.1-25.65). They did not present any congenital abnormalities, signs of trauma or previous surgery in the shoulders studied. All the dissections were performed by the same group of researchers. A pilot study was initially conducted on the four shoulders of two

cadavers, before data-gathering was started, in order to study and gain better knowledge of the local anatomy (Table 1).

The procedures were performed with the cadaver in a standardized horizontal dorsal decubitus position, with a pad under the ipsilateral scapula and the upper limb in neutral position. Using a surgical pen, the superficial anatomy of the clavicle and the acromioclavicular and sternoclavicular joints was marked out on the skin. A transverse incision was made in the skin along the entire length of the clavicle and the muscle layers were dissected, with exposure of the subclavian muscle (origin and insertion). Its relationship with the middle third of the clavicle was demonstrated using markers anteroinferiorly (Fig. 1).

After exposure of the muscle, the clavicle was divided into three thirds and deeper dissection of the middle third was performed. In this, the following neurovascular structures were identified: subclavian vein, upper trunk of the brachial plexus (anterior and posterior divisions) and suprascapular nerve. These structures were demarcated using colored markers and the distances to the closest point of the middle third of the clavicle was recorded using a Kingtools® 150 mm digital pachymeter (Fig. 2).

For the statistical analysis, the paired Wilcoxon test was used. The significance level adopted was 5% and the software used for the analysis was SAS version 9.2.

Results

The mean distances from the middle third of the clavicle to the suprascapular nerve, subclavian vein, upper trunk, anterior

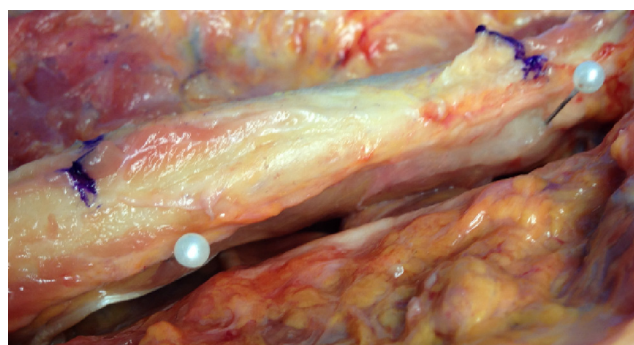


Fig. 1 – Demarcation of the middle third of the clavicle and the subclavian muscle (white markers).

Table 1 – Description of the samples, ages, heights, weights and BMI.

	Sample	Mean	Standard deviation	Median
Age (years)	10	63.6	5.5	62.5
Height (m)	10	1.67	0.06	1.68
Weight (kg)	10	62.0	11.7	66.0
BMI (kg/m ²)	10	22.1	3.5	22.9

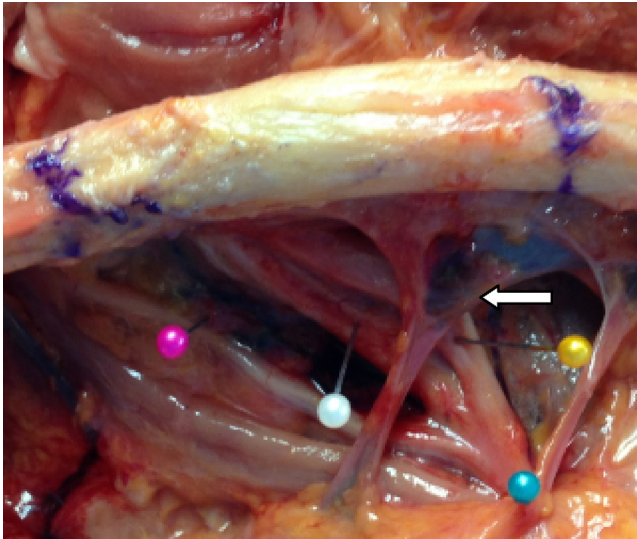


Fig. 2 – Pink marker: suprascapular nerve; green marker: upper trunk; white marker: posterior division of the upper trunk; yellow marker: anterior division of the upper trunk; white arrow: subclavian vein.

division of the upper trunk and posterior division of the upper trunk on the right side were, respectively: 15.92 cm; 10.77 cm; 23.68 cm; 14.60 cm; and 15.42 cm; and on the left side: 12.69 cm; 9.82 cm; 22.19 cm; 12.16 cm; and 13.46 cm.

Table 2 presents the results from the measurements made between the middle third of the clavicle and the neurovascular structures studied.

Discussion

The number of indications for surgical treatment of fractures of the middle third of the clavicle has increased over the years because of better understanding of the biomechanics and function of the clavicle, the greater number of prospective studies demonstrating comparative results and the modernization of synthesis materials for fixation of these fractures. Today, some types of shortening and deformities are no longer acceptable.⁴⁻⁹

According to Iannotti et al.⁶ treatment of fractures of the middle third of the clavicle through placement of a plate on its upper surface presented biomechanical advantages and facilitated surgical access. However, Kloen et al.⁷ demonstrated that iatrogenic lesions of the neurovascular structures below the clavicle occurred more frequently in these types of osteosynthesis and that the risk diminished when the plate was positioned anteroinferiorly.^{6,7}

Labrocini et al.¹⁰ demonstrated that the branches of the suprascapular nerve, which are responsible for the sensitivity on the clavicle, and the anteromedial region of the shoulder and proximal region of the chest are vulnerable in cases of fractures of the clavicle and their surgical treatment. According to Sinha et al.⁴ the structures at greatest risk of injury during osteosynthesis of the middle third of the clavicle are the subclavian vein, subclavian artery, the brachial plexus and the pulmonary pleura. According to their study, the subclavian vein was closer to the middle third of the clavicle than was the brachial plexus, with a mean distance of 12.45 mm. In our study, the right subclavian vein was at a mean distance of 10.77 mm and the left at 9.82 mm from the

Table 2 – Means, standard deviations, medians and p values of the distances between the anatomical structures and the middle third of the clavicle.

	Sample	Mean	Standard deviation	Median	p value
Right suprascapular nerve	10	15.92	5.32	15.53	
Left suprascapular nerve	10	12.69		13.02	
Difference	10	3.23	3.75	2.91	0.0273 ^a
Right subclavian vein	10	10.77	3.23	10.49	
Left subclavian vein	10	9.82	4.04	8.75	
Difference	10	0.95	2.27	1.39	0.2754
Right upper trunk	10	23.68	6.04	22.38	
Left upper trunk	10	22.19	6.41	20.10	
Difference	10	1.50	2.61	1.74	0.1309
Right anterior division	10	14.60	5.76	13.64	
Left anterior division	10	12.16	4.00	12.67	
Difference	10	2.44	2.96	2.18	0.0371 ^a
Right posterior division	10	15.42	5.16	15.39	
Left posterior division	10	13.46	3.82	13.17	
Difference	10	1.96	3.30	2.65	0.1055

^a Measured in millimeters, with statistical difference ($p < 0.05$).

middle third of the clavicle and was also the closest vascular structure.^{4,10}

According to Mouzopoulos et al.⁸ the association between fractures of the clavicle and injuries to the brachial plexus is well known and usually occurs due to high-energy supraclavicular traction. Fractures of the clavicle are associated with these events but are not the causal factor. In another study, by Della Santa et al.⁹ it was demonstrated that direct trauma of the brachial plexus caused by fragments of the clavicle occurred at low frequency (1%).^{8,9}

Jeyaseelan et al.¹¹ reported that involvement of the suprascapular nerve is a common finding in fractures of the clavicle, because this is the structure of the brachial plexus that is closest to the middle third of the clavicle. Shortening of the clavicle and mobilization of the fragments of the fracture during fixation may cause compression of the brachial plexus, due to the decreased infraclavicular space. In conservative treatment, the presence of the bone callus may also be the cause of lesions of the suprascapular nerve, due to compression. In our study, the brachial plexus structure that was closest to the middle third of the clavicle was the suprascapular nerve.¹¹

Therefore, according to the literature consulted, periclavicular neurovascular lesions are more associated with surgical iatrogenic lesions than with the trauma itself. In our study, the neurovascular structures closest to the middle third of the clavicular and therefore most susceptible to injury in this region were the suprascapular nerve and subclavian vein, respectively. During our dissections, it was also observed that the subclavian muscle provided anterosuperior protection for the adjacent neurovascular structures and that it could be used as an anatomical reference point for delimiting a "safety zone".

Conclusion

There was a statistical difference in the distances from the suprascapular nerve and the anterior division of the upper trunk, comparatively between the right and left. The neurovascular structures closest to the middle third of the clavicle were the suprascapular nerve and subclavian vein.

Conflicts of interest

The authors declare no conflicts of interest.

REFERENCES

1. Standring S. *Gray's anatomy: the anatomical basis of clinical practice*. 40th ed. New York: Churchill Livingstone; 2008.
2. Basamania CJ, Rockwood CA Jr. Fractures of the clavicle. In: Rockwood CA Jr, Matsen FA 3rd, Wirth MA, Lippitt SB, editors. *The shoulder*. 4th ed. Philadelphia: Saunders; 2009. p. 617-770.
3. Shin AY, Spinner RJ, Steinmann SP, Bishop AT. Adult traumatic brachial plexus injuries. *J Am Acad Orthop Surg*. 2005;13(6):382-96.
4. Sinha A, Edwin J, Sreeharsha B, Bhalai V, Brownson P. A radiological study to define safe zones for drilling during plating of clavicle fractures. *J Bone Joint Surg Br*. 2011;93(9):1247-52.
5. Jeray KJ. Acute midshaft clavicular fracture. *J Am Acad Orthop Surg*. 2007;15(4):239-48.
6. Iannotti MR, Crosby LA, Stafford P, Grayson G, Goulet R. Effects of plate location and selection on the stability of midshaft clavicle osteotomies: a biomechanical study. *J Shoulder Elbow Surg*. 2002;11(5):457-62.
7. Kloen P, Werner CM, Stufkens SA, Helfet DL. Anteroinferior plating of midshaft clavicle nonunions and fractures. *Oper Orthop Traumatol*. 2009;21(2):170-9.
8. Mouzopoulos G, Morakis E, Stamatakos M, Tzurbakis M. Complications associated with clavicular fracture. *Orthop Nurs*. 2009;28(5):217-24.
9. Della Santa D, Narakas A, Bonnard C. Late lesions of the brachial plexus after fracture of the clavicle. *Ann Chir Main Memb Super*. 1991;10(6):531-40.
10. Labronici PJ, Segall FS, Martins BA, Franco JS, Labronici GJ, Silva BA, et al. Fratura da clavícula – incidência de lesão do nervo supraclavicular. *Rev Bras Ortop*. 2013;48(4): 317-21.
11. Jeyaseelan L, Singh VK, Ghosh S, Sinisi M, Fox M. Iatrogenic brachial plexus injury: a complication of delayed fixation of clavicle fractures. *Bone Joint J*. 2013;95-B(1):106-10.