



Case Report

Compartment syndrome after total knee arthroplasty: regarding a clinical case[☆]



Ana Alexandra da Costa Pinheiro*, Pedro Miguel Dantas Costa Marques,
Pedro Miguel Gomes Sá, Carolina Fernandes Oliveira, Bruno Pombo Ferreira da Silva,
Cristina Maria Varino de Sousa

Unidade Local de Saúde do Alto Minho, Viana do Castelo, Portugal

ARTICLE INFO

Article history:

Received 23 June 2014

Accepted 18 August 2014

Available online 10 July 2015

Keywords:

Knee arthroplasty

Knee

Postoperative complications

ABSTRACT

Although compartment syndrome is a rare complication of total knee arthroplasty, it is one of the most devastating complications. It is defined as a situation of increased pressure within a closed osteofascial space that impairs the circulation and the functioning of the tissues inside this space, thereby leading to ischemia and tissue dysfunction. Here, a clinical case of a patient who was followed up in orthopedic outpatient consultations due to right gonarthrosis is presented. The patient had a history of arthroscopic meniscectomy and presented knee flexion of 10° before the operation, which consisted of total arthroplasty of the right knee. The operation seemed to be free from intercurrents, but the patient evolved with compartment syndrome of the ipsilateral leg after the operation. Since compartment syndrome is a true surgical emergency, early recognition and treatment of this condition through fasciotomy is crucial in order to avoid amputation, limb dysfunction, kidney failure and death. However, it may be difficult to make the diagnosis and cases may not be recognized if the cause of compartment syndrome is unusual or if the patient is under epidural analgesia and/or peripheral nerve block, which thus camouflages the main warning sign, i.e. disproportional pain. In addition, edema of the limb that underwent the intervention is common after total knee arthroplasty operations. This study presents a review of the literature and signals that the possible rarity of cases is probably due to failure to recognize this condition in a timely manner and to placing these patients in other diagnostic groups that are less likely, such as neuropraxia caused by using a tourniquet or peripheral nerve injury.

© 2014 Sociedade Brasileira de Ortopedia e Traumatologia. Published by Elsevier Editora Ltda. All rights reserved.

[☆] Work performed in the Orthopedics and Traumatology Service, Unidade Local de Saúde do Alto Minho, Viana do Castelo, Portugal.

* Corresponding author.

E-mail: ana.alexandra.pinheiro@gmail.com (A.A.d.C. Pinheiro).

<http://dx.doi.org/10.1016/j.rboe.2015.06.017>

2255-4971/© 2014 Sociedade Brasileira de Ortopedia e Traumatologia. Published by Elsevier Editora Ltda. All rights reserved.

Síndrome de compartimento após artroplastia total do joelho: a propósito de um caso clínico

R E S U M O

Palavras-chave:

Artroplastia do joelho
Joelho
Complicações pós-operatórias

Apesar de a síndrome de compartimento ser uma complicação rara da artroplastia total do joelho, essa constitui uma das complicações mais devastadoras. A síndrome de compartimento define-se como o aumento da pressão dentro de um espaço osteofascial fechado que compromete a circulação e a função dos tecidos dentro desse espaço e conduz à isquemia e à disfunção tecidual. Os autores apresentam um caso clínico de paciente seguida em consulta externa de ortopedia por gonartrose direita, com antecedentes de meniscectomia artroscópica e com flexão de 10° do joelho pré-operatório, que foi submetida a artroplastia total do joelho direito. A cirurgia aparentemente decorreu sem intercorrências e o pós-operatório evoluiu com síndrome de compartimento da perna ipsilateral. Sendo a síndrome de compartimento uma emergência cirúrgica, o seu reconhecimento e tratamento precoce por meio de fasciotomias é fulcral para evitar a amputação, disfunção do membro, insuficiência renal e morte. No entanto, o diagnóstico pode ser difícil e não reconhecido perante uma causa incomum de síndrome de compartimento. Quando o paciente está sob analgesia epidural e/ou bloqueio nervoso periférico, camufla desse modo o principal sinal de alarme, a dor desproporcional. Além disso, o edema do membro intervencionado é comum no pós-operatório de artroplastia total do joelho. Os autores revêm a literatura e alertam que a possível raridade de relatos de casos se deva ao mais provável não reconhecimento precoce dessa identidade e ao enquadramento desses doentes em outros grupos diagnósticos etiológicamente menos prováveis, como neuropraxia por uso de garrote ou lesão de nervos periféricos.

© 2014 Sociedade Brasileira de Ortopedia e Traumatologia. Publicado por Elsevier Editora Ltda. Todos os direitos reservados.

Introduction

Compartment syndrome is defined as increased pressure inside a closed osteofascial space that compromises the circulation and the functioning of the tissues within this space, thereby leading to ischemia and tissue dysfunction.¹⁻³ It is a severe complication that requires decompression fasciotomy in order to prevent tissue necrosis.

Correct early diagnosis of this entity is very important, because delay in diagnosing it is the only cause of treatment failure. The diagnosis is essentially clinical, by means of anamnesis and physical examination, and is confirmed through measuring the pressure of the compartment(s).⁴⁻⁹

Case report

The patient was a 65-year-old woman with a history of right-side arthroscopic internal meniscectomy, which was followed up through orthopedic outpatient consultations because of right-side three-compartment gonarthrosis. Before the operation, she presented severe right-knee stiffness, with flexion of 20° and maximum flexion of less than 90°.

The patient underwent right-side total knee arthroplasty (TKA) under locoregional anesthesia with subarachnoid block, which was performed in accordance with descriptions in the orthopedic literature and seemed to follow an uneventful course. The duration of the operation was 2 h and an epidural

catheter was implanted to deliver ropivacaine for postoperative analgesia. On the first day after the operation, the patient presented neurological alterations such as hypoesthesia and limitation of the mobility of the right ankle and foot. For this reason, the epidural analgesia was suspended and the bandaging of the operative wound was changed, although it had not presented abnormal tension. The right lower limb had presented good peripheral perfusion and the patient had not made any complaints about pain due to the analgesia. Because of the suspicion of a central lesion, magnetic resonance imaging (MRI) was performed on the lumbosacral spine as a matter of urgency after removal of the catheter, so as to screen for an epidural hematoma or a lumbar nerve injury, but the findings were normal. Nonetheless, administration of analgesia was started parenterally.

On the second day after the operation, the patient presented as neurologically superposed, without any vestige of motor activity below the knee. This led to the suspicion of neuropraxia of the anterior and posterior tibial nerve, with motor alterations provoked by the garrote. A postoperative control X-ray of the right knee was normal. The patient was kept under observation. On the same day, due to persistence of the hypoesthesia, pain in the proximal region of the lower leg and marked tension on the lateral face of the lower leg, the hypothesis of compartment syndrome was put forward and urgent fasciotomy was proposed, with exploration of the external popliteal sciatic nerve. The latter was explored and the anterolateral compartment of the lower leg was released. During the immediate postoperative period, hypoperfusion of

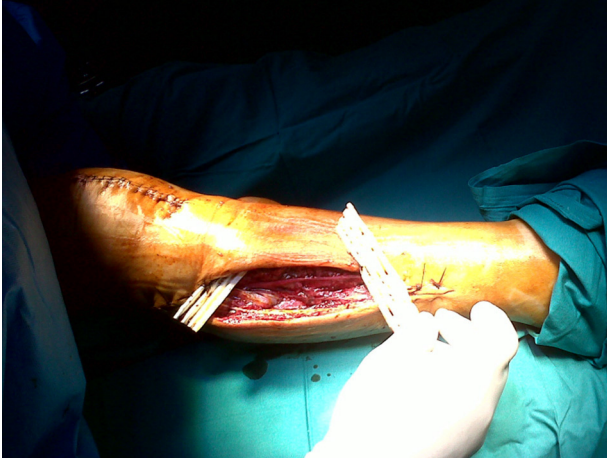


Fig. 1 – Care with the bandaging of the fasciotomy sites demonstrated the presence of necrosis of the muscles of the anterior and lateral compartments of the right leg. Consequently, progressive muscle debridement was performed.

the right lower limb was observed and fasciotomy of the four compartments of the right leg was performed. The patient underwent urgent computed tomography angiography on the right lower limb, which had normal findings and did not show any vascular lesions or space-occupying lesions. The care taken with the bandaging of the fasciotomy sites showed that there was necrosis of the muscles of the anterior and lateral compartments of the right leg, and therefore progressive muscle debridement was performed (Figs. 1-3).

Suturing of the fasciotomy sites was done progressively and no skin grafts were necessary.

On the day of hospital discharge, the patient continued to be asymptomatic in the right knee and presented mobility of 0-90°, without significant inflammatory signs. She did not present any extension strength in the ankle and toes, and had slight dorsiflexion in the ankle and second to fifth toes of the right foot. She reported having paresthesia on the lateral face

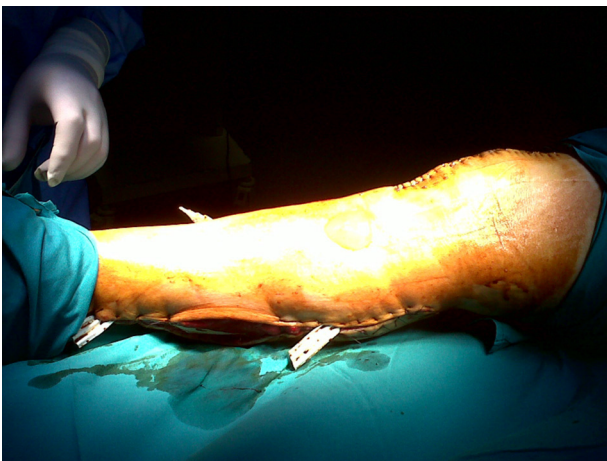


Fig. 2 – Progressive muscle debridement and care with the bandaging of the fasciotomy sites over the course of the operation.

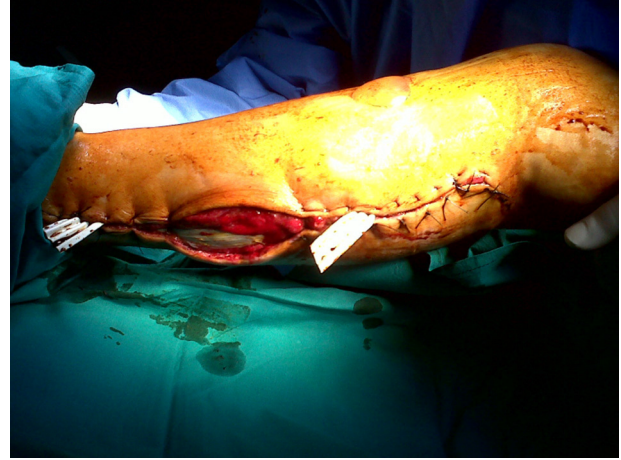

Fig. 3 – Suturing of the fasciotomy sites was performed progressively and no skin grafts were necessary.

of the lower leg and hypoesthesia on the heel, internal face of the foot and first and second toes of the right foot. Because she was walking with a hanging foot, an anti-equinus splint was prescribed. On the 40th postoperative day, the patient was walking with the aid of a frame and was using a splint. She was advised to undergo rehabilitation at a continuing care unit, with intensive physiotherapy. Two months after the operation, she was still having physiotherapy and continued to present a deficit of dorsiflexion in her right foot, with swelling of the posterior muscles of the lower leg, and was using a splint to stabilize her gait. She was being followed up as an orthopedics outpatient, with improvement of right-knee joint range of motion and walking with crutches (Figs. 4 and 5).

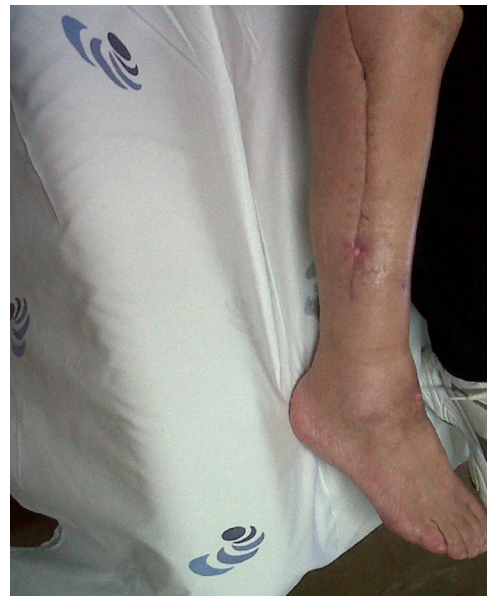

Fig. 4 – Two months after the operation, the patient was still undergoing physiotherapy and the deficits of dorsiflexion in the right foot remained, with swelling of the posterior muscles of the lower leg.

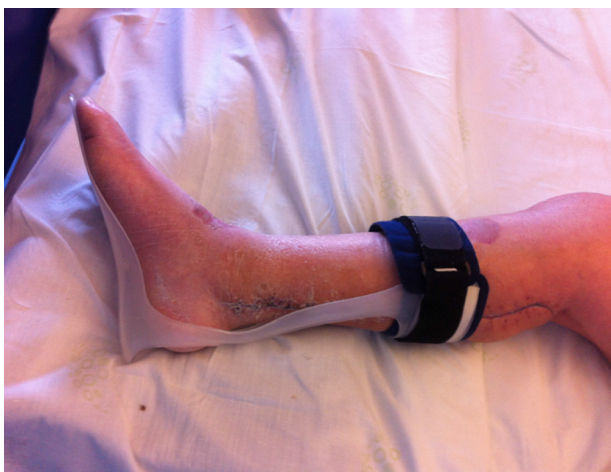

Fig. 5 – Anti-equinus splint prescribed because the patient was walking with a hanging foot.

Discussion

Compartment syndrome can develop silently over the post-operative period. Its diagnosis is essentially clinical and is characterized by incessant pain beyond the expected level for the underlying injury and by the need for more analgesia than what would be expected for this injury or surgery.

When compartment syndrome occurs subsequent to “low risk” surgery such as TKA, delayed diagnosis is common and may lead to dramatic consequences due to irreversible ischemia of the nerves and muscle tissue.¹⁰ Hence, early diagnosis and treatment of compartment syndrome is very important.

The role of fasciotomy in cases of compartment syndrome diagnosed at a late stage (more than 8 h after the operation) is questionable, since the neuromuscular deficits that become established are only rarely recovered after fasciotomy.¹¹ Even if compartment syndrome is suspected at a stage in which fasciotomy may be late, as occurred in the case described here, salvage of the compartment should be attempted. Increased pain, despite the use of analgesic medication, is the main warning sign for compartment syndrome. Epidural block, which excludes pain as an indicator of compartment syndrome, together with a low degree of suspicion, may create a disastrous combination. When local epidural anesthetics are used, it is essential that the intensity of the block should be appropriate for the expected intensity of pain, without inducing motor block.¹² However, the analgesia should not be taken to be the cause, but only a factor in the delay in the diagnosis.¹³

The diagnosis in this case was complicated because of the mechanism of the associated injury and because of the post-operative analgesia. TKA is a rare cause of acute compartment syndrome in the calf muscles and only 11 cases have been described in the literature.⁷ Although surgeons generally do not like to publish their complications, it is important for us

to do this, so as to alert the scientific community regarding the existence of compartment syndrome and so that all surgeons know how to diagnose it and treat it early on. For this reason, we presented a rare case of compartment syndrome in the lower leg (little reported in the literature) that developed after TKA had been performed.

Compartment syndrome constitutes a surgical emergency. Recognition and early treatment of this entity by means of fasciotomy is pivotal for avoiding amputation, limb dysfunction, kidney failure and death.

Nevertheless, the diagnosis may be difficult to make and may not be recognized in the light of an uncommon cause of compartment syndrome and when the patient is under analgesia.

Conflicts of interest

The authors declare no conflicts of interest.

REFERENCES

1. Cortés AM, Castrejón HAM. Síndrome compartimental en extremidades. *Conceptos actuales. Cir Gen.* 2003;25(4):342–8.
2. Wallace S, Goodman S, Smith DG. Compartment syndrome, lower extremity. *Orthopedic Surgery Trauma*; 2007. Available from: <http://www.emedicine.com/orthoped/to-pic596.htm>
3. Kahan JS, McClellan RT, Burton DS. Acute bilateral compartment syndrome of the thigh induced by exercise. A case report. *J Bone Joint Surg Am.* 1994;76(7):1068–71.
4. Shadgan B, Menon M, Sanders D, Berry G, Martin C Jr, Duffy P, et al. Current thinking about acute compartment syndrome of the lower extremity. *Can J Surg.* 2010;53(5):329–34.
5. Masquelet AC. Acute compartment syndrome of the leg: pressure measurement and fasciotomy. *Orthop Traumatol Surg Res.* 2010;96(8):913–7.
6. Tiwari A, Haq AI, Myint F, Hamilton G. Acute compartment syndromes. *Br J Surg.* 2002;89(4):397–412.
7. Lasanianos NG, Kanakaris NK, Roberts CS, Giannoudis PV. Compartment syndrome following lower limb arthroplasty: a review. *Open Orthop J.* 2011;5:181–92.
8. Haggis P, Yates P, Blakeway C, Fick D, Morgan DA, Holt M, et al. Compartment syndrome following total knee arthroplasty: a report of seven cases. *J Bone Joint Surg Br.* 2006;88(3):331–4.
9. Ashish P, Shalinder S, Prakash J. Acute non-traumatic compartment syndrome of anterior compartment of leg; an unusual presentation: a case report. *Inj Extra.* 2009;40(1):68–9.
10. Whitesides TE, Heckman MM. Acute compartment syndrome: update on diagnosis and treatment. *J Am Acad Orthop Surg.* 1996;4(4):209–18.
11. Finkelstein JA, Hunter GA, Hu RW. Lower limb compartment syndrome: course after delayed fasciotomy. *J Trauma.* 1996;40(3):342–4.
12. Mumtaz FH, Chew H, Gelister JS. Lower limb compartment syndrome associated with the lithotomy position: concepts and perspectives for the urologist. *BJU Int.* 2002;90(8):792–9.
13. Tang WM, Chiu KY. Silent compartment syndrome complicating total knee arthroplasty: continuous epidural anesthesia masked the pain. *J Arthroplasty.* 2000;15(2):241–3.