



Original article

Are the good functional results from arthroscopic repair of massive rotator cuff injuries maintained over the long term?[☆]



Alberto Naoki Miyazaki*, Pedro Doneux Santos, Luciana Andrade da Silva*,
Guilherme do Val Sella, Sérgio Luiz Checchia, Alexandre Maris Yonamine

Faculdade de Ciências Médicas da Santa Casa de São Paulo, São Paulo, SP, Brazil

ARTICLE INFO

Article history:

Received 12 February 2015

Accepted 19 February 2015

Available online 30 December 2015

Keywords:

Rotator cuff

Arthroscopy/method

Evaluation studies

ABSTRACT

Objective: To evaluate whether the good and excellent functional results from arthroscopic repair of massive rotator cuff tears are maintained over the long term.

Methods: From the sample of the study conducted by our group in 2006, in which we evaluated the functional results from arthroscopic repair of massive rotator cuff tears, 35 patients were reassessed, 8 years after the first evaluation. The inclusion criteria were that these patients with massive rotator cuff tears operated by means of an arthroscopic technique, who participated in the previous study and achieved good or excellent outcomes according to the UCLA criteria. Patients whose results were not good or excellent in the first evaluation according to the UCLA criteria were excluded.

Results: Among the 35 patients reassessed, 91% of them continued to present good and excellent results (40% excellent and 51% good), while 3% presented fair results and 6% poor results. The time interval between the first and second evaluations was 8 years and the minimum length of follow-up since the immediate postoperative period was 9 years (range: 9–17 years), with an average of 11.4 years.

Conclusion: The good and excellent results from arthroscopic repair of massive rotator cuff tears were mostly maintained (91%), with the same level of function and satisfaction, even though 8 years had passed since the first assessment, with a follow-up period averaging 11.4 years.

© 2015 Sociedade Brasileira de Ortopedia e Traumatologia. Published by Elsevier Editora Ltda. All rights reserved.

[☆] Work performed in the Department of Orthopedics and Traumatology, Faculdade de Ciências Médicas da Santa Casa de São Paulo (DOT-FCMSCSP), São Paulo, SP, Brazil.

* Corresponding authors.

E-mails: lucalu01@me.com (A.N. Miyazaki), amiyazaki@uol.com.br (L.A. da Silva).

<http://dx.doi.org/10.1016/j.rboe.2015.12.009>

2255-4971/© 2015 Sociedade Brasileira de Ortopedia e Traumatologia. Published by Elsevier Editora Ltda. All rights reserved.

Os bons resultados funcionais do reparo artroscópico das lesões extensas do manguito rotador mantêm-se em longo prazo?

R E S U M O

Palavras-chave:

Bainha rotadora
Artroscopia/método
Estudos de avaliação

Objetivos: Avaliar se os bons e excelentes resultados funcionais do reparo artroscópico das lesões extensas do manguito rotador se mantêm em longo prazo.

Métodos: A partir da amostra do trabalho feito por nosso grupo em 2006, no qual avaliamos os resultados funcionais do reparo artroscópico das lesões extensas do manguito rotador, foram reavaliados 35 pacientes, totalizando oito anos após a primeira avaliação. Critérios de inclusão: pacientes com lesão extensa do manguito rotador operados por técnica artroscópica que participaram do trabalho anterior e que obtiveram bons ou excelentes resultados segundo os critérios da UCLA. Critérios de exclusão: pacientes que não obtiveram resultado bom ou excelente segundo os critérios da UCLA na primeira avaliação.

Resultados: Dos 35 pacientes reavaliados, 91% mantiveram-se com bons e excelentes resultados (40% excelentes, 51% bons), 3% regulares e 6% ruins. O intervalo de tempo entre a primeira e a segunda avaliação foi de oito anos, o tempo de seguimento mínimo desde o pós-operatório imediato foi de nove anos, variou entre nove e 17 anos com média de 11,4.

Conclusão: Os bons e excelentes resultados do reparo artroscópico das lesões extensas do manguito rotador mantiveram-se em sua maioria (91%) com o mesmo nível de função e satisfação mesmo após oito anos de sua primeira avaliação, totalizando tempo de seguimento com média de 11,4 anos.

© 2015 Sociedade Brasileira de Ortopedia e Traumatologia. Publicado por Elsevier Editora Ltda. Todos os direitos reservados.

Introduction

Rotator cuff injuries are considered to be one of the commonest diseases of the shoulder.¹ Their incidence is greatest among women in the age group between 55 and 60 years¹ and they may have either traumatic or degenerative origin.^{2,3} They can be classified according to their size as small, medium, large or extensive.⁴ When small injuries are not properly treated, they may evolve to extensive injuries that are a challenge to treat, even for experienced surgeons.

When surgery is indicated for treating extensive rotator cuff injuries, this involves great technical complexity because of the poor quality and/or retraction of the tendon, which adds difficulty to the repair.⁵⁻⁸

Through improvements in arthroscopic techniques, it has become possible to treat these injuries less invasively, without aggression to the deltoid musculature. Earlier rehabilitation and a lower complication rate have thus also become possible.⁹⁻¹² Despite the high rerupture rate,¹³ arthroscopic repair of extensive rotator cuff injuries leads to good functional results with a high satisfaction rate.¹⁴⁻¹⁶

However, it needs to be asked whether these good results would be maintained over the long term. In the literature, the number of studies showing good results from this technique, with long-term follow-up, remains small.^{5,13,17}

In 2006, our group evaluated 61 cases of extensive rotator cuff injuries that underwent arthroscopic repair. According to the UCLA criteria, 89% of the results were good or excellent.^{14,18}

With the aim of making a long-term assessment of our clinical results 8 years after the operations, we proposed to

reevaluate the same group of patients that we evaluated in 2006, to ascertain whether the results had been maintained.

Sample and methods

In August 2006, our institution's shoulder and elbow surgery group evaluated the results from treating 61 patients with extensive rotator cuff injuries who had undergone operations using an arthroscopic technique.¹⁴ From that group, the patients whose results were good or excellent were selected in order to assess whether these results were maintained 8 years later. Therefore, the inclusion criteria were that the patients needed to have presented extensive rotator cuff injuries that were treated arthroscopically and were included in the previous study, and that the results obtained were good or excellent according to the UCLA criteria.¹⁸ Patients whose results were not good or excellent at the first evaluation and those who could not be contacted for the reevaluation were excluded. With these criteria, out of the initial group of 61 patients, 53 who had been classified as having good or excellent results were included in the present study. Among these, it was only possible to reevaluate 35. The sample loss (18 patients; 33%) was composed of 15 patients who could not be located, two deaths and one patient who refused to take part in the investigation (Table 1).

The length of time between the first evaluation and the reevaluation was 8 years. The minimum length of follow-up since the postoperative period was 9 years, with a range from 9 to 17 years (mean of 11.4 years) (Table 1).

Among the 35 patients, 18 were male (51%). The patients' mean age at the time of the reevaluation was 75.8 years, with

Table 1 – Clinical data on the patients.

Case	Sex	Dom	Age	Postop mob	RER	Follow	UCLA
1	M	+	72	130/50/T7	+	204	32
2	M	+	68	110/60/L1		120	17
3	M	+	63	160/60/T7		123	35
4	F	+	75	130/60/T10		145	33
5	M	+	74	160/60/T7		130	34
6	M	+	52	150/40/T9		119	34
7	M	+	72	150/60/T5		156	34
8	M		75	120/45/L1		114	29
9	M	+	76	120/60/T10		152	29
10	F	+	71	160/70/T7		120	32
11	M	+	83	130/40/L1		109	34
12	F		82	130/45/L1		141	30
13	M	+	84	140/45/T7		171	35
14	F	+	87	120/45/T12		126	34
15	F	+	77	120/60/L1		143	33
16	F	+	85	130/60/T12		136	33
17	M		71	140/50/T10		130	34
18	F	+	69	100/45/L1	+	122	28
19	M	+	77	150/80/T12		117	35
20	F	+	93	130/30/T10		170	25
21	F		80	120/45/T10		161	32
22	F	+	79	130/30/T10		122	34
23	F	+	77	140/60/L1		149	33
24	F	+	82	120/45/L1		114	30
25	F	+	67	150/45/T12		123	32
26	F	+	85	110/45/T12		134	28
27	F		85	110/45/T12		122	29
28	F		85	140/45/T12		120	31
29	M	+	79	140/40/T12		157	32
30	M	+	64	130/60/T10		176	34
31	M	+	67	140/30/L1		109	29
32	M	+	70	120/60/T12	+	135	19
33	M		69	150/40/T10		157	35
34	F	+	83	140/45/T12		152	34
35	M		76	130/50/L2		126	34

Source: Hospital's medical files.

M, male; F, female; Dom, dominant side; Postop mob, postoperative mobility; RER, rerupture; Follow, follow-up in months.

a range from 52 to 93 years. The dominant side was affected in 28 cases (80%). Among the injuries, 30 (85%) resulted from trauma or physical force on the shoulder (Table 1).

Among the 35 patients, 27 (77%) had injuries that fully or partially compromised the insertion of the tendon of the subscapularis muscle, along with injury to the tendons of the supraspinatus and infraspinatus. Acromioplasty was performed on 30 patients (85%) and resection of the distal extremity of the clavicle on seven (20%). In relation to the long head of the biceps brachii, tenotomy followed by tenodesis was performed in 14 cases, tenotomy alone in five cases and the tendon was not in the bicipital groove in another five cases.

In all the patients, suturing of the lesion was performed by means of anchors. The number of anchors used ranged from two to five, with a mean of three. The number of stitches used ranged from five to ten, with a mean of seven. In 31 cases, tendon-to-tendon stitches were also used, in order to bring the edges of the lesion together, before suturing to the bone. A mean of two tendon-to-tendon stitches was used, with a range from one to four stitches.

Between May and October 2014, all the patients were reassessed clinically by means of the University of California at Los Angeles (UCLA) method,¹⁸ and their joint mobility was reevaluated using the parameters described by Hawkins and Bokus¹⁹ (Table 1).

To evaluate whether the group of patients studied was different to the group of patients lost (around 33% of the sample), we compared the variables of sex, age and dominance between the two groups in order to diminish the bias in the results. To compare the variables of sex and dominance, Fisher's exact test was used, and to compare the mean ages, Student's t test was used. The assumption of equal variances was made, given that the adherence of age to normal distribution in the two groups was tested by means of the Anderson-Darling test and equality of variance by the F test.

After the present sample had been validated, shoulder range of motion was compared in situations of two groups by means of the Mann-Whitney nonparametric test on differences in means. When there were three or more groups, Kruskal-Wallis nonparametric analysis of variance was used. To compare the UCLA scores,¹⁸ divided between a good and

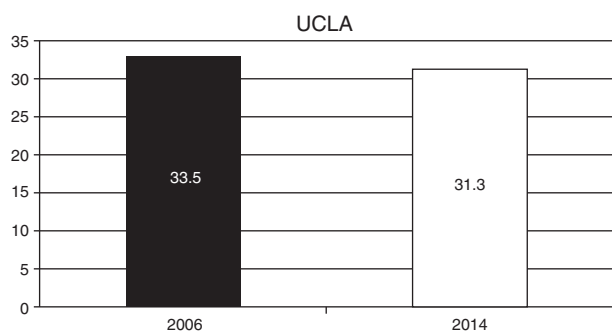


Fig. 1 – Functional evaluation according to the UCLA criteria: change in mean values from 2006 to 2014.

excellent group and a fair and poor group, Fisher's exact test of independence was used.

All the tests were performed with a significance level of 5% ($p \geq 0.05$).

This study was approved by our hospital's ethics committee under the number CAAE 3091491.4.4000.5479.

Results

In validating the sample, the group without follow-up was composed of 18 patients and the group investigated was composed of 35 patients. There was no difference in the distributions of sex ($p = 0.773$) or dominance ($p = 0.464$) between the two groups. Making the assumptions that there was adherence to normal distribution for the variable of age in the two groups ($p = 0.619$ and $p = 0.631$) and that there was equality of variance ($p = 0.569$), Student's *t* test did not reject the hypothesis of equality between the mean ages of the two groups ($p = 0.162$). Thus, the sample was considered to be validated.

In reassessing these 35 patients using the UCLA criteria,¹⁸ we obtained a mean score of 31.31 (range: 17–35) (Fig. 1; Table 1). We found that 40% of the results were excellent, 51% good, 3% fair and 6% poor. Worsening of the UCLA result¹⁸ was only observed in 9% of the cases. The mean range of motion was 132° for elevation (range: 100–160°), 50° for lateral rotation (range: 30–70°) and T10 for medial rotation (range: T7 to L2). Rupture was observed in three cases: two patients who maintained good or excellent results and one who presented worsening (Table 1). The patients who had undergone acromioplasty presented better results according to the UCLA criteria¹⁸ than those of patients who had not undergone this procedure ($p = 0.02$).

Discussion

In the literature, we found some studies on arthroscopic repair of extensive rotator cuff injuries with short-term results that were encouraging. Jones and Savoie¹⁶ retrospectively evaluated 50 cases of large and extensive injuries that were repaired using an arthroscopic technique with a mean length of follow-up of 32 months. They obtained a satisfaction rate of 98% and mean score of 32.7 using the UCLA method, and 88% of their patients were classified as having good or excellent results.¹⁶

Bennett¹⁵ evaluated 37 cases with a mean follow-up of 3.2 years, in which 78% of the injuries were completely repaired, and obtained a mean ASES score of 77 for injuries of posterosuperior pattern and 85 for injuries of anterosuperior pattern. In 2009, we published a series of 61 cases of extensive rotator cuff injuries with a mean follow-up of 36 months and found that 89% of the results were good or excellent, according to the UCLA method.^{14,18}

More recently, Denard et al.⁵ conducted a long-term evaluation on 126 cases with a minimum follow-up of 5 years and mean of 8.2 years and found that 78% of the results were good or excellent, according to the UCLA method. We found that 91% of the results that had been considered to be good or excellent according to the UCLA method were maintained.¹⁸ Our results also showed favourable outcomes from using the arthroscopic technique, and showed that the good and excellent results were maintained, even for long times after the first evaluation.

In relation to mobility, no significant diminution of the range of motion was observed, either for elevation or for lateral and medial rotation. No difference regarding the functional results was observed in comparing traumatic and nontraumatic causes of the injuries. The number of anchors used did not influence the results and neither did the different approaches used for the long head of the biceps.

The patients who underwent acromioplasty achieved better results according to the UCLA method,¹⁸ in relation to those who did not undergo this procedure ($p = 0.029$). This was very likely because the latter cases were of greater severity and the surgeon decided not to perform acromioplasty because of the high probability of rerupture.²⁰ We found that there was worsening of the functional results in only three patients, and the explanations for this may have been the fact that one of them was a long-term smoker (case 2), another practiced sports frequently (case 32) and the third suffered worsening of preexisting comorbidities (case 20). We found that in some studies, social habits such as smoking and occupational activities had a negative influence on tendon healing.²¹

The number of cases of rerupture diagnosed in the present study was very small, which was discordant with findings in the literature. This was probably because we did not routinely perform magnetic resonance imaging on the shoulders of asymptomatic patients.²² However, like Gerber et al.,²³ Jost et al.,²⁴ and Mellado et al.,²⁵ we believe that rerupture of repaired tendons is not necessarily associated with poor clinical results. This was seen in our case 1, which despite rerupture observed on shoulder magnetic resonance imaging, continued to present an excellent functional result (Table 1).

One limiting factor of the present study was our loss of 33% of the sample, which may have led to some form of bias in the results. However, we took the precaution of comparing the samples (studied versus lost) through statistical tests and observed that there was no heterogeneity between these two groups.

Conclusion

The arthroscopic technique was shown to be effective in treating extensive rotator cuff injuries, even over the long term.

Among the group of 35 patients with good or excellent results from the arthroscopic repair, most of them (91%) maintained the same level of function and satisfaction over the entire period, with a mean of 11.4 years.

Conflicts of interest

The authors declare no conflicts of interest.

REFERENCES

- White JJ, Titchener AG, Fakis A, Tambe AA, Hubbard RB, Clark DI. An epidemiological study of rotator cuff pathology using The Health Improvement Network database. *Bone Joint J.* 2014;96-B(3):350-3.
- Fukuda H. Partial thickness rotator cuff tears: a modern view on Codman's classic. *J Shoulder Elbow Surg.* 2000;9(2):163-8.
- Sorensen AK, Bak K, Krarup AL, Thune CH, Nygaard M, Jorgensen U, et al. Acute rotator cuff tear: do we miss the early diagnosis? A prospective study showing a high incidence of rotator cuff tears after shoulder trauma. *J Shoulder Elbow Surg.* 2007;16(2):174-80.
- DeOrto JK, Cofield RH. Results of a second attempt at surgical repair of a failed initial rotator cuff repair. *J Bone Joint Surg Am.* 1984;66(4):563-77.
- Denard PJ, Jiwani AZ, Lädermann A, Burkhart SS. Long-term outcome of arthroscopic massive rotator cuff repair: the importance of double-row fixation. *Arthroscopy.* 2012;28(7):909-15.
- Gerber C, Krushell RJ. Isolated rupture of the tendon of the subscapularis muscle: clinical features in 16 cases. *J Bone Joint Surg Br.* 1991;73(3):389-94.
- Koester MC, Dunn WR, Kuhn JE, Spindler KP. The efficacy of subacromial corticosteroid injection in the treatment of rotator cuff disease: a systematic review. *J Am Acad Orthop Surg.* 2007;15(1):3-11.
- Nho SJ, Yadav H, Shindle MK, Macgillivray JD. Rotator cuff degeneration: etiology and pathogenesis. *Am J Sports Med.* 2008;36(5):987-93.
- Gartsman GM, Khan M, Hammerman SM. Arthroscopic repair of full-thickness tears of the rotator cuff. *J Bone Joint Surg Am.* 1998;80(6):832-40.
- Jost B, Pfirrmann CW, Gerber C, Switzerland Z. Clinical outcome after structural failure of rotator cuff repairs. *J Bone Joint Surg Am.* 2000;82(3):304-14.
- Tauro JC. Arthroscopic rotator cuff repair: analysis of technique and results at 2- and 3-year follow-up. *Arthroscopy.* 1998;14(1):45-51.
- Checchia SL, Doneux PS, Miyazaki AN, Fregoneze M, Silva AL, Ishi M, et al. Avaliação dos resultados obtidos na reparação artroscópica das lesões do manguito rotador. *Rev Bras Ortop.* 2005;40(5):229-38.
- Galatz LM, Ball CM, Teefey SA, Middleton WD, Yamaguchi K. The outcome and repair integrity of completely arthroscopically repaired large and massive rotator cuff tears. *J Bone Joint Surg Am.* 2004;86(2):219-24.
- Miyazaki AN, Fregoneze M, Doneux PS, Silva LA, Pinto ECM, Ortiz RT, et al. Lesões extensas do manguito rotador: avaliação dos resultados do reparo artroscópico. *Rev Bras Ortop.* 2009;44(2):148-52.
- Bennett WF. Arthroscopic repair of massive rotator cuff tears: a prospective cohort with 2- and 4-year follow-up. *Arthroscopy.* 2003;19(4):380-90.
- Jones CK, Savoie FH. Arthroscopic repair of large and massive rotator cuff tears. *Arthroscopy.* 2003;19(6):564-71.
- Paxton ES, Teefey SA, Dahiya N, Keener JD, Yamaguchi K, Galatz LM. Clinical and radiographic outcomes of failed repairs of large or massive rotator cuff tears: minimum ten-year follow-up. *J Bone Joint Surg Am.* 2013;95(7):627-32.
- Ellman H, Hunker G, Bayer M. Repair of the rotator cuff. End result study of factors influencing reconstruction. *J Bone Joint Surg Am.* 1986;68(8):1136-44.
- Hawkins RJ, Bokos DJ. Clinical evaluation of shoulder problems. In: Rockwood CA Jr, Matsen FA 3rd, editors. *The shoulder.* 2nd ed. Philadelphia: Saunders; 1998. p. 175-80.
- Flatow EL, Weinstein DM, Duralde XA, Compito CA, Pollock RG, Bigliani LU. Coracoacromial ligament preservation in rotator cuff surgery. *J Shoulder Elbow Surg.* 1994; Suppl. 3:S73.
- Carbone S, Gumina S, Arceri V, Campagna V, Fagnani C, Postacchini F. The impact of preoperative smoking habit on rotator cuff tear: cigarette smoking influences rotator cuff tear sizes. *J Shoulder Elbow Surg.* 2012;21(1):56-60.
- Boileau P, Baque F, Valerio L, Ahrens P, Chuinard C, Trojani C. Isolated arthroscopic biceps tenotomy or tenodesis improves symptoms in patients with massive irreparable rotator cuff tears. *J Bone Joint Surg Am.* 2007;89(4):747-57.
- Gerber C, Fuchs B, Hodier J. The results of repair of massive tears of the rotator cuff. *J Bone Joint Surg Am.* 2000;82(4):505-15.
- Jost B, Zumstein M, Pfirrmann CW, Gerber C. Long-term outcome after structural failure of rotator cuff repairs. *J Bone Joint Surg Am.* 2006;88(3):472-9.
- Mellado JM, Calmet J, Olona M, Esteve C, Camins A, Pérez Del Palomar L, et al. Surgically repaired massive rotator cuff tears: MRI of tendon integrity, muscle fatty degeneration, and muscle atrophy correlated with intraoperative and clinical findings. *AJR Am J Roentgenol.* 2005;184(5):1456-63.