



## Case Report

# Radial head fracture associated with posterior interosseous nerve injury<sup>☆</sup>



Bernardo Barcellos Terra\*, Tannus Jorge Sassine, Guilherme de Freitas Lima, Leandro Marano Rodrigues, David Victoria Hoffmann Padua, Anderson de Nadai

Santa Casa de Misericórdia de Vitória, Departamento de Ortopedia e Traumatologia, Vitória, ES, Brazil

### ARTICLE INFO

#### Article history:

Received 4 November 2015

Accepted 1 December 2015

Available online 15 October 2016

#### Keywords:

Radial head fractures

Radial nerve

Hematoma

### ABSTRACT

Fractures of the radial head and radial neck correspond to 1.7–5.4% of all fractures and approximately 30% may present associated injuries. In the literature, there are few reports of radial head fracture with posterior interosseous nerve injury. This study aimed to report a case of radial head fracture associated with posterior interosseous nerve injury.

*Case report:* A male patient, aged 42 years, sought medical care after falling from a skateboard. The patient related pain and limitation of movement in the right elbow and difficulty to extend the fingers of the right hand. During physical examination, thumb and fingers extension deficit was observed. The wrist extension showed a slight radial deviation. After imaging, it became evident that the patient had a fracture of the radial head that was classified as grade III in the Mason classification. The patient underwent fracture fixation; at the first postoperative day, thumb and fingers extension was observed. Although rare, posterior interosseous nerve branch injury may be associated with radial head fractures. In the present case, the authors believe that neuropraxia occurred as a result of the fracture hematoma and edema.

© 2016 Sociedade Brasileira de Ortopedia e Traumatologia. Published by Elsevier Editora Ltda. This is an open access article under the CC BY-NC-ND license (<http://creativecommons.org/licenses/by-nc-nd/4.0/>).

### Fratura da cabeça do rádio associada a lesão do nervo interósseo posterior

#### RESUMO

As fraturas da cabeça e do colo do rádio correspondem a 1,7% a 5,4% de todas as fraturas e 30% podem apresentar lesões associadas. Na literatura existem poucos casos descritos de fratura da cabeça do rádio com lesão do nervo interósseo posterior. O objetivo deste trabalho é relatar um caso de fratura da cabeça do rádio associada a lesão do nervo interósseo posterior (NIP).

#### Palavras-chave:

Fraturas do rádio

Nervo radial

Hematoma

<sup>☆</sup> Study conducted at the Santa Casa de Misericórdia de Vitória, Departamento de Ortopedia e Traumatologia, Vitória, ES, Brazil.

\* Corresponding author.

E-mail: [bernardomed@hotmail.com](mailto:bernardomed@hotmail.com) (B.B. Terra).

<http://dx.doi.org/10.1016/j.rboe.2016.10.002>

2255-4971/© 2016 Sociedade Brasileira de Ortopedia e Traumatologia. Published by Elsevier Editora Ltda. This is an open access article under the CC BY-NC-ND license (<http://creativecommons.org/licenses/by-nc-nd/4.0/>).

*Relato de caso:* Paciente masculino, 42 anos, procurou atendimento médico após queda de skate. Relatava dor e limitação de movimento do cotovelo direito, bem como dificuldade de estender os dedos da mão ipsilateral. Durante o exame físico, evidenciou-se déficit de extensão do polegar e dos dedos da mão. A extensão do punho apresentava um leve desvio radial. Após exames de imagem, ficou evidenciado que o paciente apresentava uma fratura da cabeça do rádio tipo grau III de Mason. O paciente foi submetido à fixação da fratura; no primeiro dia do pós-operatório notou-se o retorno da extensão do polegar e dos dedos da mão. Apesar de rara, a lesão do ramo interósseo posterior pode estar associada a fraturas da cabeça do rádio. No presente caso, acredita-se que a neuropraxia se deu em decorrência do hematoma e do edema fraturário.

© 2016 Sociedade Brasileira de Ortopedia e Traumatologia. Publicado por Elsevier Editora Ltda. Este é um artigo Open Access sob uma licença CC BY-NC-ND (<http://creativecommons.org/licenses/by-nc-nd/4.0/>).

## Introduction

Fractures of the radial head and neck correspond to 1.7–5.4% of all fractures and around 33% of all elbow fractures; almost 30% have associated injuries.<sup>1</sup>

The incidence of associated injuries increases with the severity of the fracture, ranging from 20% in cases of fractures without deviation to 80% in multifragmentary fractures.<sup>1,2</sup>

The association with neurologic injury is rare, and it may occur mainly in fractures with anterior deviation, Monteggia fracture-dislocations, and open gun shot fractures. In the literature, there are few reports of radial head fracture with posterior interosseous nerve injury.<sup>2-4</sup>

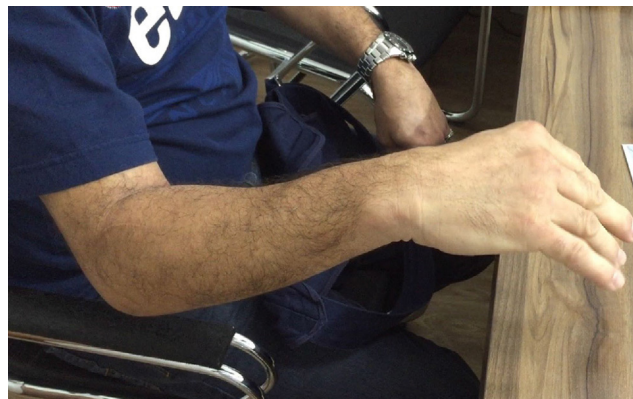This study aimed to report a case of radial head fracture associated with posterior interosseous nerve (PIN) injury.

## Case report

Male patient, aged 42 years, without comorbidities, sought medical care after a skateboard fall. He reported pain and range of motion impairment in the right elbow, as well as difficulty in extending the fingers of the ipsilateral hand.

On physical examination, edema of the lateral aspect of the elbow was observed, without pain or ecchymosis on the medial region; limited range of motion (ROM) was observed for both flexion-extension and pronosupination. The neurovascular examination showed extension deficit of fingers at the metacarpophalangeal joint level, as well as abduction and extension deficit of the thumb (Fig. 1). The patient also presented radial deviation during wrist extension. He did not have sensitive alterations; the neurological examination of median and ulnar nerves was normal. Peripheral pulses and perfusion were unaltered.

Elbow radiographs were initially requested and a Mason type III radial head fracture was observed, with an anteriorly deflected fragment consisting of 40% of the radial head area (Fig. 2). To better understand and visualize the fracture, a CT scan of the elbow was performed and associated fractures were observed (Figs. 3 and 4). Given the fracture pattern and neurological deficit, surgical treatment was chosen.

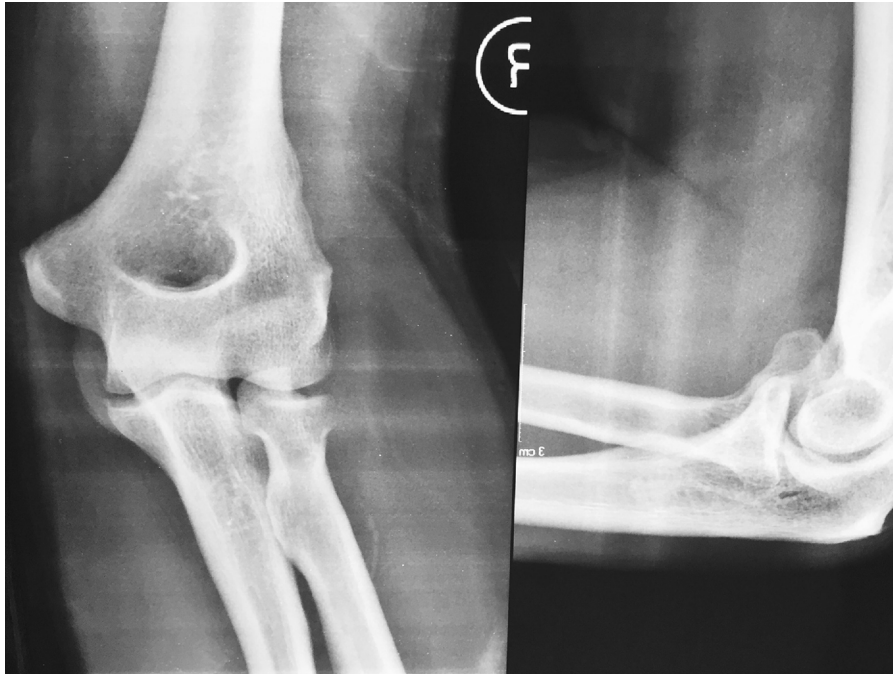


**Fig. 1 – Photograph of the patient showing extension of the fingers at the level of the metacarpophalangeal joints disability.**

## Surgical technique

A lateral Kocher approach was used, whereby the elbow joint is exposed between the anconeus and the extensor carpi ulnaris muscles.<sup>5</sup> The joint capsule was opened with the forearm in pronation, through which a large amount of the hematoma was drained. No injury or instability signs were observed in the lateral ligament complex. After irrigating the joint, it was observed that there was no avulsion of the anterior capsule, but a chondral injury was observed in the capitellum, and the radial head fragment was in anterior position. Anatomical reduction of the radial head fracture was performed, with temporary fixation with Kirschner wires to aid permanent fixation with two 2.7-mm screws using interfragmentary compression technique. The joint capsule and the muscle interval were sutured. The authors chose not to explore the nerve, as the literature reports that the posterior interosseous nerve injuries are usually due to indirect nerve compression by the anterior fragment of the radial head or by the joint hematoma.<sup>1</sup>

An axillary-palmar plaster splint was placed in the neutral position to prevent pronosupination for three weeks. After this period, assisted passive motion was initiated, followed by active movement; muscle strengthening was initiated two months after surgery.



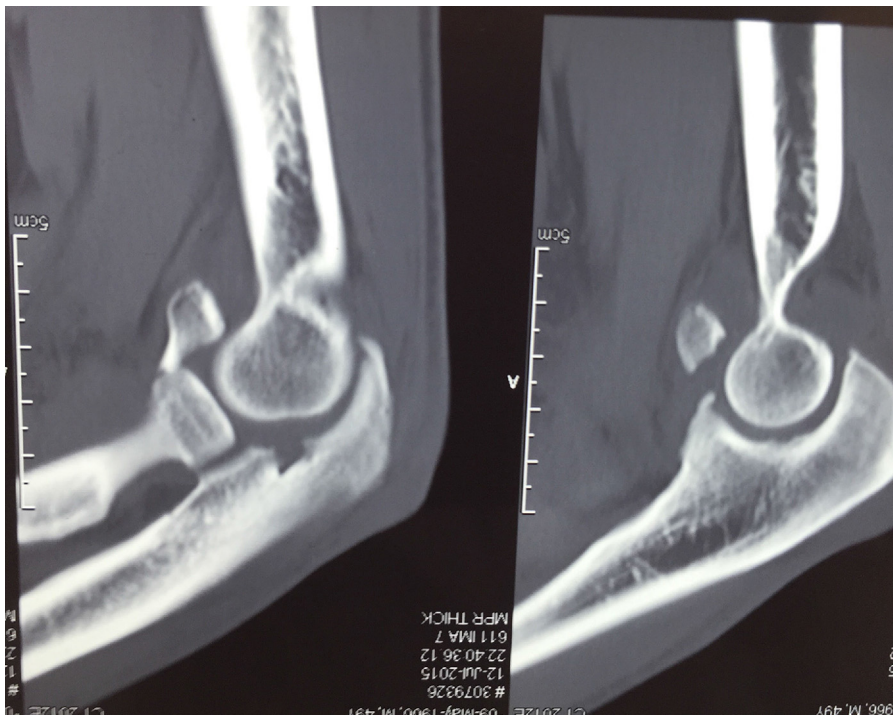
**Fig. 2 – Radiograph in AP and lateral views showing the radial head fracture and anterior displacement of the fragment.**

In the second day after surgery, normal posterior interosseous nerve function was observed, with full extension of the fingers and normal function of the thumb.

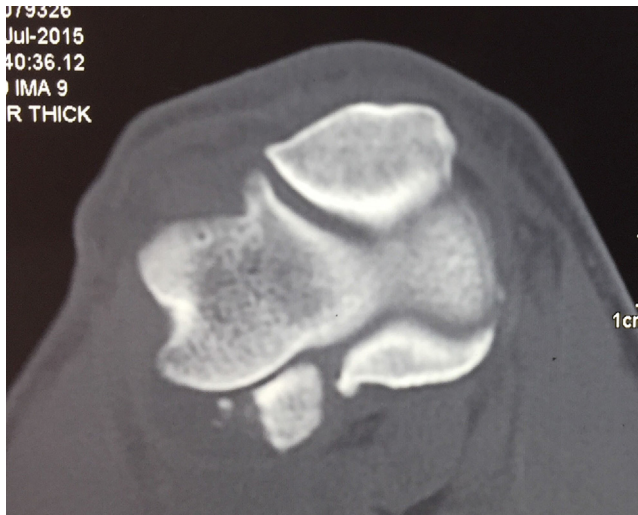Three months after surgery (Figs. 5 and 6), the patient was completely asymptomatic, with ROM in flexion-extension of 0–140 degrees and 90–80 degrees of pronosupination. Radiographs showed complete fracture healing (Figs. 7 and 8).

## Discussion

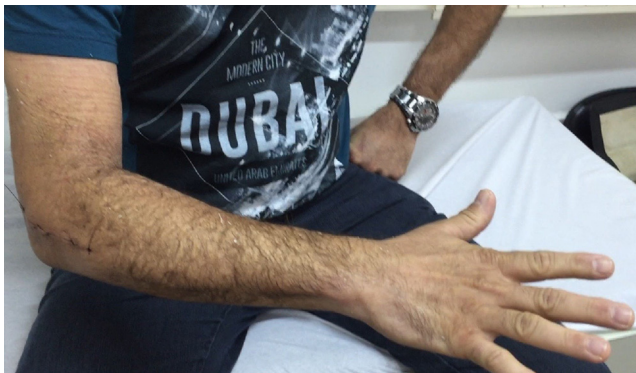The radial nerve originates from the posterior cord of the brachial plexus along with the axillary nerve, with its fibers originating in C6, C7, and C8 roots, and sometimes, T1; it is majorly a motor nerve. The radial nerve is responsible for the



**Fig. 3 – Sagittal plane CT scan showing the radial head fracture and anterior displacement of the fragment.**



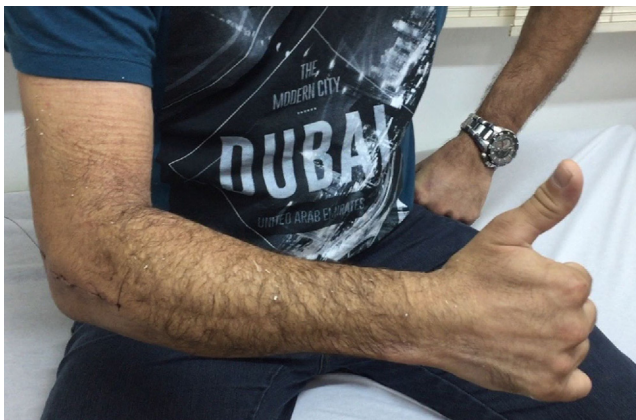**Fig. 4 – CT scan showing the radial head fracture.**



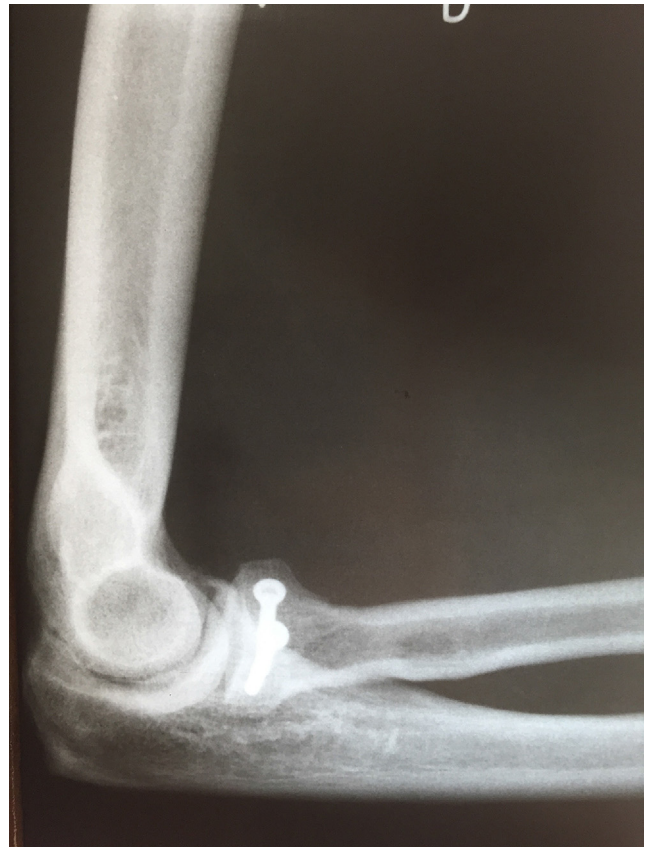**Fig. 5 – Patient on the fifth postoperative day. Complete metacarpophalangeal joint extension is observed.**

innervation of the triceps, anconeus, extensor carpi radialis longus and brevis muscles.<sup>6-8</sup>

The PIN is a motor branch of the radial nerve; it has six sub-branches, which are responsible for the innervation of the extensor digitorum communis, extensor indicis proprius, extensor pollicis brevis and longus, abductor pollicis longus,



**Fig. 6 – Patient on the fifth postoperative day. Complete thumb extension and abduction are observed.**

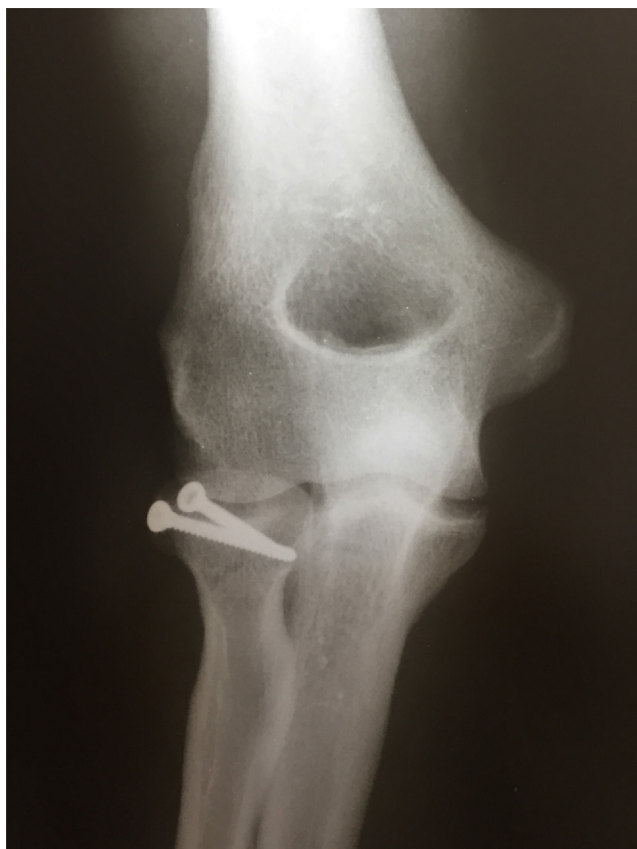

**Fig. 7 – Postoperative lateral view elbow radiograph in showing the fixation of the head fracture with two micro fragment screws.**

supinator, and extensor carpi ulnaris muscles. The branch to the supinator muscle emerges before the nerve enters the arcade of Frohse, and the other branches emerge afterwards.<sup>6</sup> Due to this subdivisions, Spinner<sup>6</sup> divided PIN compression into two types: type I, in which all branches are compressed, and type II, in which the isolated compression of a branch may occur.

The diagnosis of neurological injuries is clinical, being a part of the orthopedic physical examination. Upon examination, the present patient showed active wrist extension with radial deviation, since the radial wrist extensors are innervated by the radial nerve, but was unable to extend the fingers and thumb, demonstrating involvement of the PIN, which is responsible for the innervation of the extensor digitorum communis, extensor indicis proprius, extensor pollicis brevis and longus, abductor pollicis longus, and the extensor carpi ulnaris.

Neuropraxia of the interosseous posterior branch of the radial nerve has been reported in fractures of the proximal third of the radius, elbow fracture-dislocations (Monteggia), and fractures due to firearm injuries, as well as compression syndromes at the level of the arcade of Frohse, iatrogenic injuries in surgical approaches, elbow arthroscopy, and rheumatoid arthritis.<sup>5,7,9,10</sup> Joint swelling caused by undisplaced fracture of the radial head may lead to compression of the PIN.<sup>10</sup> In the present case, the authors believe that the



**Fig. 8 – Postoperative elbow AP radiograph showing the fixation of the radial head fracture with two micro fragment screws.**

temporary PIN dysfunction was due to compression by both the intra-articular hematoma and the anterior displacement of the radial head fragment.

The literature on the association of PIN neuropraxia with isolated radial head fracture is scarce, with few case reports.<sup>1,9-11</sup> The proximity of the PIN with the radial neck creates the risk of injuries in this region, as well as in its surgical approaches.<sup>2</sup> Anatomical studies have shown that the mean distance between the radiocapitellar joint and the PIN origin is between  $1.2\text{ cm} \pm 1.9\text{ mm}$  and only 1% are in contact with the radius.<sup>8</sup>

There is no consensus in the literature regarding the best treatment in such cases; there are reports of conservative and surgical treatments with or without nerve exploration.<sup>1,5</sup> In the present case, the authors opted for surgical treatment without nerve exploration, due to the deviation of the radial

head fragment, as the patient had no capsular injury nor evidence suggesting direct trauma to the nerve.

Surprisingly, the patient had a full recovery of wrist and fingers motion on the second day after surgery. Six months postoperatively, he presented full ROM, with radiographic signs of fracture healing.

## Conclusion

Although rare, posterior interosseous nerve branch injury may be associated with acute or late radial head fractures, even in undisplaced fractures. Proper clinical and neurologic assessments were important in the initial care of this patient.

## Conflicts of interest

The authors declare no conflicts of interest.

## REFERENCES

1. Daurka J, Chen A, Akhtar K, Kamineni S. Tardy posterior interosseous nerve palsy associated with radial head fracture: a case report. *Cases J.* 2009;2(1):22.
2. Hirachi K, Kato H, Minami A, Kasashima T, Kaneda K. Clinical features and management of traumatic posterior interosseous nerve palsy. *J Hand Surg Br.* 1998;23(3):413-7.
3. Marmor L, Lawrence JF, Dubois EL. Posterior interosseous nerve palsy due to rheumatoid arthritis. *J Bone Joint Surg Am.* 1967;49(2):381-3.
4. Ogino T, Minami A, Kato H. Diagnosis of radial nerve palsy caused by ganglion with use of different imaging techniques. *J Hand Surg Am.* 1991;16(2):230-5.
5. Pike JM, Grewal R, Athwal GS, Faber KJ, King GJ. Open reduction and internal fixation of radial head fractures: do outcomes differ between simple and complex injuries? *Clin Orthop Relat Res.* 2014;472(7):2120-7.
6. Spinner M. The arcade of Frohse and its relationship to posterior interosseous nerve paralysis. *J Bone Joint Surg Br.* 1968;50(4):809-12.
7. Tornetta P 3rd, Hochwald N, Bono C, Grossman M. Anatomy of the posterior interosseous nerve in relation to fixation of the radial head. *Clin Orthop Relat Res.* 1997;(345):215-8.
8. Strachan JC, Ellis BW. Vulnerability of the posterior interosseous nerve during radial head resection. *J Bone Joint Surg Br.* 1971;53(2):320-3.
9. Pike JM, Athwal GS, Faber KJ, King GJ. Radial head fractures – an update. *J Hand Surg Am.* 2009;34(3):557-65.
10. Sudhahar TA, Patel AD. A rare case of partial posterior interosseous nerve injury associated with radial head fracture. *Injury.* 2004;35(5):543-4.
11. Hak DJ. Radial nerve palsy associated with humeral shaft fractures. *Orthopedics.* 2009;32(2):111.