



## Original Article

# Comparative study between lateral decubitus and traction table for treatment of pertrochanteric fractures with cephalomedullary nails<sup>☆</sup>



Eric Fernando de Souza<sup>\*</sup>, José Octávio Soares Hungria, Lucas Romano Sampaio Rezende, Davi Gabriel Bellan, Jonas Aparecido Borracini

Hospital Municipal do Campo Limpo Dr. Fernando Mauro Pires da Rocha, Departamento de Ortopedia e Traumatologia, São Paulo, SP, Brazil

## ARTICLE INFO

## Article history:

Received 11 November 2015

Accepted 18 April 2016

Available online 14 December 2016

## Keywords:

Bone nails

Bone screws

Femoral fractures

## ABSTRACT

**Objective:** To perform a retrospective radiographic assessment of the reduction and implant position in the femoral head in patients with pertrochanteric fractures treated with cephalomedullary nailing in the lateral position versus traction table.

**Methods:** Radiographs of patients with pertrochanteric fracture of the femur treated with cephalomedullary nailing in the lateral position and traction table were retrospectively evaluated. For the evaluation we used the anteroposterior radiographic view of the pelvis and the lateral view of the affected side. The cervicodiaphyseal angle, the tip-apex distance (TAD), and the spatial position of the cephalic component in the head were measured. Two patient groups were created, one group operated on the traction table and another group operated in the lateral position.

**Results:** Regarding the cervicodiaphyseal angle observed in the traction table group, the results of 11 patients (61.1%) were outside the acceptable parameters proposed in the present study. Both groups were equivalent regarding TAD and the position of the cephalic component in the head.

**Conclusion:** A difference in the cervicodiaphyseal angle was observed; the group operated on the traction table had 11 patients (61.1%) whose measurements were outside the acceptable parameters.

© 2016 Sociedade Brasileira de Ortopedia e Traumatologia. Published by Elsevier Editora Ltda. This is an open access article under the CC BY-NC-ND license (<http://creativecommons.org/licenses/by-nc-nd/4.0/>).

<sup>☆</sup> Study conducted at the Hospital Municipal do Campo Limpo Dr. Fernando Mauro Pires da Rocha, Departamento de Ortopedia e Traumatologia, São Paulo, SP, Brazil.

<sup>\*</sup> Corresponding author.

E-mail: [ericefs@gmail.com](mailto:ericefs@gmail.com) (E.F. Souza).

<http://dx.doi.org/10.1016/j.rboe.2016.04.009>

2255-4971/© 2016 Sociedade Brasileira de Ortopedia e Traumatologia. Published by Elsevier Editora Ltda. This is an open access article under the CC BY-NC-ND license (<http://creativecommons.org/licenses/by-nc-nd/4.0/>).

## Estudo comparativo entre decúbito lateral e mesa de tração para tratamento de fraturas pertrocantericas com hastes cefalomedulares

### R E S U M O

#### Palavras-chave:

Pinos ortopédicos  
Parafusos ósseos  
Fraturas de fêmur

**Objetivo:** Fazer uma avaliação comparativa radiográfica retrospectiva da redução e posição do implante na cabeça femoral em pacientes com fraturas pertrocantericas tratados com haste cefalomedular em decúbito lateral ou em mesa de tração.

**Métodos:** Foram avaliadas retrospectivamente radiografias de pacientes com diagnóstico de fratura pertrocanterica do fêmur tratados com haste cefalomedular em decúbito lateral ou em mesa de tração. Para avaliação radiográfica ambulatorial usamos as incidências antero-posterior da pelve e o perfil do lado afetado. Aferimos o ângulo cervicodiafisário, a *tip-apex distance* (TAD) e a posição espacial do elemento cefálico na cabeça. Foram criados dois grupos de pacientes, um operado na mesa de tração e outro em decúbito lateral.

**Resultados:** Com relação ao ângulo cervicodiafisário, observamos no grupo da mesa de tração 11 pacientes (61,1%) fora dos parâmetros aceitáveis propostos em nosso trabalho. Para a TAD e a posição do elemento cefálico na cabeça, os dois grupos se mostraram equivalentes.

**Conclusão:** Observamos diferença com relação ao ângulo cervicodiafisário, no qual o grupo operado em mesa de tração apresentou 11 pacientes (61,1%) fora dos parâmetros aceitáveis.

© 2016 Sociedade Brasileira de Ortopedia e Traumatologia. Publicado por Elsevier Editora Ltda. Este é um artigo Open Access sob uma licença CC BY-NC-ND (<http://creativecommons.org/licenses/by-nc-nd/4.0/>).

## Introduction

Pertrochanteric fractures are common in the elderly, due to osteoporosis, and their incidence has increased significantly because of the longer life expectancy of the population. Their incidence is expected to double in the next 25 years.<sup>1,2</sup> Currently, there is a consensus that pertrochanteric fractures of the femur should be treated surgically.<sup>3,4</sup> The techniques for fixation of these fractures with cephalomedullary nails are best conducted with a traction table. However, in the absence or impossibility of its use, it is necessary to adopt another position, such as lateral decubitus.<sup>5</sup> In an earlier study conducted in the present hospital by de Oliveira et al.,<sup>6</sup> conditions that could influence the efficiency of the reduction and the positioning of the cephalic element in the femoral head in pertrochanteric fractures, when fixated in lateral decubitus, were assessed. Given the encouraging results of that study,<sup>6</sup> the present authors conducted a comparative study to assess the results regarding the reduction and the spatial positioning of the cephalic element (CE) in the femoral head (cervicodia-physeal angle), tip-apex distance (TAD), and spatial position of the CE in the femoral head (circle of Baumgaertner et al.<sup>7</sup>) in pertrochanteric fractures treated on a traction table. The goal was to assess whether the reduction and positioning of the cephalic element in both positioning methods were equivalent.

The present study aimed to evaluate whether there are differences in the quality of reduction and in the spatial positioning of the CE of cephalomedullary nails in pertrochanteric fractures treated with these nails in lateral decubitus and on a traction table.

## Patients and methods

### Patients

Between January 2014 and June 2015, 35 patients diagnosed with pertrochanteric femoral fracture were treated with cephalomedullary nail on a traction table in a teaching hospital in a large urban center. Of those, 18 attended the retrospective final assessment, 14 could not be located, and three died, one in the hospital and two postoperatively. Five (27.8%) were female and 13 (72.2%) were male, with a mean age of 65 years (range 41–91 years). Regarding the trauma mechanism, ten had a ground-level fall; two, a fall from bed; two, a fall from stairs; one had suffered a beating; one, a fall from the roof; one, a motorcycle accident; and one, a fracture after the use of Reamer Irrigator Aspiration<sup>®</sup> (RIA). Five patients had fracture of the left side and 13, on the right side. Twenty-nine fractures treated in the lateral decubitus position between June 2012 and November 2013 were assessed. Of those, 19 attended the retrospective final assessment, eight could not be located, and two died in the hospital, due to postoperative trauma complications; 11 were female and eight male, mean age 60 years (range 18–87 years). The mechanisms of trauma were ground-level falls in 13 patients; motorcycle falls, in four; injury by firearm, in one; and bicycle fall, in one. Eleven patients presented fracture of the left side and eight on the right.<sup>6</sup>

Two groups of patients were created: Group 1 comprised patients with pertrochanteric fractures fixated with cephalomedullary nails treated in the lateral decubitus position and Group 2, patients with pertrochanteric fractures fixed with cephalomedullary nails treated on a traction table.

Of the preoperative radiographs analyzed from Group 2, six (33.3%) patients presented the A1 pattern; seven (38.9%), A2; and five (27.8%), A3. The minimum time of postoperative evaluation for that group was one month. In turn, in Group 1 one (5.3%) patient presented the A1 pattern, 11 (57.9%), A2; and seven (36.8%), A3. The minimum time of postoperative evaluation for that group was six months.

## Methods

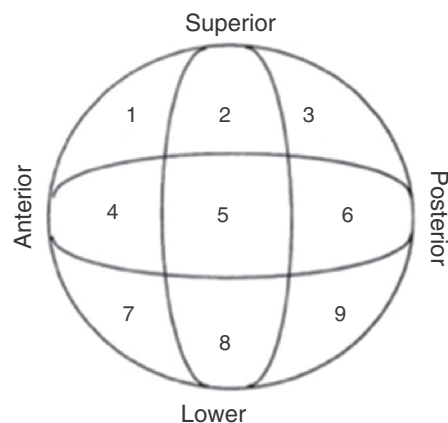
To classify the fractures, authors used pelvic radiographs of the affected hip in anteroposterior (AP) and lateral (L) views, and applied the AO rating for pertrochanteric fractures (31-): A1 are simple, two-part fractures with good bone support in the medial cortical; A2 are multifragmentary fractures in which the medial and dorsal cortices (lesser trochanter) are broken on different levels, but the lateral cortex is intact; in A3 fractures, the lateral cortex is also broken (reverse oblique fractures).<sup>8</sup>

To perform the surgical procedure on a traction table, patient was placed under general or spinal anesthesia in the supine position in an orthopedic surgical table with mounted traction boots, properly positioned; the non-fractured limb was placed in a flexed and abducted position to provide more room for the C-arm. Closed reduction of the fracture, with traction and internal or external rotation, depending on the fracture pattern, was confirmed by radioscopy. Then, surgical site was prepped from the iliac crest to the foot of the affected side. Cephalomedullary nails (Gamma™ nail® or TFN®) were used, adopting the standard technique for internal fixation of fractures.<sup>9</sup> For the proximal fixation, it was sought to position the cephalic fixation element on the center of the head, at 1-cm from the subchondral bone in normal bone and at 0.5-cm in porotic bone in AP and L. Distal fixation was performed with a guide when a standard-size cephalomedullary nail was used, or freehand when a long nail was used. Radioscopic control was performed in both AP and L at every step. All cases were operated by a third year resident, overseen by the same attending physician.

In the group in which osteosynthesis was performed in the lateral position, patient was placed in the lateral decubitus position with the aid of cushions on the back and abdomen; AP and L radiographs were made to assess the correct visualization of the entire femur and pelvis in two planes, as described by Oliveira et al.<sup>6</sup>

For outpatient radiographic evaluation, the AP view of the pelvis was used, with the patient in the supine position; the incident ray was positioned on the midline of the pubic symphysis, with the feet internally rotated at 15°–20° using the standard technique. The L view was also used, with the patient positioned in supine, the affected hip at 45° flexion and 20° abduction, and the incident ray was centered vertically on the hip joint, following the standard technique.<sup>10</sup> For these incidences, the following variables were evaluated:

Cervicodiaphyseal angle: angle between two lines, one that crosses the center of rotation of the femoral head and the longitudinal axis of the femoral neck and the other, the long axis of the femoral shaft.<sup>11</sup> Values between 130° and 135° were considered as normal.



**Fig. 1 – Arrangement of the quadrants in nine zones.**

TAD: defined in accordance with Baumgaertner et al.<sup>7</sup>; distances shorter than 25 mm from the subchondral bone in the central portion of the femoral head to the end of the cephalic pin of the nail are ideal.

Spatial position of the CE in relation to the head: the femoral head is divided into nine separate areas in which the CE is located. These are: superior-, middle-, and lower-third in the AP radiograph and anterior-, center-, and posterior-third in the L radiograph.<sup>7</sup> The central-central zone in quadrant 5 was considered ideal (Fig. 1), and quadrants with increased risk of cut-out were avoided.

Two groups of patients were created, separated by the positioning and reduction method used in the surgical treatment of fractures. To compare them, three parameters were used: cervicodiaphyseal angle, TAD, and spatial position of the CE. The quantitative characteristics of the groups were described as mean, standard deviation, median, and minimum and maximum, and compared with Student's t-test. The qualitative characteristics of the groups were described by absolute and relative frequencies; the associations between the groups were verified using the chi-squared test, Fisher's exact test, or the likelihood ratios.<sup>12</sup>

A 5% significance level was adopted.

## Results

The data collected from both groups were tabulated. Patient characteristics, such as age, sex, weight, and height, were chosen for analysis. Fracture characteristics analyzed were side, AO classification, and mechanism of injury, as described in Table 1.

Table 1 shows that patients operated in the lateral decubitus position and on the traction table showed similar characteristics ( $p > 0.05$ ).

Similarly, to assess the results of surgery by the criteria set forth in the present study, the results of both groups were organized and described in Table 2.

Table 2 shows that the cervicodiaphyseal angle was significantly more altered in patients who underwent surgery with the use of a traction table than in those whose surgery was

**Table 1 – Description of the personal characteristics and the procedure by groups and results of statistical tests.**

Variable	Group		Total (n = 37)	p
	Lateral decubitus (n = 19)	Traction table (n = 18)		
Sex, n (%)				0.65
Female	11 (57.9)	5 (27.8)	16 (43.2)	
Male	8 (42.1)	13 (72.2)	21 (56.8)	
Age (years)				0.340 <sup>a</sup>
Mean (SD)	60 (20.9)	65.9 (16.4)	62.9 (18.8)	
Median	64 (18; 87)	64 (41; 91)	64 (18; 91)	
Weight (kg)				0.788 <sup>a</sup>
Mean (SD)	68.2 (21.4)	66.6 (11.7)	67.4 (17.2)	
Median	67.8 (40; 121)	67 (50; 90)	67.8 (40; 121)	
Height (m)				0.433 <sup>a</sup>
Mean (SD)	1.62 (0.11)	1.65 (0.07)	1.64 (0.09)	
Median	1.62 (1.45; 1.85)	1.65 (1.55; 1.79)	1.65 (1.45; 1.85)	
Side, n (%)				0.65
Right	8 (42.1)	13 (72.2)	21 (56.8)	
Left	11 (57.9)	5 (27.8)	16 (43.2)	
Classification, n (%)				0.076 <sup>b</sup>
A1	1 (5.3)	6 (33.3)	7 (18.9)	
A2	11 (57.9)	7 (38.9)	18 (48.6)	
A3	7 (36.8)	5 (27.8)	12 (32.4)	
Trauma mechanism, n (%)				0.420
Ground-level fall	13 (68.4)	10 (55.6)	23 (62.2)	
Others	6 (31.6)	8 (44.4)	14 (37.8)	

Chi-squared test.  
<sup>a</sup> Student's t-test.  
<sup>b</sup> Likelihood ratio test.

**Table 2 – Description of the surgical evaluation criteria according to groups and results of statistical tests.**

Variable	Group		Total (n = 37)	p
	Lateral decubitus (n = 19)	Traction table (n = 18)		
Position of cephalic implant, n (%)				0.823
Quadrant 5	7 (36.8)	6 (33.3)	13 (35.1)	
Other quadrants	12 (63.2)	12 (66.7)	24 (64.9)	
TAD, n (%)				0.660 <sup>a</sup>
Normal	17 (89.5)	15 (83.3)	32 (86.5)	
Altered	2 (10.5)	3 (16.7)	5 (13.5)	
Cervicodiaphyseal, n (%)				<0.001
Normal	18 (94.7)	7 (38.9)	25 (67.6)	
Altered	1 (5.3)	11 (61.1)	12 (32.4)	

Chi-squared test.  
<sup>a</sup> Fisher's exact test.

performed in the lateral decubitus position ( $p < 0.001$ ). Both groups were similar regarding TAD and implant positioning.

## Discussion

There are some options for reduction and patient positioning in the treatment of pertrochanteric fractures.<sup>13</sup> The present hospital did not use to have a traction table, so patients were treated in the lateral position, a method that was shown to be effective in this service regarding spatial positioning of the

CE, TAD, and cervicodiaphyseal angle. The hospital now has a traction table, and it has become the method of choice for the treatment of these fractures. Therefore, most professionals have started to perform this type of osteosynthesis in the present hospital, as the method is widely described among orthopedic surgeons and the procedure requires a smaller team. In contrast, the lateral decubitus positioning is a more meticulous technique that requires experience and expertise on the part of the surgeon and a larger, trained team.

For the reduction of pertrochanteric femoral fractures, traction of the affected limb is necessary in most cases. In the

lateral decubitus technique, this is controlled by the surgeons themselves, who can have more precise control of the reduction at each stage of osteosynthesis. With the traction table, this adjustment is made at the initial position and is difficult to make in other stages of osteosynthesis, as the fine adjustment is made with a non-sterile device.

Considering both groups of patients (one treated on the traction table and the other in lateral decubitus), the results of both methods were assessed, aiming to reconstruct the normal cervicodiaphyseal angle between 130° and 135°, so that the implant could be properly positioned, avoiding reductions in varus.<sup>14,15</sup> For the proximal fixation, it was sought to position the cephalic fixation element on the center of the head, in AP and L at 1-cm from the subchondral bone in normal bone and at 0.5-cm in porotic bone, following the concept introduced by Baumgaertner et al.<sup>7</sup>

In both groups, the parameters were successfully achieved. Regarding the TAD (described for osteosynthesis with dynamic hip screws, it can be used to assess the correct positioning of cephalomedullary nails)<sup>15,16</sup> and the spatial position of the cephalic fixation element, the safest quadrants were always obtained, avoiding those with higher cutout risk.<sup>5,7</sup>

As for the cervicodiaphyseal angle, unsatisfactory results were observed in the cases operated on the traction table; 61.1% of cases did not fall within the stipulated standard. In the patients operated in lateral decubitus, only one (5.3%) was found to be outside the accepted standards in the present study.

## Conclusion

A statistically significant difference was observed regarding the cervicodiaphyseal angle ( $p$ -value < 0.001); the group operated on the traction table presented 11 patients (61.1%) outside the acceptable parameters.

## Conflicts of interest

The authors declare no conflicts of interest.

## REFERENCES

- Haidukewych GJ. Intertrochanteric fractures: ten tips to improve results. *J Bone Joint Surg Am.* 2009;91(3):712-9.
- Uliana CS, Abagge M, Malafaia O, Kalil Filho FA, Cunha LAM. Fraturas transtrocantericas – Avaliação dos dados da admissão à alta hospitalar. *Rev Bras Ortop.* 2014;49(2): 121-8.
- Butler M, Forte ML, Joglekar SB, Swiontkowski MF, Kane RL. Evidence summary: systematic review of surgical treatments for geriatric hip fractures. *J Bone Joint Surg Am.* 2011;93(12):1104-15.
- Canto RS, Sakaki M, Susuki I, Tucci P, Belangero W, Kfuri M Jr, et al. Fratura transtrocanteriana. São Paulo: Sociedade Brasileira de Ortopedia e Traumatologia; 2007. Projeto Diretrizes.
- Buchholz RW, Court-Brown CM, Tornetta P 3rd. Fraturas em adultos de Rockwood e Green. 7ª ed. Barueri: Manole; 2013.
- de Oliveira EJ, Hungria JO, Bellan DG, Borracini JA. Decúbito lateral para tratamento das fraturas pertrocanterica com hastes cefalomedulares. *Rev Bras Ortop.* 2015;40(4): 409-15.
- Baumgaertner MR, Curtin SL, Lindskog DM, Keggi JM. The value of the tip-apex distance in predicting failure of fixation of peritrochanteric fractures of the hip. *J Bone Joint Surg Am.* 1995;77(7):1058-64.
- Rüedi TP. Princípios AO do tratamento de fraturas. 2ª ed. Porto Alegre: Artmed; 2009.
- Canale ST. Campbell's operative orthopaedics. 12th ed. St. Louis: Mosby; 2013.
- Polesello GC, Nakao TS, Queiroz MC, Daniachi D, Ricioli W Jr, Guimarães RP, et al. Proposta de padronização do estudo radiográfico do quadril e da pelve. *Rev Bras Ortop.* 2011;46(6):634-42.
- Giordano V, Dias MC, Santos GF, Cabral S, Amaral NP, Albuquerque RP. Estudo radiográfico da extremidade proximal do fêmur para avaliação do risco de fratura osteoporótica. *Rev Bras Ortop.* 2007;42(4):88-96.
- Kirkwood BR, Sterne JA. Essential medical statistics. 2nd ed. Massachusetts, USA: Blackwell Science; 2006.
- Ozsoy MH, Basarir K, Bayramoglu A, Erdemli B, Tuccar E, Eksioglu MF. Risk of superior gluteal nerve and gluteus medius muscle injury during femoral nail insertion. *J Bone Joint Surg Am.* 2007;89(4):829-34.
- Guimarães JA, Guimarães AC, Franco JS. Avaliação do emprego da haste femoral curta na fratura trocanterica instável do fêmur. *Rev Bras Ortop.* 2008;43(9): 406-7.
- Borger RM, Leite FA, Araújo RP, Pereira TF, Queiroz RD. Avaliação prospectiva da evolução clínica, radiográfica e funcional do tratamento das fraturas trocantericas instáveis do fêmur com haste cefalomedular. *Rev Bras Ortop.* 2011;46(4):380-9.
- De Bruijn K, den Hartog D, Tuinebreijer W, Roukema G. Reliability of predictors for screw cutout in intertrochanteric hip fractures. *J Bone Joint Surg Am.* 2012;94(14):1266-72.