



Original Article

Reverse shoulder arthroplasty: clinical results and quality of life evaluation[☆]



Arnaldo Amado Ferreira Neto^a, Eduardo Angeli Malavolta^a,
Jorge Henrique Assunção^{a,*}, Evelinda Marramon Trindade^b,
Mauro Emilio Conforto Gracitelli^a

^a Universidade de São Paulo, Faculdade de Medicina, Instituto de Ortopedia e Traumatologia, São Paulo, SP, Brazil

^b Secretaria da Saúde do Estado de São Paulo, Rede Paulista de Avaliação em Tecnologia de Saúde, São Paulo, SP, Brazil

ARTICLE INFO

Article history:

Received 14 March 2016

Accepted 20 June 2016

Available online 4 May 2017

Keywords:

Arthroplasty, replacement

Joint diseases

Osteoarthritis

Rotator cuff

ABSTRACT

Objective: To evaluate the clinical and radiological results and the impact on quality of life of the reverse shoulder arthroplasty.

Methods: Retrospective case series evaluating 13 patients undergoing reverse shoulder arthroplasty with at least two years of clinical follow-up. Clinical evaluation was performed before and after surgery with the ASES and VAS scales and hand-mouth, hand-neck, and hand-head functional tests. Quality of life was measured with the SF-12 questionnaire. The rate of complications and radiographic postoperative findings were recorded.

Results: The patients improved from 23.1 ± 15 to 82.7 ± 15 according to ASES scale ($p < 0.001$). The physical component of the SF-12 increased from 31.7 ± 6.9 to 47.1 ± 8.6 ($p < 0.001$), while the emotional increased from 48 ± 12.3 to 55.5 ± 7.5 ($p = 0.061$). The pain reduced from 7.9 to 1 according to the VAS ($p = 0.002$). The performance on the hand-mouth, hand-neck, and hand-head functional tests showed significant improvement ($p = 0.039$, $p < 0.001$ and $p < 0.001$, respectively). Complications occurred in 15% of patients and notching, in 31%.

Conclusion: Reverse shoulder arthroplasty led to a significant clinical improvement according to the ASES and VAS scales. The quality of life has improved according to the physical aspect of the SF-12, and showed a trend of improvement in the emotional aspect. The complication rate was 15%, and notching occurred in 31%.

© 2016 Sociedade Brasileira de Ortopedia e Traumatologia. Published by Elsevier Editora Ltda. This is an open access article under the CC BY-NC-ND license (<http://creativecommons.org/licenses/by-nc-nd/4.0/>).

[☆] Study conducted at the Universidade de São Paulo, Faculdade de Medicina, Instituto de Ortopedia e Traumatologia, Grupo de Ombro e Cotovelo, São Paulo, SP, Brazil.

* Corresponding author.

E-mail: drjorgeassuncao@gmail.com (J.H. Assunção).

<http://dx.doi.org/10.1016/j.rboe.2017.04.007>

2255-4971/© 2016 Sociedade Brasileira de Ortopedia e Traumatologia. Published by Elsevier Editora Ltda. This is an open access article under the CC BY-NC-ND license (<http://creativecommons.org/licenses/by-nc-nd/4.0/>).

Artroplastia reversa do ombro: avaliação dos resultados clínicos e da qualidade de vida

R E S U M O

Palavras-chave:

Artroplastia de substituição
Artropatias
Osteoartrose
Manguito rotador

Objetivo: Avaliar os resultados clínicos e radiológicos e o impacto na qualidade de vida da artroplastia reversa do ombro.

Métodos: Série de casos retrospectiva que avaliou 13 pacientes submetidos à artroplastia reversa do ombro com seguimento clínico mínimo de dois anos. Foi feita avaliação clínica antes e após a cirurgia com as escalas da *American Shoulder and Elbow Surgeons (ASES)* e escala visual analógica (EVA) e as manobras funcionais mão-boca, mão-nuca e mão-cabeça. A qualidade de vida foi aferida com o questionário *12-Item Short-Form Health Survey (SF-12)*. Registramos o índice de complicações e o aspecto radiográfico pós-operatório.

Resultados: Os pacientes evoluíram de $23,1 \pm 15$ para $82,7 \pm 15$ pela escala da ASES ($p < 0,001$). O componente físico do SF-12 passou de $31,7 \pm 6,9$ para $47,1 \pm 8,6$ ($p < 0,001$) enquanto o emocional de $48 \pm 12,3$ para $55,5 \pm 7,5$ ($p = 0,061$). A dor regrediu de 7,9 para 1 de acordo com a EVA ($p = 0,002$). As manobras funcionais mão-boca, mão-nuca e mão-cabeça apresentaram melhorias significativas ($p = 0,039$, $p < 0,001$ e $p < 0,001$, respectivamente). Complicações ocorreram em 15% dos pacientes e *notching*, em 31%.

Conclusão: Os pacientes submetidos à artroplastia reversa do ombro tiveram melhoria significativa de acordo com as escalas da ASES e EVA. A qualidade de vida melhorou significativamente de acordo com o aspecto físico do SF-12 e demonstrou tendência de melhoria no aspecto emocional. O índice de complicações foi de 15% e *notching* ocorreu em 31%.

© 2016 Sociedade Brasileira de Ortopedia e Traumatologia. Publicado por Elsevier Editora Ltda. Este é um artigo Open Access sob uma licença CC BY-NC-ND (<http://creativecommons.org/licenses/by-nc-nd/4.0/>).

Introduction

Reverse shoulder arthroplasty technique was developed by Paul Grammont in 1985 in France¹; the first case series was published in the following decade.^{2,3} Initially developed for the treatment of rotator cuff arthropathy,⁴⁻⁸ its use extends to cases of primary anatomical arthroplasty revisions,^{9,10} complex fractures,¹¹⁻¹³ sequelae of proximal humeral fractures,^{14,15} and inflammatory arthroplasties.¹⁶ From its original restriction to European use, it was approved by the Food and Drug Administration in the United States in 2003 and since then has been widely used in that country.¹⁷

Reverse arthroplasty has biomechanical characteristics that improve function of the deltoid muscle and compensate a dysfunctional rotator cuff.¹⁸ Its clinical results are superior to those of anatomic total shoulder arthroplasties in the treatment of rotator cuff arthropathy.⁴

Currently, reverse arthroplasty has been approved by the Brazilian National Sanitary Surveillance Agency and is part of the therapeutic arsenal of the Supplemental Health System. However, the Brazilian Unified Health System (Sistema Único de Saúde [SUS]) does not list the implant within its procedures, and most public hospitals are unable to adequately treat patients with indication for the use of this implant. The national literature features only two studies on the subject^{5,8}; both evidenced clinical improvement with treatment.

After contacting the Health Secretariat of the State of São Paulo and explaining the issue, the authors were instructed to conduct further studies on the subject in an attempt to objectively expose the problem and, consequently, aid in

the provision of reverse arthroplasty in specialized shoulder surgery centers. This is the first in a series of articles to be developed by this group. The goal is to evaluate the clinical and radiological results of reverse shoulder arthroplasty, as well as its impact on quality of life.

Methods

This was a retrospective case series. Patients who underwent reverse shoulder arthroplasty, with a minimum of two years of clinical follow-up, were assessed. The study comprised surgeries performed until December 2013. Patients submitted to other types of arthroplasties were not included. This study was approved by the Institution Review Board under No. 1103.

Indications for reverse arthroplasty were:

- Rotator cuff arthropathy; extensive and irreparable rupture of the rotator cuff; primary or secondary glenohumeral arthrosis, associated with irreparable rupture of the rotator cuff; sequela of proximal fracture of the humerus with pseudoarthrosis or major and/or minor tubercle resorption; sequela of tumor resection with irreparable rotator cuff lesion; and conventional shoulder arthroplasty with upper subluxation of the humeral component, pseudoarthrosis, or reabsorption of the tuberosities;
- Active elevation below 90°;
- Unsuccessful non-surgical treatment for at least six months.

All procedures were conducted by one of the specialists in shoulder and elbow surgery at this institution.

The following variables were analyzed:

- a) Demographic data: gender, age at surgery, date of surgery, time of symptoms prior to the procedure, time of evaluation;
- b) Diagnosis, categorized as rotator cuff arthropathy, glenohumeral arthrosis with irreversible rotator cuff lesion, sequela of proximal humerus fracture, inflammatory arthropathy, and tumor resection sequela;
- c) Type of surgery, categorized as primary arthroplasty or revision;
- d) Functional maneuvers: hand-mouth, hand-head, and hand-neck, categorized as able or unable, referring to the pre- and postoperative period;
- e) American Shoulder and Elbow Surgeons (ASES) score,¹⁹ regarding the pre- and postoperative period;
- f) SF-12²⁰ quality of life scale, regarding the pre- and postoperative period;
- g) Visual analog scale (VAS) for pre- and postoperative pain;
- h) Complications: occurrence of postoperative infection, periprosthetic fracture, deep venous thrombosis, pneumonia, urinary tract infection, acute myocardial infarction, and death.
- i) Magnetic resonance imaging, preoperative:
 - I) Degree of fatty degeneration of the supraspinatus, infraspinatus, and subscapularis muscles, according to Fuchs et al.²¹
 - II) Tendons affected by transfixing rupture.
- j) Postoperative radiographic evaluation: occurrence of humeral stem loosening, glenosphere loosening, and notching.

Intervention

Procedures were performed under general anesthesia associated with interscalene blockade. Antimicrobial prophylaxis was conducted with second-generation cephalosporin for 24 h. The surgical approach used was the deltopectoral, with removal of the remaining subscapularis tendon when it did not present rupture of its entire extension. In all cases, the joint capsule was widely released. The prostheses Delta III or Delta XTEND (DePuy, Warsaw, IN, United States) with cementing of the humeral shaft were used in nine cases and the Equinox Reverse System (Exactech, Gainesville, FL, United States) without cementing was used in four patients. The number of screws used for baseplate fixation was three or four, depending on patient's bone quality and surgeon's preference. A vacuum drain was used in all patients and maintained for 24-48 h. In the postoperative period, the patients used a sling for six weeks. Active movements of the elbow, wrist, and fingers were initiated in the immediate postoperative period. Passive and active shoulder movements were initiated after the use of sling was discontinued.

Statistical analysis

Continuous variables were assessed for normality using the Kolmogorov-Smirnov test, and for homogeneity using the

Table 1 – Demographic data.

Sex	
Male	6 (46%)
Female	7 (54%)
Diagnosis	
Rotator cuff arthropathy	9 (69%)
Fracture sequela	3 (23%)
Tumor lesion	1 (8%)
Type of arthroplasty	
Primary	9 (69%)
Revision	4 (31%)
Age (years)	62.5 ± 13.4
Time with symptoms (months)	63.7 ± 44.7
Follow-up (months)	53 ± 21.4

Levene test. Continuous variables with parametric data distribution were presented as means and standard deviations; those with non-parametric distribution, as medians and percentiles. Categorical variables were presented as absolute values and percentages.

The comparison between the pre- and postoperative periods, regarding the different categorical variables, was made using the chi-squared or Fisher's exact tests. For the continuous variables, Student's t-test was used for data with parametric distribution, and the Wilcoxon test was used for those with non-parametric distribution.

SPSS (version 20.0) was used for data analysis; a 5% significance level was adopted for all calculations.

Results

Seventeen patients underwent surgical treatment. Of these, four were excluded for the following reasons: death unrelated to the surgery before 2-year clinical follow-up (one), inability to answer the questionnaire due to dementia (two), and loss of follow-up (one). The general data of the sample is shown in Table 1.

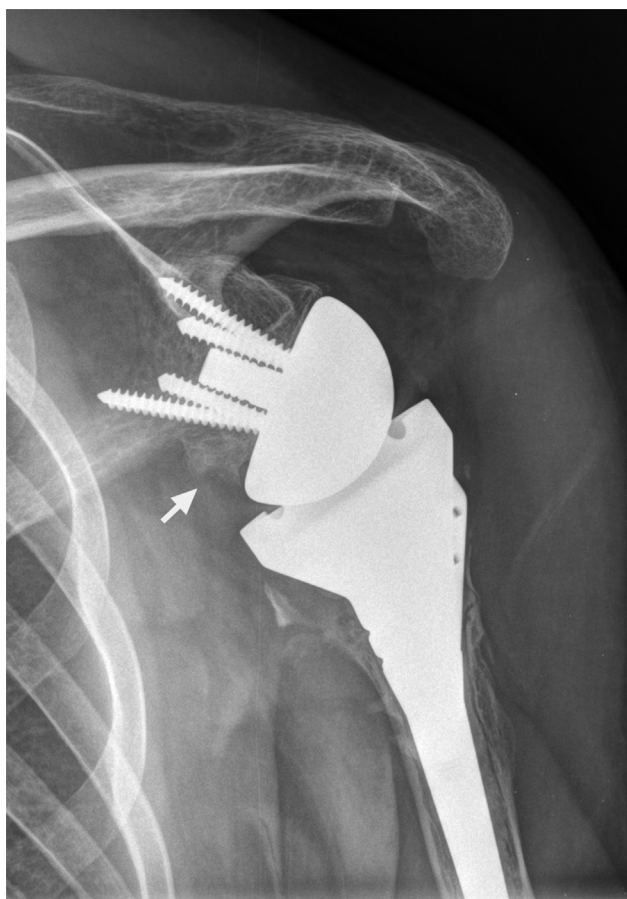
Preoperative magnetic resonance imaging was performed in the nine patients who underwent primary reverse arthroplasty. In all cases, this imaging study revealed transfixing ruptures of the supraspinatus and infraspinatus tendons, with the tendinous stump retracted at the glenoid level. In six cases (66%), a transfixing lesion of the upper two thirds of the subscapularis tendon was observed. In all other cases, the tendon was ruptured along its entire extension. Fatty degeneration was classified according to Fuchs et al.²¹ as grade III in 100% of the supraspinatus and infraspinatus muscles. Subscapularis degeneration was rated as grade II in five cases (56%) and as grade III in four cases (44%). In the four cases undergoing partial shoulder arthroplasty, magnetic resonance imaging was not performed.

The results of the ASES scale increased from 23.1 ± 15 to 82.7 ± 15, a statistically significant difference ($p < 0.001$). The physical component of the SF-12 showed a significant improvement, increasing from 31.7 ± 6.9 to 47.1 ± 8.6 ($p < 0.001$). The emotional component increased from 48 ± 12.3 to 55.5 ± 7.5, a non-statistically significant difference ($p = 0.061$). In the VAS, pain was reduced from 7.9 to 1 ($p = 0.002$). The ability to perform the functional hand-mouth,

Table 2 – Pre- and postoperative clinical evaluation.

	Preoperative period	Postoperative period	p
ASES	23.1 ± 15	82.7 ± 15	<0.001
SF-12 physical	31.7 ± 6.9	47.1 ± 8.6	<0.001
SF-12 emotional	48 ± 12.3	55.5 ± 7.5	0.06
VAS	7.9 ± 2.9	1 ± 1.7	0.002
Hand-mouth	8 (62%)	13 (100%)	0.39
Hand-neck	2 (15%)	12 (92%)	<0.001
Hand-head	0 (0%)	13 (100%)	<0.001

ASES, American Shoulder and Elbow Surgeons; VAS, visual analog scale; SF-12, 12-Item Short-Form Health Survey.

**Fig. 1 – Post-operative radiograph. Reverse shoulder arthroplasty with scapular notching.**

hand-neck, and hand-head tests also showed a significant improvement ($p=0.039$, $p<0.001$, and $p<0.001$, respectively). Clinical data are shown in [Table 2](#).

Clinical complications were observed in two patients (15%); one case of post-operative infection, treated by surgical debridement and intravenous antibiotic therapy, and one case of dislocation on the 5th postoperative day, treated with reduction under anesthesia without revision.

Postoperative radiography did not reveal humeral, glenoid, or periprosthetic fractures. Notching was observed in four patients (31%; [Fig. 1](#)).

Discussion

The present results showed a significant clinical improvement of patients. A progression from 23.1 to 82.7 points was observed on the ASES scale. The results are consistent with other studies that used the same rating scale, showing clinical improvement and final results between 72 and 84.^{7,9} The improvement of symptoms was also demonstrated by authors who used other assessment tools.^{5,6,8,10,16} A significant improvement was also observed in pain, decreasing from 7.9 to 1 in the VAS, a finding similar to that reported by other authors.⁷

According to the physical component of SF-12, there was a significant improvement in quality of life. Nonetheless, the mental component showed only a trend for better results. Quality of life analysis is rarely reported in studies of reverse arthroplasty; this was the first Brazilian study to address the issue. Woodruf et al.²² assessed the use of reverse arthroplasty in rheumatoid patients and found postoperative results of 38.2 for the physical component and 49.3 for the mental, lower than those observed in the present study.

The occurrence of notching in the present series was 31%. This result is within the spectrum reported by other authors, which ranges from 13% to 68%.^{5-8,10,16} Likewise, 15% of complications found in the present study are similar to those reported by Brazilian and international authors.^{6,16} Complications occurred in primary arthroplasty, even though the cases of revision present higher complication rates.^{9,10} Due to the small sample size, stratified analysis was not performed. Fávoro et al.⁸ observed a rate of complications of only 4%, a lower incidence than that reported in the present study and by other authors.^{5,6,9,10,16} This is possibly explained by the fact that their study only included cases of primary arthroplasty, with a shorter follow-up period than that of the present study.

The main limitations of the present study are its retrospective design and small sample size. Another limitation was the inclusion of different diagnoses and the use of two different implant models. Moreover, the minimum follow-up time of 24 months, although meeting the requirements of most orthopedic journals, does not address possible long-term complications possible in arthroplasties procedures. However, the authors emphasize that the mean follow-up time of 53 months was superior to that of the other Brazilian studies.^{5,8}

The present study contributes to the knowledge of the panorama of reverse arthroplasty in Brazil. The Brazilian experience is small; there are only two published studies on the subject.^{5,8} The present study, albeit smaller than those previously published in the country, provides information on the quality of life of patients undergoing this procedure. This analysis was not done in most studies on reverse arthroplasty. The authors restate that this study was suggested by the Nucleus of Health Technology Evaluation of the Health Department of the State of São Paulo. It is part of a research project that also includes a cross-sectional and a prospective study, in an effort to persuade public healthcare agencies of the importance of including this procedure in the SUS.

Conclusion

Patients who underwent reverse shoulder arthroplasty had significant improvement in the ASES and VAS scales. Quality of life improved significantly, according to the physical aspect of SF-12, and a trend for improvement was observed in the emotional aspect. The complication rate was 15%, and notching occurred in 31% of the cases.

Conflicts of interest

The authors declare no conflicts of interest.

REFERENCES

- Grammont P, Trouilloud P, Laffay J, Deries X. Concept study and realization of a new total shoulder prosthesis. *Rhumatologie*. 1987;39:407-18.
- Grammont PM, Baulot E. Delta shoulder prosthesis for rotator cuff rupture. *Orthopedics*. 1993;16(1):65-8.
- Baulot E, Chabernaud D, Grammont PM. Results of Grammont's inverted prosthesis in omarthritis associated with major cuff destruction. Apropos of 16 cases. *Acta Orthop Belg*. 1995;61 Suppl. 1:112-9.
- Young SW, Zhu M, Walker CG, Poon PC. Comparison of functional outcomes of reverse shoulder arthroplasty with those of hemiarthroplasty in the treatment of cuff-tear arthropathy: a matched-pair analysis. *J Bone Joint Surg Am*. 2013;95(10):910-5.
- Amaral MVG, Faria JLR, Siqueira G, Cohen M, Brandão B, Moraes R, et al. Artroplastia reversa do ombro no tratamento da artropatia do manguito rotador. *Rev Bras Ortop*. 2014;49(3):279-85.
- Al-Hadithy N, Domos P, Sewell MD, Pandit R. Reverse shoulder arthroplasty in 41 patients with cuff tear arthropathy with a mean follow-up period of 5 years. *J Shoulder Elbow Surg*. 2014;23(11):1662-8.
- Wiater JM, Moravek JE Jr, Budge MD, Koueiter DM, Marcantonio D, Wiater BP. Clinical and radiographic results of cementless reverse total shoulder arthroplasty: a comparative study with 2 to 5 years of follow-up. *J Shoulder Elbow Surg*. 2014;23(8):1208-14.
- Fávaro RC, Abdulahad M, Filho SM, Valerio R, Superti MJ. Artropatia de manguito: o que esperar do resultado funcional da artroplastia reversa? *Rev Bras Ortop*. 2015;50(5):523-9.
- Kelly JD 2nd, Zhao JX, Hobgood ER, Norris TR. Clinical results of revision shoulder arthroplasty using the reverse prosthesis. *J Shoulder Elbow Surg*. 2012;21(11):1516-25.
- Valenti P, Kilinc AS, Sauzières P, Katz D. Results of 30 reverse shoulder prostheses for revision of failed hemi- or total shoulder arthroplasty. *Eur J Orthop Surg Traumatol*. 2014;24(8):1375-82.
- Ferrel JR, Trinh TQ, Fischer RA. Reverse total shoulder arthroplasty versus hemiarthroplasty for proximal humerus fractures: a systematic review. *J Orthop Trauma*. 2015;29(1):60-8.
- Ross M, Hope B, Stokes A, Peters SE, McLeod I, Duke PF. Reverse shoulder arthroplasty for the treatment of three-part and four-part proximal humeral fractures in the elderly. *J Shoulder Elbow Surg*. 2015;24(2):215-22.
- Gupta AK, Harris JD, Erickson BJ, Abrams GD, Bruce B, McCormick E, et al. Surgical management of complex proximal humerus fractures – a systematic review of 92 studies including 4500 patients. *J Orthop Trauma*. 2015;29(1):54-9.
- Gwinner C, Greiner S, Gerhardt C, Scheibel M. Reverse shoulder arthroplasty for fracture sequelae. *Orthopade*. 2013;42(7):531-41.
- Martinez AA, Bejarano C, Carbonel I, Iglesias D, Gil-Albarova J, Herrera A. The treatment of proximal humerus nonunions in older patients with reverse shoulder arthroplasty. *Injury*. 2012;43 Suppl. 2:S3-6.
- Gee ECA, Hanson EK, Saithna A. Reverse shoulder arthroplasty in rheumatoid arthritis: a systematic review. *Open Orthop J*. 2015;9:237-45.
- Rockwood CA Jr. The reverse total shoulder prosthesis. The new kid on the block. *J Bone Joint Surg Am*. 2007;89(2):233-5.
- Boileau P, Watkinson DJ, Hatzidakis AM, Balg F. Grammont reverse prosthesis: design, rationale, and biomechanics. *J Shoulder Elbow Surg*. 2005;14 1 Suppl. S:147S-61S.
- Richards RR, An KN, Bigliani LU, Friedman RJ, Gartsman GM, Gristina AG, et al. A standardized method for the assessment of shoulder function. *J Shoulder Elbow Surg*. 1994;3(6):347-52.
- Ware J Jr, Kosinski M, Keller SD. A 12-Item Short-Form Health Survey: construction of scales and preliminary tests of reliability and validity. *Med Care*. 1996;34(3):220-33.
- Fuchs B, Weishaupt D, Zanetti M, Hodler J, Gerber C. Fatty degeneration of the muscles of the rotator cuff: assessment by computed tomography versus magnetic resonance imaging. *J Shoulder Elbow Surg*. 1999;8(6):599-605.
- Woodruff MJ, Cohen AP, Bradley JG. Arthroplasty of the shoulder in rheumatoid arthritis with rotator cuff dysfunction. *Int Orthop*. 2003;27(1):7-10.