



## Case report

# Sarcomatous transformation of a hemosiderotic fibrohistiocytic lipomatous tumor: a case report<sup>☆</sup>



Renata Margarida Etchebehere<sup>a,\*</sup>, Elia Cláudia Souza Almeida<sup>a</sup>,  
Carlos David Teixeira Santos<sup>b</sup>, Adilha Misson Rua Micheletti<sup>a</sup>,  
Antônio Sebastião Leitão<sup>a</sup>

<sup>a</sup> Universidade Federal do Triângulo Mineiro (UFTM), Hospital de Clínicas, Serviço de Patologia Cirúrgica, Uberaba, MG, Brazil

<sup>b</sup> Consultoria em Patologia, Botucatu, SP, Brazil

## ARTICLE INFO

### Article history:

Received 3 March 2016

Accepted 14 July 2016

Available online 16 November 2016

### Keywords:

Hemosiderin

Histiocytes

Adipose tissue

Connective tissue

Sarcoma

## ABSTRACT

Hemosiderotic fibrohistiocytic lipomatous tumors are rare neoplasms that were first described in 2000. Initially considered a benign lipomatous lesion of the soft tissues, nowadays they are considered to be a locally aggressive tumor. They occur mainly in the foot and ankle of women in their fifth and sixth decades, although they may be found in any place in the lower limbs and, more rarely, in other parts of the body. Histologically, hemosiderotic fibrohistiocytic lipomatous tumors consist of a mixture of mature adipose tissue, fusiform cell fascicles, macrophages that often contain cytoplasmic hemosiderin, mononuclear inflammatory infiltrate, and stroma that may be focally myxoid. Local recurrence is observed in nearly one-third of all cases. There is no consensus in the literature whether this tumor is a part of a spectrum that comprises pleomorphic hyalinizing angiectatic tumors and myxoinflammatory fibroblastic malignant tumors, or if it is an independent entity.

The authors report a case of a neoplasia after a diagnosis of a hemosiderotic fibrohistiocytic lipomatous tumor in a 38-year-old woman, with two recurrences and later sarcomatous transformation. An immunohistochemical study indicated myofibroblastic differentiation of a malignant neoplasm. To the best of the authors' knowledge, there are only few reported cases of malignant transformation in hemosiderotic fibrohistiocytic lipomatous tumors.

© 2016 Sociedade Brasileira de Ortopedia e Traumatologia. Published by Elsevier Editora Ltda. This is an open access article under the CC BY-NC-ND license (<http://creativecommons.org/licenses/by-nc-nd/4.0/>).

<sup>☆</sup> Work performed in the Hospital de Clínicas, Universidade Federal do Triângulo Mineiro (UFTM), Uberaba, MG, Brazil.

\* Corresponding author.

E-mail: [renataetch@hotmail.com](mailto:renataetch@hotmail.com) (R.M. Etchebehere).

<http://dx.doi.org/10.1016/j.rboe.2016.11.002>

2255-4971/© 2016 Sociedade Brasileira de Ortopedia e Traumatologia. Published by Elsevier Editora Ltda. This is an open access article under the CC BY-NC-ND license (<http://creativecommons.org/licenses/by-nc-nd/4.0/>).

## Transformação sarcomatosa de tumor lipomatoso fibrohistiocítico hemosiderótico: relato de caso

### R E S U M O

*Palavras-chave:*  
Hemosiderina  
Histiócitos  
Tecido adiposo  
Tecido conjuntivo  
Sarcoma

Os tumores lipomatosos fibrohistiocíticos hemosideróticos são neoplasias raras que foram descritas pela primeira vez no ano 2000. Inicialmente considerada uma lesão lipomatosa benigna dos tecidos moles, atualmente é considerado um tumor localmente agressivo. Estas lesões ocorrem principalmente no pé e no tornozelo das mulheres na quinta e sexta décadas de vida, embora possam ser encontrados em qualquer lugar nos membros inferiores e, mais raramente, em outras partes do corpo. Histologicamente, tumores lipomatosos fibrohistiocíticos hemosideróticos são formados por uma combinação de tecido adiposo maduro, fascículos de células fusiformes, macrófagos que contêm frequentemente hemosiderina citoplasmática, infiltrado inflamatório mononuclear e estroma, que pode ser focalmente mixoide. Há recidiva local em quase um terço dos casos. Não existe consenso na literatura se este tumor faz parte de um espectro que envolve os tumores angiectásicos hialinizantes pleomórficos e os tumores fibroblásticos mixoinflamatórios malignos, ou se configura uma entidade independente.

Relatamos um caso de uma neoplasia após o diagnóstico de tumor lipomatoso fibrohistiocítico hemosiderótico em uma mulher de 38 anos, com duas recorrências e posterior transformação sarcomatosa. Um estudo imuno-histoquímico indicou diferenciação miofibroblástica de uma neoplasia maligna. Para nosso conhecimento, há apenas poucos casos relatados de uma transformação maligna em tumores lipomatosos fibrohistiocíticos hemosideróticos.

© 2016 Sociedade Brasileira de Ortopedia e Traumatologia. Publicado por Elsevier Editora Ltda. Este é um artigo Open Access sob uma licença CC BY-NC-ND (<http://creativecommons.org/licenses/by-nc-nd/4.0/>).

## Introduction

Hemosiderotic fibrohistiocytic lipomatous tumor (HFLT) is a rare neoplasm that was initially thought to be a reactive process secondary to trauma or an excessive tissue response to chronic venous stasis, which would stimulate the proliferation of elements seen in the lesion.<sup>1</sup> Browne and Fletcher (2006) published a classic review of this tumor in which defined the clinical and histological characteristics.<sup>2</sup> Initially, HFLT was believed to be a benign lipomatous neoplasm. The contemporary understanding is that HFLT is an unencapsulated, locally aggressive neoplasm that is composed of adipocytes, hemosiderin-laden spindle cells and macrophages, as well as scattered chronic inflammatory cells. The commonest site for HFLT is the dorsum of the foot, followed by other ankle and foot sites, the dorsum of the hand, and, finally, the calf, thigh, and cheek. HFLT is most frequently found in women in their fifth or sixth decade of life.<sup>1-6</sup>

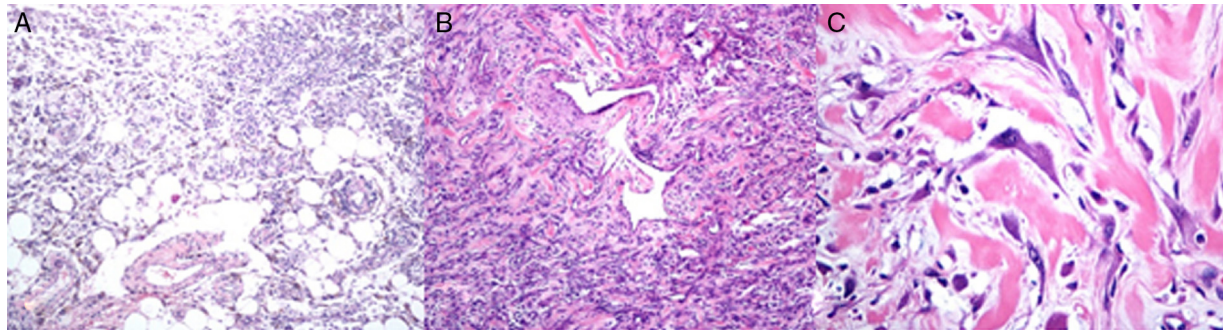
Radiologic images of the lesion reveal adipose tissue, often with septation, and features mimicking lipoma or low-grade sarcoma.<sup>7</sup> Clinical and pathological features of HFLT are similar to those of pleomorphic hyalinizing angiectatic tumor (PHAT) and myxoinflammatory fibroblastic malignant tumor (MIFS), leading authors to speculate that HFLT may be a part of a spectrum involving these two other tumor types.<sup>8-10</sup> HFLT does not produce metastases and is of uncertain lineage according to the soft-tissue tumor classification system of the World Health Organization.<sup>1</sup>

There are few reports of the malignant transformation of HFLT into MIFS.<sup>9,10</sup> Herein, we report a published case of a lesion that had previously been diagnosed, according to its morphological and by immunohistochemical (IHC) features, as HFLT.<sup>8</sup> The lesion recurred twice and later showed malignant transformation to a low-grade unclassified pleomorphic sarcoma, with an IHC study suggesting myofibroblastic differentiation.

## Case report

This case report was approved by the Ethics Committee at a tertiary public hospital. A 38-year-old female patient came to our clinic in December of 2010. She complained of a painful lesion in the back area of her left thigh, in the vicinity of prior tumor surgical resections (performed in September of 2006 and January of 2008). Previous resections led to a diagnosis of HFLT, based on morphological examination and complementary IHC study. The prior biopsies were reviewed, and the diagnosis was maintained. This case of HFLT has been previously reported in the literature.<sup>8</sup>

Magnetic resonance imaging showed a heterogeneous lesion with expansive growth and enhancement. Imaging suggested compromise to the muscle groups and subcutaneous tissues of the distal third of the left thigh, associated with an osteolytic lesion in the cortical region of the middle third of the left femur. Tumor resection was performed, and two roughly ovoid fragments of black-yellow and elastic



**Fig. 1 – (A) Hemosiderotic fibrohistiocytic lipomatous tumors (HFLT) area (hematoxylin–eosin – HE, 100×); (B) malignant transformation area of HFLT showing increased cellularity and nuclear pleomorphism (HE, 100×); (C) nuclear atypia in the malignant transformation area of HFLT (HE, 400×).**

tissue were obtained for histological evaluation. Tissues had hemorrhagic foci jointly measuring 22 cm × 18 cm × 11 cm and weighing 485 g.

Microscopy showed an infiltrative, pleomorphic malignant neoplasm, with irregular edges in the soft tissues and variable cellularity. The neoplasm was comprised of round, oval, and fusiform cells, with hyperchromatic nuclei, sometimes bizarre and eosinophilic cytoplasm, and rare mitotic figures, compatible with sarcomatous transformation of the HFLT. We also noted areas with mature and often histiocytic adipose tissue containing hemosiderin (Fig. 1). This finding suggested that these were areas of a residual HFLT. No necrotic foci were visible.

On IHC analysis, the lesion was focally positive for smooth muscle actin and desmin, but negative for S100 protein and CD34, suggesting myofibroblastic differentiation of the sarcomatous component. A cell proliferation index of approximately 5% (Ki 67) was observed. Amputation was proposed to the patient, who refused this treatment and underwent chemotherapy and radiotherapy at other hospital.

## Discussion

We compared findings from the previous resections, which yielded a diagnosis of HFLT, with the current morphology,<sup>2</sup> which exhibited malignant features. This comparison allowed us to conclude that the lesion had undergone malignant transformation to a low-grade unclassified pleomorphic sarcoma, with IHC features suggesting myofibroblastic differentiation. The presence of areas with a benign pattern similar to the initial lesion intermixed with pleomorphic and infiltrative areas, as well as the proliferative index, reinforced this conclusion.

Reports have described the presence of gene rearrangements in tumors showing mixed features, which strongly suggested a relationship of HFLT with PHAT and MIFS. Previous authors have concluded that HFLT, PHAT, and MIFS represent morphologic variants of a single entity, in which only the later has acquired the capacity to metastasize.<sup>3,8,9</sup> One histological study suggested that most, if not all, tumors diagnosed as PHATs might actually represent examples of MIFS with aberrant angiectatic hyalinized vessels. Furthermore, the vascular changes in PHAT may represent only a histologic pattern and

not a true neoplasm. Thus, MIFS and most cases of PHAT may represent different morphologic manifestations of a single entity.<sup>10</sup>

In this report, we present a case of HFLT with malignant transformation. The tumor retained areas similar to the original tumor, reinforcing the possibility that this entity is part of a spectrum of lesions with the potential for malignant evolution. After surgical resection of HFLT, patients should undergo rigorous and regular follow-up because of the possibility of sarcomatous transformation.

## Conflicts of interest

The authors declare no conflicts of interest.

## Acknowledgements

We thank Dr Christopher DM Fletcher and Dr Fred Ellinger for reviewing this case.

## REFERENCES

1. Fanburg-Smith JC, Fletcher CDM, Mertens F. Hemosiderotic fibrolipomatous tumour. In: Fletcher CD, Unni KK, Mertens F, editors. World Health Organization classification of tumours of soft tissue and bone. Lyon: IARC Press; 2013.
2. Browne TJ, Fletcher CD. Hemosiderotic fibrolipomatous tumor (so-called hemosiderotic fibrohistiocytic lipomatous tumor): analysis of 13 new cases in support of a distinct entity. *Histopathology*. 2006;48(4):453–61.
3. Hallor KH, Sciort R, Staaf J, Heidenblad M, Rydholm A, Bauer HC, et al. Two genetic pathways, t(1;10) and amplification of 3p11-12, in myxoinflammatory fibroblastic sarcoma, hemosiderotic fibrolipomatous tumour, and morphologically similar lesions. *J Pathol*. 2009;217(5):716–27.
4. Wettach GR, Boyd LJ, Lawce HJ, Magenis RE, Mansoor A. Cytogenetic analysis of a hemosiderotic fibrolipomatous tumor. *Cancer Genet Cytogenet*. 2008;182(2):140–3.
5. Moretti VM, Brooks JS, Ogilvie CM. Case report: hemosiderotic fibrohistiocytic lipomatous lesion: a clinicopathologic characterization. *Clin Orthop Relat Res*. 2010;468(10):2808–13.
6. West AT, Toms AP, Murphy J, Sultan M. Hemosiderotic fibrohistiocytic lipomatous lesion/tumour of the foot: MRI and histopathology. *Skeletal Radiol*. 2008;37(1):71–4.

7. O'Driscoll D, Athanasian E, Hameed M, Hwang S. Radiological imaging features and clinicopathological correlation of hemosiderotic fibrolipomatous tumor: experience in a single tertiary cancer center. *Skeletal Radiol.* 2015;44(5):641-8.
8. Ramalho AR, Nunes MN, Adad SJ, Leitão SA, Micheletti AM. Hemosiderotic fibrohistiocytic lipomatous lesion: case report and review of the literature. *Sao Paulo Med J.* 2009;127(3):174-6.
9. Carter JM, Sukov WR, Montgomery E, Goldblum JR, Billings SD, Fritchie KJ, et al. TGFBR3 and MGEA5 rearrangements in pleomorphic hyalinizing angiectatic tumors and the spectrum of related neoplasms. *Am J Surg Pathol.* 2014;38(9):1182-992.
10. Michal M, Kazakov DV, Hadravský L, Agaimy A, Švajdler M, Kuroda N, et al. Pleomorphic hyalinizing angiectatic tumor revisited: all tumors manifest typical morphologic features of myxoinflammatory fibroblastic sarcoma, further suggesting 2 morphologic variants of a single entity. *Ann Diagn Pathol.* 2016;20:40-3.