



Original article

Open versus arthroscopic approach in the treatment of femoroacetabular impingement: a case–control study with two-years follow up[☆]



Bruno Dutra Roos^{a,*}, Milton Valdomiro Roos^a, Antero Camisa Júnior^a, Ezequiel Moreno Ungaretti Lima^a, Maurício Domingos Betto^b

^a Hospital Ortopédico de Passo Fundo, Departamento de Ortopedia e Traumatologia, Passo Fundo, RS, Brazil

^b Hospital Ortopédico de Passo Fundo, Grupo de Cirurgia do Quadril, Passo Fundo, RS, Brazil

ARTICLE INFO

Article history:

Received 1 December 2016

Accepted 26 January 2017

Available online 9 August 2017

Keywords:

Hip joint

Femoroacetabular impingement

Hip injuries

Osteoarthritis

ABSTRACT

Objective: To compare clinical and imaging results and complications between patients treated for femoroacetabular impingement (FAI) who underwent either anterior open surgery or an arthroscopic approach, with a minimum follow-up of two years.

Methods: This retrospective case–control study included patients submitted to FAI surgical treatment between November 2007 and March 2012. Patients treated with open surgery were compared with those treated with arthroscopy. Patients were clinically assessed by the modified Harris Hip Score, Non-Arthritic Hip Score, and internal hip rotation. Patients were radiographically assessed by the center-edge angle, joint space width, alpha angle, neck-head index, degree of arthrosis, and presence of heterotopic ossification of the hip.

Results: In the study period, 56 patients (58 hips) with FAI were included; 16 underwent open surgery and 40 underwent arthroscopy. The 40 patients treated by the arthroscopic route had a mean follow-up of 29.1 months, and 75.6% presented good or excellent clinical results. The radiographic evaluation parameters progressed to normal levels. The 16 patients who underwent open surgery had a mean follow-up of 52 months, and 70.58% presented good or excellent clinical results. The radiographic evaluation parameters progressed to normal levels. Postoperative clinical and radiographic results were considered similar in both groups.

Conclusions: Arthroscopy and open surgery treatments for FAI provided comparable clinical and radiographic results. However, a higher rate of complications was observed in the open surgery group.

© 2017 Published by Elsevier Editora Ltda. on behalf of Sociedade Brasileira de Ortopedia e Traumatologia. This is an open access article under the CC BY-NC-ND license (<http://creativecommons.org/licenses/by-nc-nd/4.0/>).

[☆] Study conducted at Hospital Ortopédico de Passo Fundo, Centro de Estudos Ortopédicos, Passo Fundo, RS, Brazil.

* Corresponding author.

E-mail: brunodroos@gmail.com (B.D. Roos).

<http://dx.doi.org/10.1016/j.rboe.2017.07.007>

2255-4971/© 2017 Published by Elsevier Editora Ltda. on behalf of Sociedade Brasileira de Ortopedia e Traumatologia. This is an open access article under the CC BY-NC-ND license (<http://creativecommons.org/licenses/by-nc-nd/4.0/>).

Abordagem anterior aberta versus artroscópica no tratamento do impacto femoroacetabular: estudo caso-controle com seguimento mínimo de dois anos

R E S U M O

Palavras-chave:

Articulação do quadril
Impacto femoroacetabular
Lesões do quadril
Osteoartrite

Objetivos: Comparar os resultados clínicos e radiográficos, bem como as complicações observadas em pacientes submetidos ao tratamento cirúrgico, devido a impacto femoroacetabular, sob abordagem artroscópica ou anterior aberta, com seguimento mínimo de dois anos.

Métodos: Estudo caso-controle retrospectivo, com pacientes operados entre novembro de 2007 e março de 2012 e que foram submetidos a tratamento cirúrgico de impacto femoroacetabular. Pacientes submetidos à abordagem aberta foram comparados com pacientes submetidos à abordagem artroscópica. Os pacientes foram avaliados clinicamente pelos escores clínicos *Harris Hip* modificado, *Non Arthritic Hip* e quanto à rotação interna do quadril. Os pacientes foram avaliados radiograficamente, aferiram-se o ângulo centro-borda, a dimensão do espaço articular, o ângulo alfa, o índice colo-cabeça, o grau de artrose e a presença de ossificação heterotópica do quadril.

Resultados: Foram incluídos no estudo 56 pacientes, 16 submetidos à abordagem aberta e 40 à artroscópica. Os 40 pacientes tratados por via artroscópica foram seguidos por, em média, 29,1 meses, 75,6% apresentaram resultados clínicos bons ou excelentes. Quanto à avaliação radiográfica, observou-se correção para índices considerados normais. Os 16 pacientes operados por via aberta obtiveram seguimento médio de 52 meses, 70,58% apresentaram resultados clínicos bons ou excelentes. Quanto à avaliação radiográfica, observou-se correção para índices considerados normais. Os resultados clínicos e radiográficos pós-operatórios foram considerados semelhantes em ambos os grupos.

Conclusão: Os resultados clínicos e radiográficos do tratamento artroscópico do impacto femoroacetabular foram comparáveis aos resultados do tratamento aberto. Observamos um maior número de complicações no grupo aberto.

© 2017 Publicado por Elsevier Editora Ltda. em nome de Sociedade Brasileira de Ortopedia e Traumatologia. Este é um artigo Open Access sob uma licença CC BY-NC-ND (<http://creativecommons.org/licenses/by-nc-nd/4.0/>).

Introduction

Femoroacetabular impingement (FAI) is now recognized as a common cause of hip pain in the young population, with possible degenerative consequences.^{1,2} Both the known impact mechanisms (cam or inclusion, and pincer or impaction) are associated with pain, restricted range of motion, and decreased exercise tolerance.³ Currently, several studies have suggested that some cases that were previously considered as idiopathic hip osteoarthritis are secondary to FAI.⁴⁻⁸

Conservative treatment can be attempted initially; it consists of modifying high-impact physical activities, avoiding weighted exercises associated with excessive flexion and torsion movements that increase joint demand, and, finally, the use of anti-inflammatory medications. Surgical treatment is indicated in cases when conservative treatment brings only temporary relief.^{9,10} Some authors claim that, since it is a mechanical condition, delaying surgical treatment of the FAI may not be beneficial to the patient. However, there is still no consensus in the literature regarding this subject.^{1,2,10,11}

Surgical treatment options for FAI include open surgical correction with posterior hip dislocation (Ganz approach), anterior hip approaches (Smith-Petersen, Hueter, Somerville, and anterior extensible, among others),

videoarthroscopic surgery, and a combination of arthroscopic technique and anterior mini-incision.¹⁻⁹

The present study aimed to compare the clinical and radiographic results and the complications related to patients who underwent surgical treatment of FAI performed by the Hip Surgery Group of this institution using the arthroscopic or anterior open (iliofemoral) approach, with a minimum two year follow-up.

Material and methods

This was a retrospective case-control study that included patients who underwent arthroscopic and open FAI treatment, performed by the Hip Surgery Group, operated consecutively between November 2007 and March 2012. During this period, 62 patients (64 hips) underwent this treatment; all arthroscopic surgeries were performed by the same surgeon (BDR) through the extracapsular approach¹² and, similarly, all open surgeries were performed by the same surgeon (MVR) through the iliofemoral approach. Exclusion criteria for this study were: patients with isolated pincer-type IFA (four cases), losses to follow-up (one case), and follow-up of less than two years (one case). All patients were called in for a reassessment. The study was approved by the Research Ethics Committee.

According to the established criteria, 56 patients (58 hips) met all the necessary requirements for this study. Patients were divided into two groups: Group I included cases that underwent arthroscopic surgery, and Group II, those that underwent open approach.

Group I (arthroscopic treatment) included 40 patients; 36 (87%) were male, and the mean age was 36.12 years (SD=8.7, range: 21–47 years). The right hip was operated on in 20 cases (48.78%), and the left hip, in 21 (51.21%); one case was operated bilaterally at different times.

Group II (open approach) included 16 patients; 11 (68.75%) were male, and the mean age was 35.76 years (SD=9.5, range: 19–47 years). The right hip was operated on in eight cases (47.05%), and the left, in nine (52.94%); one case was operated bilaterally at different times.

Regarding the clinical aspects, patients were assessed pre- and postoperatively through the Harris Hip Score, modified by Byrd *apud* Guimarães¹³ (MHHS); the Non-Arthritic Hip Score¹⁴ (NAHS); and the range of internal rotation (IR) of the affected hip (with goniometer for gauging).

According to the Harris Hip Score modified by Byrd,¹³ results were stratified as poor (MHHS < 70 points), fair (70–79 MHHS), good (MHHS 80–89), or excellent (MHHS 90–100).¹⁰

All patients were assessed by radiographs (anteroposterior [AP] view of the hip in the orthostatic position, Dunn 45°, Dunn 90°, and Lequesne's false profile),¹⁵ as well as magnetic resonance imaging for the diagnosis of chondral and labral injuries. Pincer-type FAI was diagnosed by measuring the angle of femoral head coverage and acetabular version on AP radiographs of the hip in the orthostatic position and in Lequesne's false profile. Cam-type FAI was defined as alpha angle greater than 50° in Dunn 45° radiographs.¹⁶

In the preoperative period, the following were measured: Tönnis¹⁷ hip arthrosis classification; center-edge angle (θ CE); size of the smallest joint space, in millimeters, on AP radiographs of the hip in the orthostatic position; alpha angle, as described by Meyer¹⁶ in Dunn 45° radiographs ($\theta\alpha$); and lateral view head-neck index (NHI) in Dunn 90° radiographs.¹⁵ In the late postoperative period, the size of the smallest joint space in millimeters, the $\theta\alpha$, and the NHI were assessed for comparison with pre-operative measurements; the presence of heterotopic hip ossification was assessed in accordance with Brooker *et al.*¹⁸ To avoid inter- and intra-observer errors, the measurements were made by two surgeons from the hip group. In cases of disagreement of more than three degrees in the angular measurements or of more than 1 mm in the minimum joint space, a new evaluation was performed by a third surgeon, and a consensus was then reached. The mean magnification of the AP radiograph of the hip was 15%, which was quantified by the equipment.

The Wilcoxon test (SPSS version 18.0, SPSS, Chicago, IL, USA) was the statistical method used to analyze the intergroup paired variables (MHHS, NAHS, IR, alpha angle, and pre- and postoperative NHI). The Mann-Whitney test was applied for the intergroup analysis of the same variables; both tests were considered statistically significant when $p < 0.05$. In order to assess the homogeneity between the groups, the chi-squared test was applied for the preoperative measurements.

Results

According to the preoperative statistical analysis, both groups were considered homogeneous.

In Group I (arthroscopy), the mean follow-up was 29.1 months (24–42). Regarding the assessment of the MHHS score, the mean preoperative score was 65 points (SD=9.8, range 38–77) and the mean postoperative, 88 (SD=11, range 60–100), with a mean postoperative increase of 22.1. According to the established criteria, 31 (75.60%) cases presented good or excellent clinical results; eight (19.51%), fair; and three (7.31%), poor. Regarding the assessment of the MHHS score, the mean preoperative score was 68.8 points (SD=12.5, range 45–80) and the mean postoperative, 92.5 (SD=10, range 60–100), with a mean postoperative increase of 21.5. The mean pre-operative hip IR was 5° (SD=10°, range –15° to 30°) and postoperative, 20° (SD=12.5°, range 5°–40°), with a mean postoperative increase of 16.4°. Statistically significant differences were observed ($p < 0.001$) in the pre- and postoperative measurements of the MHHS and NAHS clinical scores, as well as in hip IR.

Cam-type FAI was observed in 29 hips (70.73%) and mixed-type FAI, in 12 (28.27%). In 20 cases (48.78%) isolated femoral osteochondroplasty was performed during the arthroscopic surgical treatment; in the remaining 21 cases (51.21%), other complementary procedures were performed, such as acetabular osteochondroplasty in mixed-type FAIs (12 cases [29.26%]), debridement of the acetabular labrum (seven cases [17.07%]), acetabular chondral microfracture in Outerbridge grade 4 chondral injuries (four cases [9.75%]) and labrum reattachment in accordance with Fry and Domb *apud* Ribas *et al.*¹⁹ (five cases [12.19%]).

Regarding the preoperative radiographic evaluation, 13 cases (31.7%) presented arthrosis classified as Tönnis grade 0, 21 (51.21%) as Tönnis 1, and seven (17.07%) as Tönnis 2; no cases were classified as Tönnis 3. The mean CE angle was 35.78° (24°–46°). No patient presented CE angle lower than 20° (hip developmental dysplasia). In the preoperative period, the mean smallest joint space was 3.31 mm (2–4 mm); no statistically significant difference was observed in comparison with the late postoperative result ($p = 1.000$). Regarding the alpha angle, the mean postoperative reduction was 32.9°; the mean preoperative angle was 76° (SD=14°, range 60°–100°), and the mean postoperative, 44° (SD=12.5°, range 32°–55°). Regarding the HNI, the mean postoperative increase was 0.10; the mean preoperative value was 0.10 (SD=0, range 0.06–0.14), and the mean postoperative, 0.20 (SD=0.1, range 0.16–0.32). A statistically significant difference ($p < 0.001$) was observed for the pre- and postoperative alpha angle and HNI. In the late postoperative period, 36 cases (87.80%) did not present heterotopic ossification; in four patients (9.75%), heterotopic ossification was found and classified as Brooker¹⁸ grade 1 and one case (2.43%), as grade 3 (Fig. 1).

Regarding complications, one case (2.43%) presented deep venous thrombosis, one case (2.43%) presented heterotopic ossification classified as Brooker¹⁸ grade 3, and one case (2.43%) presented transient paresthesia of the pudendal nerve. There were two cases (4.87%) with persistent pain (both with Tönnis 2 arthrosis); total hip arthroplasty has been indicated for one of these patients.

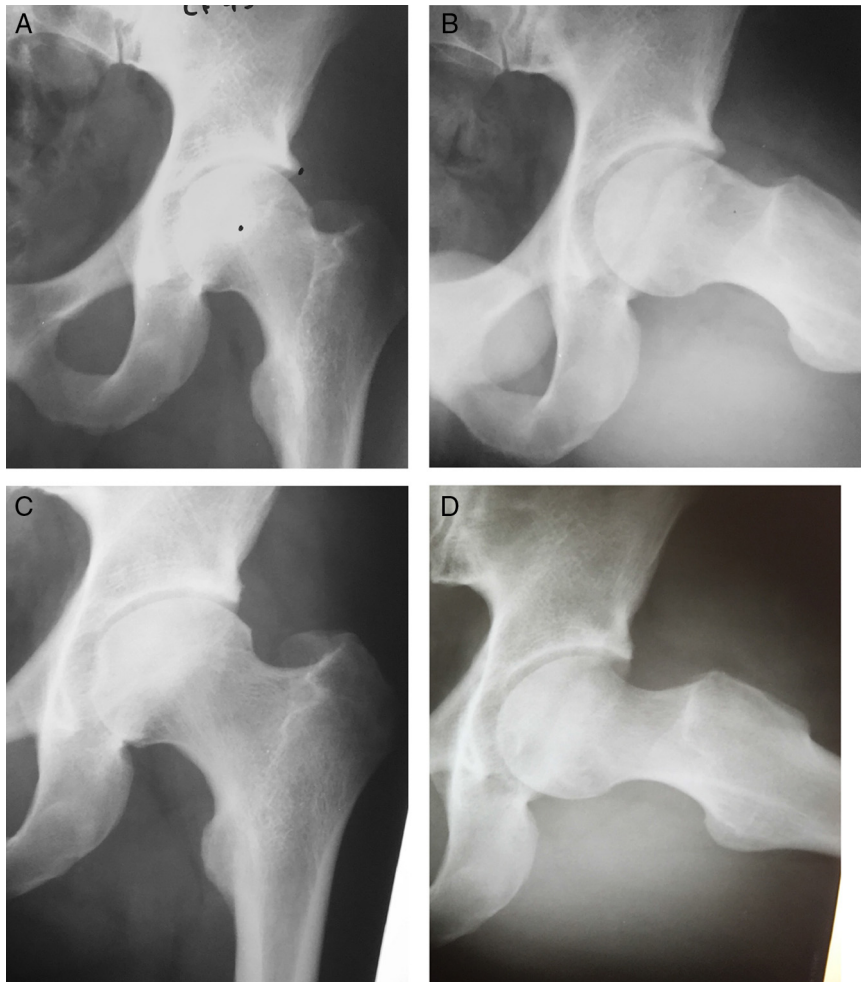


Fig. 1 – Male patient aged 28 years, arthroscopic surgery group. A and B, preoperative radiographic evidence of mixed-type FAI, CE angle: 39°; α angle: 64°. C and D, post-operative radiographic imaging 3 years and 2 months after femoral and acetabular osteochondroplasty, combined with labral re-fixation. CE angle: 28°; α angle: 34°.

In Group II (open), the mean follow-up was 52 months (43–74). Regarding the assessment of the MHHS score, the mean preoperative score was 63 points (SD=9, range 48–70) and the mean postoperative, 88 (SD=22, range 58–94), with a mean postoperative increase of 21.7. According to the established criteria, 12 (70.58%) cases presented good or excellent clinical results; two (11.76%), fair; and three (17.64%), poor. Regarding the assessment of the NAHS score, the mean preoperative score was 65 points (SD=11.3, range 48.75–77.5) and the mean postoperative, 90 (SD=20, range 60–95), with a mean postoperative increase of 20.4. The mean pre-operative hip IR was 5° (SD=10°, range -5° to 20°) and postoperative, 25° (SD=10°, range 15°–40°), with a mean postoperative increase of 21.2°. Statistically significant differences were observed ($p < 0.001$) in the pre- and postoperative measurements of the MHHS and NAHS clinical scores, as well as in hip IR.

Cam-type FAI was observed in 12 hips (70.58%) and mixed-type FAI, in five (29.42%). In 12 cases (70.58%), during the arthroscopic surgical treatment, isolated femoral osteochondroplasty was performed; in the remaining five cases (29.42%, mixed-type FAIs), acetabular osteochondroplasty with labral re-fixation was also performed.

Regarding the preoperative radiographic evaluation, nine cases (52.9%) presented arthrosis classified as Tönnis grade 0, six (35.29%) as Tönnis 1, and two (11.76%) as Tönnis 2; no cases were classified as Tönnis 3. The mean CE angle was 32.82° (23°–44°). No patient presented CE angle lower than 20°. In the preoperative period, the mean smallest joint space was 3 mm (2–4 mm); no statistically significant difference was observed in comparison with the late postoperative result ($p = 0.58$). Regarding the alpha angle, the mean postoperative reduction was 32.5°; the mean preoperative angle was 72° (SD=12.5°, range 60°–90°), and the mean postoperative, 40° (SD=9°, range 32°–52°). Regarding the HNI, the mean postoperative increase was 0.12; the mean preoperative value was 0.11 (SD=0, range 0.08–0.15), and the mean postoperative value, 0.22 (SD=0.1, range 0.2–0.3). A statistically significant difference ($p < 0.001$) was observed for the pre- and postoperative alpha angle and HNI. In the late postoperative period, 12 cases (70.58%) did not present heterotopic ossification; in five patients (29.41%), the heterotopic ossification was found and classified as Brooker¹⁸ grade 1 (Fig. 2).

Regarding complications, in Group II four cases (23.5%) of lateral femoral cutaneous nerve injury were observed. There

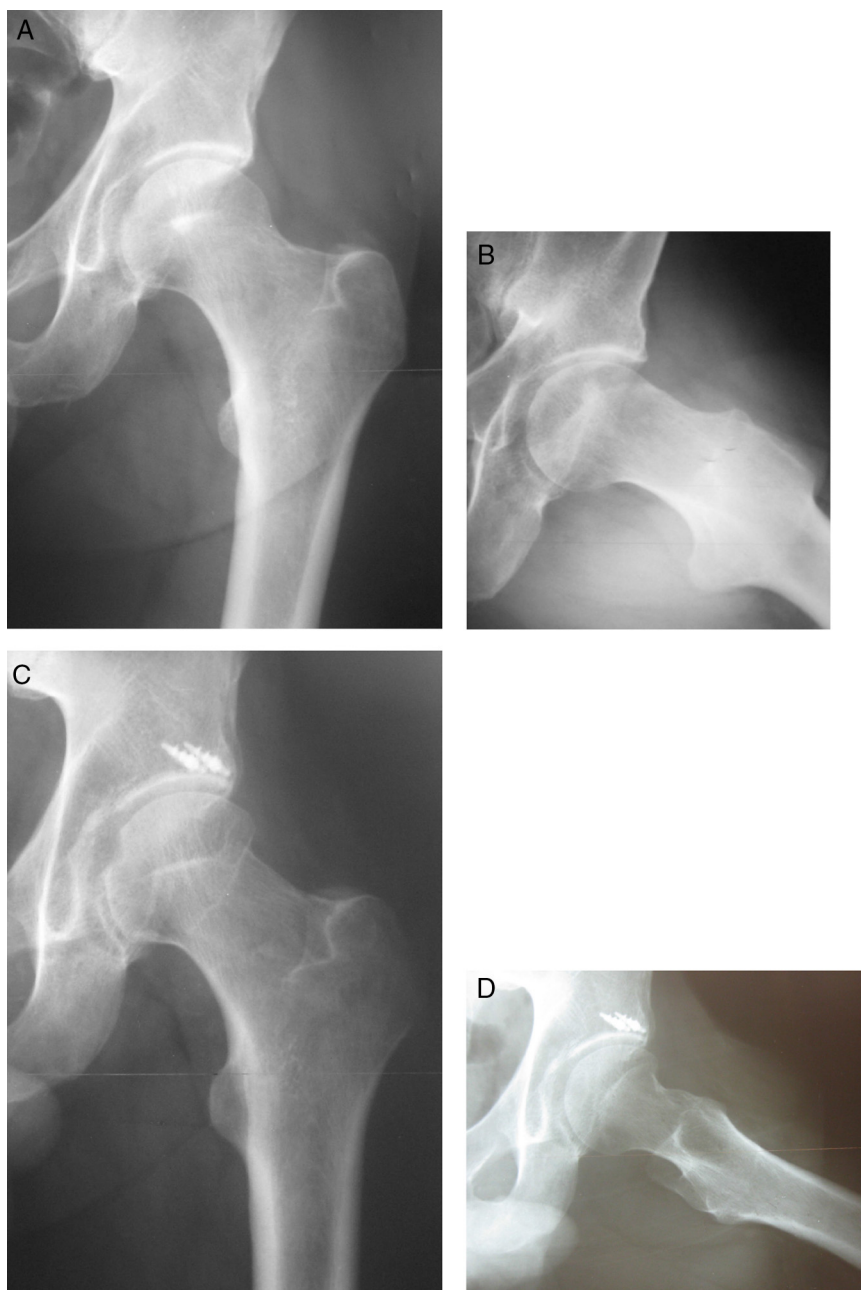


Fig. 2 – Male patient aged 37 years, open surgery group. A and B, preoperative radiographic evidence of mixed-type, CE angle: 32°; α angle: 62°. C and D, post-operative radiographic imaging 4 years and 4 months after femoral and acetabular osteochondroplasty, combined with labral re-fixation. CE angle: 28°; α angle: 32°.

were four cases (23.5%) of persistent pain; two cases (both with Tönnis 2 arthrosis) presented progression of the joint degeneration and total hip arthroplasty was indicated.

No major complications, such as avascular necrosis of the femoral head, femoral neck fracture, or infection were observed.

According to the statistical analysis, both groups presented similar postoperative results regarding the clinical and radiographic evaluation (Tables 1-3).

Discussion

The surgical treatment of FAI is based on the remodeling of the proximal femur and acetabulum, as well as in the treatment of chondral and labral injuries, in order to reduce the impingement of the femur against the acetabular ridge and therefore improve the hip range of motion.¹⁻⁸

Table 1 – Results of the hip arthrosis assessment in patients submitted to surgical treatment of femoroacetabular impingement.

Groups	Evaluation	Time	Median	IQR	p
Open surgery	Tönnis grade 0	Pre	9 (52.9%)		
		Post	Not assessed		
	Tönnis grade 1	Pre	6 (35.29%)		
		Post	Not assessed		
	Tönnis grade 2	Pre	2 (11.76%)		
		Post	Not assessed		
	Tönnis grade 3	Pre	0		
		Post	Not assessed		
Smallest joint space (mm)	Pre	3 (SD 1, range 2 to 4)	1	0.58	
	Post	2.85 (SD 1.3, range 1.5 to 4)	1.3		
Arthroscopic surgery	Tönnis grade 0	Pre	13 (31.7%)		
		Post	Not assessed		
	Tönnis grade 1	Pre	21 (51.21%)		
		Post	Not assessed		
	Tönnis grade 2	Pre	7 (17.07%)		
		Post	Not assessed		
	Tönnis grade 3	Pre	0		
		Post	Not assessed		
Smallest joint space (mm)	Pre	3.31 (SD 1, range 2 to 4)	1	1.000	
	Post	3.31 (SD 1, range 2 to 4)	1		

IQR, interquartile range.

Table 2 – Results of the radiographic measurements of patients submitted to surgical treatment of femoroacetabular impingement.

Group	Evaluation	Time	Value	IQR	p
Open surgery	Alpha angle (degree, median)	Pre	72° (SD 12.5°, range 52° to 87°)	12.5	<0.001
		Post	40° (SD 9°, range 32° to 48°)	9	
	NHI (median)	Pre	0.11 (SD 0, range 0.08 to 0.15)	0	<0.001
		Post	0.22 (SD 0.1, range 0.2 to 0.3)	0.1	
	CE θ (mean, degree)	Pre	32.82° (23° to 44°)		
		Post	Not assessed		
Arthroscopic surgery	Alpha angle (degree, median)	Pre	76° (SD 11°, range 60° to 88°)	14	<0.001
		Post	44° (SD 12.5°, range 32° to 55°)	12.5	
	NHI (median)	Pre	0.10 (SD 0, range 0.06 to 0.14)	0	<0.001
		Post	0.20 (SD 0.1, range 0.16 to 0.32)	0.1	
	CE θ (mean, degree)	Pre	35.78° (27° to 46°)		
		Post	Not assessed		

IQR, interquartile range.

Table 3 – Results of the functional clinical evaluation of patients submitted to surgical treatment of femoroacetabular impingement.

Group	Evaluation	Time	Median, SD, and range	IQR	p
Open surgery	MHHS	Pre	63 (SD 9, range 48 to 70)	9	<0.001
		Post	88 (SD 22, range 58 to 94)	22	
	NAHS	Pre	65 (SD 11.3, range 48.75 to 77.5)	11.3	<0.001
		Post	90 (SD 20, range 60 to 95)	20	
	Internal rotation	Pre	5 (SD 10°, range -5° to 20°)	10	<0.001
		Post	25 (SD 10°, range 15° to 40°)	10	
Arthroscopic surgery	MHHS	Pre	65 (SD 9.8, range 38 to 77)	9.8	<0.001
		Post	88 (SD 11, range 60 to 100)	11	
	NAHS	Pre	68.8 (SD 12.5, range 45 to 80)	12.5	<0.001
		Post	92.5 (SD 10, range 60 to 100)	10	
	Internal rotation	Pre	5 (SD 10°, range -15° to 30°)	10	<0.001
		Post	20 (SD 12.5°, range 5° to 40°)	12.5	

IQR, interquartile range.

In the literature, several authors have presented results of the surgical treatment of FAI, whether using Ganz's open approach, anterior approaches (Smith-Petersen, Hueter, etc.), arthroscopic technique, or the combination of arthroscopic technique and anterior mini-approach. To date, the Ganz approach is considered the gold standard FAI treatment.^{2,6} The results are generally positive regarding symptom relief and improvement of hip mobility and level of physical activity; they also suggest joint preservation in the long term.¹⁻⁹

Most studies that compare the open and arthroscopic techniques are comparative meta-analyses. Matsuda et al.,¹ in a comparative systematic review, assessed 18 articles that presented results of surgical hip dislocation techniques and anterior and arthroscopic mini approach; they concluded that all of these techniques are capable of improving pain and function in the medium term. However, open techniques presented a greater number of complications related to lateral cutaneous-femoral nerve injury in the anterior mini approach; in surgical hip dislocation, they presented a greater number of complications related to the site of greater trochanter osteotomy (pseudoarthrosis and local pain). Botser et al.²⁰ found similar results in a meta-analysis of 26 articles, and concluded that there is evidence that the arthroscopic technique presents fewer complications and faster rehabilitation. Recently, Domb et al.²¹ prospectively paired ten patients undergoing surgical treatment for FAI by Ganz surgical dislocation technique (mean follow-up of 24.8 months) with 20 patients undergoing treatment through the arthroscopic technique (mean follow-up of 25.5 months). They concluded that patients submitted to the arthroscopic treatment presented a significantly greater improvement in the clinical scores evaluated.

The iliofemoral anterior approach described by Smith-Petersen²² is also used in the treatment of FAI, allowing direct access to the hip joint. However, it does not provide good access to the acetabulum and does not allow the correction of alterations in femoral orientation.¹ Injury of the lateral femoral cutaneous nerve is the most prevalent complication, which in most cases presents spontaneous resolution. After one year of follow-up, Ribas et al.¹⁹ reported significant improvement in a series of 35 FAI hips surgically treated through the anterior approach. A 23° increase in hip IR was observed, as well as a significant improvement in the clinical parameters evaluated. Regarding complications, femoral lateral cutaneous nerve dysfunction was observed in six cases (17.1%), being transient in five. Laude et al.²³ evaluated 100 hips operated with anterior approach combined with arthroscopic assistance (mean follow-up of 4.9 years); a mean increase of 29.1 points was observed for NAHS, and 11% of patients had undergone arthroplasty at the end of follow-up.

Arthroscopy has been widely diffused in the treatment of FAI due to its short rehabilitation period and good access to the hip joint. Complications are usually related to the time of more frequent injuries such as those of the lateral pudendal and lateral femoral cutaneous nerves, and rarer injuries such as to the sciatic nerve (0-12.9%).^{1,10-12,20} Phillipon et al.¹¹ used the arthroscopic technique for FAI treatment in 112 patients (mean follow-up of 2.3 years) and found a mean increase of 24 points in the MHHS, without complications. In a recent publication, Bryrd and Jones¹⁰ evaluated 207 hips (mean follow-up

of 16 months) and found a mean increase of 20 points in the MHHS; complications were observed in 1.5% of cases and in 0.5% of cases progressed to total hip arthroplasty. Horisberger et al.²⁴ applied a similar technique to 105 hips of 88 patients (mean follow-up of 2.3 years) and observed a mean postoperative increase of 28 points in the NAHS, with a 1.9% complication rates for sciatic or pudendal nerve neuropraxia and 11% for neuropraxia of the lateral femoral cutaneous nerve. In 8.6% of cases, there was a need for conversion to hip arthroplasty.

In the present study, results similar to those in the literature were observed for both groups. A postoperative improvement in the clinical evaluation of the patients was observed, and the radiographic parameters progressed to levels considered normal. The higher number of hip arthroplasty indications in the open group can be explained by the longer follow-up of these patients (mean of 52 months). In the arthroscopic group, a lower number of postoperative complications was observed. A longer follow-up of this group is necessary in order to define whether the postoperative joint preservation and clinical results will remain satisfactory.

The limitations of the present study were the small number of patients in the open group, as well as the predominance of male patients and the short follow-up time (29.1 months) in the arthroscopic group.

Conclusion

The clinical and radiographic results of the arthroscopic treatment of FAI were comparable to those of the open anterior approach. A greater number of complications were observed in the open group.

Conflicts of interest

The authors declare no conflicts of interest.

REFERENCES

1. Matsuda DK, Carlisle JC, Arthurs SC, Wiekrs CH, Phillipon MJ. Comparative systematic review of the open dislocation, mini-open, and arthroscopic surgeries for femoroacetabular impingement. *Arthroscopy*. 2011;27(2):252-69.
2. Ganz R, Parvizi J, Beck M, Leuning M, Noltzi H, Siebenrock KA. Femoroacetabular impingement: a cause for osteoarthritis of the hip. *Clin Orthop Relat Res*. 2003;(417):112-20.
3. Srinivasan SC, Hosny HA, Williams MR. Combined hip arthroscopy and limited open osteochondroplasty for anterior femoroacetabular impingement: early patient reported outcomes. *Hip Int*. 2013;23(2):218-24.
4. Ito K, Minka MA, Leuning M, Werlen S, Ganz R. Femoroacetabular impingement and the cam-effect. A MRI-based, quantitative anatomical study of the femoral head-neck offset. *J Bone Joint Surg Br*. 2001;83(2):171-6.
5. Goodman DA, Feighan JE, Smith AD, Latimer B, Buly RL, Cooperman DR. Subclinical slipped capital femoral epiphysis. Relationship to osteoarthritis of the hip. *J Bone Joint Surg Am*. 1997;79(10):1489-97.
6. Ganz R, Gill TJ, Gautier E, Ganz K, Krugel N, Berlemann U. Surgical dislocation of the adult hip. A technique with full

- access to the femoral head and acetabulum without the risk of avascular necrosis. *J Bone Joint Surg Br.* 2001;83(8):1119-24.
7. Fitzgerald RH Jr. Acetabular labrum tears. Diagnosis and treatment. *Clin Orthop Relat Res.* 1995;311:60-8.
 8. Seldes RM, Tan V, Hunt J, Katz M, Winiarski R, Fitzgerald RH Jr. Anatomy, histologic features, and vascularity of the adult acetabular labrum. *Clin Orthop Relat Res.* 2001;382:232-40.
 9. Guanche CA, Bare A. Arthroscopic treatment of femoroacetabular impingement. *Arthroscopy.* 2006;22(1):95-106.
 10. Byrd JW, Jones KS. Arthroscopic management of femoroacetabular impingement: minimum 2-year follow-up. *Arthroscopy.* 2011;27(10):1379-88.
 11. Philippon MJ, Briggs KK, Yen KM, Kuppersmith DA. Outcomes following hip arthroscopy for femoroacetabular impingement with associated condrolabral dysfunction: minimum two years follow up. *J Bone Joint Surg Br.* 2009;91(1):16-23.
 12. Roos BD, Roos MV, Camisa Júnior A, Lima EMU, Gyboski DP, Martins LS. Abordagem extracapsular para tratamento do impacto femoroacetabular: resultados clínicos, radiográficos e complicações. *Rev Bras Ortop.* 2015;50(4):430-7.
 13. Guimarães RP, Alves DPL, Azuaga TL, Ono NK, Honda E, Polesello GC, et al. Tradução e adaptação transcultural do Harris Hip Score modificado por Byrd. *Acta Ortop Bras.* 2010;18(6):339-43.
 14. Christensen CP, Althausen PL, Mittleman MA, Lee JA, McCarthy JC. The non arthritic hip score: reliable and validated. *Clin Orthop Relat Res.* 2003;406:75-83.
 15. Clohisy JC, Carlisle JC, Beaulé PE, Kim Y, Trousdale RT, Sierra RJ, et al. A systematic approach to the plain radiographic evaluation of the young adult hip. *J Bone Joint Surg Am.* 2008;90(4):47-66.
 16. Meyer DC, Beck M, Ellis T, Ganz R, Leunig M. Comparison of six radiographic projections to assess femoral head/neck asphericity. *Clin Orthop.* 2006;445:181-5.
 17. Busse J, Gasteiger W, Tönnis D. A new method for roentgenologic evaluation of the hip joint - the hip factor. *Arch Orthop Unfallchir.* 1972;72(1):1-9.
 18. Brooker AF, Bowermann JW, Robinson RA, Riley RH Jr. Ectopic ossification following total hip replacement. Incidence and method of classification. *J Bone Joint Surg Am.* 1973;55(8):1629-32.
 19. Botser IB, Smith TW, Nasser R, Domb BG. Open surgical dislocation versus arthroscopy for femoroacetabular impingement: a comparison of clinical outcomes. *Arthroscopy.* 2011;27(2):270-8.
 20. Domb BG, Stake CE, Botser IB, Jackson TJ. Surgical dislocation of the hip versus arthroscopic treatment of femoroacetabular impingement: a prospective matched-pair study with average 2-year follow-up. *Arthroscopy.* 2013;29(9):1506-13.
 21. Smith-Petersen MN. Treatment of malum coxae senilis, old slipped upper capital femoral epiphysis, intrapelvic protrusion of the acetabulum, and coxae plana by means of acetabuloplasty. *J Bone Joint Surg Am.* 1936;18:869-80.
 22. Ribas M, Marín-Peña OR, Regenbrecht B, De La Torre B, Villarubias JM. Hip osteoplasty by an anterior minimally invasive approach for active patients with femoroacetabular impingement. *Hip Int.* 2007;17(2):91-8.
 23. Laude F, Sariali E, Nogier A. Femoroacetabular impingement treatment using arthroscopy and anterior approach. *Clin Orthop Relat Res.* 2009;467(3):747-52.
 24. Horisberger M, Brunner A, Herzog RF. Arthroscopic treatment of femoroacetabular impingement of the hip. *Clin Orthop Relat Res.* 2010;468(1):182-90.